

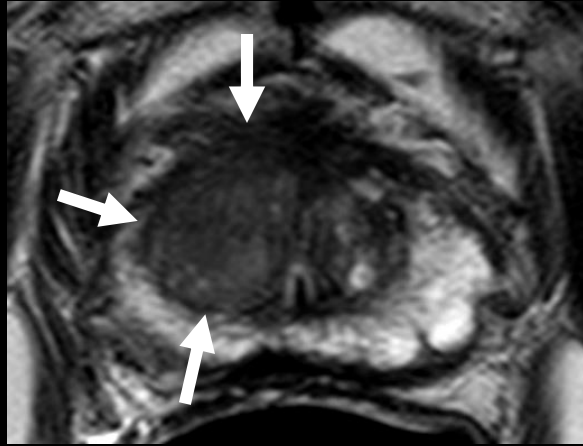
Incidental Pharyngeal Cancer Identified at PSMA PET

Peter L. Choyke M.D., Baris Turkbey M.D.

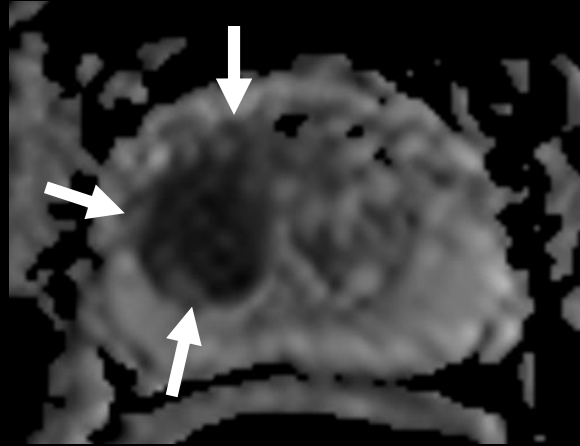
Molecular Imaging Program, NCI, NIH



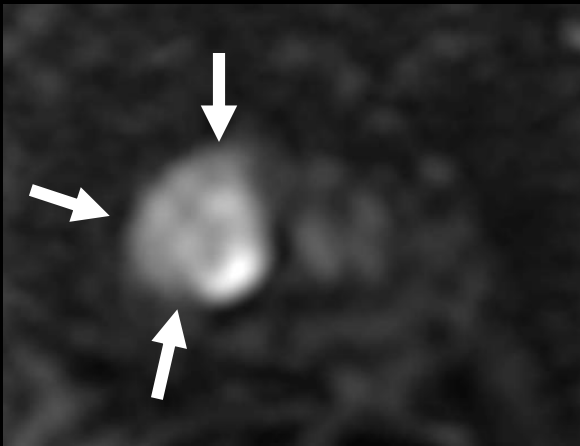
73-year-old man with serum PSA=15.80ng/ml



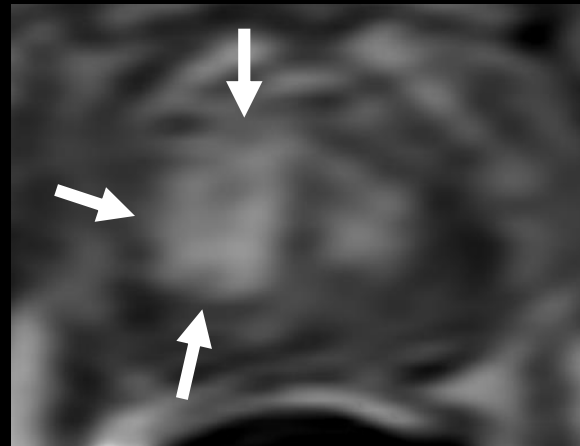
T2W MRI



ADC map



b2000 DW MRI

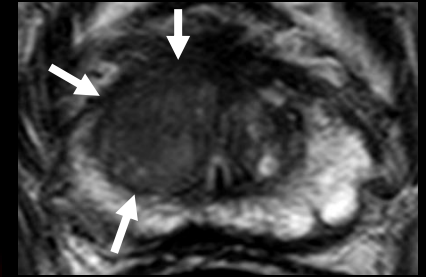
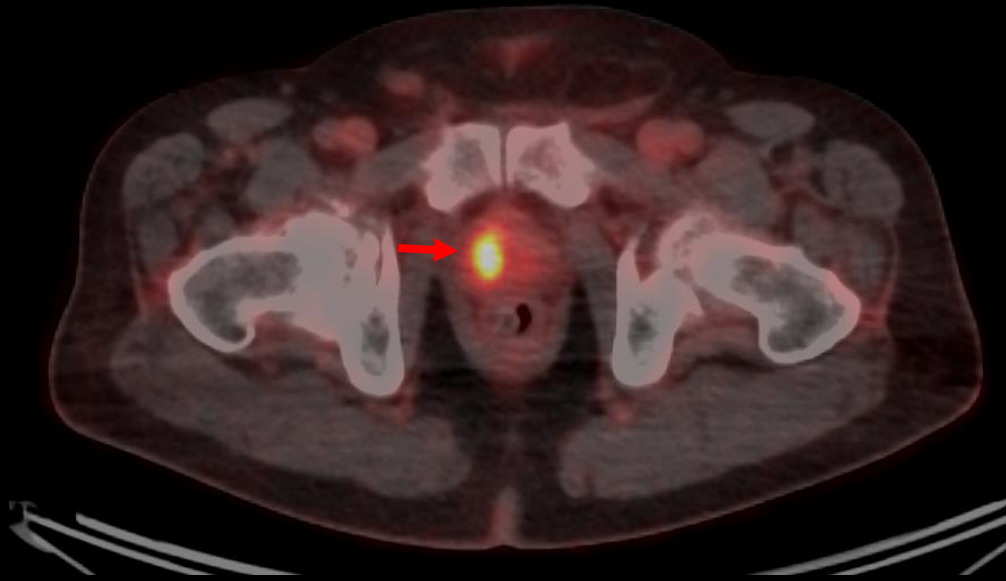
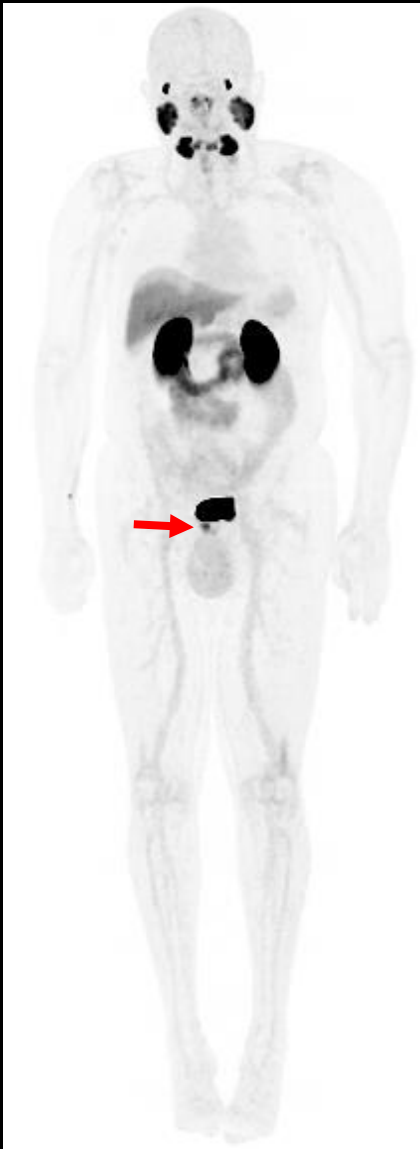

DCE MRI

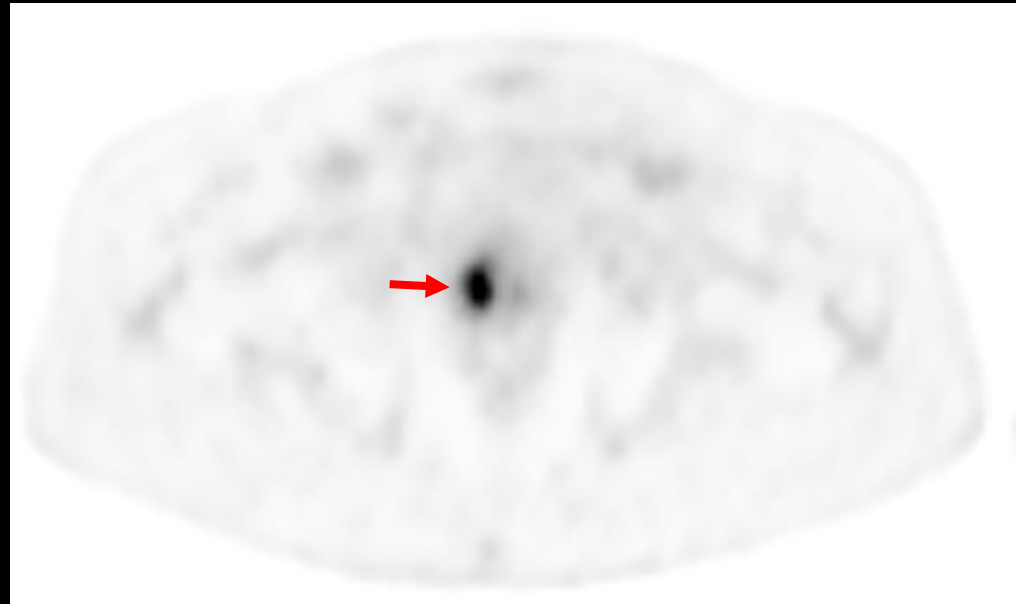
MRI of the Prostate:
Right apical-mid
transition zone lesion
(PI-RADS: T2W: 5,
DWI: 5, DCE: +,
Overall: category 5)

TRUS/MRI Fusion
Guided biopsy:
Gleason 4+5 Prostate
adenocarcinoma

Staging Evaluation with ^{18}F -DCFPyL PET (PSMA Targeting PET)



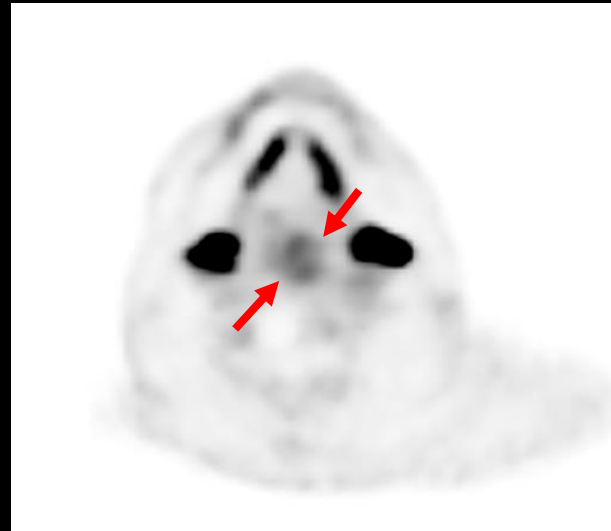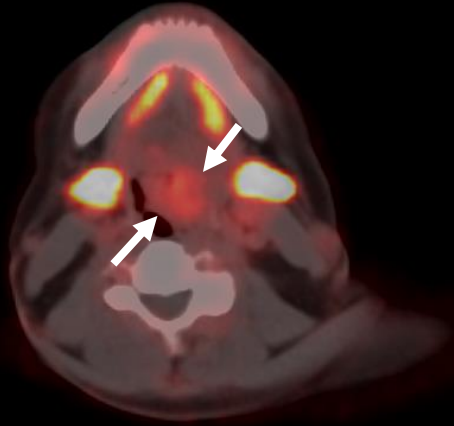
Axial T2W MRI



Intense DCFPyL uptake within the right apical-mid TZ lesion ($\text{SUV}_{\text{max}} 13.3$), which is concordant with MRI findings

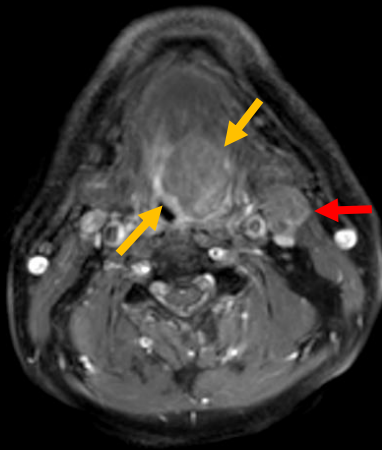
Staging Evaluation with ^{18}F -DCFPyL PET (PSMA Targeting PET)

^{18}F -DCFPyL PET

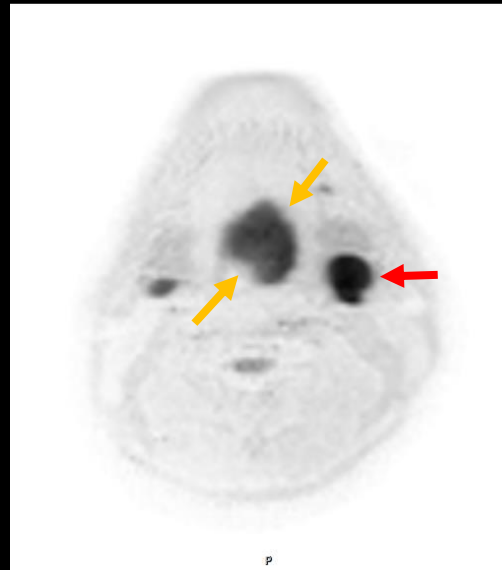

Incidental DCFPyL uptake within the left hypopharynx with soft tissue thickening (SUV_{max} 4.6)

MRI of the neck



Contrast enhanced T1W MRI



DW MRI

Contrast enhanced T1W MRI and DW MRI confirms presence of mass which is suspicious for pharyngeal carcinoma. Additionally noted includes a left sided adenopathy (red arrow)

Teaching Points

- PSMA PET is a strong imaging method to locate and stage high risk prostate cancer lesions.
- PSMA PET can also demonstrate incidental malignancies (e.g. renal cell carcinoma, thyroid cancer, colorectal carcinoma, pharyngeal carcinoma, soft tissue sarcoma).
- Being aware of physiologic uptake patterns (e.g. salivary glands) and careful evaluation of the entire organ systems at PSMA PET is important as this novel imaging technique is becoming more available in clinical care.

References

- Sheikhbahaei S, Afshar-Oromieh A, Eiber M, Solnes LB, Javadi MS, Ross AE, Pienta KJ, Allaf ME, Haberkorn U, Pomper MG, Gorin MA, Rowe SP. Pearls and pitfalls in clinical interpretation of prostate-specific membrane antigen (PSMA)-targeted PET imaging. *Eur J Nucl Med Mol Imaging*. 2017 Nov;44(12):2117-2136.
- Joshi A, Nicholson C, Rhee H, Gustafson S, Miles K, Vela I. Incidental Malignancies Identified During Staging for Prostate Cancer With (68)Ga Prostate-specific Membrane Antigen HBED-CC Positron Emission Tomography Imaging. *Urology*. 2017 Jun;104:e3-e4.
- Plouznikoff N, Woff E, Artigas C, Alexiou J, Flamen P. Incidental Detection of a Radiation-Induced Soft-Tissue Sarcoma on 68Ga-PSMA PET/CT in a Patient Previously Treated for Prostate Cancer. *Clin Nucl Med*. 2019 Apr 12.
- Malik D, Sood A, Mittal BR, Singh H, Basher RK, Shukla J, Bhattacharya A, Singh SK. Nonspecific Uptake of (68)Ga-Prostate-Specific Membrane Antigen in Diseases other than Prostate Malignancy on Positron Emission Tomography/Computed Tomography Imaging: A Pictorial Assay and Review of Literature. *Indian J Nucl Med*. 2018 Oct-Dec;33(4):317-325.