

Patient history

- 59 year old African American male with family history of prostate cancer
- 2011
 - PSA : 4.1
 - Random 12 core biopsy: Left apex 1 core of 12 Gleason (3+3)
- 2013 Active surveillance
 - PSA: 5.3
 - Repeat random biopsy: Left apex 1/12 Gleason (3+3)

Prostate MRI Case

- Rosaleen Parsons MD. FSAR,FACR
- Rosaleen.Parsons@fccc.edu

Patient history

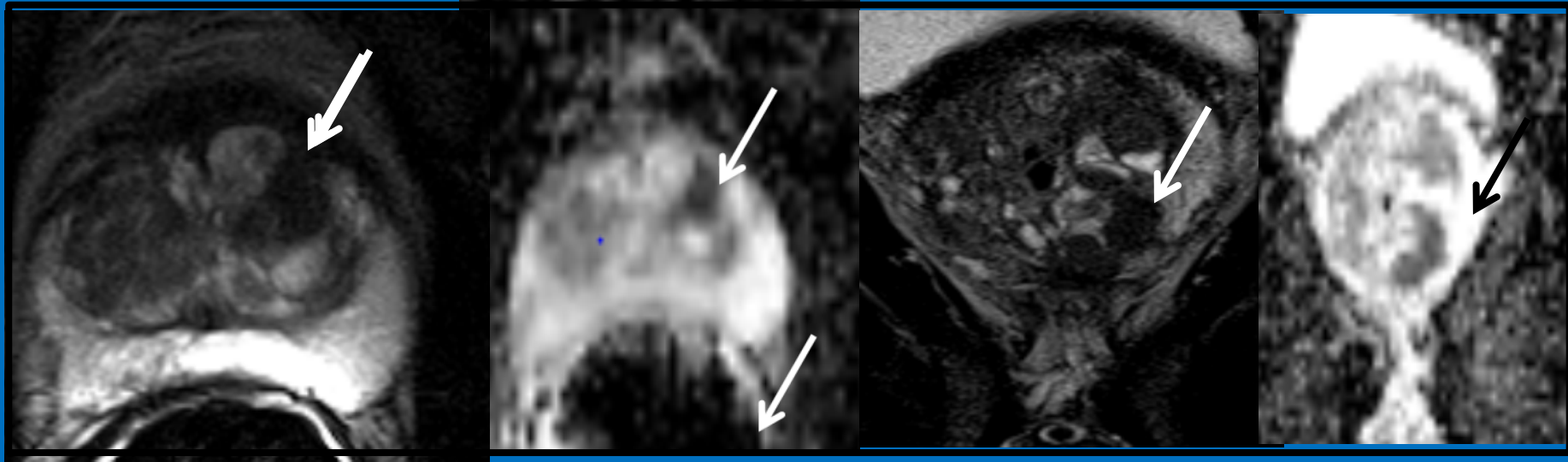
- **2015**
 - **PSA: 7**
 - **Patient undergoes Endorectal Prostate MRI**
 - **Pi Rads 4 lesion reported left Ant transitional zone**
 - **Repeat random and fusion biopsy**
 - **Left Transitional zone lesion Gleason 6(3+3)**
 - **No other cancer detected**

Patient history

- **2017 Active surveillance**
 - PSA: 9
 - Repeat MRI Left TZ lesion slightly increased insize now meets criteria for Pi Rad 5
 - Repeat targeted and random biopsy lesion left apex now Gleason 7(3+4)
 - Robotic prostatectomy performed confirms above involving 15% of gland
 - No extracapsular disease

Imaging

2015



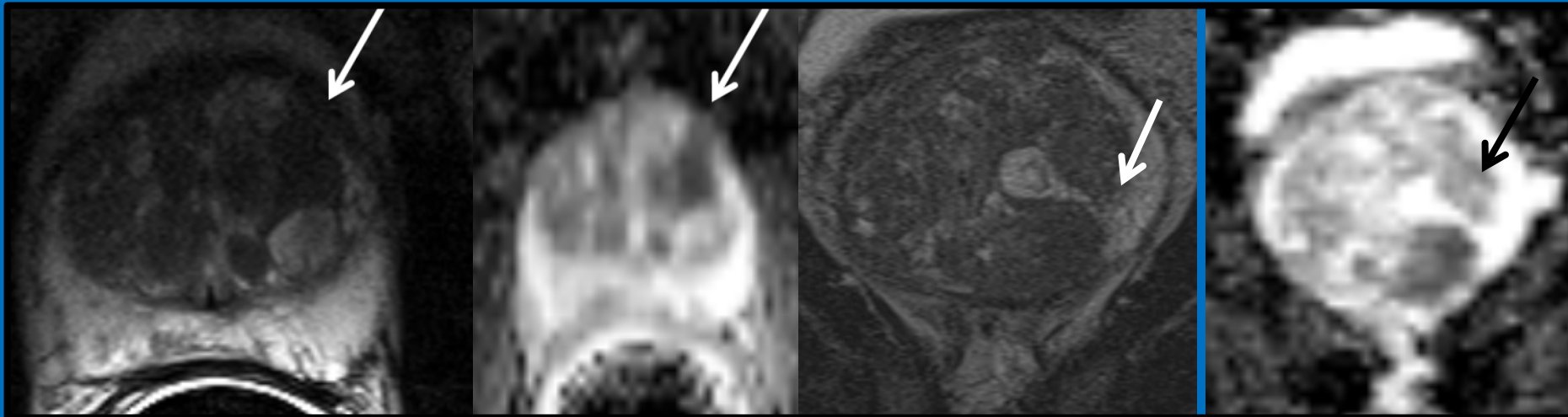
Ax T2

ADC

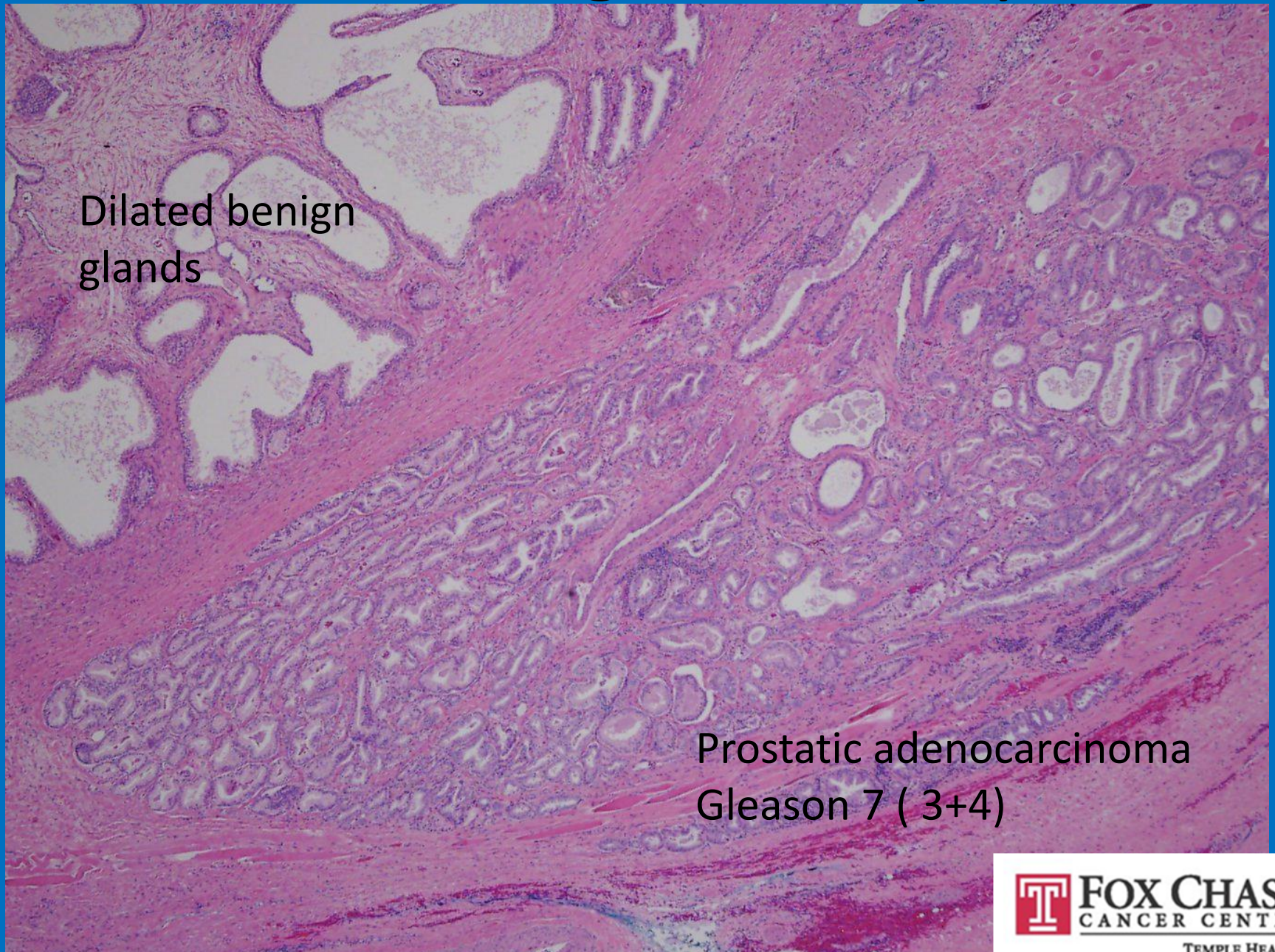
2017

Coronal T2

ADC

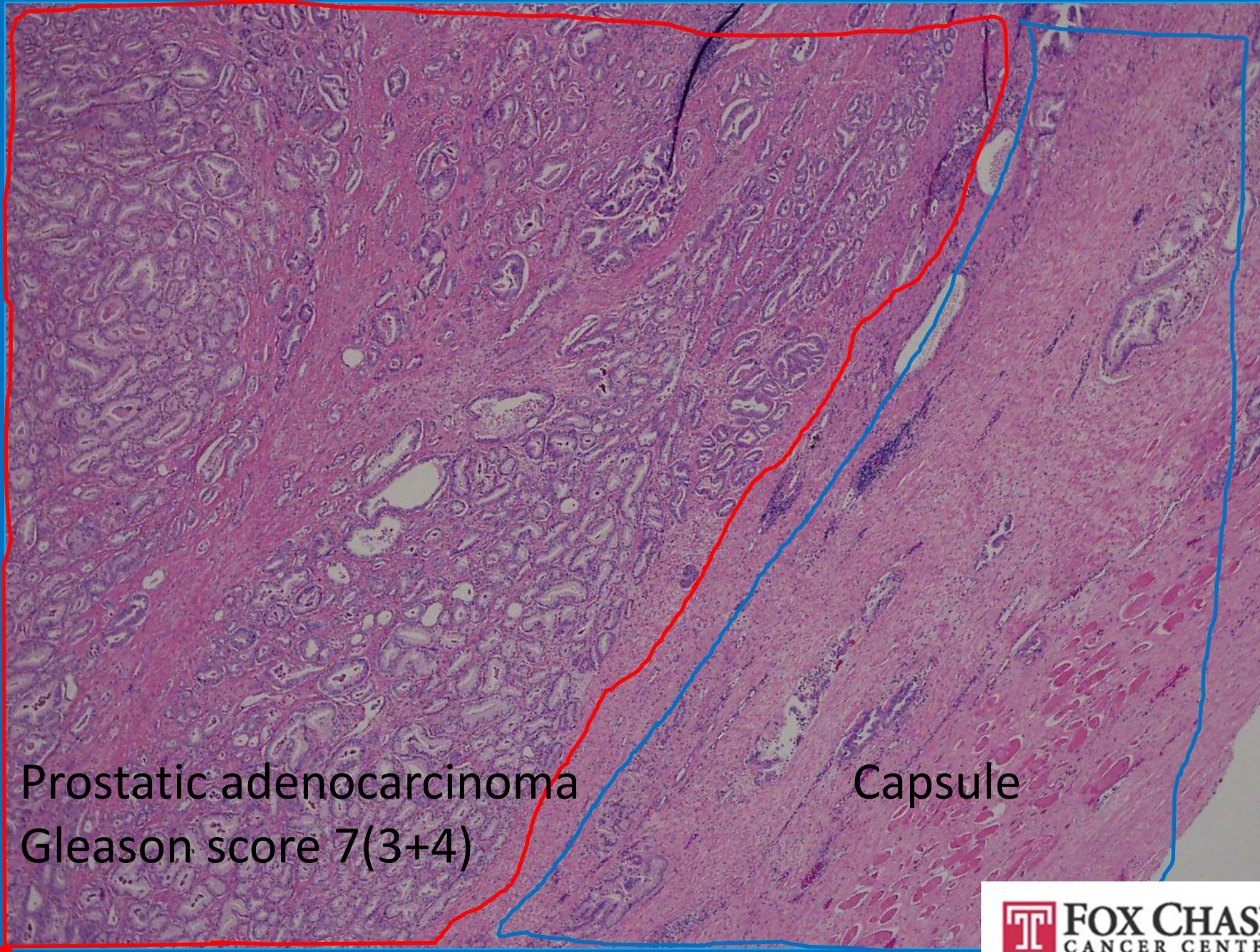


Left TZ zone targeted biopsy 2017



Dilated benign
glands

Prostatic adenocarcinoma
Gleason 7 (3+4)



Prostatic adenocarcinoma
Gleason score 7(3+4)

Capsule