

# Prostate Cancer in Transgender Women

Mukesh Harisinghani, MD, FACR  
Professor of Radiology  
Massachusetts General Hospital



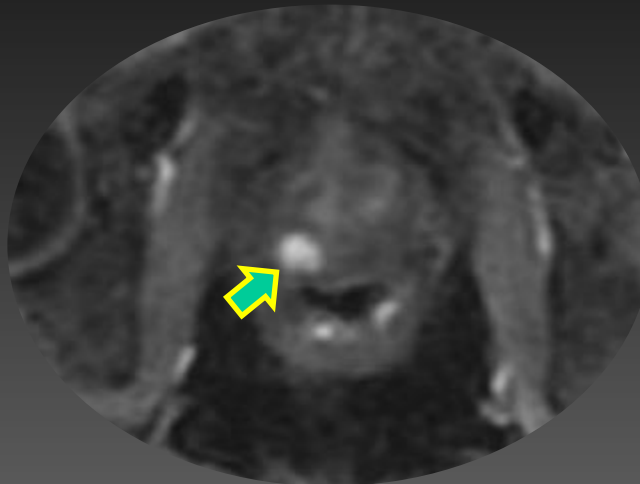
# History

- 60 year old transgender female presented to multidisciplinary clinic owing to abnormal digital rectal exam by her PCP
- Patient also had urinary obstructive symptoms
- PSA testing revealed a value of 3.3 ng/ml

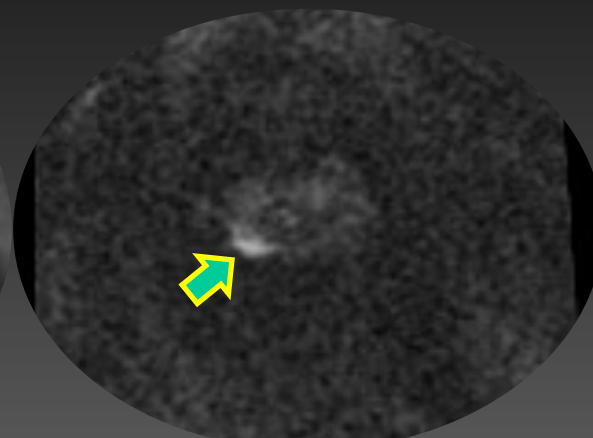
# History

- Patient reported nearly 20 year history of intranasal GnRH agonist to facilitate her MTF transition
- She had not undergone gender affirmation surgery
- mp MRI was performed

DCE

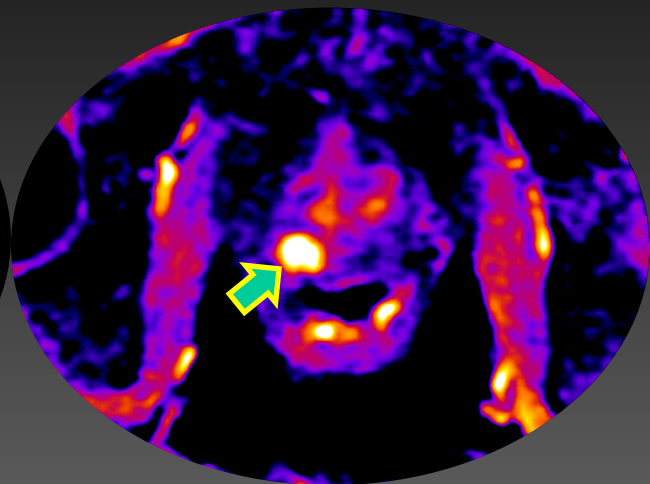


DWI

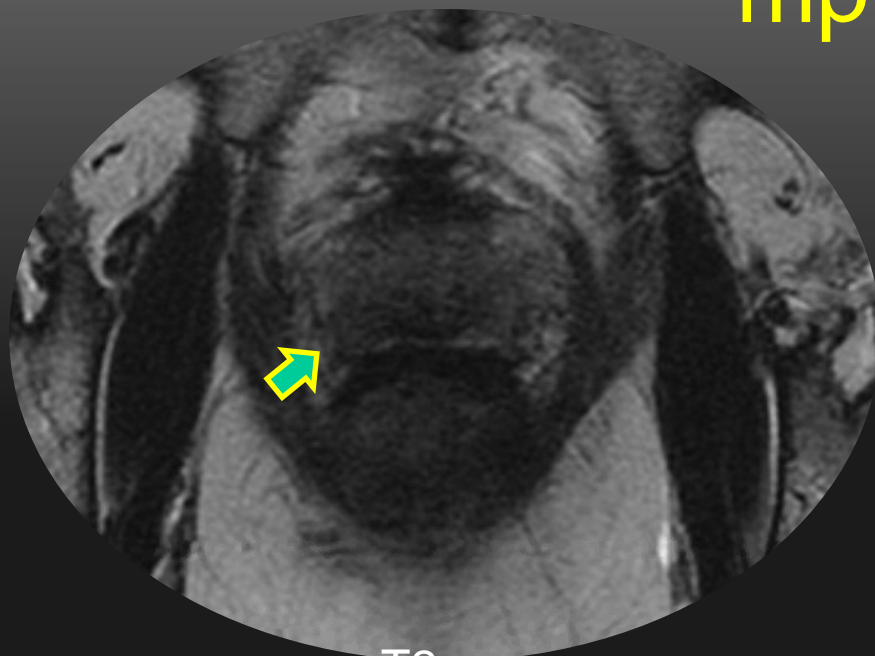


b=2000

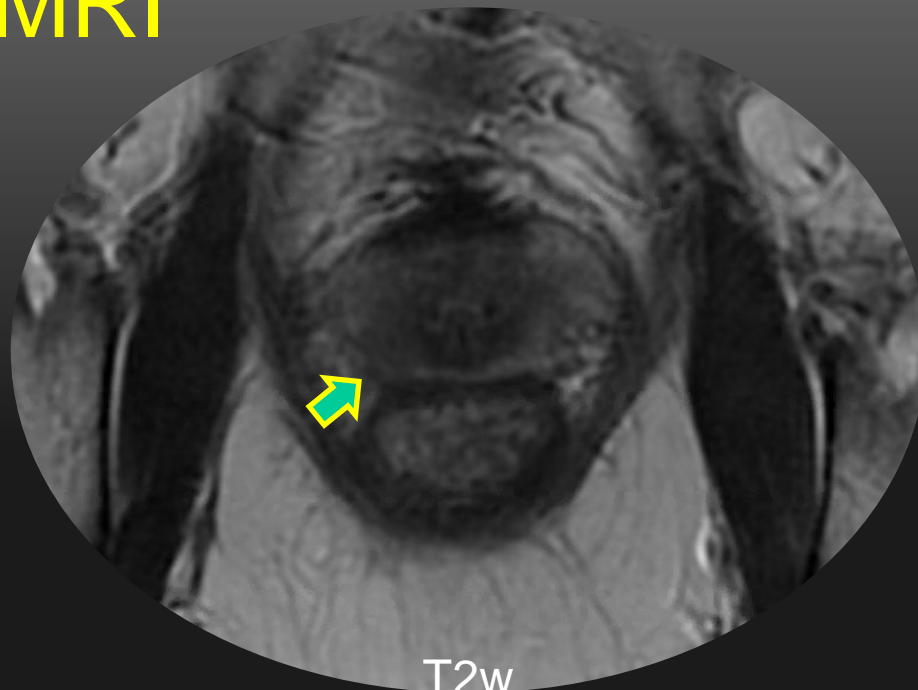
DCE



mp MRI



T2w



T2w

# Findings

- On mpMRI the gland showed poor zonal differentiation
- There was a 1 cm T2 dark lesion showing marked restricted diffusion in the right posterior peripheral zone with a capsular bulge; on the post gadolinium enhanced images; lesion showed early enhancement and washout

# Pathological Diagnosis

- On targeted fusion biopsy, Gleason 4+5 (grade group 5) adenocarcinoma of the prostate in 2 cores
- A unilateral nerve sparing radical prostatectomy was subsequently performed showing pT2cN0M0 R0 Gleason Score 4+5 (Grade Group 5) adenocarcinoma of prostate

# Take Home Point

- Screening of cisgender males for prostate cancer is to be done as per current recommendations
- It is important to remember that PSA levels in MTF transgender patients, on gender affirmation hormonal therapy, will be suppressed and lower than what you would expect in non transgender men; hence a **PSA level of 1ng/ml should be used as an upper threshold of normal**