

SAR Prostate Cancer Disease-Focused Panel

Teaching Case of the Week

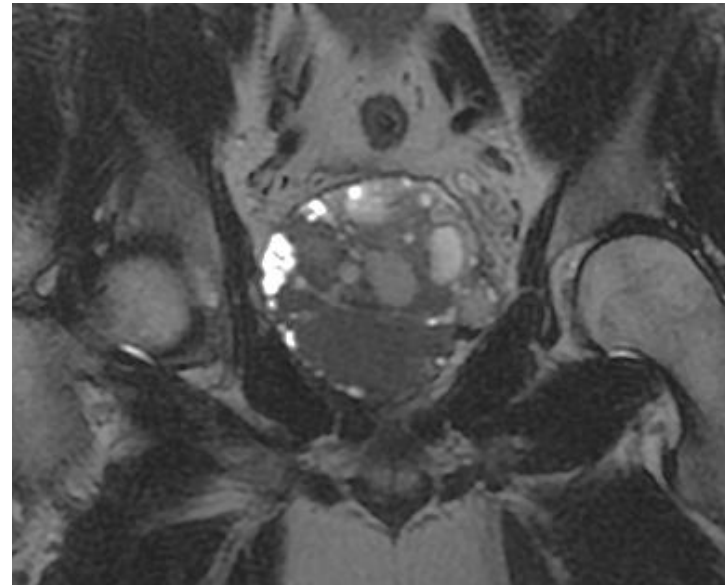
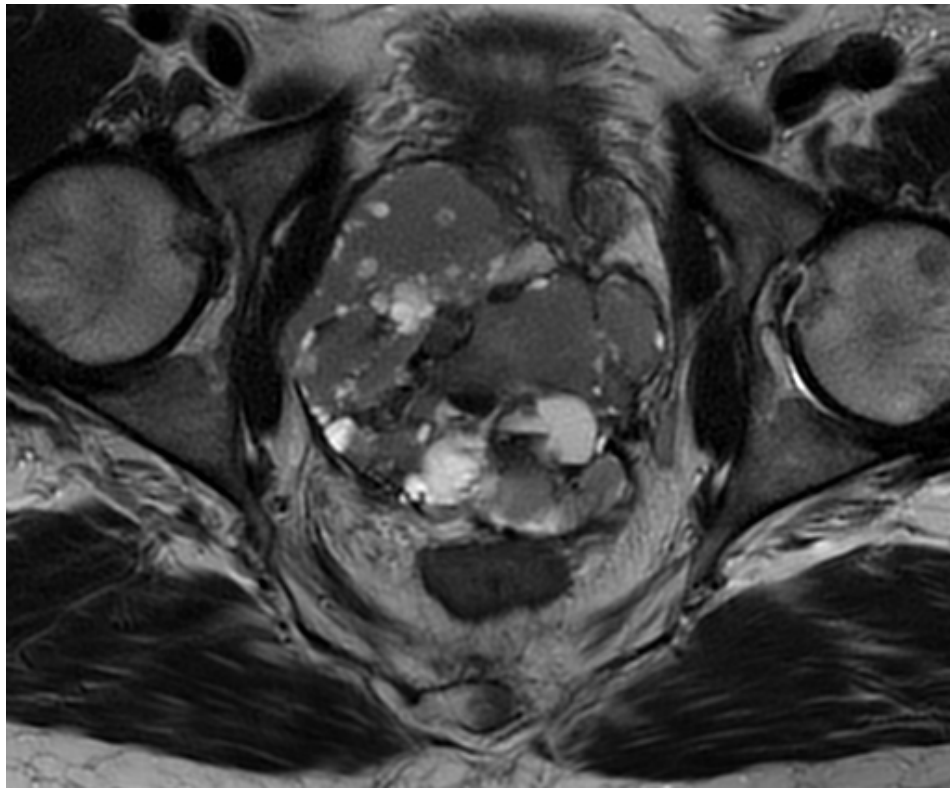
STUMP

Aytekin Oto, MD, MBA

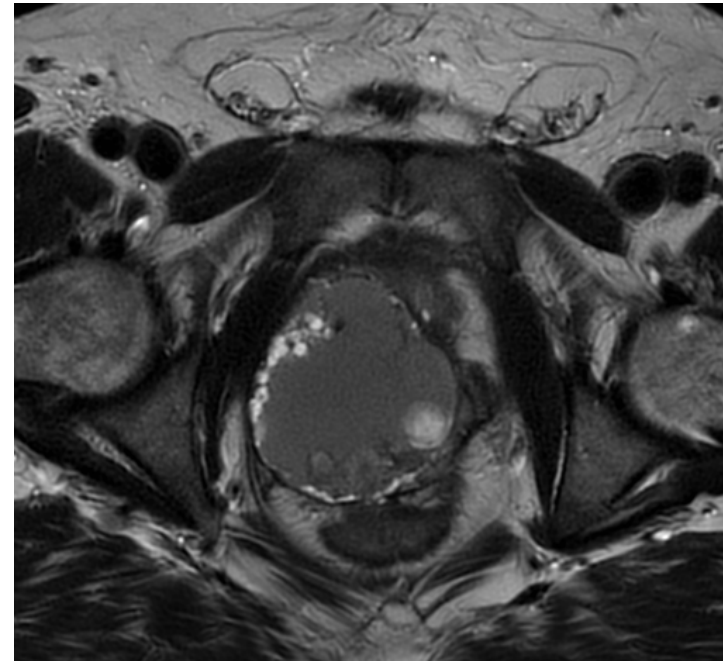
Department of Radiology, University of Chicago, Chicago, IL, USA

History

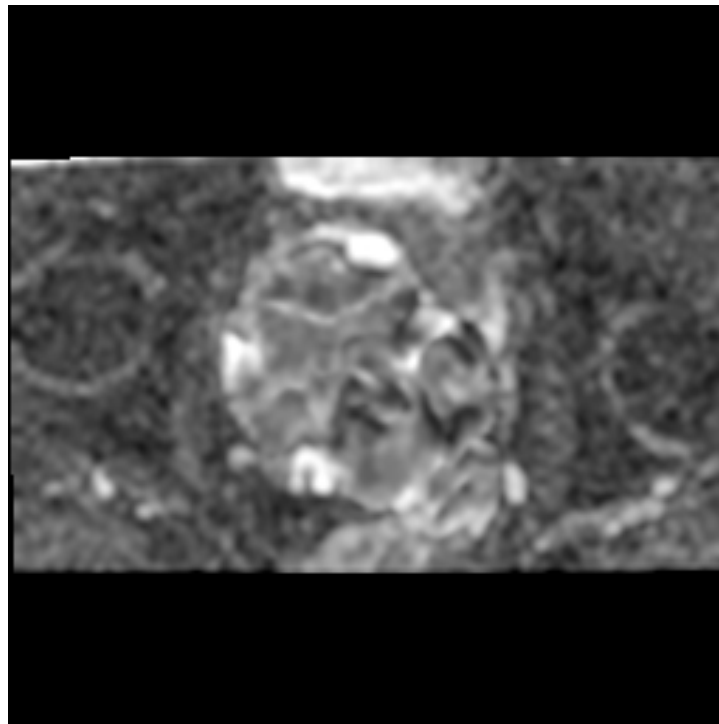
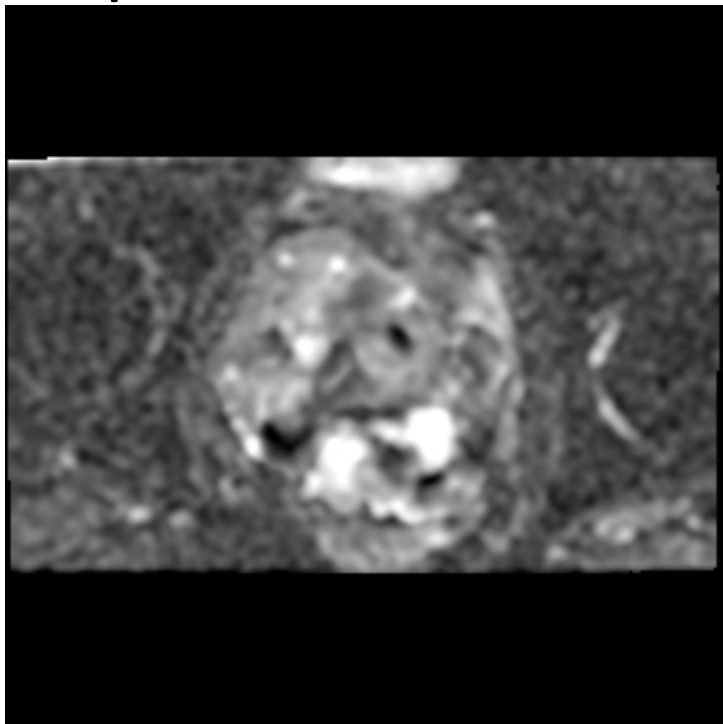
55 year old man with elevated BPH and positive DRE

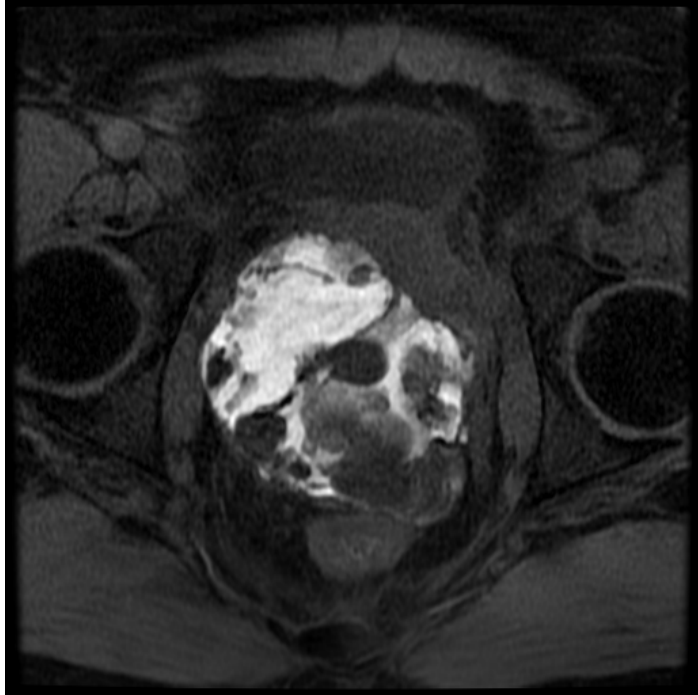


T2-weighted images

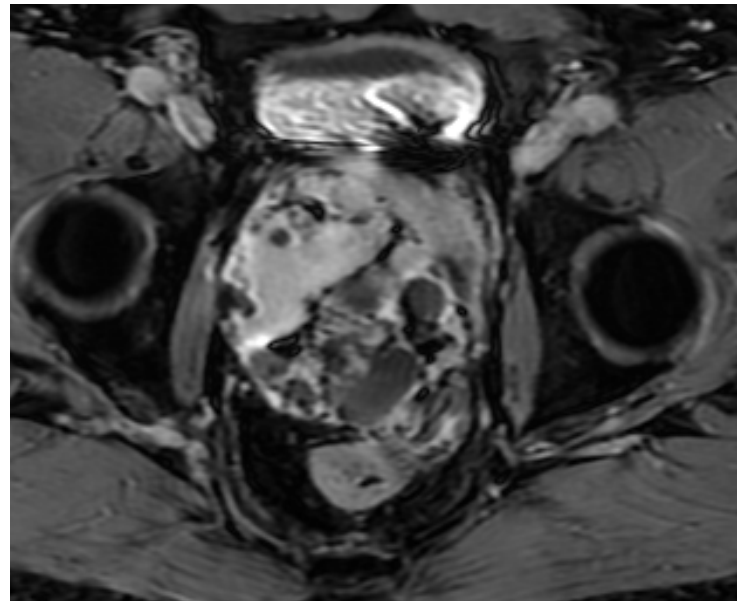
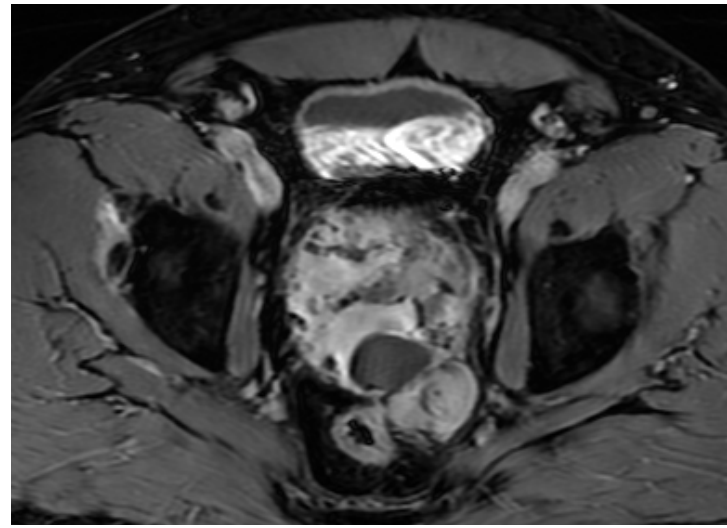


ADC Maps





Pre- and Post-contrast Axial Images



STUMP Tumors

A **prostatic** stromal **tumor** of uncertain malignant potential (**STUMP**) is a non-epithelial, mesenchymal spindle-cell **tumor** that can be classified as a specialized stromal **tumor** of the **prostate**. **STUMPs** have the capability to diffusely infiltrate the **prostate** gland and extend into adjacent tissues.

The diagnosis of prostate STUMP is usually made by core biopsy; however, it can be derived from a transurethral resection of prostate or even from specimens of radical prostatectomy owing to an adenocarcinoma.

MRI Findings: Cystic areas interspaced by septae and solid components with enhancement on solid areas and septae

Muglia et al BJR 2011