



# Tibial Rotational Alignment in Total Knee Arthroplasty

## Preliminary Report of the Tibial Rotation Study Group of European Knee Associates (EKA)

**Reha N. Tandogan<sup>(1)</sup>, Pier Indelli<sup>(2)</sup>, Mo Saffarini<sup>(3)</sup>, Alfredo-Schiavone Panni<sup>(4)</sup>, Ersin Ercin<sup>(5)</sup>**

- (1) Reha N. Tandogan, Ankara, Turkey, EKA Board Member
- (2) Pier Indelli, Palo Alto, California, USA
- (3) Mo Saffarini, Nyon, Switzerland
- (4) Alfredo-Schiavone Panni, Naples, Italy, EKA Board Member
- (5) Ersin Ercin, Istanbul, Turkey

Correct rotational orientation of the tibial component is important for the performance and longevity of total knee arthroplasty (TKA). Malrotation may lead to patellar maltracking, pain and stiffness. Malrotation may also increase poly wear and may adversely affect the survivorship of TKA.

### **Anatomical landmarks**

Several points and axes in the antero-posterior and medio-lateral planes have been described to aid in the rotational alignment of the tibial component. Reference points around the tibial tubercle (medial third, medial border); patellar tendon (medial third, medial sixth) have been used. The most commonly-used anatomical antero-posterior axis for tibial rotation is “Akagi line” (mid-PCL to medial border of the tibial tubercle). Medio-lateral axes, such as the most medial and lateral points on the tibial plateau (MLP) and tangent to the posterior tibial margin (PTM) have also been found useful. Rotational alignment using the anterior tibial border (ATB) is more reliable than the original ‘Akagi line’ or its variants. The ATB, MLP, and PTM seem to be best landmarks to use on the tibia, but more research is necessary.

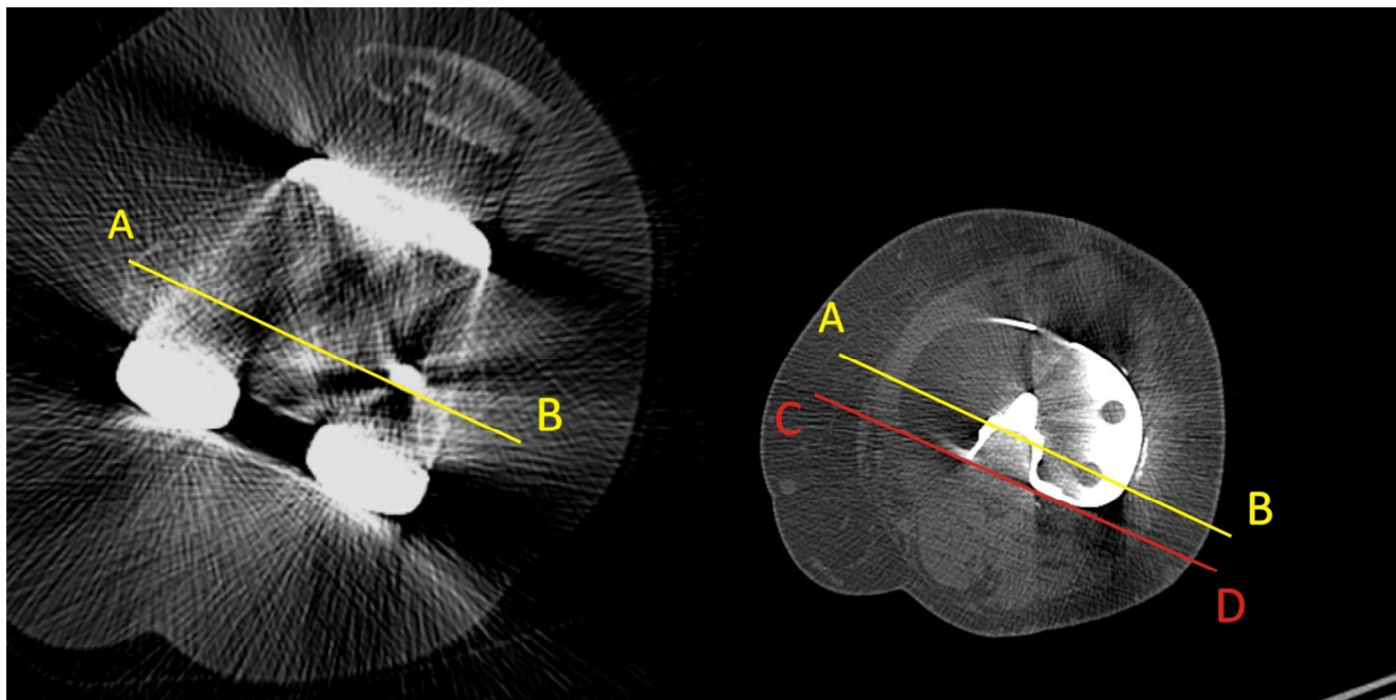
### **Intra-operative methods**

Intra-operative rotation of the tibial tray can be defined using fixed landmarks or dynamically adjusted to fit the femoral component. Landmarks referencing the tibial tubercle or the patellar tendon insertion have been described. However, the tibial tubercle is unreliable, since its location changes in valgus knees and with distal resection of the tibia. Best fit anterior cortex has been shown to be a reliable landmark for symmetrical baseplates. The posterolateral locked technique described by Rossi; and Akagi line and its variants are other fixed reference landmarks. Dynamic adjustment of rotation with the femoral component in flexion-extension can also be used. Dynamic methods have the advantage of providing perfect conformity with the femoral component and are important in reducing post wear for PS designs, however, they require a correct femoral orientation. No single intra-operative technique has been found to be superior to achieve optimal rotation. Fixed landmarks should be supplanted with dynamic self-alignment methods while checking for patellar tracking and post impingement.

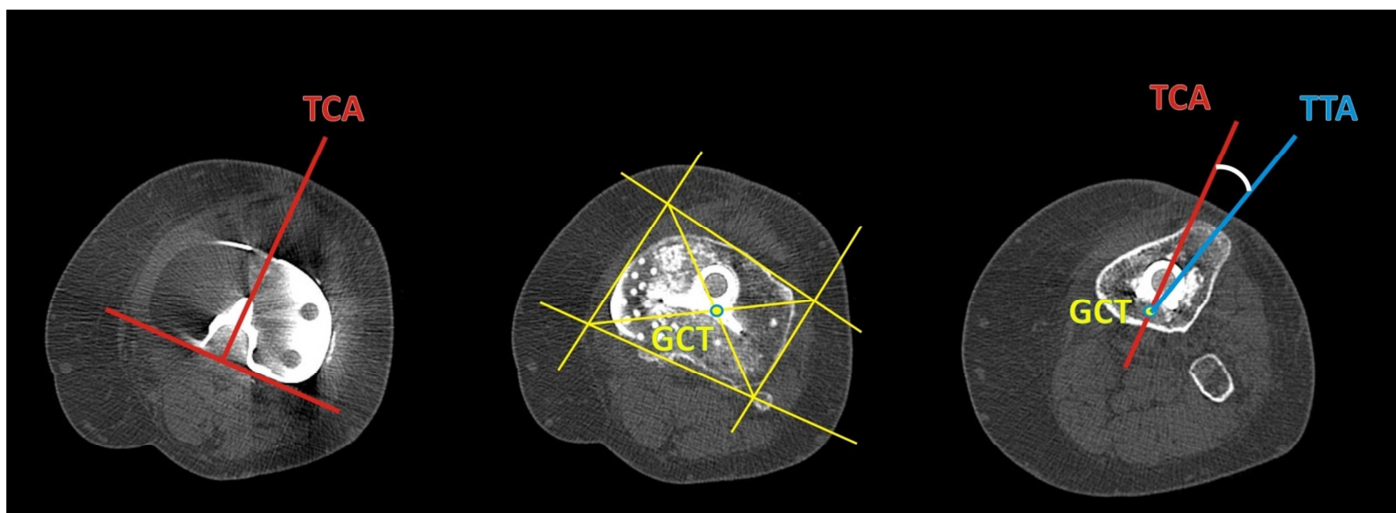
### **Post-operative measurement of tibial rotation**

Tibial component rotation is usually measured with computed tomography (CT). 3D CT has been shown to be more accurate than 2D CT. Methods measure the angle between the extrapolation of the surgical transepicondylar axis (sTEA) and a medio-lateral axis of the tibia (either the posterior tangent of the tibial baseplate or the medio-lateral widest points) are the most accurate for symmetrical fixed bearing baseplates (Figure 1). These also reflect the combined rotational alignment of the

femoral and tibial components. The Berger method measures rotation from the geometric centre of the tibia and the antero-posterior axis of the base plate referencing the tibial tubercle (Figure 2).



**Figure 1:** The surgical transepicondylar axis (AB) is transposed over the slice through the tibial baseplate. The posterior tangent to the tibial baseplate is marked (CD). The angle between AB and CD is the tibial rotation, 2° of external rotation in this case. Up to 3° of rotation in both planes is acceptable.



**Figure 2:** Berger technique to measure tibial rotation. Three levels of CT slices are used. The first slice passes through the tibial baseplate and the tibial component axis (TCA) is drawn as a perpendicular to the posterior tangent of the baseplate. The second slice passes just below the baseplate, where the geometric centre of the tibia (GCT) is drawn as shown in the middle figure. GCT and the TCA transposed to the third axial slice at the level of the tibial tubercle. The tibial tubercle axis (TTA) is the line drawn from GCT to the most prominent part of the tubercle. The angle between TCA and TTA is the rotational position of the tibial component. Normal rotation using this method is 18° ( $\pm 2.5^\circ$ ) internal rotation.

### **Malrotation and clinical outcomes**

The association between malrotation and anterior knee pain, stiffness, patellar instability and inferior clinical outcome has been demonstrated in several studies. Although experimental studies have shown that both external and internal malrotation is detrimental, external malrotation is better tolerated. Reported thresholds causing symptoms and need for revision vary considerably from 2° to 10° internal rotation. Based on the available literature, it is not possible to set a safe range for tibial rotation, since some studies report excellent clinical outcomes in patients well outside the accepted normal range. Mobile bearing implants have been reported to be more forgiving for minor rotational errors.

Several insights can be gleaned from the available studies. Internal rotation of the tibial component more than 3° causes higher patellar contact stresses, patellar tilt and maltracking. Internal rotation error more than 5° is associated with anterior knee pain. Internal rotation more than 10° may lead to stiffness. Higher than 15° malrotation results in increased polyethylene wear, increased tension on surrounding ligaments and finally failure of the arthroplasty. External rotation seems to be better tolerated up to 5° to 10°.

### **Improvement of rotation with new technology**

A limited number of studies in the literature show that patient specific instrumentation PSI performs equally well or slightly better compared to classical instrumentation (CLI) to achieve optimal tibial rotation in TKA. The variability of PSI data acquisition and manufacturing methods, instrument and implant systems, and post-operative measurement protocols of tibial rotation makes comparison between systems or pooling of data very difficult.

Twelve studies have reported specifically on tibial rotation and/or femoro-tibial rotational mismatch using computer aided surgery (CAS). Nine of these studies could not demonstrate an increased accuracy for tibial rotation using CAS compared to CLI. Three studies have shown a significantly increased accuracy and a reduction in outliers favouring CAS. The variability of implants, CAS software and CT protocol for measuring rotation makes it difficult to compare studies; however, it can be concluded that CAS has a limited benefit for improving the accuracy of tibial rotational alignment.

### **Conclusions**

1. Tibial malrotation causes inferior functional outcomes and increased rate of complications.
2. Ideal method of intra- and post-operative rotational measurement is still debated.
3. Rotation should be measured referencing some form of femoral axis instead of landmarks around the tibial tubercle.
4. New technology (PSI/computer navigation) does not significantly improve tibial rotational alignment.

### **Select References**

Akagi M, Oh M, Nonaka T, Tsujimoto H, Asano T, Hamanishi C (2004) An anteroposterior axis of the tibia for total knee arthroplasty. *Clin Orthop Relat Res* 213-219

Bell SW, Young P, Drury C, Smith J, Anthony I, Jones B, et al. (2014) Component rotational alignment in unexplained painful primary total knee arthroplasty. *Knee* 21:272-277

Berger RA, Crossett LS, Jacobs JJ, Rubash HE (1998) Malrotation causing patellofemoral complications after total knee arthroplasty. *Clin Orthop Relat Res* 144-153

De Valk EJ, Noorduyn JC, Mutsaerts EL (2016) How to assess femoral and tibial component rotation after total knee arthroplasty with computed tomography: a systematic review. *Knee Surg Sports Traumatol Arthrosc* 24:3517-3528

Huijbregts HJ, Khan RJ, Sorensen E, Fick DP, Haebich S (2016) Patient-specific instrumentation does not improve radiographic alignment or clinical outcomes after total knee arthroplasty: A meta-analysis. *Acta orthopaedica* 87:386-394

Indelli PF, Graceffa A, Marcucci M, Baldini A (2016) Rotational alignment of the tibial component in total knee arthroplasty. *Ann Transl Med* 4:3

Valkering KP, Breugem SJ, van den Bekerom MP, Tuinebreijer WE, van Geenen RC (2015) Effect of rotational alignment on outcome of total knee arthroplasty. *Acta Orthop* 86:432-439