



Wound
Ostomy and
Continence
Nurses
Society®

WOCN Society and ASCRS Position Statement

on Preoperative Stoma Site Marking for Patients Undergoing Colostomy or Ileostomy Surgery



WOCN Society and ASCRS Position Statement on Preoperative Stoma Site Marking for Patients Undergoing Colostomy or Ileostomy Surgery

Originated By:

Wound, Ostomy and Continence Nurses Society's (WOCN®) Stoma Site Marking Task Force in collaboration with the American Society of Colon and Rectal Surgeons (ASCRS) in 2007.¹

Updated/Revised By:

WOCN Society's Stoma Site Marking Task Force in collaboration with the ASCRS and the American Urological Association (AUA).

Contributing Authors:

Task Force Chair

- **Ginger Salvadalena, PhD, RN, CWOCN**, Principal Scientist, Global Clinical Affairs, Hollister Incorporated, Libertyville, Illinois

Task Force Members

- **Samantha Hendren, MD, MPH**, Associate Professor of Surgery, University of Michigan, Ann Arbor, Michigan
- **Linda McKenna, MSN, RN, CWOCN**, Ostomy & Wound Specialist, Memorial Medical Center, Springfield, Illinois
- **Roberta Muldoon, MD, FACS**, Assistant Professor of Surgery, Vanderbilt University Medical Center, Nashville, Tennessee
- **Debra Netsch, DNP, RN, CNP, FNP-BC, CWOCN**, Mankato Clinic, Ltd, Mankato, Minnesota
- **Ian Paquette, MD**, Assistant Professor of Surgery, University of Cincinnati College of Medicine, Cincinnati, Ohio
- **Joyce Pittman, PhD, ANP-BC, FNP-BC, CWOCN**, Team Lead Wound/Ostomy Adjunct Assistant Professor, Indiana University School of Nursing, Indiana University Health-Methodist, Indianapolis, Indiana
- **Janet Ramundo, MSN, RN, CWOCN**, WOC Nurse, Houston Methodist Hospital, Houston, Texas
- **Gary Steinberg, MD**, The Beth and Bruce White Family Professor and Director of Urologic Oncology; Vice Chairman Section of Urology, The University of Chicago Medicine, Chicago, Illinois

Date Completed:

June 2014

Date Approved by the WOCN Board of Directors:

November 12, 2014

The WOCN Society suggests the following format for bibliographic citations:

Wound, Ostomy and Continence Nurses Society. (2014). *WOCN Society and ASCRS Position Statement on Preoperative Stoma Site Marking for Patients Undergoing Colostomy or Ileostomy Surgery*. Mt. Laurel: NJ. Author.

Statement of Position:

Ostomy education and stoma site selection should be performed preoperatively for all patients when an ostomy is a possibility. Multiple studies indicate that patients who have their stoma site marked preoperatively by a trained clinician have fewer ostomy-related complications.²⁻⁷

An appropriate stoma site may decrease ostomy-related complications such as leakage of the pouching system and peristomal dermatitis. It may also influence the predictability of a pouch's wear time, ability of the patient to adapt to the ostomy and become independent, and may even help control healthcare costs. Preoperatively marking the stoma site allows assessment of the patient's abdomen in multiple positions, which promotes selection of the optimal stoma site. In addition, this preoperative session promotes a patient-centered approach respecting the individuality, values, and information needs of the patient and family. The session may allow time to provide information regarding ostomy management, including pouching options, and provide psychosocial support. While preoperative stoma site marking is strongly supported, it is acknowledged that intra-operative circumstances may not allow for the optimal stoma site to be used in all situations. The final stoma site is chosen by the surgeon after the abdominal cavity is entered and the condition of the bowel is determined.

Colon and rectal surgeons and certified ostomy nurses are the optimal clinicians to select and mark stoma sites, as this skill is a part of their education, practice and training. However, these providers are not always available, particularly in emergency situations. All physicians who are called on to choose ostomy sites should familiarize themselves with the principles of proper stoma site selection, including placement of the stoma within the rectus abdominis muscle, use of multiple patient positions to identify appropriate stoma sites, avoidance of folds and scars, and consideration of the clothing/beltline.

Purpose (Rationale for Position):

The WOCN Society in collaboration with the ASCRS and the AUA developed the following educational guide to assist clinicians (especially those who are not surgeons or WOC nurses) in selecting an effective stoma site. Marking the optimal location for a stoma preoperatively enhances the likelihood of a patient's independence in stoma care, predictable pouching system wear times, and resumption of normal activities.

Recommendations:

A. Key Points to Consider

1. The stoma site should be located within the rectus abdominis muscle.
2. Positioning issues: Contractures, posture, mobility (e.g., wheelchair confinement, use of a walker, etc.).
3. Physical considerations: Large/protruding/pendulous abdomen, abdominal folds, wrinkles, scars/suture lines, other stomas, rectus abdominis muscle, waist line, iliac crest, braces, pendulous breasts, vision, dexterity, and the presence of a hernia.

4. Patient considerations: Diagnosis, age, occupation, prior experience with a stoma, and preferences about the stoma's location.
5. Surgical considerations: Surgeon's preferences, type of surgery/stoma planned, segment of intestine used, and whether an incontinent versus a continent, catheterizable diversion is planned.
6. Multiple stoma sites: If a urinary stoma is also present or planned, consider marking the fecal and urinary stoma sites on different horizontal planes/lines in the event that an ostomy belt is required.

B. Stoma Site Marking Procedure

1. Gather items needed for the procedure: Marking pen, surgical marker, transparent film dressing, and flat skin barrier (i.e., according to the surgeon's preference and/or the facility's policy).
2. Explain the stoma site marking procedure to the patient, and encourage the patient's participation and input.
3. Carefully examine the patient's abdominal surface. If possible, begin with the patient fully clothed in a sitting position with both feet on the floor.
 - Observe the presence of belts, braces, and any other ostomy pouches.
 - Individuals with spinal cord injuries are optimally marked in their usual position, as this will facilitate fitting and care of the pouching system.⁸
 - If the patient uses a wheel chair, it is best to position them in their own chair and allow time for their body to relax into their usual habitus before marking.⁹
4. Have the patient completely remove any clothing that is placed over the abdomen, rather than just moving it out of the way. Waistbands and elastic can create or obscure skin folds that may or may not be present when the clothing is completely removed.
5. Examine the patient's exposed abdomen in various positions (e.g., standing, lying, sitting, and bending forward) to observe for creases, valleys, scars, folds, skin turgor, and contour.
6. Consider an imaginary line where the surgical incision will be located. If possible, choose a point at least 2 inches from the surgical incision where 2 to 3 inches of a flat adhesive skin barrier can be placed.
7. With the patient lying on his or her back, identify the rectus abdominis muscle. This can be done by having the patient do a modified sit up (i.e., raise the head up and off the bed) or by having the patient cough. Palpate the edge of the rectus abdominis muscle. Expert opinion suggests that placement of the stoma within the rectus abdominis muscle may help prevent a peristomal hernia and/or a prolapse.¹
8. Mark a spot on the skin of the abdomen that is located within the rectus abdominis muscle, in the appropriate quadrant for the planned surgery, and within the patient's visual field.
 - Care should be taken to avoid scars or creases; the priority is a flat pouching surface.
 - Individuals who use a wheelchair or have a large, rounded abdominal contour may benefit from having the stoma site marked in an upper quadrant.⁹
 - Choose an area that is visible to the patient, and if possible below the belt line to conceal the pouch.

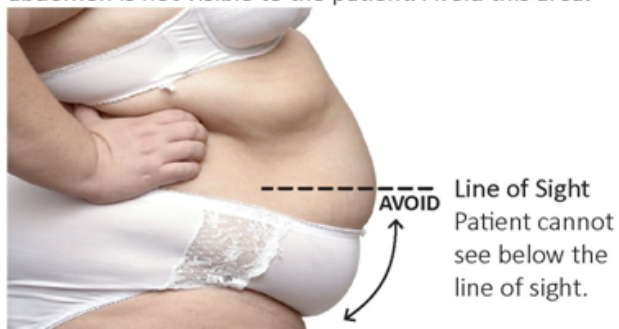9. If the abdomen is protuberant, choose the apex of the abdominal contour, or if the patient is extremely obese, consider marking the site in an upper abdominal quadrant.¹⁰ In many obese patients the adipose layer is not as thick in the upper abdominal quadrants as compared to the lower quadrants, which may allow better visualization of the stoma.^{8,10}
10. The mark should initially be made with a sticker or ink pen that can be removed if this is not the optimal spot.
 - It may be desirable to mark sites on the right and left sides of the abdomen to prepare for a change in the surgical outcome, and number the first choice as #1.
 - Have the patient assume sitting, bending, and lying positions to assess and confirm the best choice.
 - It is important to have the patient confirm they can see the site. However, the critical consideration should be a flat pouching surface.
11. After the optimal site is chosen, clean the desired site with alcohol and allow it to dry. Then proceed with marking the selected site with a surgical marker or pen. If desired, cover the site with a transparent film dressing to preserve the final mark. Ensure that any other stray marks have been removed.

C. Examples of Stoma Site Marking

1. See Figure 1: Example of marking a stoma site for a female with a protuberant abdomen, creases, and folds.
2. See Figure 2: Example of marking a stoma site for a male with a protuberant abdomen.

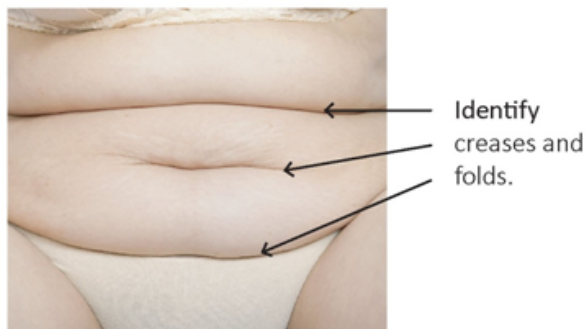
Step 1

Look at the profile of the patient. Notice where the abdomen curves back under toward the body. The underside of the abdomen is not visible to the patient. Avoid this area.



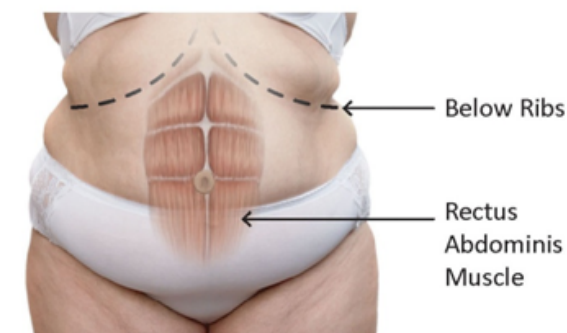
Step 2

While patient is seated, look for skin folds and creases. Note and avoid skin folds and creases.



Step 3

Identify and target the rectus abdominis muscle below the ribs.



Step 4

Mark optimal stoma sites on the rectus abdominis, that are in patient's line of sight, while avoiding creases and skin folds.

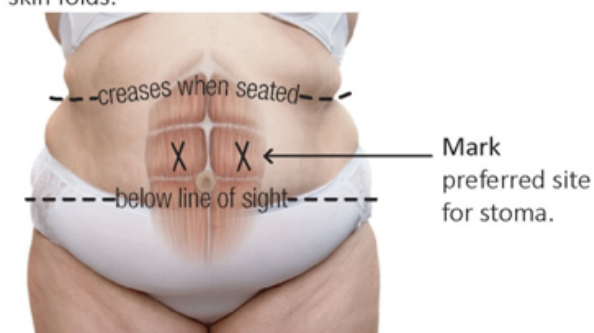
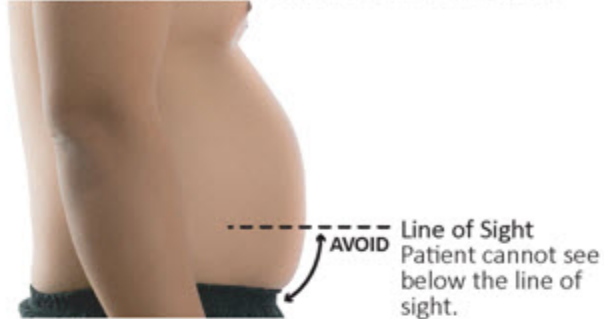

Figure 1. Illustration of stoma site marking for a female with a protuberant abdomen.

Images used with permission: Step 1, female photograph © mik122/veer; Step 2, female photograph © SeDmi/veer; Step 3 and 4, female photograph ©Kokhanchikov/shutterstock, and muscle overlay ©Randall Reed Photography/veer.

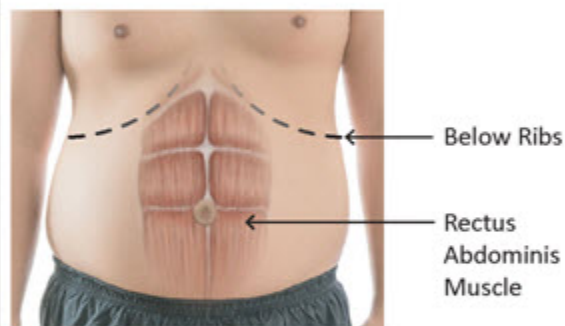
Step 1

Look at the profile of the patient. Notice where the abdomen curves back under toward the body. The underside of the abdomen is not visible to the patient. Avoid this area.



Step 2

Identify and target the rectus abdominis muscle below the ribs.



Step 3

Mark optimal stoma sites on the rectus abdominis muscle, that are in patient's line of sight, while avoiding creases and skin folds.

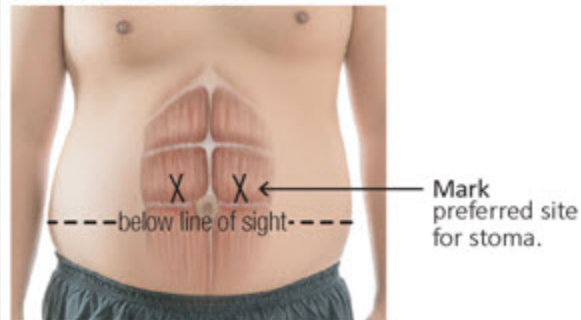


Figure 2. Illustration of stoma site marking for a male with a protuberant abdomen.

Images used with permission: Step 1, 2 and 3, male photograph ©sirastock/shutterstock; Step 2 and 3, muscle overlay ©Randall Reed Photography/veer.

Summary:

Stoma site selection should be a priority during the preoperative visit. Marking the site for a stoma preoperatively provides an opportunity to select the optimal site, which can help reduce postoperative problems such as leakage, peristomal dermatitis, and difficulty with self-care of the ostomy. Whenever possible, ostomy education and stoma site selection should be performed preoperatively when an ostomy is a possibility.

ACKNOWLEDGEMENT

The task force wishes to acknowledge Christina Augustyn, Industrial Designer, Innovation Management Office, Hollister Incorporated, Libertyville, Illinois, for her contribution in the selection and development of the images.

References

1. American Society of Colon and Rectal Surgeons Committee Members. Wound Ostomy Continence Nurse Society Committee Members. ASCRS and WOCN joint position statement on the value of preoperative stoma marking for patients undergoing fecal ostomy surgery. *J Wound Ostomy Continence Nurs.* 2007; 34(6): 627-628.
2. Millan M, Tegido M, Biondo S, Garcia-Granero E. Preoperative stoma siting and education by stomatherapists of colorectal cancer patients: A descriptive study in twelve Spanish colorectal surgical units. *Colorectal Dis.* 2010; 12(7 Online): e88-e92. doi:10.1111/j.1463-1318.2009.01942.x
3. Wound, Ostomy and Continence Nurses Society (WOCN). *Management of the Patient with a Fecal Ostomy: Best Practice Guideline for Clinicians.* Mount Laurel, NJ: WOCN Society; 2010.
4. Gulbiniene J, Markelis R, Tamelis A, Saladzinskas Z. The impact of preoperative stoma siting and stoma care education on patient's quality of life. *Medicina (Caunas).* 2004; 41(1): 1045-1053.
5. Park JJ, Del Pino A, Orsay CP, et al. Stoma complications: The Cook County Hospital experience. *Dis Colon Rectum.* 1999; 42(12): 1575-1580.
6. Parmar KL, Zammit M, Smith A, Kenyon D, Lees NP. A prospective audit of early stoma complications in colorectal cancer treatment throughout the Greater Manchester and Cheshire colorectal cancer network. *Colorectal Dis.* 2011; 13(8): 935-938. doi:10.1111/j.1463-1318.2010.02325.x
7. Pittman J, Rawl SM, Schmidt CM, et al. Demographic and clinical factors related to ostomy complications and quality of life in veterans with an ostomy. *J Wound Ostomy Continence Nurs.* 2008; 35(5): 493-503. doi:10.1097/01.WON.0000335961.68113.cb
8. Cataldo PA. Technical tips for stoma creation in the challenging patient. *Clin Colon Rectal Surg.* 2008; 21(1):17-22. doi:10.1055/s-2008-1055317
9. Hocevar B, Gray M. Intestinal diversion (colostomy or ileostomy) in patients with severe bowel dysfunction following spinal cord injury. *J Wound Ostomy Continence Nurs.* 2008; 35(2):159-166. doi:10.1097/01.WON.0000313638.29623.40
10. Colwell JC. The role of obesity in the patient undergoing colorectal surgery and fecal diversion: A review of the literature. *Ostomy Wound Manage.* 2014; 60(1): 24-28.