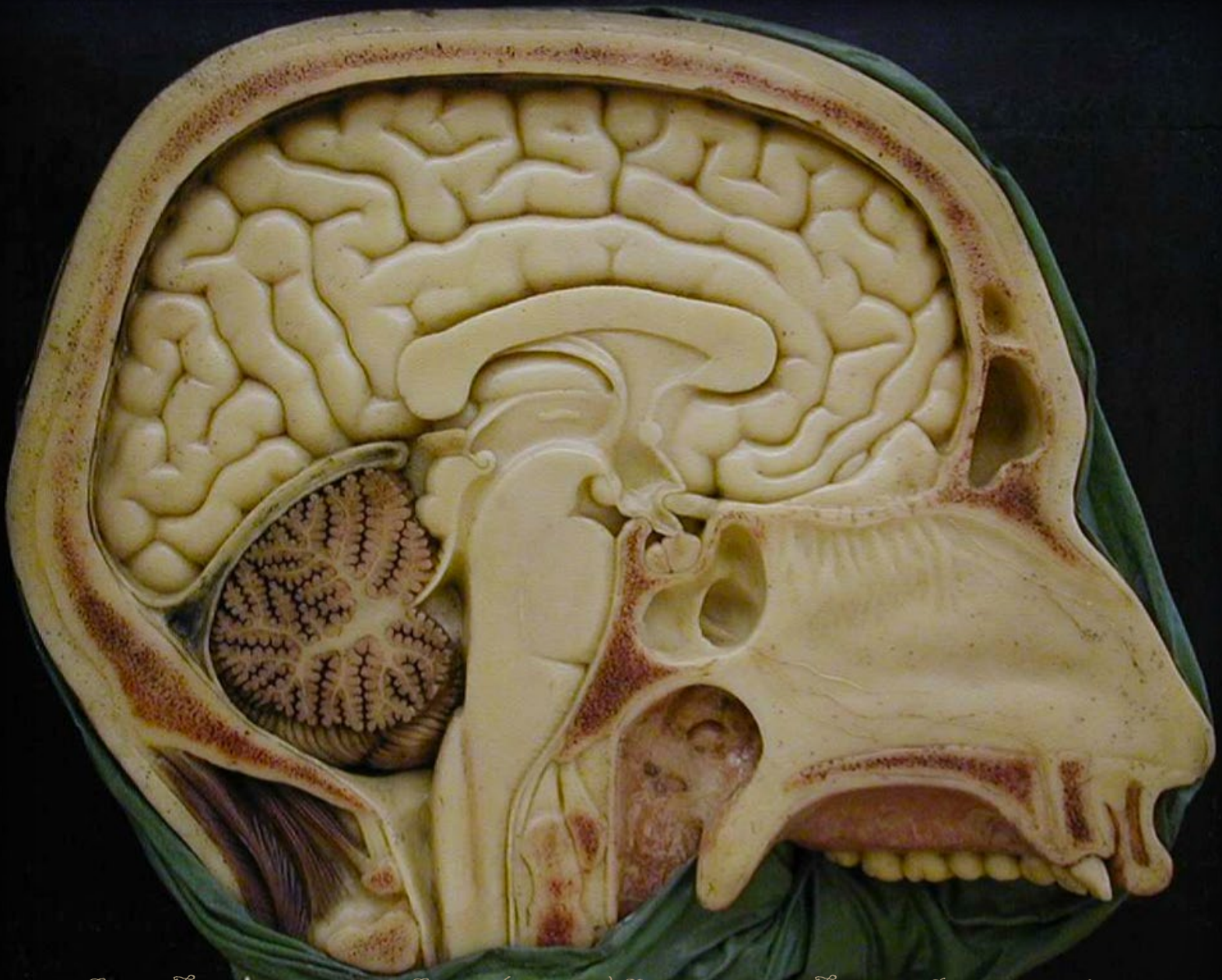


ESTABLISHED IN 1989 BY HUMAN ANATOMY & PHYSIOLOGY TEACHERS



EDUCATOR

VOLUME 19 ISSUE 2 · SPRING 2015



*Brain Morphology by Cesare Bettini (1814-1885), Luigi Cattaneo Museum of Anatomical Waxes,
Bologna Institute of Human Anatomy, University of Bologna.*

Promoting Excellence in the Teaching of Human Anatomy & Physiology

What is Lt?



After 27 years at the cutting edge of life science education, ADInstruments is bringing a new element to the table.



Scan for a sneak
preview of **Lt**.
Find out more at:

www.adinstruments.com/lt


ADINSTRUMENTS
making science easier

PRESIDENT

Tom Lehman
tlehman@hapsconnect.org

PAST-PRESIDENT

Valerie O'Loughlin
voloughl@hapsconnect.org

PRESIDENT-ELECT

Betsy Ott
bott@hapsconnect.org

SECRETARY

Carol Veil
cveil@hapsconnect.org

TREASURER

Karen McMahon
kcmcmahon@hapsconnect.org

REGIONAL DIRECTORS

Central: Murray Jensen
msjensen@hapsconnect.org
US: IA, IL, IN, MI, MN, OH, WI, MO
International: MB, ON, all other
non-Canadian members

Eastern: Leslie Day
lday@hapsconnect.org
US: CT, DC, DE, MA, MD, NH, NJ,
NY, PA, RI, VA, VT, WV
International: NB, NF, NS, PE, QC

Southern: Jason LaPres
jlapres@hapsconnect.org
US: AL, AR, FL, GA, KY, LA, MS,
NC, OK, SC, TN, TX; Territory: PR

Western: Jon Jackson
jjackson@hapsconnect.org
US: AK, AZ, CA, CO, HI, ID, IS, MY,
NE, ND, NM, NV, OR, SD, UT, WA,
WY
International: AB, BC, NU, NT, SK,
YT

HAPS EDUCATOR

CONTENTS

Articles:

Marvels of the Bologna Anatomical Wax Museum: their theoretical and clinical importance in the training of 21st century medical students

By Primary Author: Francesco M. Galassi, Co-authors: Alessandro Ruggeri, Kevin Petti, Hutan Ashrafian4

A Functional MRI (fMRI) Study Showing Neuroanatomical Correlates of Medical Image Interpretation and Effects of Art Instruction on Visuo-spatial skills in Medical Education

By Elliot Dickerson BS, Caryn Babaian, MS, Med, Kim Curby, PhD, Beverley Hershey, MD, Scott H. Faro, MD, Feroze B. Mohamed, PhD 10

The Anatomical Landmarks Most Important for Dental Implant Surgery

By Sarah Cooper 19

Anastomosis: Connecting History and Anatomy Education

By Vinson H. Sutlive26

Identification of Unknown Mammalian Quadruped Bones by Histological Techniques And Bone Morphology

By Olena Prikhodko, Sarah Cooper and Jennifer Wood, PhD30

The Nerve of it All: The Brachial Plexus in 3D. A Workshop Presentation at the Central Regional Conference in Cincinnati

By Christine Yu37

A Summary of the HAPS Regional Conference in Cincinnati

By Bonnie Richmond, PhD. 38

Edu-Snippets:

Snippets

By Roberta Meehan39

COVER ART - Brain Morphology by Cesare Bettini (1814-1885), Luigi Cattaneo Museum of Anatomical Waxes, Bologna Institute of Human Anatomy, University of Bologna.

In this ceroplastic model, Bettini beautifully demonstrates a midsagittally sectioned brain within the cranial vault. Beyond the anatomical accuracy and incredible detail, the technical capacities of Bettini are astonishing as this sculpture is approximately four times life-sized. Bettini was particularly skilled at creating large-scale anatomical preparations, many of which are on display in the Luigi Cattaneo Museum. The art and science of sculpting human organs from wax was founded at the University of Bologna in the 18th century as the supply of human cadavers for medical education was unable to meet demand, and the preservation of human specimens was problematic. Ceroplastic models provided a valuable three-dimensional alternative to human dissection, and are an important element in the history of anatomy education. Works by Bettini and other renowned anatomic artists are on public display at the University of Bologna where their artistic beauty and scientific importance can be appreciated. These treasures in the history of anatomy education are explored in this issue of the HAPS Educator in the article Marvels of the Bologna Anatomical Wax Museum. The authors suggest that these centuries old sculptures could be used in medical education today, connecting art and science in the modern curriculum.

Image and text provided by Dr. Francesco M. Galassi and Emeritus Prof. Alessandro Ruggeri, University of Bologna, and Prof. Kevin Petti, San Diego Miramar College. Special thanks to the Luigi Cattaneo Museum of Anatomical Waxes and the Sistema Museale d'Ateneo (SMA), University of Bologna.

Committee Members

Mary Lou Bareither
Brad Barger
Jackie Carnegie
Janet Casagrand

Kelly Cassidy
Elaine Chapman
David Evans
Kebret Kebede

Barbie Klein
Richelle Laippy
Roberta Meehan
Benjamin Miller

Hiranya Roychowdhury
Brian Salisbury
Mary Scott
Zoe Soon

Maria Squire
Kathy Starr
Nina Zanetti

The *HAPS-EDucator* is the official publication of the Human Anatomy and Physiology Society. As such, the *HAPS-EDucator* aims to foster the advancement of anatomy and physiology education by facilitating the collaboration of HAPS members through the publication of a biannual journal. Journal articles may include, but are not limited to, those that discuss innovative teaching techniques (eg., the use of technology in classrooms or active learning practices), original lesson plans or lab exercises, reviews of trending topics in anatomy and physiology, and summaries of newsworthy events (eg., seminars or conferences that not all society members can attend). Additionally, an extra issue of *HAPS-EDucator* will be published after the Annual Conference, highlighting the update speakers, workshops and poster presentations. All submitted articles will undergo a peer-review for **educational scholarship**. Articles not immediately accepted will be returned to authors with feedback and the opportunity to resubmit.

Submission Guidelines for Authors

The complete "Author Submission Packet" is available [HERE](#).

Terms of submission

The *HAPS-EDucator* publishes manuscripts consisting of original material that is not currently being considered for publication by another journal, website, or book and has not previously been published. Publication of the manuscript must be approved by all of the authors and have the approval of the appropriate institution(s). Manuscripts are to be submitted electronically to both editors: Sarah Cooper and Jennelle Malcos at haps-ed@hapsconnect.org. Materials for Snippets should be submitted directly to Roberta Meehan at Edu-Snippets@hapsconnect.org.

Formatting

Manuscripts are to be submitted in rich text format (rtf.) or .docx, in Arial (10) font with 1" margins on all sides. Accompanying the text, authors should submit an Author Submission Form consisting of a title page that lists the full name, associated institution and address, and email address of each author. A short Abstract of 150 to 200 words that explains the primary thesis of the submission should be included. Photos and illustrations should not be included in the body of the manuscript but they should be submitted, clearly labeled, with the manuscript. They should be submitted in JPEG form or in some other appropriate and usable form.

References

It is the responsibility of the author to make sure that the information on each reference is complete, accurate and properly formatted. References should be included in the body of the manuscript where appropriate using the following format: Author's last name and date of publication, (Martini 2011). A list of 'Literature Cited' should appear at the end of the paper alphabetically by author's last name. Example references are available in the complete "[Author Submission Packet](#)".

Submissions are accepted at all times and should be sent to haps-ed@hapsconnect.org

Deadlines for specific issues are:

- March 15 for the Spring Issue
- July 15 for the Conference Issue
- November 15 for the Winter Issue

You do not need to be a member of HAPS to publish in the *Educator*. For more information see the complete submission guidelines using the link above.

Human and animal research subjects

Research that includes dissection and manipulation of animal tissues and organs must adhere to the Human Anatomy and Physiology Society (HAPS) [Position Statement on Animal Use](#) (Adopted July 28, 1995,

modified January 2001, Approved April 29, 2012), which states that the use of biological specimens must be in strict compliance with federal legislation and the guidelines of the National Institutes of Health and the United States Department of Agriculture. The use of humans or animals in research must fulfill clearly defined educational objectives.

Experimental animals must be handled in accordance with the author's institutional guidelines and informed consent must be obtained for studies on humans. It is the responsibility of the author(s) to secure IRB approval for research on humans.

How your submission will be handled

The editors will assign the manuscript to a minimum of 2 and a maximum of 4 members of the *HAPS-EDucator* editorial board for **Educational Scholarship** review. The reviewers will evaluate the manuscript for scientific accuracy, appropriateness to the audience, readability and grammar. The reviewers will submit their reports along with a recommendation that the manuscript be (a) published unaltered, (b) published with minor changes, (c) published with major changes or (d) not published at all. The editors will then decide what action will be taken with the manuscript and the author will be notified to prepare and submit a final copy of the manuscript with the changes suggested by the reviewers and agreed upon by the editors. Once the editors are satisfied with the final manuscript, the manuscript can be accepted for publication.

If the editors recommend rejection of the manuscript due to inappropriateness of its subject, lack of quality in its presentation or incorrectness of grammar or style, it will be rejected. If two reviewers recommend rejection of the manuscript made on the basis of inappropriateness of its subject, lack of quality in its presentation or incorrectness of grammar or style, it will be rejected.

The review process is single blinded which means that the reviewers know the identity of the authors of the manuscript but the authors do not have access to information regarding the identity of the reviewers.

Plagiarism

Authors must obtain permission to reproduce any copyright material and the source of this material must be acknowledged in their manuscript.

Disclaimer

Responsibility for (1) the accuracy of facts, (2) the expression of opinion and (3) the authenticity of any supporting material presented by the author rests solely with the author. The *HAPS-EDucator*, its publishers, editors, reviewers and staff, take no responsibility for these things.

CONTACT THE *HAPS-EDucator* Editor: haps-ed@hapsconnect.org
HAPS, PO Box 2945, LaGrange, GA 30241

The HAPS Educator is published electronically by The Human Anatomy and Physiology Society (HAPS). The written and visual contents of this magazine are protected by copyright. Temporary permission is granted for members of the Human Anatomy and Physiology Society to read it on-line, to print out single copies of it, and to use it unchanged for any non-commercial research and educational purpose, including making copies for classroom use provided the materials are not modified and appropriate acknowledgment is made of the source. All other uses of this material are conditional and require the consent of the editor - and when applicable, the other copyright owners. Requests for permission should be directed to the editor via the contact information stated above.

©2015 All rights reserved.

Major Upgrade!
NOW SHIPPING!



Biopac Student Lab 4.1

Integrated Hardware, Software & Curriculum for Life Science Education

Students record data from their own bodies, animals, or tissue preps

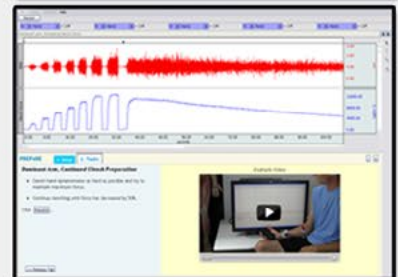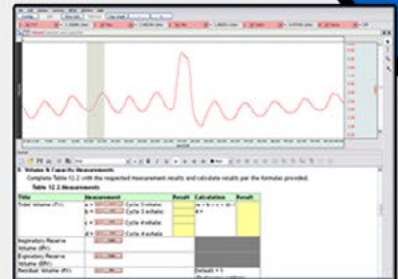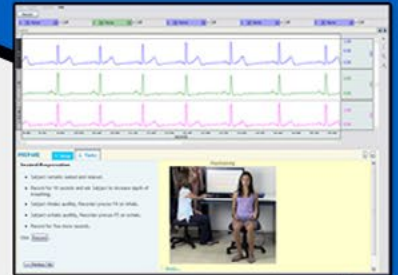New! Teach Your Way with Powerful Curriculum Management System

Easily control & customize lesson content, including on-screen instructions, introductory concepts, recording and analysis procedures, and data reports.

Engage & Empower Your Students with Interactive, Multi-Media Lessons

The Gold Standard in Life Science Labs

The ultimate teaching solution for life science labs...



Watch tutorials online

“...these systems have successfully transformed the physiology laboratory.”

Biopac Student Lab 4.1

- ✓ Proven to increase confidence & proficiency
- ✓ Used in thousands of labs worldwide
- ✓ Incorporated in major published lab manuals

Request a demo or upgrade now!



www.biopac.com info@biopac.com

42 Aero Camino, Goleta, CA 93117 | T 805-685-0066 | F 805-685-0067



Marvels of the Bologna Anatomical Wax Museum: their theoretical and clinical importance in the training of 21st century medical students

Primary Author: Francesco M. Galassi¹ f.galassi@imperial.ac.uk

Co-authors: Alessandro Ruggeri², Kevin Petti³, Hutan Ashrafian¹

¹ Department of Surgery and Cancer, Faculty of Medicine, Imperial College London (UK), 1089 Queen Elizabeth the Queen Mother Wing (QEQM) St Mary's

² Department of Biomedical and Neuromotor Sciences (DIBINEM), Via Irnerio, 48, 40126, School of Medicine, University of Bologna, Italy

³ Departments of Science and Health, San Diego Miramar College, 10440 Black Mountain Road, San Diego, California, 92126

Abstract: The purpose of this paper is to draw the attention of history of anatomy enthusiasts to the anatomical wax sculpture treasures located at the University of Bologna, using a recent exhibition as a vehicle for this examination. After briefly recalling the history of the University and its anatomical wax collection, some of the major specimens chosen for this recent exhibition are described. The paper concludes with a commentary suggesting the reintroduction of anatomical wax models into the education of contemporary medical students as a useful enterprise for connecting art and anatomy, and enriching the educational experience.

Key words: history of anatomy, anatomical waxworks, medical education, anatomy teaching, University of Bologna, Italy

INTRODUCTION

The Museum of Human Anatomy at the University of Bologna is home to world-renowned artistic/anatomical treasures from the 18th and 19th centuries (Scarani *et al.* 2001). Visitors from across the globe, anatomists and artists alike, frequently travel here to enjoy anatomical wax sculptures that uniquely blend art and science. In addition to the beauty of such works, their scientific relevance has left its mark on the history of medical education. For legions of anatomy students generations ago, they served as an invaluable substitute for first-hand dissection, as well as stylized, two-dimensional textbook images. This was especially true in the past when the supply of cadavers for medical education was limited, and the preservation of dissected specimens was problematic. While the dissection experience was considered the ideal method for teaching and learning human structure, ceroplastic models provided a valuable three-dimensional alternative, and are an important element in the history of anatomy education (Miraldi *et al.* 2000).

The Luigi Cattaneo Museum of Anatomical Waxes, located in the Bologna Institute of Human Anatomy, houses a significant portion of the collection. The exhibition *Amazing Models*, which ran from November 16, 2012 to March 15, 2013, celebrated the rich history of the collection at the Bologna Institute and served to revive the interest in anatomical waxworks. This exhibition was a collaboration between several European university museums: the Boerhaave Museum, Leiden, the Netherlands; the Josephinum Museum

at the Medical University of Vienna, Austria; and the Luigi Cattaneo Museum at the University of Bologna, Italy. The direct involvement of medical students in assembling the exhibition highlighted the tight bond between education, art, and science, and served as an opportunity to reintroduce to today's medical students the historic practice of teaching with anatomical waxworks.

The purpose of this paper is to describe the exhibition, provide a historical account of the Bologna Institute, and discuss some of the more intriguing specimens that were displayed. Additionally, the authors will describe the nexus between art and anatomy, and present the notion of reintroducing into modern anatomy education the historic practice of utilizing ceroplastic models. Considering the historic and fragile nature of these artifacts, the context proposed is one of examination in a museum setting, as opposed to direct physical manipulation.

THE EXHIBITION

This was the first time these three long-operating institutions joined forces to promote the reconsideration of anatomical models as a didactic tool in the field of medical studies. Bologna inaugurated the exhibition that then traveled to Vienna, and finally Leiden later in the year. Strong symbolic value justified Bologna as the first seat of the exhibit. Indeed, Bologna is the oldest continuously operating university in the Western world, tracing its foundation back to the year 1088 (Verger 1992). It was here that medicine as a component of university training in the modern sense emerged from

continued on next page

the errors and superstitions of the Dark Ages. Indeed, the oldest surviving, and most significant statutes for the medical curriculum date back to 1405 at the University of Bologna. Outlining medieval medical practice, these texts endured for two centuries and were influential beyond Bologna (Grendler 2002).

In a centuries-old style reminiscent of a bygone era, the exhibition, *Amazing Models: 3D anatomical models between the 16th and 19th centuries*, opened with Latin quotations delivered by Rector Magnificus of the university, Ivano Dionigi, emphasizing the gravitas of this exhibition at such a historic institution. The opening ceremony was held in the Aula Magna of the Institute of Anatomy, overlooked by inscriptions of the historic professors of the Anatomical School. Most notable of these is Mondino de' Liuzzi (1275-1326), considered to be the founder of anatomic studies in the Middle Ages. Indeed, it was Mondino who reinstated human dissection into the medical curriculum (Maraldi *et al.* 2000), and authored the *Anathomia* in 1316, which was the most widely used anatomical text across Europe until the 16th century (Cunningham 1997).

The exhibition is a collection of historic and amazingly accurate anatomical models that are also works of art. The wax sculptures of the Bologna and Josephinum collections were joined by papier-mâché models from the Boerhaave Museum. Displays exhibited exquisite representations from muscles, nerves, and brains, to pathological preparations. An entire room was dedicated to a more strictly didactic section on oncology, particularly the evolution of theories and therapies for breast cancer. This unique collection demonstrated both normal and pathological anatomy in multiple media in an effort to revive the connection between art and anatomy, and was likely reminiscent of an era when students used these specimens for their studies. Brochures organized in thematic itineraries (neurology, obstetrics, teratology, normal anatomy, etc.) were written by tutors of the Bologna Department of Anatomy and accompanied every showcase as testimony to the inclusion of modern students into a teaching modality used centuries ago.

THE BOLOGNA MUSEUM OF HUMAN ANATOMY

The totality of the historic anatomical wax model collection at the University of Bologna resides in two locations: the anatomical chambers of the Academy of Sciences (Palazzo Poggi) and the Luigi Cattaneo Museum at the Institute of Human Anatomy. Artist Ercole Lelli (1702-1766) produced the core of the collection although the oldest anatomical specimens date to those produced under the direction of Antonio Maria Valsalva (1666-1723) (Maraldi *et al.* 2000). A pioneer in anatomical wax modeling, Lelli created a

collection that was unparalleled in accuracy. Using a technique of sculpting wax musculature upon natural bone, Lelli focused his work on osteology and myology. Lelli worked with other artists/anatomists such as the husband wife team of Anna Morandi (1714-1774) and Giovanni Manzolini (1700-1755) who constructed models of the organs of sensation, digestion and reproduction. The result of their combined efforts created the world's first and greatest collection of anatomical waxes for medical education. This collection was enriched through the work of modelers Clemente Susini (1757-1814) from the school of the abbot Felice Fontana (La Specola in Florence), Giuseppe Astorri (1785-1852) and Cesare Bettini (1801-1855) (Miraldi *et al.* 2000).

Professor Luigi Calori (1807-1896) played a decisive role in the process of expansion, both by establishing a collection of approximately 2000 natural bone human skulls for his anthropological studies, and collaborating with artist Cesare Bettini to produce wax models representing both normal and pathological anatomy. By 1804, a collection of pathological anatomy waxes had been established and markedly expanded under the direction of Cesare Taruffi (1821-1902) who was the first scholar to be appointed as professor of anatomical pathology at the University of Bologna.

In the last decade of the previous century, the original nucleus of 18th century waxes by Lelli, Manzolini and Morandi (along with waxes by other modelers) were moved to the original seat of the Academy of Sciences. The portion of the collection remaining at the Institute of Human Anatomy bears the name of professor Luigi Cattaneo (1925-1992) who directed the restoration and reorganization of the wax model assemblage (Ruggeri 2003) and served as home for *Amazing Models*. While containing representations of normal anatomy, the majority of the models in the Luigi Cattaneo collection however, focuses on pathology and contains mostly 19th century specimens. Bolognese anatomists consider the collections at the University Museum of Palazzo Poggi, and the Institute of Human Anatomy as a whole, and represent a continuum in the history of anatomical teaching.

SOME SPECIMENS

Four of the more impressive wax sculptures that were included in the *Amazing Models* exhibit are discussed below. These models portray a midsagittal section of a brain within the cranial vault; a fetus, umbilical cord, and placenta; the teratological condition pygopagus; and the oncological condition of lower limb melanoma.

continued on next page

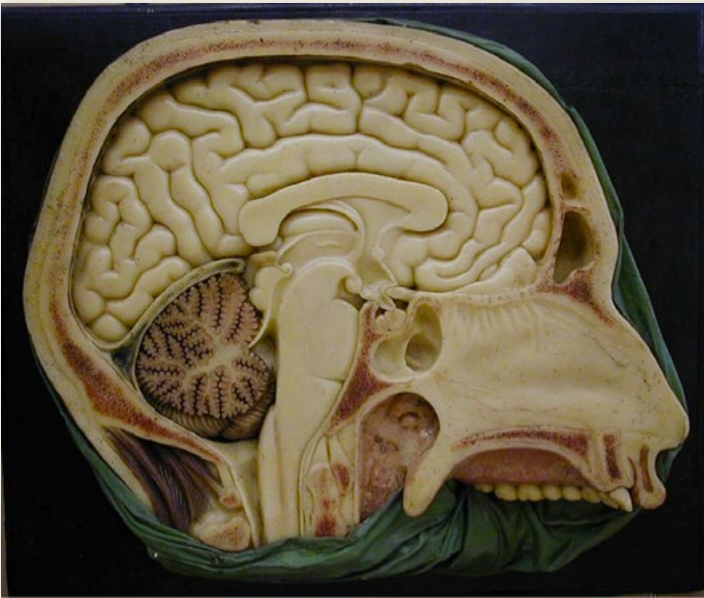


Figure 1 Brain morphology by Cesare Bettini. This waxwork model is three to four times life-sized.

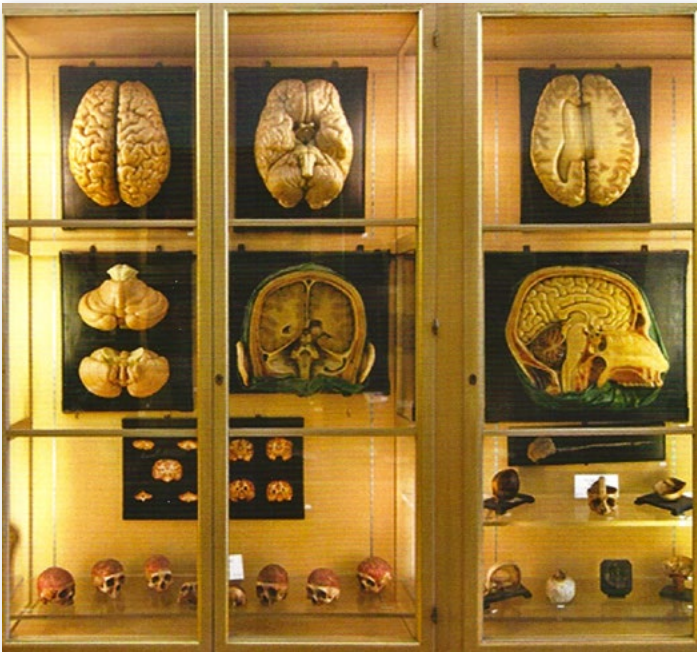

Figure 2 Display cabinet, Luigi Cattaneo Museum of Anatomical Waxes. The size of Bettini's Brain Morphology wax model in Figure 1 is demonstrated as it hangs above shelves containing natural skulls.

The extraordinary 19th century wax sculpture in Figure 1 by Cesare Bettini represents a midsagittal section of the skull. It can be seen that the whole brain is exposed within the skull and divided exactly into two halves. Note that the septum pellucidum is entirely intact. Bettini impressively demonstrates an array of anatomical detail: the cerebral convolutions of sulci and gyri; a well-defined tentorium cerebelli separating the hemispheres of cerebellum from those of the cerebrum; the communication between the cerebral aqueduct and fourth ventricle; and the sinuses of the sphenoid and frontal bones. Shown in all of its colorful intricacies, the cerebellar arbor vitae is perhaps the most striking feature of this model.

With the appointment of Bettini as official sculptor, the usefulness of producing very large models became clear. Indeed, this specimen is several times life-sized. The scale of Bettini's work can be best appreciated in Figure 2. Compare the life-sized skull and brain specimens on the bottom two shelves with Bettini's oversized brain model from Figure 1 (hanging above on the right). In fact, Bettini sculpted all of the hanging neurologic models in Figure 2. Illustrating fine workmanship and subtly different shades of color, these preparations were extremely beneficial to medical students in helping them understand difficult spatial relationships, and indeed sometimes proved to be "more accurate" than a dissected cadaver (Pigozzi and Ruggeri 2010).

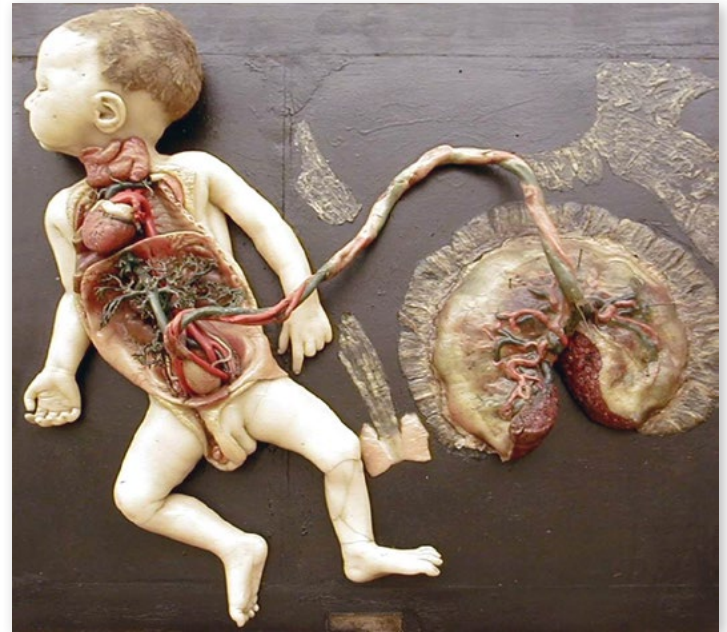


Figure 3 Fetus linked to the placenta via the umbilical cord with demonstration of fetal circulation by Giuseppe Astorri.

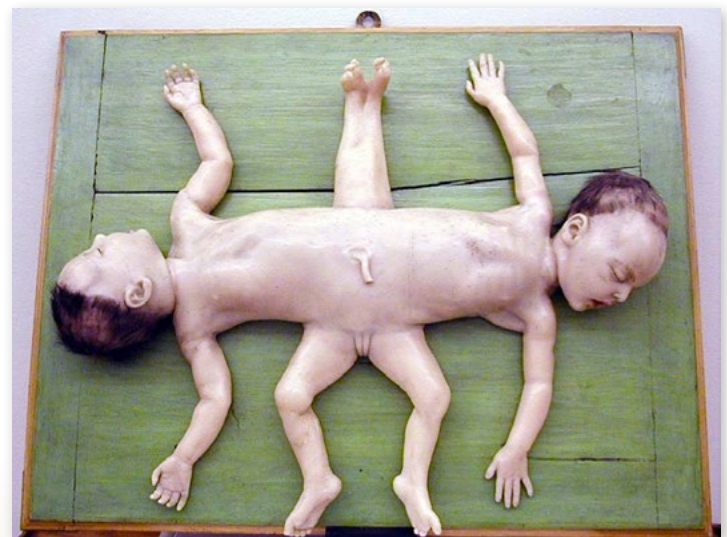


Figure 4 Pygopagus by Giuseppe Astorri.

continued on next page

The ceroplastic artist Giuseppe Astorri sculpted these 19th century obstetric models. Not long before Astorri's day, obstetrics had been regarded as a practice for midwives, and was just admitted into the family of medical specializations (Tega 2001). A collection of normal and pathological obstetric teaching models for physicians was needed.

Figure 3, also larger than life-size, deftly depicts the communication of the umbilical cord with the fetus and placenta. The heart is awkwardly represented perhaps to reveal its posterior structure. Figure 4 demonstrates the conjoined twins condition pygopagus, where the two fetuses are joined at the sacrococcygeal region. This model is important as it represents an early element of the pathological collection of the Institute of Anatomy. These two ceroplastic sculptures together represent just a fraction of the didactic models used for 19th century obstetric training at the University of Bologna.

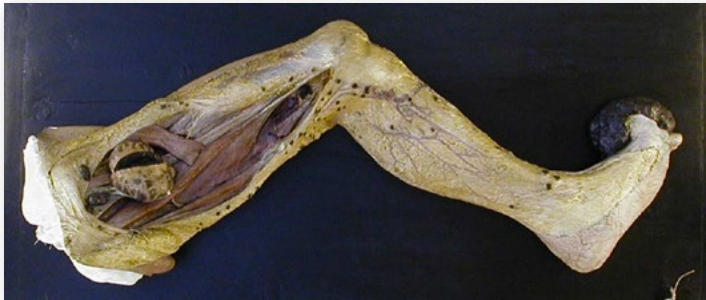

Figure 5 Wax model of lower limb melanoma by unknown artist of the University of Bologna.

The final wax model represents melanoma of the great toe (hallux) and was sculpted by an unknown artist in the 19th century. The model appears to be extremely accurate as it shows both a voluminous mass and the dissemination of the neoplastic process. The main formation ends up capping the entire toe in a fungoid pattern. The onlooker can easily observe how along the thigh and leg several smaller and more delimited malignancies are distributed, easily gaining an insight into how the process spreads in vivo. Moreover, the upper portion shows the presence of a swollen chain of lymph nodes pervaded by metastases, just another sign of tumoral infiltration and dissemination. Finally, on the proximal-medial thigh is what appears to be a larger lymph node that has been dissected so the viewer may have a better look at its inner area.

DISCUSSION

"This (anatomy) is a science which is better learnt and retained by watching and touching than by speaking about it or spending many hours reading about it" (Calori 1850). Such a powerful statement by Luigi Calori marked the success of demonstrative, three-dimensional anatomy over its textbook counterpart; an evolution that included the rise of anatomical wax sculptures.

This movement was born when Professor Mondino de' Liuzzi was at the University of Bologna. His 14th century treatise on anatomical dissection broke with the old Galenic tradition and paved the way for an era of precise anatomical dissections and direct observation of nature by medical students and faculty (Cunningham 1997). Among others, Mondino's work was reinforced and expanded upon by Berengario da Carpi in his *Commentaria super anatomia Mundini* in 1522 with what can be considered the first truly illustrated anatomical text for medical education (Rifkin *et al.* 2006). The science of anatomy and its connection to art reached a crescendo in the work of Leonardo da Vinci and Andreas Vesalius who both used artistic methods to accurately illustrate human anatomy for didactic purposes (Saunders and O'Malley 1982, Clayton and Philo 2012). Although Leonardo never published the anatomical text he was authoring Vesalius produced the most richly illustrated and important anatomical text of the Renaissance (Saunders and O'Malley 1982, Clayton and Philo 2012).

At best, medical students from the 14th to 18th centuries participated in one or two public dissections annually that were confined to the winter months; hardly adequate to acquire a command of the discipline. By the 17th century, the difficulty in acquiring enough cadavers to meet the growing demand of anatomy students resulted in the need to produce a nonperishable substitute. The inevitable result was the highly accurate anatomical wax models (and to a lesser extent papier-mâché) that were sculpted through direct observation of dissected cadavers (Ballestriero 2000). Such models were continuously available, and proved essential to the education of generations of medical students who could then conclude their studies with a solid understanding of human anatomy. Students then had a knowledge based on the three-dimensional observation of accurately represented human organs. This was substantially different from that which was characteristic of pre-18th century students who had modest exposure to actual dissection, and largely possessed a theoretical knowledge acquired through the written word, which had for centuries been regarded as superior to experience (Aldini 2010).

Furthermore, these models were works of art in their own right, and continued the tradition of anatomists collaborating with artists. Vesalius in the 16th century employed artists from the workshop of Titian, most likely by artist Jan Stephan van Calcar, to produce the famous woodcuts in his magnum opus *De Humani Corporis Fabrica* (Saunders and O'Malley 1982). And although the projects never came to fruition, Leonardo and Michelangelo Buonarroti (with Realdo Colombo) were each working to illustrate anatomy texts intended for medical education (Clayton and Philo 2012, Carlino 1994). Indeed, the earliest use of wax to demonstrate human anatomy was most likely by Leonardo who

continued on next page

injected liquid wax into the brain to demonstrate the shapes of the ventricles (Clayton and Philo 1982).

Undeniably, the historic connection between artists and anatomists can be viewed as unique and unbreakable (Laurenza 2012). Giorgio Vasari, Renaissance artist and historian, tell us in his *Lives of the Artists*, that Renaissance masters conducted human dissection to heighten their painting and sculpture (Laurenza 2012). It is as though anatomist and artist were fused into a single entity. Art was at the service of anatomy, while anatomy provided art with the foundation for magnificent representations (Scarani *et al.* 2001).

The models and the specimens produced in the past are far more than artistic sculptures; rather, they are the products of active scientific research and production, and the nexus of anatomist and artist. They are capable of furnishing students with practical knowledge for their future careers as physicians, while at the same time allowing them to admire artistic beauty and anatomical accuracy. Such an interdisciplinary enterprise is likely to deepen and enrich anatomical science education in a unique manner. The intimate relationship between art and science was celebrated in a captivating fashion in the *Amazing Models* exhibit, and was a persuasive vehicle for discussion about this connection.

CONCLUSION

It seems compelling to suggest that the study of ceroplastic models should be reconsidered as an integral tool in expanding students' understanding of human anatomy. This endeavor is valuable on many levels. It provides students with a three-dimensional vision of human structures otherwise barely comprehensible if solely studied with books. These models are also a valid adjunct to the modern plastic models ubiquitous in today's anatomy laboratory. Further, ceroplastic models can prove particularly useful in countries where dissection is not a regular component of the anatomical syllabus. It has been suggested "even today these collections (in Bologna and Florence) could serve for gross anatomy demonstrations, especially for rare entities, to medical students and pathology residents" (Nicosia 2006).

Certainly, a host of wax sculpture alternatives exists today that can provide effective anatomy education. Such options include three-dimensional computer modeling, colored radiography, photographic atlases of dissected human tissue, and plastinated human organs. Indeed, plastination can be considered a furtherance of the wax modeling practice (Maraldi *et al.* 2000). It seems self-evident however, beyond their actual didactic usefulness, that there is great value in exposing contemporary students to a glorious bygone age of scientific creativity, when anatomists employed the skills of artisans to produce anatomical wax sculptures sufficient for medical education. Students are likely to gain an appreciation for the history of their discipline, meant as a sense of continuity with the past,

and perhaps connect art and anatomy for the first time in their minds. In addition, such an approach would presumably allow students to investigate beauty in the human body, even appreciating the body itself as a work of art.

The difficulty with this concept is that these specimens reside in the holdings of a small number of university anatomy museums, limiting availability to students. Fortunately, these museums are open to the public and welcome students to examine their collections. The *Amazing Models* exhibit, with its large collection that traveled across Europe, served as a vehicle for increased student access. Perhaps in the future a virtual exhibition of these historic, artistic anatomical specimens will make them available to the whole world via the Internet.

Anatomy programs may consider incorporating into their curriculum visits to the museums that participated in the *Amazing Models* exhibit. This includes the University of Bologna anatomical wax collections at the Luigi Cattaneo Museum, and the Academy of Sciences (Palazzo Poggi), as well as the Josephinum Collection of wax sculptures in Vienna, and the papier-mâché models from the Boerhaave Museum. Other important wax anatomical collections include Clemente Susini's models at the University of Florence (La Specola), and the University of Cagliari (Riva *et al.* 2010).

While a contemporary need for uniform, quality-assured teaching methods is the norm in anatomy education, we are persuaded that rediscovering the beauty and teaching usefulness of anatomical wax sculptures – even as an optional curricular opportunity – should be taken into consideration. For many students across the globe, a visit to any one of these venues would be a once-in-a-lifetime opportunity. The result however, is likely to be an interdisciplinary understanding of the art and science of human anatomy for an entire career.

The authors wish to thank the scientific director, teaching staff, administrative body and student tutors of the Bologna Institute of Anatomy and the "Luigi Cattaneo" Museum.

LITERATURE CITED

- Aldini N, Scarani P, Orsini E (2010). *La diagnosi clinica nell'ottocento illustrata attraverso le cere anatomiche bolognesi*. Atti del Convegno Primavera della Società Italiana di Storia della Medicina; Dogliani, Italia.
- Ballestriero, R (2010). Anatomical models and wax Venuses: art masterpieces or scientific craft works? *Journal of Anat.* 216(2): 223-234.
- Calori L (1850). *Tavole Anatomiche: Volume I. Bologna, Italy: Tipografia Sassi nelle Spaderie*. Preface.

continued on next page

- Carlino A (1994). *Books of the Body: Anatomical Ritual and Renaissance Learning*. Chigago, IL: University of Chicago Press. p.63.
- Clayton M, Philo R (2012). *Leonardo da Vinci: Anatomist*. Windsor, UK: Royal Collections Publications. p.9.
- Cunningham A (1997). *The Anatomical Renaissance: The Resurrection of the Anatomical Projects of the Ancients*. Burlington, VT: Ashgate Publishing. p.42.
- Garrison, DH (2013). Vesalius and the achievement of the Fabrica, *Karger Gazette*. 73: 2-4.
- Grendler, P F (2002). *The Universities of the Italian Renaissance*. Baltimore, MD: Johns Hopkins University Press.p. 318.
- Laurenza, D (2012). *Art and Anatomy in Renaissance Italy: Images from a Scientific Revolution*. Metropolitan Museum of Art. New York. p. 5.
- Maraldi NM, Mazzotti G, Cocco L (2000) Anatomical waxwork modeling: The history of the Bologna Anatomy Museum. *Anat Rec*. 261:5-10.
- Nicosia S (2006). *Anatomical waxes in 18th century Italy*, History of Pathology Symposium, 95th Annual Meeting United States and Canadian Academy of Pathology; Atlanta, GA.
- Pigozzi M, Ruggeri A (2010). *Cesare Bettini 1814 – 1885*. Bologna: Edizioni Tip. Le. Co. p. 2.
- Rifkin, BA, Ackerman, MJ, Folkenberg, J (2006). *Human Anatomy: Five Centuries of Art and Science*. New York, Abrams Publishing.(2006). p.13.
- Riva A, Conti G, Solinas P, Loy F (2010). *The evolution of anatomical illustration and wax modeling in Italy from the 16th to 19th centuries*. *J Anat*. 216(2): 209-222.
- Ruggeri A (2003). *The Anatomical Wax Model Museum Luigi Cattaneo*. 2nd Edition. Bologna. University of Bologna. p. 2.
- Scarani P, De Caro R, Ottani V, Raspanti, M, Ruggeri, F, and Ruggeri, A (2001). Contemporaneous anatomic collections and scientific papers from the 19th century school of anatomy of Bologna: Preliminary report. *Clin Anat*. 14:19-24.
- Saunders J, O'Malley C (1982). *The Anatomical Drawings of Andreas Vesalius*. New York, NY. Bonanza Books. p. 16.
- Tega, W (editor) (2001). Room 5 – The School of Obstetrics. In *Guide to the Museo di Palazzo Poggi: Science and Art, 2nd edition*. Editrice Compositori, Bologna, Italy.
- Verger J. (1992).Chapter 2: Patterns. In Rüegg W. (Editor). *A History of the University in Europe: Volume I, University in the Middle Ages*. Cambridge, UK: Cambridge University Pres. p. 35-76.

PHOTOS

(Photos courtesy of the *Luigi Cattaneo Museum of Anatomical Waxes*)

About the Authors



Francesco M. Galassi, MD, collaborates with the Luigi Cattaneo Museum of Anatomical Waxes and served as an anatomy tutor at the University of Bologna for many years. He conducts research in neuroscience and the history of medicine at Imperial College London, and is also a freelance classicist.



Alessandro Ruggeri, MD, is Emeritus Professor of Human Anatomy at the University of Bologna, and was the scientific director of the Luigi Cattaneo Museum for decades. He is an expert in the history of waxwork and medical education in Italy.



Kevin Petti, PhD, is Professor at San Diego Miramar College and President Emeritus of HAPS. His main research is in the history of anatomy education in the Italian peninsula. As founder of Anatomia Italiana, he leads HAPS-I and undergraduate study abroad courses to Italy several times each year.



Hutan Ashrafian, PhD, MRCS, is a surgeon and Clinical Lecturer in Surgery at Imperial College London. His research focuses on surgical metabolic modulation, systems biological modelling, robotics, and enhanced patient outcomes. His interests include disease analysis in art and the history of medicine.

Introducing Our New Online Master of Science Degree in Human Anatomy and Physiology Instruction

NYCC's **Master of Science in Human Anatomy and Physiology Instruction (MSHAPI)** program is uniquely designed for those with a professional healthcare or advanced biology degree. The course of study builds on existing anatomy and physiology knowledge base, transforming the student into an exceptional A&P instructor for the undergraduate level of higher education.

This masters degree program is **offered online**, providing all the advantages of the online educational environment important to advanced learners. It has components that:

- Assure competency over the entire spectrum of undergraduate anatomy and physiology instruction
- Provide a sound foundation in instructional theory and practices
- Allow for a measure of specialization through selection of elective courses

Contact the Admissions Office at 800-234-6922 or visit us at www.nycc.edu.

"The MSHAPI approach is unique – it starts with a student already educated in A&P course content and builds on that foundation, creating a highly trained instructional specialist for the undergraduate A&P lecture room and laboratory."

Michael Mestan, D.C.
NYCC EXECUTIVE VICE PRESIDENT OF ACADEMIC AFFAIRS

Learn to
teach.
Teach to
transform.

**CLASSES
NOW
FORMING**



**NEW YORK
CHIROPRACTIC
COLLEGE**

**Finger Lakes School of
Acupuncture & Oriental
Medicine of New York
Chiropractic College**

**School of Applied
Clinical Nutrition**

2360 Route 89 • Seneca Falls, NY 13148



A Functional MRI (fMRI) Study Showing Neuroanatomical Correlates of Medical Image Interpretation and Effects of Art Instruction on Visuo-spatial skills in Medical Education

Elliot Dickerson BS¹, Caryn Babaian, MS, MEd.², Kim Curby, PhD³, Beverley Hershey, MD¹, Scott H. Faro, MD¹, Feroze B. Mohamed, PhD¹.

Department of Radiology¹, Psychology³, Temple University; Department of Math, Science and Technology, Bucks County Community College², Philadelphia, PA, USA.

Address for Correspondence: Caryn Babian, MS, MEd Department MAST, Bucks County Community College, 275 Swamp Road, Newtown, PA 18940

Abstract

Art instruction is often viewed as an important adjunct to conventional medical education. Over half of U.S. medical schools offer required or elective courses in art. Some have questioned the efficacy of this instruction. The purpose of this study was to determine whether fine art instruction improved research subjects' ability to discriminate pathologies in radiographs. To achieve this goal, the subjects' brain activity was documented while reading radiographs prior to fine art instruction and again after fine art instruction. Pre-art-instruction brain activity and corresponding changes in brain activity after fine art instruction were both determined by functional MRI (fMRI) scans. The art instruction consisted of a five-week course utilizing the scientific treatises of Leonardo DaVinci. To our knowledge, this is the first fMRI study to describe the functional activation associated with a medical image interpretation task.

Introduction

Fine art and illustration instruction has been promoted as a useful adjunct to traditional medical education. 22% of United States medical schools include visual art instruction as a required component of their medical curriculum and 43% offer elective course credit for classes covering the visual arts (Rodenhauser *et al.* 2004). In a study performed by Dolev *et al.* in 2001, first-year medical students who were randomly assigned to make in-depth observations of fine art pieces out-performed other medical students in identifying the key diagnostic features of photographs of illness. The other medical students who participated in this study had either attended didactic lectures on how to read abdominal radiographs or participated in patient history and physical examination skill sessions (Dolev *et al.* 2001). Many surgeons, particularly plastic surgeons, espouse the value of fine art and illustration in medical training (Morani 1992, Stone 2000) and infectious disease specialists have found fine art instruction an effective means for engaging medical students in humanistic and diagnostic facets of HIV/AIDS care (Tapajos 2003). In addition, active interaction with visual representations of anatomy has been demonstrated as an effective means of teaching functional cardiovascular anatomy (Wittich *et al.* 2002). The existing literature suggests that fine art instruction may lower students' threshold for detection of clinical anomalies and facilitates clinically relevant observational skills.

Functional MRI (fMRI) studies, based on blood oxygenation level dependency (BOLD) imaging, suggest that highly trained artists demonstrate greater anterior "higher-order" cortical activation during illustration tasks than novice artists. The increased cortical activity is localized in the right middle frontal gyrus, which is associated with mental manipulation and categorizing observed objects (Solso 2001). Visual-gaze tracking studies have shown that the eye movements made by trained radiologists as they evaluate radiographs differ from the eye movements of a layperson who is doing the same task. A trained radiologist directs more attention to the most clinically relevant parts of the radiograph than a layperson typically does (Kundel and Nodine 1983). Illustration training may permit medical trainees to exercise and sharpen their visuospatial processing skills and increase functional activation in regions that underlie the differences between novice and trained interpreters of medical images. To our knowledge there have been no studies to date that have identified the neural correlates involved in interpreting medical images as well as the neurocognitive effects of arts in medical image interpretation. This study used fMRI imaging to identify the neuroanatomical substrates active during medical imaging interpretation.

Although sighted individuals are exposed to an almost constant stream of varied visual stimuli, prior literature provides several examples of improved visual processing following brief but directed training

continued on next page

paradigms for interpreting visual stimuli. Yotsumoto *et al.* demonstrated that subjects subjected to a texture discrimination task in only the left upper visual field consolidated those training effects during sleep after those training sessions, but only in the primary visual cortex (V1) regions corresponding to the left upper visual field (Yotsumoto *et al.* 2009). Similarly, cats undergoing a perceptual learning task with a single eye performed better at future perceptual tasks and demonstrated increased contrast sensitivity in the V1 neurons, but only in the trained eye and corresponding section of V1 (Roelfsema *et al.* 2010).

Prior investigations have also demonstrated that conscious attention to particular aspects of a visual stimulus can produce fMRI detectable changes in basic visual processing behavior. An fMRI study by Polk *et al.* involved a Stroop task, which consisted of naming the font color of a visual stimulus in spite of the stimulus letters forming a distracting-color word. The Stroop task results showed enhanced activation in a “color area” of the lingual gyrus and reduced activation in a “word area” of the fusiform gyrus. These results demonstrated that attending to the Stroop task inhibits activations in cortical areas likely to prompt incorrect responses (the “word area”) while enhancing the activation of areas related to adaptive responses to the task (the “color area”) (Polk *et al.* 2008).

Given these demonstrations of the “room for improvement” which exists in a subject’s basic visual processing capabilities as well as the role of “top down” attention in affecting how subjects carry out visual processing tasks, we hypothesized that formal art illustration instruction and the practice which it provides in carefully attending to shape, shade, color, and spatial relationships would enhance students’ ability to interpret radiographs and be reflected in changes in brain activity during the tasks. One of the factors that motivated us was the belief that this might serve as a useful educational supplement for the wide range of trainees that will come to rely upon their ability to interpret medical images in a professional career.

Materials and Methods

Participants

Nine healthy, right-handed first and second-year medical student volunteers were recruited as test subjects. The group was composed of seven females and two males who ranged in age from 23 to 27 years. The study was HIPAA (Health Insurance Portability and Accountability Act) compliant and approved by the institutional review board of Temple University in Philadelphia, PA. (IRB# 11162) Subjects self-described their experience with illustration as either “total novice” or “one semester of college drawing.” Subjects were provided with a five-week class in basic art instruction. All subjects completed the basic art instruction course to the satisfaction of the instructor Caryn Babaian. Subjects participated in two fMRI scanning sessions with included medical imaging interpretation. The first

scanning session was performed prior to the five-week basic art instruction course and the second scanning session was performed upon completion of the basic art instruction course. One subject was unable to complete the first fMRI scanning session but completed the second fMRI scanning and the illustration task session. All components of this study are described in detail below.

Art instruction Class

Participants met three hours a week for five weeks for a total of 15 hours of instruction in artistic and scientific illustration. This served as an introduction to the use of art in anatomy and medicine. Materials included basic illustration and painting supplies and a workbook created by Caryn Babaian, one of our authors. As class projects, subjects were instructed to draw portraits of each other, to create illustrations of natural objects such as seashells and seedpods, and to make drawings of anatomical structures, including the heart and its major vessels. The drawings were made from photographs, medical imaging studies, and other medical illustrations that were obtained by the students. Participants also received live demonstrations and instruction through chalkboard drawings that included an introduction to Leonardo DaVinci’s scientific illustration treatise (Figure 1). Demonstrations included

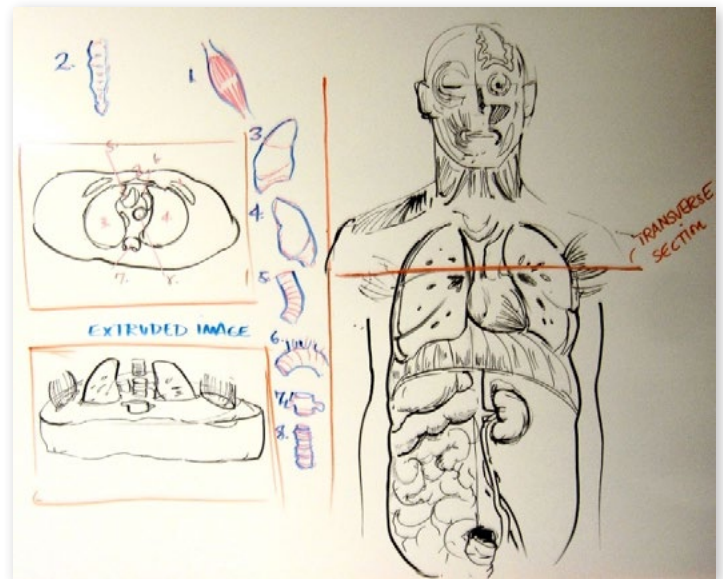


Figure 1: Samples of didactic materials by author C. Babaian on dry-erase board from art-instruction course relating to the relationship between 3D anatomy and 2D medical imaging such as CT or MRI

rotating transverse sections, drawing from surgical photographs, and drawing bones of the hand using their own hand as the model. Participants practiced visualizing anatomy and visually rotating objects as they continued to draw. As a group they re-drew DaVinci’s Vitruvian man and the multi-conceptual image created by the instructor on the chalkboard, placing the major organ systems within the Vitruvian image.

continued on next page

A more advanced project included using only lines to illustrate the heart and its contours in three dimensions. As a final project, students were instructed to re-draw the portraits they had previously done of their partner, focusing on the upper body. They were directed to place their previously illustrated heart inside the portrait of their partner.

fMRI Paradigm

The fMRI and behavioral data reported here comes from a medical imaging interpretation task. For the task, subjects were shown three types of radiographic images. The first image was of a normal CT scan of the head. The second image was a CT scan of the head that demonstrated a pathological image of a right hemispheric acute subdural hemorrhage with associated midline shift of the brain to the left. The third was a CT scan of the head that functioned as the control. The control CT image of the head was set to a “window” that did not display soft tissues, but rather displayed only a white outline of the bony structures. The object of the task was to determine if the subjects were able to distinguish the pathology faster and better after they had completed the fine art illustration course.

The fMRI paradigm was a block design consisting of five 30-second task blocks alternating with five

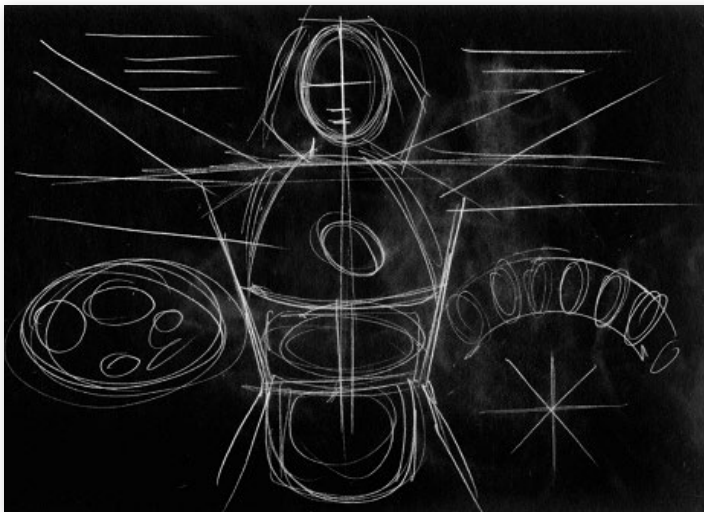
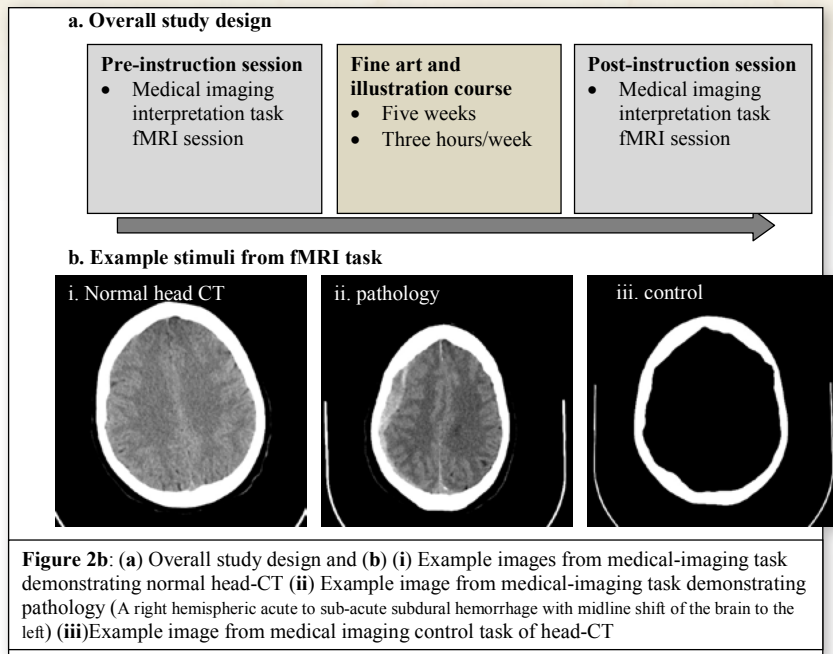


Figure 2: Basic shape layout of the Vitruvian man created during 5 week drawing course

30-second control blocks for a total functional scanning time of five minutes. In the medical imaging fMRI task (Figure 2), subjects were presented with a series of frames from computer tomography (CT) scans of the head. Images were presented in pseudo-random order for 5 seconds each. Participants were asked to judge if each scan represented normal anatomy or pathology and to respond using an MRI-safe computer mouse by clicking the right or left mouse button. The right button



indicated normal anatomy and the left button indicated pathological anatomy. Subjects were asked to prioritize accurate responses within the allotted stimulus presentation period. Our CT images were originally selected by one of the authors, Scott Faro MD, who is a board-certified neuroradiologist. Dr. Faro’s interpretations of the scans as normal or abnormal were used as the gold-standard for measuring the proportion of accurate responses made by subjects. So that fMRI signal between task and control blocks would more specifically represent the image interpretation task and minimize any changes related only to visual stimuli, subjects were presented with a series of CT images of the head in the control blocks that were set to a “window,” which did not display soft tissues, but rather displayed only a white outline of bony structures (Figure 2). Subjects were asked to respond with a left mouse click for each new control image presented. The Presentation software package was used to present images and record subject responses made via computer mouse. (Presentation 13.0 for Windows, Neurobehavioral Systems; Albany, CA).

Imaging Parameters

fMRI parameters: Blood-oxygen-level dependent (BOLD) T2* echo-planar-imaging; field of view: 220 mm, slice thickness: 5mm, repetition time: 2000 ms, 64x64 voxels, and echo time: 30 ms.

Postprocessing

SPM8b (Wellcome Trust Centre for Neuroimaging; London, UK) was used to process and analyze functional images (Friston *et al.* 1994). Using the SPM8b pre-processing tools, functional images were realigned, normalized to the provided canonical SPM8b EPI template brain, and smoothed with a Gaussian

continued on next page

kernel of 6.88 x 6.88 x 8 mm. In single-subject analysis, a design matrix was created for each subject incorporating contrasts for fMRI experimental-task condition, control-task condition, and head movement realignment parameters. Results from SPM8b are recorded in statistical parametric maps (SPM's) as β -values, which reflect the most likely-value estimate of the effect-size of various contrasts upon variance in voxel intensity in statistical parametric maps (SPM's) linear model of voxel intensity. These β -values for the contrast of the fMRI experimental task versus the control task are referred to as, "fMRI signal," later in this paper.

Cortical areas of functional activation during the experimental task were assessed using SPM8b by creating a second level analysis using a one-sample t-test which referenced single-subject statistical parametric map (SPM) from the post-training scanning session in a random effects model to determine which brain regions were on average significantly more active during the medical-imaging interpretation task. Results were thresholded at a voxel false-discovery rate (FDR) of 0.05 and minimum 30 voxel extent. Neuroanatomical locations were described using the WFU PickAtlas tool (Wake Forest University ANSIR Lab; Winston-Salem, NC) and the Anatomical Automatic Labeling (AAL) neuroanatomy atlas (Lancaster *et al.* 1997, Maldjian *et al.* 2003, Ungerleider and Mishkin 1982).

An analysis of correlation between fMRI signal and subject-wise accuracy upon radiological performance was assessed on a voxel-wise basis using the pre-instruction fMRI and behavioral dataset. Results

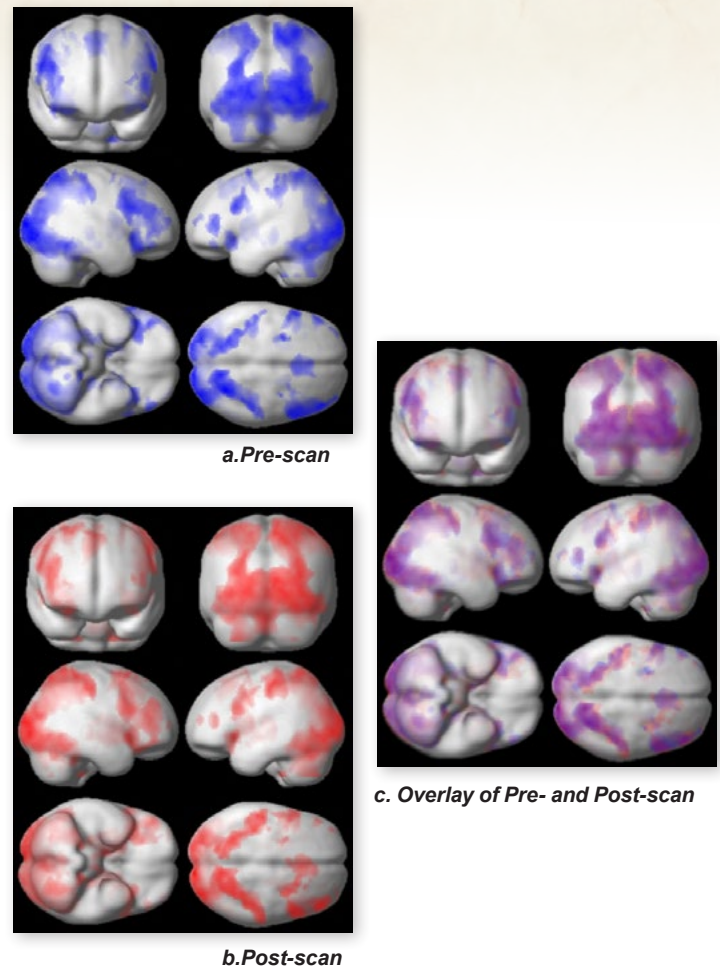


Figure 3: Task activation in (a) pre-instruction scanning session and (b) post-instruction scanning session rendered on SPM8b multiple-subject smoothed brain (FDR<0.05, minimum extent: 30 voxels). (c) Transparent overlay of pre and post-instruction activations.

Table 1: Activation before and after art instruction at a FDR < 0.05, >30 voxel extent

	MNI coordinates (mm) (x,y,z)			Brodmann area (BA)	Active in pre-instruction scanning session? (t-value)	Active in post-instruction scanning session? (t-value)
Left superior frontal gyrus	-28	4	70	6	Yes (6.45)	Yes (5.94)
Right superior frontal gyrus	30	6	62	8	Yes (9.16)	Yes (10.33)
Left middle frontal gyrus	-26	2	62	6	Yes (5.77)	Yes (5.94)
Left pars triangularis	-48	40	14	46	No	Yes (4.78)
Right supplemental motor area	8	22	48	8	Yes (9.96)	Yes (7.65)
Right cingulate gyrus	8	32	36	9	Yes (6.92)	Yes (7.65)
Right pars triangularis	54	20	22	45	Yes (11.45)	Yes (9.28)
Right middle occipital gyrus	34	-84	22	19	Yes (32.22)	Yes (26.55)
Left middle occipital gyrus	-28	-82	20	19	Yes (24.29)	Yes (25.13)
Right middle frontal gyrus	48	44	18	46	Yes (10.74)	Yes (9.26)
Right insula	40	16	-8	47	Yes (9.10)	Yes (8.45)
Right inferior occipital gyrus	30	-88	-16	18	Yes (22.73)	Yes (26.55)
Left cerebellum	-20	-36	-50	NA	Yes (7.49)	Yes (7.09)

were thresholded at an uncorrected voxel p -value of 0.05 and minimum 20 voxel extent. A region of interest (ROI) was defined using the largest above-threshold cluster from this analysis. The correlation between medical imaging interpretation task performance and blood-oxygen-level dependent (BOLD) signal was assessed in this region of interest (ROI) in the behavioral and fMRI data from the post-instruction scanning session. Outside of sharing subjects, these analysis represented independent episodes of data collection.

Statistical Analysis of Regression

The software package MIPAV (NIH Center for Information Technology; Bethesda, MD) was used to extract the average β -value from the above described ROI from the statistical parametrical maps (SPM's) created by SPM8b for each individual subject from the fMRI analysis. Correlations between illustration task

continued on next page

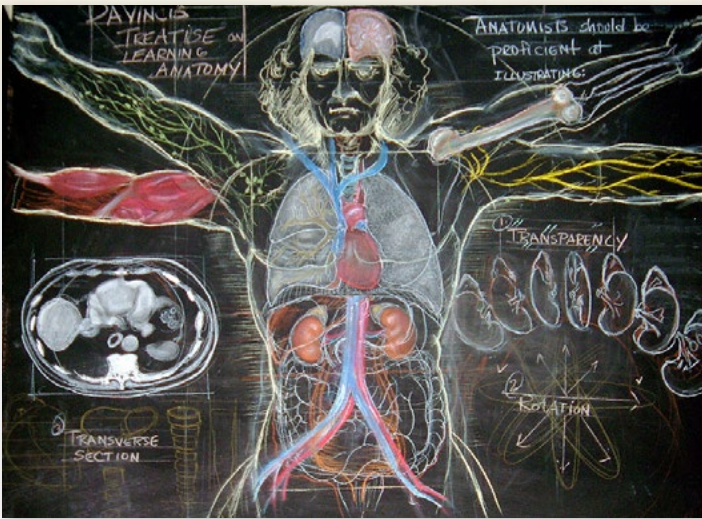


Figure 3a: Finished Vitruvian man drawing by C. Babaian showing three shared concepts in radiology imaging, the anatomical sciences, and scientific illustration. These important concepts are 1. Rotation, 2. Transparency, and 3. Transverse section. They are illustrated with a drawing of MRI section (transverse section), a kidney (rotation), and the transparent effect of the entire drawing (transparency).

performance and functional task activation were assessed in Excel and the R 2.10.1 statistical computation program (R Foundation; Wien, Austria). Specifically the “boot” library and “lm” (linear model) command were used to carry out a 10,000 sample bootstrap analysis to construct 95% and 99% confidence intervals of the Pearson’s R statistic for the correlation between medical imaging interpretation task and fMRI signal.

Change in functional activation, pre versus post-instruction

The SPM8b software was used to carry out a paired-samples *t*-test for regions that demonstrated either increased or decreased activation between the pre- and post-instruction scanning sessions. Results were limited with a threshold of an uncorrected *p*-value of 0.01 and minimum 30 voxel extent.

Also, using the above-defined region of interest (ROI), the software package MIPAV was used to extract the average β -value contained in single subject statistical parametrical map (SPM) for both the pre-instruction scanning sessions and the post-instruction scanning sessions. Using these values, a paired *t*-test matched by subject was computed in Microsoft Excel (Microsoft Corporation; Redmond, Washington).

Results

Cortical areas active during medical imaging task

The medical imaging task demonstrated a number of areas of significant functional activation both prior to and after artistic training. Activations with a false detection rate (FDR) <0.05 and a minimal 30 voxel extent are summarized in Table 1 and Figure 3, which contains renderings of areas of cortical activation both before and after artistic training. Figure 3 also includes

a transparent overlay of functional activations both pre and post-instruction.

Regions of correlation between behavioral and fMRI signal

The voxel-wise regression analysis utilizing fMRI and behavioral data from the pre-instruction scanning session revealed a 117 voxel region of interest (ROI) in the left occipital lobe where the proportion of accurate medical imaging interpretation task responses demonstrated positive correlation with fMRI signal with a Pearson’s R of 0.5031 (bootstrap simulation *p*-value <0.05). The same analysis repeated using the same ROI but with post-instruction dataset again demonstrated a positive correlation with a Pearson’s *r* of 0.5710 (bootstrap simulation *p*-value <0.05). Figure 4 contains scatterplot summaries of these data. Figure 4 also contains histogram summaries of results of bootstrap simulations for Pearson’s *r*.

Change in task accuracy before and after artistic instruction

The average proportion of correct responses to the medical imaging interpretation task showed a significant increase from an average pre-instruction proportion of 0.717 to a post-instruction proportion of 0.825 (*p* < 0.04).

Change in task activation before and after artistic instruction

Task activations within the occipital lobe region of interest (ROI) were not significantly different between the scanning session prior to artistic instruction and after artistic instruction (*p* > 0.2).

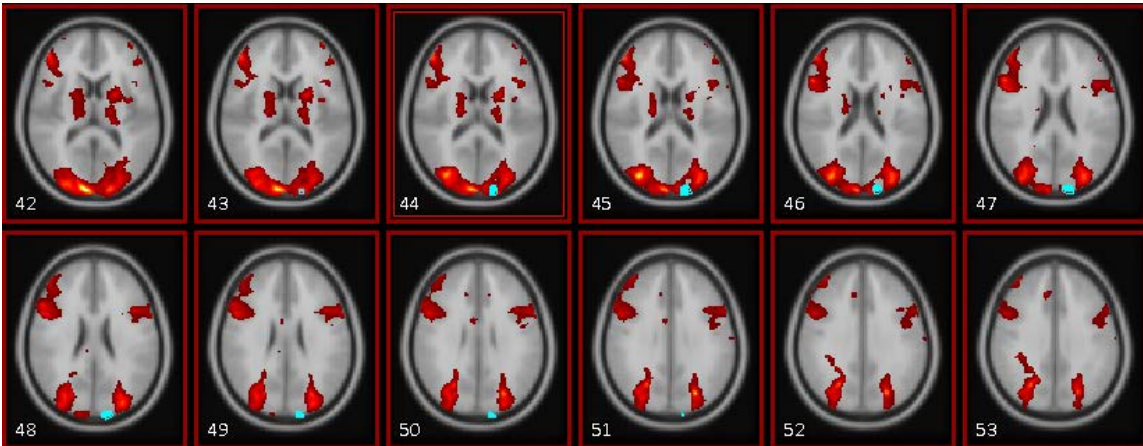
Results from the voxel-wise whole-brain paired-samples *t*-test carried out in SPM with an uncorrected *p*-value threshold of 0.01 and minimum 30 voxel extent are summarized in Figure 6 and Table 2.

Discussion

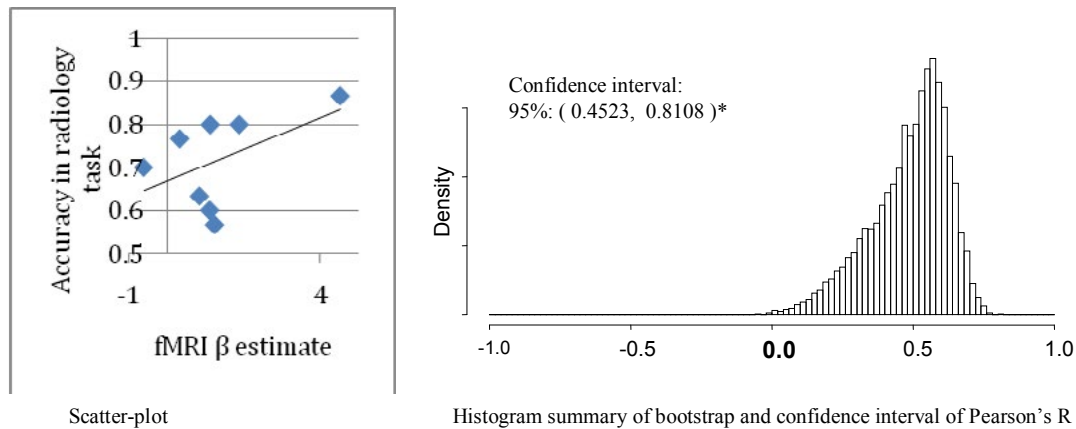
To our knowledge, this is the first fMRI study to describe the functional activation associated with a medical image interpretation task. The medical image interpretation task elicited activation in the primary visual cortex extending dorsally into the posterior parietal cortex and ventrally into the occipitotemporal cortex. These regions are classically associated with “where,” visuospatial and, “what,” visual identification pathways respectively, as suggested by Ungerleider and Mishkin in 1982 and refined by subsequent authors (Ungerleider and Mishkin 1983, Goodale and Milner 1992, Goodale and Westwood 2004). This task produced activations in the left and right superior parietal gyrus and postcentral gyrus as well as frontal cortex activations in the left and right middle and superior frontal gyrus and cingulate gyrus regions. The described task activations are largely consistent with prior descriptions of “visual working memory” areas, particularly within the primary visual cortex, dorsal visuospatial and ventral identification processing

continued on next page

a. Correlation ROI (cyan) overlaid on regions of post-instruction activation



b. Pre-instruction (statistical “training”) dataset



c. Post-instruction (statistical “results”) dataset

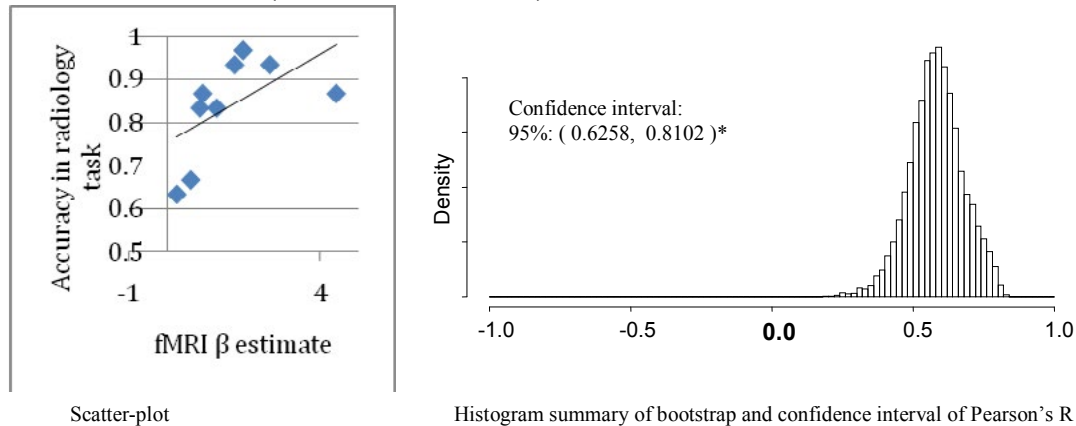


Figure 4: (a) ROI of correlation between fMRI signal (β estimate) and task accuracy on SPM8b 152 subject averaged brain with overlaid post-instruction activation. Scatterplot of correlation between fMRI signal and task accuracy as well as histogram summary of bootstrap of Pearson's R for (b) pre-instruction data (used to define ROI) and (c) post-instruction data (used to confirm results from first analysis).

continued on next page

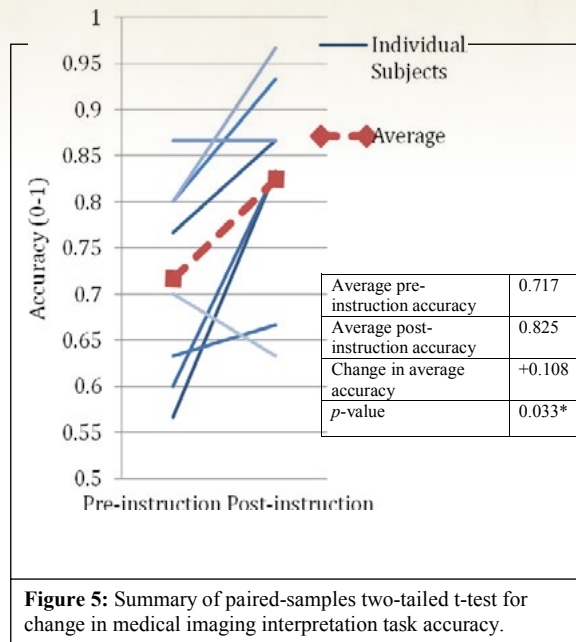


Figure 5: Summary of paired-samples two-tailed t-test for change in medical imaging interpretation task accuracy.

pathways, and the bilateral dorsolateral pre-frontal cortex (dlPFC) (Scwhartz *et al.* 2002, Zimmer 2008, Postle *et al.* 2000).

The brain region residing in V1 identified by this investigation as a region with a positive correlation between fMRI signal and medical imaging interpretation task performance is consistent with other results demonstrating a positive correlation between fMRI signal within the primary visual cortex and visual task performance (Yotsumoto *et al.* 2008, Roelfsema *et al.* 2010, Goodale and Westwood 2004, Yotsumoto *et al.* 2008, Sasaki *et al.* 2005).

The most notable changes in functional activation from the pre- to post-instruction scanning sessions were increased activation in the right dorsolateral prefrontal cortex (dlPFC) (BA 46) and left superior temporal gyrus (BA 22), and decreased activation in the right hippocampus. If they represent adaptive improvements to visual processing behaviors, as suggested by the observed improvement in experimental task accuracy, they accord with other fMRI studies of visual task execution detailed below. Generally, fMRI detected functional activation in these regions correlates with both better accuracy in performing the visual task and increased processing load. An event-related fMRI investigation found that correct responses to a visual working memory task produced fMRI β estimates of activation in the dlPFC 1.48 units greater than incorrect responses (Pessoa *et al.* 2002). Jaeggi's 2003 study with an *n*-back visual memory task showed a clear relationship between bilateral dlPFC activation and task difficulty (Pessoa *et al.* 2002). Schnell's 2007 study with a simple navigation video-game in which subjects were asked to detect incongruencies between their motor inputs and the video-game character's actions showed the same relationship between task load and activation in the dlPFC as well as the left superior temporal gyrus (Pessoa *et al.* 2002). Xu *et al.*'s 2007

study in which participants were required to classify images as identical or not found, showed decreased parahippocampal gyrus activation during the classification of more similar pairs (high load condition) compared to less similar pairs (low load condition), but an opposite trend in other regions investigated, notably the left insula and the anterior cingulate region.

Notably, prior studies suggest that the relationship between levels of fMRI task activation and levels of task training or performance ability are not often linear. For example, a number of studies have suggested that training leads to an initial increase in activation in areas

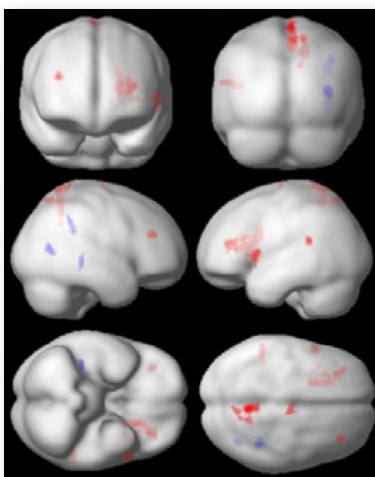


Figure 6: Regions demonstrating increased (red) or decreased activation (blue) from the pre-instruction scanning session to post instruction scanning session rendered on SPM8 multiple-subject smoothed brain (*p*-value<0.01, minimum extent: 30 voxels)

Table 2: Brain regions of increased or decreased functional activation from pre to post-instruction scanning session

Region anatomical name	MNI coordinates (mm) (x,y,z)			Brodmann area (BA)	t-value
Increased from pre to post-instruction scan					
Right middle frontal gyrus	34	36	24	46	7.88
Left superior temporal gyrus	-52	-42	18	22	6.12
Right precuneus	4	-58	70	7	5.59
Right superior frontal gyrus	8	-10	82	6	5.49
Left operculum	-52	12	4	44	4.18
Decreased from pre to post-instruction scan					
Right hippocampus	34	-34	0	NA	6.3
Right inferior parietal gyrus	42	-46	38	40	4.31
Right middle temporal gyrus	40	-66	10	39	4.23

continued on next page

relevant to task performance, but as learning continues, consolidates, and subjects are able to perform a task to a given level with decreased cognitive load, and those fMRI changes subside or even cross zero, as in Figure 7 (Yotsumoto *et al.* 2008). In Yotsumoto *et al.*'s 2008 study, subjects trained on a visual perceptual learning task over 14 sessions demonstrated the decremented response mentioned above. The number of training sessions presented in this paper (five) is consistent with the number of training sessions used by Yotsumoto *et al.* in which they observed increased V1 fMRI responses in sessions one through six, which declined to near or below naïve V1 fMRI response by session 14 (Yotsumoto *et al.* 2008). If true, this effect suggests that cognitive scientists hoping to use fMRI to explore how efficiently experts perform complex tasks compared to novices should look at longitudinal studies in comparing medical experts with novices rather than cross-sectional studies.

Our art course devoted particular attention to instructing students in how to apply abstract visual reasoning to illustration problems with a course content that was centered upon important human anatomical structures. Our course content focused on rotating structures, sectioning structures, and visualizing through and into structures (transparency). The significant increase in task accuracy identified in this study indicates that such training in artistic illustration may play a role in increasing task accuracy in clinically relevant medical imaging interpretation.

Weaknesses of this study include a small study population size (n=9) and the use of a non-randomized, quasi-experimental study design measuring fMRI data against same-subject historical controls, which were the fMRI and behavioral data from the pre-intervention scanning session. Other potential weaknesses include task-practice effects and coincidental medical education.

Clinical and pedagogical applications for this research include evaluating artistic training or other programs intended to improve participant's visuospatial processing abilities. Identifying areas of functional activation during a medical imaging interpretation task may identify how visual processing behavior differs between novice and expert performers of that task. fMRI investigation might also highlight tasks outside of explicit medical imaging training which are nonetheless worthwhile investments of time and effort for trainees who will require medical imaging interpretation abilities in the future. Future explorations of this line of research include more narrowly defining the component visual processing behaviors of artistic illustration and medical imaging interpretation, developing exercises for training these visual processing behaviors, or evaluating the aptitude of subjects for tasks requiring extensive visual processing skill. Future research may also further elaborate on the functional activation demonstrated by medical professionals throughout

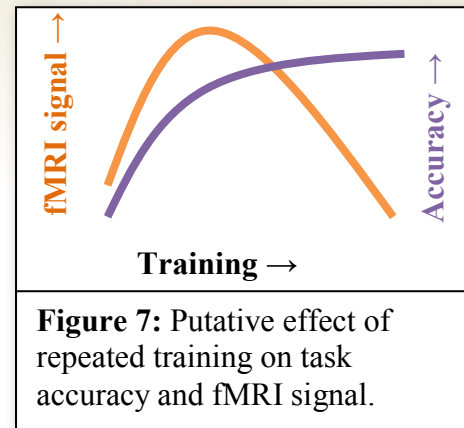


Figure 7: Putative effect of repeated training on task accuracy and fMRI signal.

different career stages. Coupling functional imaging with data on the diagnostic accuracy of subjects could potentially highlight particular image interpretation behaviors that lead to the successful detection of pathology and discrimination from normal variants.

Conclusion

The task of interpreting medical images leads to consistent functional activations within several regions of the frontal cortex, the primary visual cortex, and bilaterally in the parietal lobes in dorsal and ventral, "what" and "where," pathways, respectively.

Observed improvements in the medical imaging interpretation task in this preliminary investigation may have been due to a five week course (15 total hours) of visual art instruction but confounding factors such as task-practice effects and coincidental medical education, may encourage future investigations to utilize random assignment and a larger sample size. This investigation also suggests that visual art training activities such as the ones described in this paper may be an appropriate investment of time and resources to supplement traditional medical education practices in the area of anatomy, specifically with respect to retention of complex anatomical material and rapid identification of anatomical forms and images.


Literature cited

- Dolev JC, Friedlaender LK, Braverman IM. (2001) Use of fine art to enhance visual diagnostic skills. *JAMA* (286):1020-1.
- Friston KJ, Holmes AP, Worsley KJ *et al.* (1994). Statistical parametric maps in functional imaging: A general linear approach. *Hum Brain Mapp* (2):189-210.
- Goodale MA, Milner AD. (1992). Separate visual pathways for perception and action. *Trends Neurosci* (15):20-5.

continued on next page

- Goodale MA, Westwood DA. (2004). An evolving view of duplex vision: Separate but interacting cortical pathways for perception and action. *Curr Opin Neurobiol* (14) :203-11.
- Kundel HL, Nodine CF. (1983). A visual concept shapes image perception. *Radiology* (146):363-8.
- Lancaster JL, Rainey LH, Summerlin JL *et al.* (1997). Automated labeling of the human brain: A preliminary report on the development and evaluation of a forward-transform method. *Hum Brain Mapp* (5):238-42.
- Lancaster JL, Woldorff MG, Parsons LM, *et al.* (2000). Automated talairach atlas labels for functional brain mapping. *Hum Brain Mapp* (10):120-31.
- Maldjian JA, Laurienti PJ, Kraft RA, *et al.* (2003). An automated method for neuroanatomic and cytoarchitectonic atlas-based interrogation of fMRI data sets. *Neuroimage* (19):1233-9.
- Morani AD. (1992) Art in medical education: Especially plastic surgery. *Aesthetic Plast Surg*,(16):213-8.
- Pessoa L, Gutierrez E, Bandettini P *et al.* (2002). Neural correlates of visual working memory: fMRI amplitude predicts task performance. *Neuron* (35):975-87.
- Polk TA, Drake RM, Jonides JJ *et al.* (2008). Attention enhances the neural processing of relevant features and suppresses the processing of irrelevant features in humans: A functional magnetic resonance imaging study of the stroop task. *J Neurosci* (28):13786-92.
- Postle BR, Stern CE, Rosen BR, *et al.* (2000). An fMRI investigation of cortical contributions to spatial and nonspatial visual working memory. *Neuroimage* (11):409-23.
- Roelfsema PR, van Ooyen A, Watanabe T. (2010). Perceptual learning rules based on reinforcers and attention. *Trends Cogn Sci*.(14):64-71.
- Rodenhauser P, Strickland MA, Gambala CT. (2004) Arts-related activities across U.S. medical schools: A follow-up study. *Teach Learn Med* (16):233-9.
- Sasaki Y, Vanduffel W, Knutsen T *et al.* (2005). Symmetry activates extrastriate visual cortex in human and nonhuman primates. *Proc Natl Acad Sci U S A* (102):3159-63

About the Authors



Elliot Dickerson is a radiology resident of the University of Michigan. He intends to specialize in neuroradiology. His research interests include advanced MRI techniques such as perfusion MR imaging and fMRI.



Caryn Babaian is an adjunct biology professor at BCCC. Ms. Babaian's work involves visualizing biology with a focus on creative learning strategies in life science education and on scientific drawing and visualizing complex systems in physiology, ecology, and evolution. She has received awards from the NSF and is the recipient of the 2011 2- year college biology teacher of the year award from the NABT. Her work can also be seen on NOVA's Secret Life of Scientists.



Dr. Curby obtained her PhD from Vanderbilt University before completing her post-doctoral training at Yale University. She is now a research fellow at Macquarie University in Sydney, Australia. Her research focuses on understanding the cognitive and neural basis of expert visual information processing.

Photo not available.

Beverly Hershey, MD is a radiologist employed by the Department of Radiology of Temple University in Philadelphia, PA.



Dr. Scott Faro is Vice Chairman of Radiology at Temple University and professor of Radiology, Electrical, Biomedical and Computer Engineering. He is a founding member of the American Society for Functional Neuroradiology and has authored four books including "Functional Neuroradiology – Physical Principles and Clinical Applications." Dr. Faro's research interests include optimization and clinical applications of BOLD fMRI and Diffusion Tensor Imaging.



Feroze Mohamed, Ph.D., is a Biomedical MRI Physicist and Professor in the Department of Radiology at Temple University. He is also an Associate Professor in the departments of Neuroscience, Bioengineering, and Electrical & Computer Engineering. He serves as the Associate Director of the Functional Brain Imaging Laboratory at Temple University. His research interests are in development and application of functional neuroimaging methods that includes BOLD and Diffusion Tensor Imaging to study the brain and spinal cord in humans.

The Anatomical Landmarks of the Mandible Most Important For Dental Implant Surgery

Sarah Cooper, M.Ed.
Department of Biology
Arcadia University
coopers@arcadia.edu

Abstract: The growing popularity of dental implants has caused the number of surgical procedures in the mandible to increase significantly and focused renewed attention on the anatomical markings of this bone. Now that the mandibular structures can be visualized with modern imaging techniques, the anatomical complexity of the mandible may be more readily observed and characterized. This article examines dental implant surgery and the anatomical landmarks most closely associated with it. The landmarks include the mandibular foramen, the inferior alveolar nerve, the mental foramen, the mental nerve, the lingual nerve, the incisive canal and the incisive nerve all of which are of particular interest to clinicians who are planning dental implant surgery.

Modern dentistry has as its goal a multifaceted corrective strategy that can restore a patient's face and mouth to their normal contour, reestablish lost function and optimize patient comfort, speech, aesthetics and overall health. The challenge is to accomplish all of this regardless of the limitations that might be imposed by disease, injury or atrophy of the area that requires restoration (Guler 2005).

The loss of teeth characteristically results in resorption and remodeling of the associated alveolar processes that ultimately leads to atrophy of the alveolar ridges. The amount of bone loss and the rate at which it occurs may be influenced by a person's gender, hormone production, and overall metabolism but, in general, bone loss has an adverse effect on eating, speech and facial aesthetics. Dental implants can mediate bone loss and provide the necessary support for several types of dental prostheses (Guler 2005). They have become a reliable and popular choice for the restoration of missing teeth where the quantity and quality of maxillary and mandibular bone are adequate, or can be augmented, to form a platform for the implant (Juodzbalys and Kubilius 2013).

Osseointegration at the Implant Site

Modern dental implant surgery would not have been possible without the contributions of Dr. Per-Ingvar Branemark, a Swedish physician whose experiments on "osseointegration" laid the groundwork for the process. Dr. Branemark is known as the father of implant dentistry but his early work was not well received by the scientific community. In his obituary, which appeared in the New York Times on December 27, 2014, reporter Tamar Lewin described the serendipity that eventually led to the acceptance of osseointegration as a viable scientific principle (Lewin 2014).

In 1952, Dr. Branemark was conducting experiments in his laboratory in Sweden with the goal of learning more about the affect of blood flow on bone healing. His

protocol called for implanting titanium covered optical devices in rabbit tibia/fibulas so that the bone healing process could be more closely observed (Branemark 1983). When it came time to remove and examine the implanted devices, Dr. Branemark discovered, to his surprise, that the bone had fused with the titanium covering of the devices and it was impossible to separate the two. It became clear to him that the body did not interact with titanium as it does with other foreign bodies. While dogma of that time asserted that the introduction of any foreign body into a living system eventually resulted in inflammation and rejection, Dr. Branemark found no sign of inflammation or swelling at the implantation sites in his rabbit tibia/fibulas and no sign of any type of rejection. He concluded that the body not only tolerated titanium very well but also was able to incorporate it into the living system over time (Branemark 1983, Lewin 2014).

To test his hypothesis, Dr. Branemark enlisted the help of twenty of his young, male laboratory assistants, asking each of them to volunteer to have a small titanium object implanted into their humerus. This is perhaps one of the reasons why the scientific community of the mid to late 1950's did not immediately accept Branemark's methods. His early grant applications for the study of the bone/titanium interface were turned down and it was not until 1982 that he won widespread support and recognition for his work. Today osseointegration, the fusion of bone with the metal titanium, is widely used in orthopedic, veterinary and general medical applications (Lewin 2014).

Implant survival depends on the quality of osseointegration at the bone/titanium interface. For high quality osseointegration to occur there can be no non-bone tissue growth between the titanium implant post and the surrounding bony matrix. Osteoblast cells play an essential role in the process of osseointegration. They are necessary for bone cell adhesion to the metal post, cellular proliferation

continued on next page

at the implant site, the production of osteocytes and mineralization of the bone matrix surrounding the implant. The structural characteristics of the implant itself influence the overall quality of osseointegration by encouraging the proliferation of osteoblasts and the subsequent osteoblast adhesion to the implant. For this purpose, nano-structured titanium oxide implant post coverings have been found to be functionally superior to microstructured outer coverings or smooth surface coverings for maximizing osseointegration. Low numbers of osteoblasts and slow osteoblast proliferation are correlated with negative results in achieving the osseointegration (Goldman *et al.* 2014).

Transmission electron microscopy of osseointegration sites has revealed bone growth directly into the nano-structured titanium oxide covering of the implant post. In TEM micrographs prepared by Palmquist *et al.* in 2011, investigators documented mineralized bone tissue in direct contact with titanium. Collagen banding was observed perpendicular to the titanium oxide surface of the implant post, indicating that collagen fibers were laid down parallel to the implant surface. Groupings of titanium, oxygen, phosphorus and calcium signals at a distance of approximately 100 nm from the implant post indicate that bone had penetrated directly into the nano-structured titanium oxide of the implant surface. The study documented precise contact between the hydroxyapatite crystals of the alveolar bone and the titanium oxide of the implant surface (Palmquist *et al.* 2011).

Over view of Dental Implant Surgery

The goal of dental implant surgery is to replace the roots of teeth that have been lost due to accident, disease or age with metal screw-like posts, usually constructed of titanium, that are carefully positioned into the maxillary or mandibular alveolar processes. The inserted post bonds with the bone over time by osseointegration, and serves as the foundation for the attachment of artificial teeth. Dental implant surgery

requires careful planning and is generally done in stages since the process may require more than one procedure. Because the bone needs to integrate with the implant post, the process may take several months (Mayo 2015, Moriconi 2015).

Cone beam computed tomography (CBCT) is the preferred method for assessing the characteristics of the proposed implant site and facilitating pre-surgical planning. In a CBCT scan, the x-rays are divergent so that they form a cone. The equipment consists of a scanner that rotates around the patient's head while obtaining hundreds of separate images. The scanning software makes it possible to reconstruct a 3-D image of the targeted area (Figure 1), which can then be manipulated by the surgeon and visualized from many different angles. CBCT technology produces clear images of several different tissue types including bone, muscle, adjacent soft tissue and the associated vasculature (Moriconi 2015).

The dental implant process typically includes five steps, the first of which is extraction of the tooth the implant will replace, if necessary. Once the extraction site has healed, the bone is assessed for overall quantity and quality in the proposed implant region. If insufficient bone is present at the proposed implant site, bone grafting may be necessary to augment the existing bone. When the bone is judged to be adequate for the procedure, a metal post is surgically implanted in the alveolar process. Local anesthesia is used for the surgical placement of the post since positioning the implant requires that the gum be cut and the underlying bone exposed. Precision drilling into the bone provides a channel into which the metal implant post is inserted. The post must be placed deep into the bone since it is replacing a tooth root that would normally be subjected to the powerful forces generated by mastication over a period of years (Mayo 2015, Moriconi 2015).

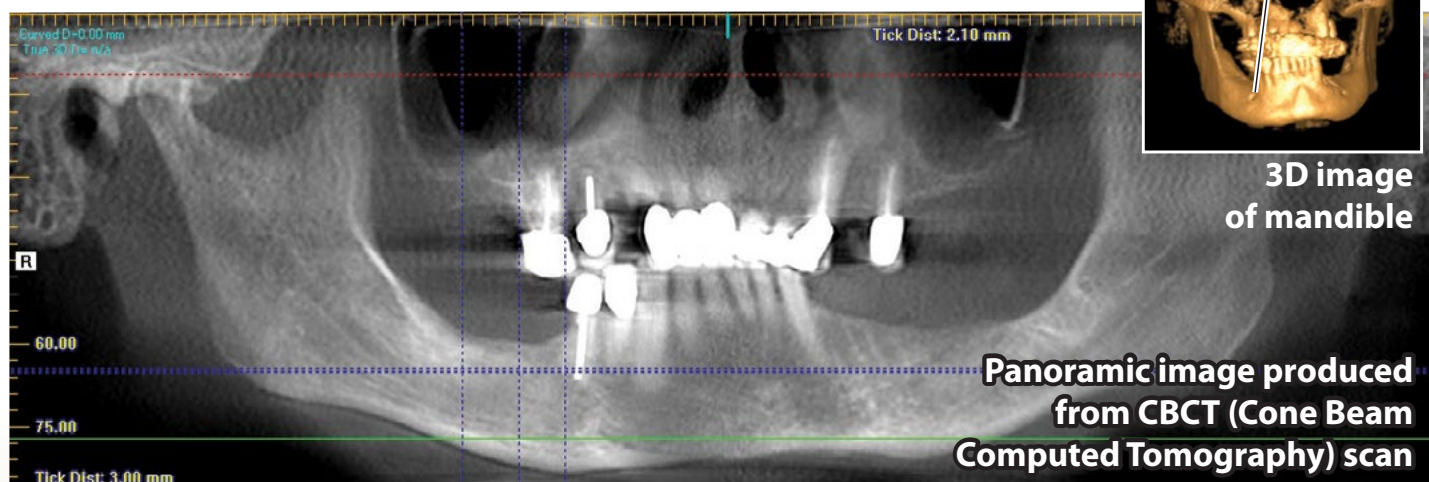


Figure 1 Panoramic image produced by a cone beam computed tomography scan to facilitate pre-surgical planning. The image shows the maxillary sinuses, the nasal cavity, the maxilla and the mandible. The mandibular canal can be seen as a thin gray line progressing along the mandible on the left side of the image.

continued on next page

When the osseointegration of the bone/titanium interface is judged to be complete and the implant is able to withstand the forces of mastication, the oral surgeon will add an abutment or extension to the implanted post that will serve as the site of attachment for the artificial tooth or crown. From start to finish the process may take from four to nine months with much of the intervening time being devoted to the healing process. Once in place, dental implants can be used to replace single teeth or to anchor a removable prosthesis that may replace several teeth (Mayo 2015, Moriconi 2015).

Anatomical Landmarks of the Mandible:

The anterior mandible has historically been considered a fairly safe place for surgery but recent developments in dentistry have lead several investigators to take a closer look at the area (Mraiwa *et al.* 2003). The growing popularity of dental implants has caused the number of surgical procedures in the mandible to increase significantly and now that the mandibular structures can be visualized with modern imaging techniques, the anatomical complexity of the mandible may be more readily observed and characterized. It may reasonably be expected that as dental implants become more common and clinicians accept more complex cases, the number of complications and problems with dental implant surgery may increase (Juodzbalys 2011). The best way to mediate the potential difficulties associated with more clinicians performing dental implant surgery is to clarify and categorize the anatomy of the mandible as precisely as possible. The anatomical landmarks that are most closely associated with dental implant surgery include the mandibular foramen, the inferior alveolar nerve, the mental foramina (Figure 2), the mental nerve, the lingual nerve and the incisive canal and its associated neurovascular bundle (Mraiwa 2003).

Inferior Alveolar Nerve

The mandibular nerve is the third and most inferior division of the trigeminal nerve. From its entrance into the mandible via the mandibular foramen until its exit from the mental foramen, this nerve is known as the inferior alveolar nerve (IAN). The inferior alveolar nerve

bifurcates in the molar region of the mandibular canal to form the mental nerve and the incisive nerve. The mental nerve exits the mental foramen and gives off three small branches. One of the branches innervates the skin of the chin and the other two innervate the lower lip, the gingiva and the mucous membrane as far posterior as the second premolar. The incisive nerve innervates the teeth anterior to the mental foramen: the incisors, canines and the first premolars (Juodzbalys 2011). Recent studies have confirmed the existence of an incisive canal located medial to the mental foramen, which is believed to be a continuation of the mandibular canal. The incisive canal is not usually well defined on radiological studies and its neurovascular bundle may meander through large intra-trabecular spaces in the anterior tip of the mandible (Greenstein and Tarnow 2006).

The mandibular canal bifurcates in about 1% of people in either the longitudinal or transverse plane (Juodzbalys *et al.* 2010). The presence of a bifurcated mandibular canal is associated with the presence of more than one mental foramen. The additional mental foramina may be either unilateral or bilateral (Greenstein and Tarnow 2006). The mental foramen is usually located at the apex of the second mandibular premolar but it may also be found positioned between

the premolars. Minor variations from either pattern are possible and may be related to ancestry (Greenstein and Tarnow 2006).

Within the mandibular canal, the inferior alveolar nerve is accompanied by the inferior alveolar artery and several small inferior alveolar veins along with their associated lymphatic vessels. Together these entities constitute the inferior alveolar neurovascular bundle. The inferior alveolar neurovascular bundle is in close contact

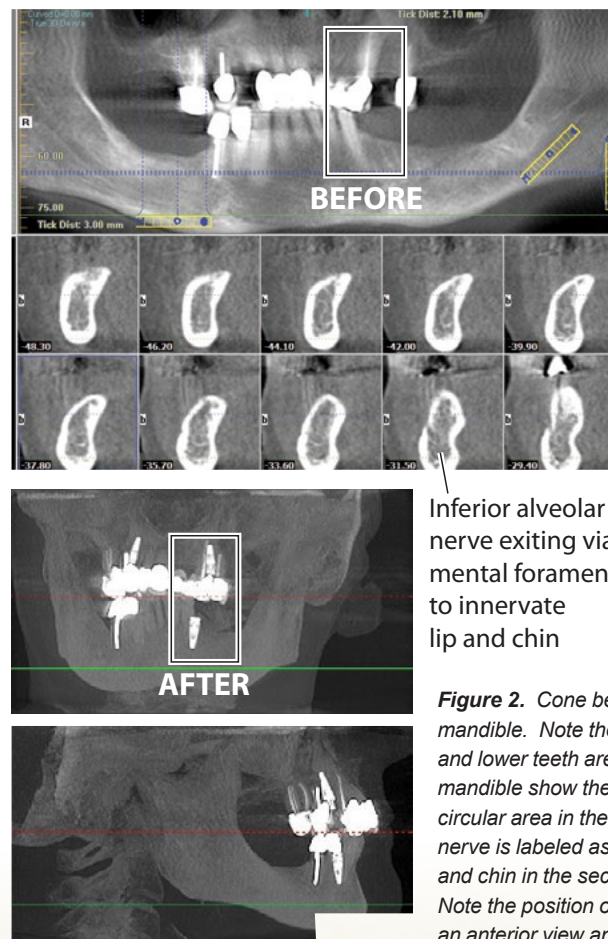


Figure 2. Cone beam computed tomography of maxilla and mandible. Note the empty space in “before” photo where upper and lower teeth are missing. Ten serial sections through the mandible show the location of the mandibular canal as a dark circular area in the lower third of each section. The inferior alveolar nerve is labeled as it exits the mental foramen to innervate the lip and chin in the second serial section from the right, bottom row. Note the position of the implant posts in the “after” photo, seen in an anterior view and a lateral view. The 3-D image of the maxilla and mandible and the other images can be rotated and manipulated using CBCT software.

continued on next page

with, or in close proximity to, the lingual mandibular cortex throughout its length. The pattern of nerve distribution from the inferior alveolar nerve varies from person to person. The most common pattern of nerve distribution, seen in approximately 66% of cases, is a single structural nerve entity that gives off branches to individual teeth of the mandible. However, the inferior alveolar nerve may also give off a plexus or plexuses prior to giving off branches to individual teeth and the specific geometry of the plexuses may vary (Juodzbaly *et al.* 2010).

In about 50% of cases the inferior alveolar neurovascular bundle is found low enough in the anterior mandible to leave sufficient alveolar height to accommodate an implant osteotomy (Juodzbaly *et al.* 2010). In the case of alveolar atrophy, however, the alveolar ridge may sink to become repositioned closer to the inferior alveolar nerve. In approximately 48% of cases, the inferior alveolar nerve is positioned high in the mandible where it may be an impediment to implant osteotomy. In some cases, transposition of the inferior alveolar nerve may be done in order to obtain a viable dental implant site (Juodzbaly *et al.* 2010). Some investigators have reported good results with nerve transposition while others have reported a significant number of postoperative sensory problems with this procedure (Greenstein and Tarnow 2006).

There are several other variations in the nerve and vascular tissues of the mandible that are considered to be normal variations. In approximately 70% of cases the mandibular canal, and the inferior alveolar neurovascular bundle within, traverse the mandible in an "S" shaped curve from the lingual side of the mandible in the molar region to the buccal surface of the mandible anteriorly. Another possible anatomical variation concerns the presence or absence of an anterior loop of the inferior alveolar nerve, which is currently a subject for debate. Those who have documented its existence have described the anterior loop as an extension of the inferior alveolar nerve anteriorly for 3-7mm before it doubles back to exit the mental foramen (Greenstein and Tarnow 2006, Mraiwa *et al.* 2003, Rosenquist 1996). In an area already crowded with anatomical details, the possible existence of an anterior loop of the inferior alveolar nerve may add yet another potential anatomical obstacle to successful dental implant surgery. Any of these anatomical variations may be affected by a person's age, gender and degree of bone atrophy. For all of these reasons, the precise anatomical location of the inferior alveolar nerve, the distribution of nerves from its neurovascular bundle and the variations of related anatomical structures are all of particular interest to clinicians who are planning dental implant surgery (Juodzbaly *et al.* 2010).

Injury to the Inferior Alveolar Nerve

The inferior alveolar nerve is the nerve most commonly injured (64.4%) during dental implant surgery. The next most commonly injured nerve is the lingual nerve (28.8%), which branches off the mental nerve to innervate the tongue. Most injuries to the inferior alveolar nerve are iatrogenic. Such injuries can affect the patient's quality of life and the fact that the source of the injury remains unexplained may add to the psychological problems patients experience following nerve injury (Juodabaly *et al.* 2011). Nerve injuries that occur during dental implant surgery fall into two basic categories, intraoperative injuries that occur during surgery and postoperative injuries that occur after surgery. Intraoperative injuries may be the result of thermal, chemical or mechanical events. Postoperative injuries are usually related to scaring and ischemia associated with infection, localized hematoma or the residual effect of thermal injury (Juodabaly *et al.* 2011).

The inferior alveolar nerve can sustain thermal injury due to the presence of excess heat generated by drilling into bone. Excessively high drill speed, and the heat it generates, results in osteocyte destruction, osteoclast proliferation and generalized tissue necrosis. Bone necrosis is most likely to occur when the heat generated by drilling exceeds a maximum temperature of 47 °C. The temperature parameter for thermal injury has been set at this level because subjecting bone to temperatures of 47 °C for five minutes results in the resorption of 20% of the bone mass (Juodabaly *et al.* 2011). The extent of tissue necrosis is proportional to the amount of excess heat that was generated by the drilling process. To avoid thermal injury to the inferior alveolar nerve, the implant site must be properly irrigated to facilitate cooling of the site and drill speeds must be constantly monitored (Juodzbaly *et al.* 2011).

Chemical injury to the inferior alveolar nerve may be related to injection of local anesthesia directly into the nerve fascicles or the release of anesthesia inside of the nerve as the injection needle is being withdrawn. The type of local anesthesia that is administered, the concentration of the anesthesia and the buffers and preservatives associated with the anesthesia can also contribute to nerve injury. For example, a 4% solution of prilocaine or articaine is more likely to injure the nerve than a comparable solution of lidocaine since lidocaine is judged to be the least irritating of the local anesthesia options (Juodzbaly *et al.* 2011). The possible manifestations of chemical trauma to nerve tissue include demyelination of the nerve fiber, degeneration of the axon and inflammation of the nerve fibers inside of the fascicles (Juodzbaly *et al.* 2011). If all goes well, however, the effectiveness of local anesthesia use for pain control and pain management far outweighs the possible adverse events that are associated with its usage.

continued on next page

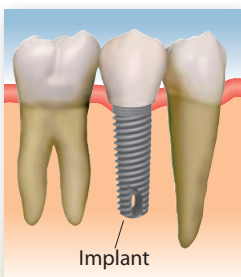
Intraoperative mechanical injuries are most frequently the result of damage done by the needle tip during the injection of local anesthesia, over-penetration of the drill tip into the mandibular canal, improper positioning of the titanium implant, bone debris that end up in the surgical wound, or the formation of a hematoma in the mandibular canal secondary to implant placement, scalpel use or retractor pressure against the adjacent soft tissue (Juodabalys *et al.* 2011).

Injury to the inferior alveolar nerve may result in localized tissue anesthesia, a complete loss of feeling in the affected area; parathesia, a feeling of numbness; dyesthesia, a sensation of pain; or hyperesthesia, increased sensitivity in the affected area. Most of these altered sensations are transient and will run their course in six months or less. Injury to the inferior alveolar nerve may affect many everyday activities that involve the use of the mouth such as eating, drinking, speaking, kissing, shaving and the application of cosmetics (Greenstein and Tarnow 2006).

Accessory Foramina

The term accessory foramen applies to all of the openings in the human mandible except the mandibular foramen and the mental foramen. Accessory foramina are located almost exclusively along the posterior surface of the anterior mandible and 96% of all adult human mandibles have at least one of them. The location, size and frequency of accessory foramina vary from person to person but most are structures of the midline, located close to or within the genial tubercle, the area of the four mental spines. In this region, the landmarks are the two superior mental spines, which serve as the origin of the genioglossus muscle, and the two inferior mental spines, which serve as the origin of the geniohyoid muscle (Przystanska and Bruska 2012).

In a study undertaken by Przystanska and Bruska in 2012, 397 mandibles were macroscopically investigated. A total of 700 accessory foramina were documented whose frequency ranged from zero in twelve of the mandibles, to seven in two of the mandibles (Przystanska and Bruska 2012). If the accessory foramina are associated with microvasculature and nerves, which is highly likely, injury to any of them may have an effect on sensory perception or cause excessive bleeding at the implant site.



Dental implant when complete, showing the titanium post in the alveolar process and the crown positioned above the gum line.

Illustration by Kelly Paralis, Penumbra Design, Inc.

Implant Failures

Implant failures may be classified as biological, mechanical or iatrogenic. Of these, the most problematic are biological failures, which are defined as the inability of the recipient's system to establish osseointegration with the titanium post. In this case, scar tissue and fibrous tissue have grown between the implant post and the adjacent alveolar bone preventing the stable union of the two. This is most likely the result of bacterial contamination at the implant site or excessive trauma imposed during the surgery (Geckili *et al.* 2013).

Mechanical implant failure refers to the inability of the implant to withstand the biomechanical forces of mastication. It may involve the failure of any of the prefabricated implant components that are embedded in the alveolar process or failure of the laboratory produced tooth replacements that are positioned above the gum line (Salvi and Bragger 2009).

There is a statistically significant higher rate of failure for implants in the anterior maxillary region compared to those in the anterior mandible or the posterior maxillae. The amount of alveolar bone available in the maxillae is restricted by the presence of the maxillary sinus and to compensate for this, shorter implant posts are often used in this area. Shorter implant posts may have an adverse effect on the success of the implant by affecting its ability to withstand biomechanical force. Since the anterior mandible is an aesthetic region of the mouth (Figure 3), advanced surgical skill may be required to properly position implants in this more challenging environment (Geckili *et al.* 2013).

The likelihood of implant success is higher in the space between the mental foramina of the anterior mandible compared to all other regions. Success in this area is judged to be between 90-100% irrespective of the type of implant used, the specific topography of the bone or the overall design of the prosthesis (Geckili *et al.* 2013).

Age and gender are not known to have an influence on the likelihood of implant success or failure (Geckili *et al.* 2013).

Implant length and width

Dental implants are available in many different lengths to accommodate a wide range of implant sites. They can vary from 6mm to 20mm in length but most commonly, the lengths range from 10mm to 16mm. Ten millimeters is considered to be the minimal length for predictable success. Dental implants under 10mm in length are classified as short and may be inserted in situations where the most desirable amount of bone mass is lacking. Lack of optimal bone quality may have an effect on the stability of the implant and this may influence implant failure. Several clinical trials have documented increased failure rates with the placement of shorter implants (Geckili *et al.* 2013).

continued on next page

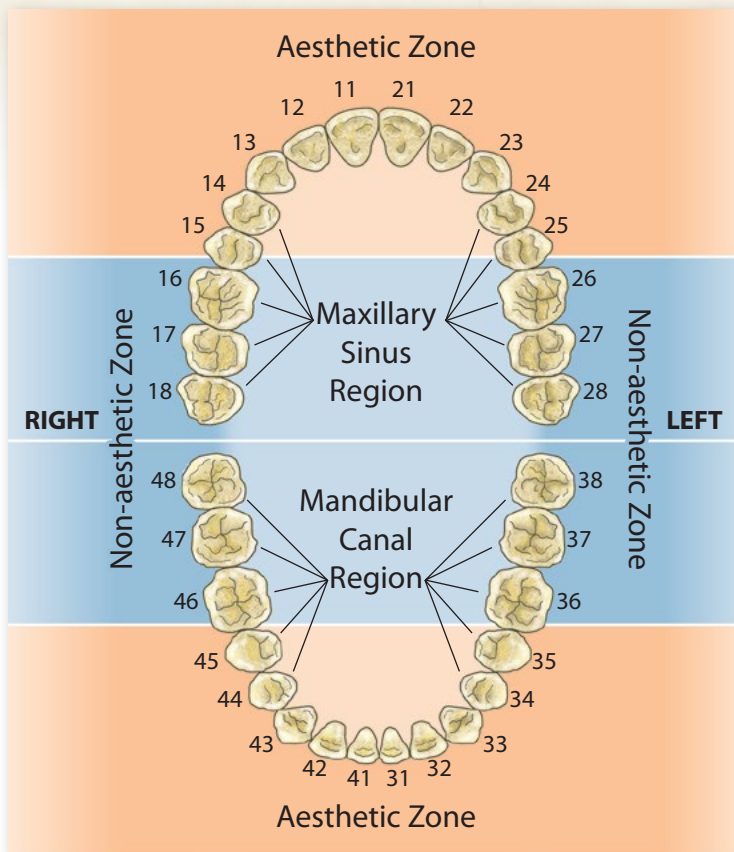


Figure 3. The aesthetic zone includes the anterior maxilla and mandible, which comprises a more challenging environment for proper placement of implants, especially with respect to the observable gum line/tooth crown interface. The location of the maxillary sinuses must be considered in positioning implants in the maxilla and the position of the mandibular canal must be considered in positioning implants in the mandible.

Illustration by Kelly Paralis adapted from Juodzbalys and Kubilius, 2013.

The most common implant widths range from 3.75mm to 5mm. A width less than 3.75mm is considered to be narrow and a width of more than 5mm is wide. Increasing the implant diameter proportionally increases its surface area, resulting in more resistance to the forces of mastication. Implant diameter is not known to affect the success or failure of the implant. The experience and skill of the implant surgeon is the variable that is most related to implant success. (Geckili *et al.* 2013).

Conclusion

The anatomical landmarks of the mandible associated with dental implant surgery, especially the precise location of the inferior alveolar nerve and the structures associated with it, vary from person to person and can be found in different locations in the mandible relative to a person's age, gender, degree of alveolar bone atrophy, and general health. The outcome of dental implant surgery depends on the skill of the surgeon, proper identification of the appropriate landmarks using state-of-the-art imaging, satisfactory osseointegration at the bone/implant post interface, and the quality of the compact and

alveolar bone of the mandible. Successful dental implant surgery can ensure that the aesthetics of the facial contours will be maintained and provide a functional replacement for teeth lost to age, injury or disease that can be expected to last for many years.

CBCT scans courtesy of E. Steven Moriconi, DMD. Oral and Maxillofacial Surgery. Chief, Dental Division, Abington Memorial Hospital. 609 Harper Avenue, Jenkintown, PA 19046.

Illustrations courtesy of Kelly Paralis, Owner, Penumbra Design, Inc.- Studio: 143 North Sylvania Avenue, First Floor, Rockledge, PA 19046
kelly@penumbradesigninc.com tel- 215.379.2832

Literature cited

- Branemark, Per-Ingvar (1983). Osseointegration and its experimental background. *The Journal of Prosthetic Dentistry*. 50(3): 399-409.
- Geckili, Onur, Hakan Bilhan, Esmâ Geckili, Emre Mumcu and Canan Burai. (2013). Evaluation of possible prognostic factors for the success, survival, and failure of dental implants. *Implant Dentistry*. 23(1) 44-50.
- Goldman, Maxim, Gintaras Juodzbalys and Valdas Vilkinis. (2014). Titanium surfaces with nanostructure influence on osteoblasts proliferation: a systematic review. *J Oral Maxillofac Res* 2014;5(3):e1
 URL: <http://www.ejomr.org/JOMR/archives/2014/3/e1/v5n3e1ht.pdf>
 doi: 10.5037/jomr.2014.5301
- Greenstein, Gary and Dennis Tarnow. (2006). The mental foramen and nerve: clinical and anatomical factors related to dental implant placement: A literature review. *J Periodontol*.77(12):1933-1943.
- Guler, AU, M Sumer, P Sumer, and I Bicer. (2005). The evaluation of vertical heights of maxillary and mandibular bones and the location of anatomic landmarks in panoramic radiographs of edentulous patients for implant dentistry. *Journal of Oral Rehabilitation*. 32:741-746.
- Mraiwa, Nuri, Rhinilde Jacobs, Daniel van Steenberghe, and Marc Quirynen (2003). Clinical assessment and surgical implications of anatomic challenges in the anterior mandible. *Clinical Implant Dentistry and Related Research*. 5(4): 219-225.

continued on next page

- Juodzbaly, Gintaras and Marius Kubilius (2013). Clinical and radiological classification of the jawbone anatomy in endosseous dental implant treatment.
- J Oral Maxillofac Res 2013 (Apr-Jun): 4(2): e2
URL: <http://www.ejomr.org/JOMR/archives/2013/2/e2/v4n2e2ht.htm>
doi:10.5037/jomr.2013.4202
- Juodzbaly, Gintaras, Hom-Lay Wang and Gintautas Sabalys (2010). Anatomy of mandibular vital structures. Part II: Mandibular incisive canal, mental foramen and associated neurovascular bundles in relation with dental implantology.
- J Oral Maxillofac Res 2010 (Jan-Mar):1(1):e3
URL: <http://www.ejomr.org/JOMR/archives/2010/1/e3/e3ht.pdf>
doi:10.5037/jomr.2010.1103
- Juodzbaly, Gintaras, Hom-Lay Wang and Gintautas Sabalys (2010). Anatomy of mandibular vital structures. Part I: Mandibular canal and inferior alveolar neurovascular bundle in relation with dental implantology. J Oral Maxillofac Res 2010 (Jan-Mar);1(1):e2
URL: <http://www.ejomr.org/JOMR/archives/2010/1/e2/e2ht.pdf>
doi:10.5037/jomr.2010.1102
- Juodzbaly, Gintaras, Hom-Lay Wang and Gintautas Sabalys (2011). Injury of the inferior alveolar nerve during implant placement: a literature review.
- J Oral Maxillofac Res 2011 (Jan-Mar);2(1):e1
URL: <http://www.ejomr.org/JOMR/archives/2011/1/e1/v2n1e1ht.pdf>
doi: 10.5037/jomr.2011.2101
- Lewin, Tamar. (2014) Per-Ingvar Branemark, Dental Innovator, Dies at 85. The New York Times.
URL: http://www.nytimes.com/2014/12/28/health/per-ingvar-branemark-dental-innovator-dies-at-85.html?_r=0
Accessed January 2015.
- Mayo Clinic. (2015). Dental implant surgery.
URL: <http://www.mayoclinic.org/tests-procedures/dental-implant-surgery/basics/what-you-can-expect/PRC-20009052?p=1>
Accessed January 2015.
- Moriconi, Steven E. DMD. Oral and Maxillofacial Surgery, Chief, Dental Division, Abington Memorial Hospital, Private Practice, 609 Harper Avenue, Jenkintown, PA. Personal interview, January 2015.


Palmquist, Anders, Katheryn Grandfield, Brigitta Norlindh, Torsten Mattsson, Rickard Branemark, and Peter Thomsen. (2012). Bone-titanium oxide interface in humans revealed by transmission electron microscopy and electron tomography. J R Soc Interface. 9(67): 396-400.

Przystanska, Agnieszka and Malgorzata Bruska.(2012). Anatomical classification of accessory foramina in human mandibles of adults, infants, and fetuses. Anatomical Science International. 87(3): 141-149.

Rosenquist, B. (1996). Is there an anterior loop of the inferior alveolar nerve? Int J Periodontics Restorative Dent. 16(1):40-45.

Salvi, Giovanni, Urs Bragger (2009). Mechanical and Technical Risks in Implant Therapy. The International Journal of Oral & Maxillofacila Implants. 24:69-83

About the Author



Sarah Cooper is co-editor of the HAPS-EDucator. She has taught human anatomy and general biology at Arcadia University since 1981 and she serves as the pre-nursing adviser and coordinator of the interdisciplinary science program.

Anastomosis: Connecting History and Anatomy Education

Vinson H. Sutlive
Pfeiffer University
PO Box 960
Misenheimer, NC 28109
vinson.sutlive@pfeiffer.edu

Abstract

Giving a historical context to the details of anatomy and physiology can be a useful method of helping some students to integrate and learn what to them seems like overwhelming amount of information. A goal of teaching is to help students master and retain subject material beyond the scheduled exams. As instructors we can create a variety of learning environments – e.g. flipped classrooms, peer-instruction - and we have a wealth of computer-ready and internet-based technology to use. Still, providing a story or the historical context for something is a relatively simple teaching method that piques student interest. History, especially stories that highlight the contributions of individuals, gives students another way to add meaning and significance to their study of anatomy and physiology. This paper uses history – Dr. Robert Gross' first ligation of patent ductus arterioles, Dr. Alfred Blalock, Helen Taussig and Vivien Thomas' Blue-Baby Operation, and Dr. C. Walton Lillehei's first open-heart repair of Tetralogy of Fallot - as a way to teach and reinforce the anatomy and physiology of the heart and circulation. Allowing students to connect a human story to the specific anatomical and physiological information stimulates interest and makes the lessons 'stick'.

Introduction

Recently, the topic of the day in my undergraduate anatomy and physiology course was the endocrine system, specifically the pancreas. I dutifully described the islets of Langerhans, alpha cells, and beta cells. Just to be clever, I asked if anyone remembered another area of the body where we had encountered the name Langerhans? I stood there, 'all-knowing', as students shuffled through class notes to find the answer. At last, one student raised her hand. "In the skin," she said, "There are Langerhans cells in the skin." I feigned astonishment. "Very impressive," I said, "It has been a long time since we covered the integumentary system." I silently congratulated myself for this fine teaching moment, forcing students to recall this anatomical gem. Then, another student raised her hand: "I don't get it. You said they are in the pancreas and the skin. So, what is a Langerhans?"

Almost as quickly as it had come, the shine on my self-described teaching moment disappeared. I realized that I had asked the students to make a connection between two types of cells or tissues that really had nothing in common; at least not in terms of location, structure, or function. The only real link was that the islets in the pancreas and the cells in the skin were both first identified by the German pathologist and physiologist, Paul Langerhans. The student who asked the question was trying

to make a structural or functional link between the two because she did not have any historical context in which make such a connection. The students did not have that historical context because I had not shared it with them.

As instructors, we have at our disposal a variety of instructional paradigms: guided inquiry learning (i.e., POGIL), project-based learning, on-line platforms, peer-instruction and flipped classrooms. We have an array of terrific technologies: computer-based slide presentations, virtual microscopes, virtual cadavers, and video-streaming. We use laboratory activities to give a hands-on dimension to learning hoping that students will see the overlap between the lab and lecture portions of the course. Nevertheless, as students frequently point out to us, there is a lot of material to organize and learn.

Some students will learn the material using a 'brute' force approach, taking detailed notes, reviewing learning objectives and terms, and yes, memorizing. Some students latch onto the clinical examples we use, learning about function from dysfunction. Still others seem especially interested in learning about those systems in which they have some personal experience. For example, a

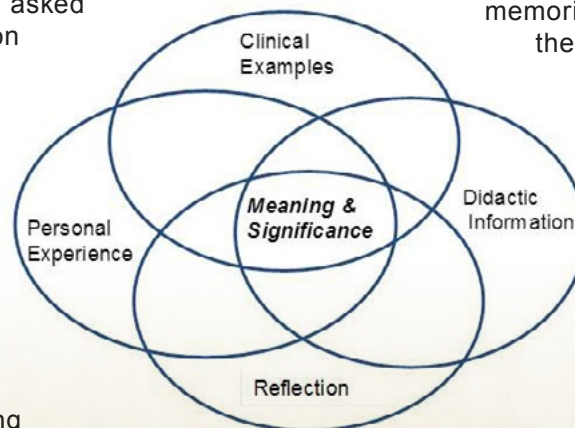


Figure 1. Students attach meaning and significance to information from a variety of contexts.

continued on next page

student with asthma has a personal interest in learning about the respiratory system, or a student with a family member undergoing dialysis treatment may take becomes especially interested in learning about kidney anatomy and physiology.

The model in Figure 1 suggests this combination of effects, some developing from the instructor, some from the learning setting and some from the student's own engagement and experience, brings meaning and significance to the material. Taken individually, each aspect does not necessarily create meaning. Experience alone does not always create meaning; reflection on the experience is required (Loughran 2002). On the other hand, when students personalize information, when they are able to attach meaning and significance to what they learn, they not only do well, but also seem to have a higher level of motivation. Although not shown as part of the model, historical context can also contribute to meaning. It may even spark a student's imagination.

I have observed that what often seems to pique student interest is the inclusion of a story or the historical context for something that must be learned. Preachers use stories (they call them illustrations or parables) to reinforce the information or concepts they wish to convey. I began to notice that when I presented a short historical background along with the requisite anatomical information, students seemed to pay better attention. Later, some students would even ask me about the story, giving me another chance to also reinforce the anatomical information.

In my undergraduate anatomy and physiology course, I include a short unit on development. It is not possible to cover the development of all body systems. I use the circulatory system as an example. This includes fetal circulation and the changes that occur shortly after birth. I also include the principle that we can learn about function from dysfunction, and offer clinical examples of congenital anomalies in the circulatory system. And here I try to add some historical reference that can also be used to reinforce learning the anatomy and physiology of circulation. There is a rich history, including the work of Harvey. However, the history I include comes from the relatively recent history of cardiovascular surgery and the repair of several developmental anomalies.

What follows is a brief version of how I attempt to combine the two teaching elements – history and anatomy – in an attempt to create a frame of reference that goes beyond the usual details of anatomy and physiology. Simply connecting a person's name to a topic seems to give students another means of retaining information. Not all students find this helpful, or even interesting, but I have received sufficient positive feedback to continue incorporating history into a number of my anatomy lessons.

Part I: Dr. Gross and Ligation of patent ductus arteriosus

Less than a hundred years ago, most physicians still held that cardiovascular problems could not be cured - only managed. Intervening surgically to correct a problem was not considered possible. That changed in 1938 when Dr. Robert Gross, M.D., a surgeon at Harvard Medical School, described the first surgical correction of patent ductus arteriosus (Gross & Hubbard 1939). Of course, to understand patent ductus arteriosus (PDA) requires a review of the structure of the normal ductus arteriosus, its function in fetal circulation, and the typical transition in the first few days after birth from the ductus arteriosus to the ligamentum arteriosum (Marieb *et al.* 2014). In the case of PDA, the ductus does not close, allowing oxygenated blood in the aorta to mix with deoxygenated blood in the pulmonary artery. This obviously decreases total oxygen in the peripheral circulation, leaving the child with a variety of symptoms including rapid heart rate and early-onset of fatigue from activity. Dr. Gross developed a technique called ligation of PDA, whereby he sutured the open ductus shut. What today seems like a simple solution was a significant step in the history of cardiovascular surgery.

In roughly the same amount of time it takes to describe this aspect of function and dysfunction in fetal circulation, one can add a historical context for the same information. Although my evidence is only anecdotal, students seem to retain better the anatomical and physiological details of the lesson when it is framed historically. They recall details of the story – anatomy and all. During subsequent review sessions, students can recall who Dr. Gross was, what the ductus arteriosus is, ligation of PDA, and why it is necessary.

Part II: The Blalock-Taussig Shunt

I continue the brief history of developments in cardiovascular surgery as a way of reinforcing anatomy instruction by describing the development of the Blalock-Taussig shunt. While Dr. Gross was developing his surgical correction to PDA, another physician was searching for a solution to a more serious congenital heart problem. Dr. Helen Taussig was Chief of Pediatric Cardiology at Johns Hopkins University Medical School, Baltimore. She was particularly interested in a group of young patients with Tetralogy of Fallot (TOF). Etienne Fallot gave a detailed description of the condition in 1888, hence the condition bears his name, but accounts of TOF date back to 1671 (Apitz *et al.* 2009). Patients with TOF have four simultaneous congenital heart defects: stenosis of the pulmonary valve, hypertrophy of the right ventricle, ventricular septal defect, and a rightward shift of the aorta. These patients were prone to 'spells' of hyper-cyanosis. They were also called 'Blue Babies' (Thomas 1985).

Despite being almost deaf, Dr. Tausig was an excellent diagnostician who could evaluate these complex heart

continued on next page

anomalies with a special stethoscope and her hands (Baldwin 1992, Thomas 1985). Dr. Taussig recognized that TOF patients, who also had PDA, seemed to do better. This seemed counter-intuitive but she concluded that, despite the additional problem of PDA, these patients were able to get slightly more blood to the lungs for oxygenation. Dr. Taussig conceived the idea of a surgical shunt, redirecting an artery in the systemic circulation and connecting it to the pulmonary artery, thereby increasing blood flow to the lungs (Evans 2009). Dr. Taussig originally took her idea to Dr. Gross, but he was involved in other research and declined the offer to develop the shunt. (Baldwin 1992).

Dr. Taussig then turned to Dr. Alfred Blalock, the new Chief of Surgery at Johns Hopkins Medical School. Blalock accepted the challenge and began to develop the surgical procedure with his technician, Vivien Thomas. Thomas was a thoroughly remarkable individual. He had gone to work in Blalock's lab at at Vanderbilt University when he nineteen (I point out that this is the age of some in the present class). His highest level of formal education was high school and yet he ran all of Blalock's research experiments, including the surgical experiments that led to the Blalock-Taussig shunt (Kennedy 2005, Timmermans, 2003).

In November 1944, with Vivien Thomas observing over his right shoulder, Dr. Blalock performed the first Blalock-Taussig shunt on a small girl named Eileen Saxon. (Here, as an aside, I tell students that confidentiality requirements were very different in the 1940's. Publishing patient's names or at least their initials, was not uncommon). Blalock, with help from Thomas, transected the left subclavian artery, deflected it down and performed an anastomosis with the pulmonary artery. This successfully increased the supply of blood to the lungs (Blalock and Tausig 1945). The surgery was highly successful and brought relief to thousands of children with TOF. A remarkable case study was reported in 2011. This study described a 63-year old woman who was evaluated by a cardiologist for heart function. The cardiologist discovered that the patient had undergone the Blalock-Taussig procedure at the age of three - in 1948 (Scholtz *et al.* 2011).

From a teaching standpoint, the purpose of this historical information is to reinforce the anatomy and physiology of cardio-pulmonary circulation, and some aspects of its development. To understand the problems with TOF, students must understand normal heart anatomy. In order to understand the benefit from the Blalock-Taussig shunt, students must understand normal pulmonary circulation. It is my experience that students are often taken by the social implications of this story: a white male surgeon, a female pediatric cardiologist, and a black surgical technician gathered around a table in the operating room, but they were unable to eat a meal with each other in the hospital cafeteria. Being able to tell the story seems to invigorate the anatomy and physiology lesson.

Part III. The First Open-Heart Repair of Tetralogy of Fallot

The third and last phase of the history lesson is about the development of open-heart repair of TOF. Both Dr. Gross' surgical ligation of PDA and the Blalock-Taussig shunt involved the vessels around the heart, but not actual surgery on the organ itself. There was still a reticence with regard to actually operating on the heart. That changed after 1945, when a generation of surgeons returned from World War II. One of these physicians was Dr. C. Walton Lillehei. Like many of his contemporaries, Lillehei had performed surgeries on casualties, including men with wounds that involved the heart. He had operated on men whose hearts had been injured by stabbings, bullets and shrapnel. Many of these men survived direct wounds to the heart. Lillehei was convinced that the heart was a robust organ and open-heart surgery was possible (Miller 2000).

The challenge was finding a way to temporarily stop blood flow to and within the heart long enough to give the surgeon time to make a repair, yet also find a way to supply blood to the rest of the body. Hypothermia was used, but it allowed only about ten minutes of opportunity. In the absence of a working heart-lung machine, Lillehei conceived a method of oxygenating a patient's blood using a donor. The technique was called cross-circulation (Miller 2000, Stoney 2009). The technique involved clamping the patient's superior and inferior vena cava shut so that no blood would enter the heart. "Blood flow was routed from the patient's caval system to the [donor's] femoral vein and lungs, where it was oxygenated and then returned to the patient's carotid artery" (Cooley 1999).

The first successful use of cross-circulation was reported in March 1954. Although the surgery was successful, the patient died from complications. In July 1954, Lillehei performed the first repair of TOF using cross-circulation. The patient's name was Mike Shaw, a ten-year-old boy. The donor was a volunteer who was not a relative of the patient. Lillehei performed 48 surgeries using cross-circulation; 28 patients survived (Miller 2000). Cross-circulation had its limitations. It was inherently dangerous, putting at risk two individuals: the patient and one presumably healthy donor. It could only be used with children. The flow of blood from the donor, even with an auxiliary pump, was not sufficient to support an adult undergoing surgery. Lillehei only used the technique until 1955, when he and his colleague, Dr. Richard DeWall developed the first clinically successful 'bubble oxygenator' that could be used in surgery (Stoney 2009).

Discussion

Recently, I have attempted to include a historical context to some of the lessons I teach in my undergraduate anatomy and physiology course. On the whole, student response has been positive. Often

continued on next page

their questions focus on the history, the people involved, or perhaps on a specific condition. However, these questions nearly always present an opportunity to reinforce the anatomical and physiological aspects of the story. There exists an overlap in learning between the historical context and necessary anatomical information (Figure 2). One observation is the number of students who identify with one or more of the historical individuals. Female students tend to relate to Dr. Helen Taussig; other students identify strongly with Vivien Thomas, who accomplished much despite not having the opportunity to become a physician himself; still others identify with Dr. Lillehei, a maverick of sorts who is now recognized as the ‘father of open-heart surgery’.

Including short history lessons gives students another reason to learn anatomy and physiology. Rather than the seemingly endless stream of structures with Greek and Latin names, the lessons provide a kind of personality to the information. It is also another step toward adding meaning to what they learn; another way to make the information stick. Although purely anecdotal, I have seen an increase in the attention to and persistence in learning those lessons, labs and units when a historical context is provided. Learning how the Golgi apparatus of a cell and the Golgi tendon organ are related can be interesting, even if that connection is simply the name of anatomist Camillo Golgi. Of course, this is not intended as way of letting students off the hook. They still must learn the vocabulary, cells, tissues, chemistry, and organ systems inherent to an undergraduate course in anatomy and physiology. And, just to make that point, I like to remind my students that Paul Langerhans was an undergraduate – just like them - when he first described the Langerhans cells of the epidermis, and he was only 22 years old when he wrote his thesis on the islets of Langerhans (Jolles 2002).

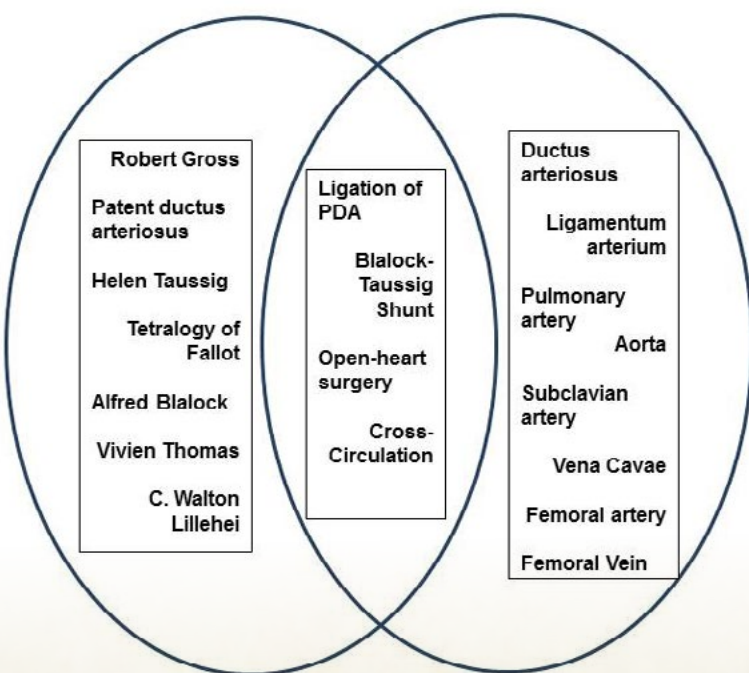


Figure 2. Overlap between the historical context and anatomical information

Literature Cited

- Apitz, C., Webb, G.D. & Redington, A.N. (2009). Tetralogy of Fallot. *Lancet*. 374(14): 1462-1471.
- Blalock, A. & Taussig, H. B. (1945). The surgical treatment of malformations of the heart in which there is pulmonary stenosis or pulmonary atresia. *Journal of the American Medical Association*. 128(3): 189-202.
- Blue Baby Operation Exhibit. Available at: <http://medicalarchives.jhmi.edu>. Accessed March 10, 2015.
- Cooley, D. (1999). In memorium: C.Walton Lillehei, the “Father of Open-Heart Surgery”. *Circulation*. 100: 1364-1365.
- Evans, W. N. (2009). The Blalock-Taussig shunt: the social history of an eponym. *Cardiology In The Young*. 19(2): 119-128.
- Gross, R. E. and Hubbard, J. P. (1939). Surgical ligation of patent ductus arteriosus: Report of first successful case. *Journal of the American Medical Association*, 112 (8): 729-731.
- Jolles, S. (2002). Paul Langerhans. *Journal of Clinical Pathology*. 55(4): 243.
- Kennedy, D. M. (2005). In Search of Vivien Thomas. *Texas Heart Institute Journal*, 32(4): 477-478.
- Loughran, J. J. (2002). Effective reflective practice: In search of meaning about teaching. *Journal of Teacher Education*. 53(1): 33-43.
- Marieb, E.N., Wilhelm, P.B., & Mallat, J. (2014). *Human anatomy*. Boston: Pearson.
- Miller, G.W. (2000). *King of Hearts, The true story of the maverick who pioneered the open heart surgery*. New York: Crown Publishers.
- Scholtz, W., Jategaonakar, S.R, Dimitriadis, Z., Haas, N.A., & Horstekotte, D. (2011). 63-year survival after Blalock-Taussig shunt operation in patient with single ventricle, tricuspid atresia, and pulmonary stenosis. *Congenital Heart Disease*. 6:179-182.
- Stoney, W. S. (2009). Historical perspective in cardiology: Evolution of cardiopulmonary bypass. *Circulation*. 119: 2844-2853.
- Baldwin, J. (1992). *To Heal the Heart of a Child: Helen Taussig*, M.D. Walker & Company.
- Thomas, V. (1985). *Pioneering research in surgical shock and cardiovascular surgery: Vivien Thomas and his work with Alfred Blalock: An autobiography*. Philadelphia: University of Pennsylvania Press.
- Timmermans, S. (2003). A black technician and blue babies. *Social Studies in Science*. 33(2), 197-229.

About the Author

Vinson H. Sutlive, Ph.D, is Professor and Chair of the Department of Health & Exercise Science at Pfeiffer University.



Identification of Unknown Mammalian Quadruped Bones by Histological Techniques And Bone Morphology

Jennifer Wood, PhD
University of Maryland
University College (UMUC)
Jennifer.wood@faculty.UMUC.edu

Olena Prikhodko
Arcadia University
Glenside, PA 19038
okostyshack@arcadia.edu

Sarah Cooper
Biology Department
Arcadia University
coopers@arcadia.edu

Abstract

Skeletal and dental remains are the end products of all mammalian species after death and decomposition. The remains have significant importance to forensic anthropologists and osteologists in providing them with the evidence needed to determine the species, gender, age and cause of death of skeletal remains. This article describes the techniques and methods that are most commonly used to evaluate skeletal remains and applies those techniques to the skeletal remains of an unknown mammalian quadruped that was found in Manassas, Virginia in 2014. Using these techniques, the remains were successfully identified as those of a juvenile red fox, *Vulpes vulpes*.

In addition to identifying skeletal remains that are clearly human, forensic anthropologists are frequently called upon to separate human skeletal remains from non-human remains. Sometimes the remains are fragmented or badly damaged by natural or man-made disaster and they may include comingled bone fragments from humans and non-humans. When bone fragments are small, comingled and not accompanied by animal pelts or intact skull remains, species identification can be problematic. Increasingly, forensic anthropologists are turning to histological analysis as an aid to species identification in situations when standard identification techniques cannot be used.

The diagenetic altering of bone is the tendency of bone to change in response to the changing external and internal postmortem environment. This process is well understood (Hillier and Bell 2007). Change is initially triggered when bone is subjected to bacterial invasion as bacteria from the digestive system move along vasculature channels to other body organs. The presence of digestive bacteria in bone disrupts the microstructure of the bone and these changes can be seen during histological assessment. Exposure to marine environments introduces a variety of microorganisms that are not observed in bone that is found in a terrestrial environment, while diatoms and other unique microorganisms may populate bone exposed to a fresh water environment. Heating bone causes the mineral content to melt and recrystallize, which causes Haversian canals to shrink and blurs the formative lines of individual lamellae.

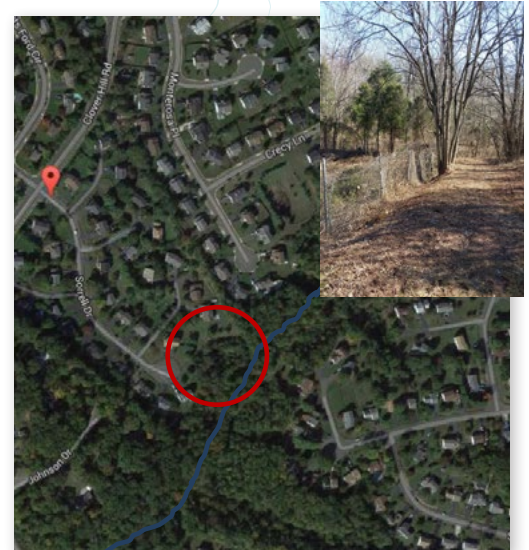


Freezing bone, however, has no apparent effect on its microscopic structure (Byers 2008, Hillier and Bell 2007).

The realization that specific types of changes in the microstructure of bone could be useful in identifying the place of death, or the place where a body was taken after death, lead forensic investigators to hypothesize that bone histology might be useful in species identification of fragmented bone material.

Histological considerations for species identification

There is limited research on the microstructure of non-human mammalian bone but a few representative species have been investigated. A histological study of dog bone, for example, has revealed that the compact bone of the ribs and long bones of adult animals is composed of dense Haversian systems that are small in comparison to human Haversian systems and more variable in shape. The periosteal surface has remnants of plexiform bone; a type of bone tissue that is rarely seen in humans and primates and frequently seen in large mammals that grow quickly such as dogs, cows and pigs. Plexiform bone is characterized by the presence of large vascular plexuses in a lamellar bone configuration. The resulting bone is arranged in



Area near Manassas, Virginia where fox skeleton was found. A small stream runs behind the evergreens to the left in the photo.

distinctive symmetrical blocks resembling the repetitive patterning of a brick wall (Hillier and Bell 2007).

The compact bone of domestic cats is also composed of dense Haversian systems. The Haversian canals in cat bone are very small and Volkman's canals are much more numerous compared to human bone or other cat-sized small mammals. Circumferential lamellae are usually present in a thin layer at the periosteal surface of the bone and a thicker, more organized layer of circumferential bone is typically found at the endosteal surface (Hillier and Bell 2007).

The compact bone of deer contains both plexiform and Haversian bone tissue. In immature deer, plexiform bone is concentrated near the periosteal surface while Haversian bone forms along the endosteal surface. The long bones of adult deer are composed primarily of dense Haversian systems that have replaced plexiform bone. Through out the body, a thin layer of circumferential lamellar bone covers the periosteal bone surface. In fetal and newborn animals, the compact bone of the long bones consists primarily of plexiform and reticular tissue with scattered avascular areas and acellular bone regions (Hillier and Bell 2007).

Organized Haversian systems are rare in the long bone of common brown rats and when present, they tend to be scattered near the endosteal surface. The compact bone of long bones is composed primarily of longitudinal bone tissue containing scattered areas of small avascular and acellular bone material (Hillier and Bell 2007).

A survey of just a few of these relatively common representative animals; dog, cat, deer and rat, gives evidence that it might be possible to assess species based on species specific Haversian and non-Haversian bone patterns. Unfortunately, prepared slides of non-human bone material are not yet readily available on the commercial market and individual schools may not have the equipment necessary to make histological slides of representative animal bone.

Macroscopic considerations for species identification

The best and easiest way to identify an animal is with an intact pelt (Travini *et al.* 2000). In the absence of an intact pelt or histological preparations of representative bone, or in addition to these if they are available, non-human bone can be distinguished from human bone on the basis of bone morphology if the bones are relatively intact. The pelvic bones of humans are broad and shallow and can be easily distinguished from the long,

Bones	Missing?	Missing Description	Fracture	Fracture Type
Cranium	N		N	
Vertebrae				
Cervical	Y	6/7 missing. C7 present	N	
Thoracic	N	13/13present	N	
Lumbar	N	7/7present	N	
Sacrum	N	3/3present	N	
Coccygeal	N	15/15present	N	
Ribs				
R1	N		N	
R2	Y. Left		N	
R3	Y. Left		N	
R4	Y. Left		Y. Right	slight greenstick
R5	Y. Both		N	
R6	Y. Both		N	
R7	Y. Right		Y. Left	Transverse, Full
R8	Y. Right		Y. Left	Oblique, 1/2 through bone
R9	Y. Right		Y. Left	Transverse, 1/2 through
R10	N		Y. Both	L: Transverse, 1/2 though R: Transverse, Full
R11	N		Y. Both	L: Transverse, 1/2 though R: Transverse, Full
R12	N		Y. Right	Transverse, Full
R13	N		N	
Sternal Bones	Y	6/6missing		
Scapula	Y. Right		Y. Left	2 greenstick
Pelvis	Y			
Legs- Front				
Humerous	N			
Radius	N			
Ulna	N			
Legs- Back				
Femur	Y			
Tibia	Y			
Fibula	Y			

narrow pelvic bones of non-human quadrupeds. The human femur is the longest bone in the body and it has only one linea aspera. In quadrupeds, the femur is short in relation to the overall body size. If an unknown femur appears to be approximately the same length as an adult human femur, a non-human bone may be twice the thickness of the human bone and it is likely to have a double or plateau formed linea aspera. The tibia and fibula are two distinct bones in the human while they are likely to be fused in non-human quadrupeds. In non-human quadrupeds, the tibial tuberosity is very large with respect to the rest of the tibia. The compact bone of the long bones of the body is proportionally thicker in non-human mammals that it is in human bone. Typically, the compact bone of a human diaphysis accounts for about a quarter of the cross-sectional diameter of the bone. Any bone exceeding this cross-sectional diameter of compact bone is more likely to be non-human (Byers 2008).

The human scapula is triangular in shape, a clavicle is present, the humerus, radius and ulna are gracile and a thumb is present. In other mammals, the scapula is rectangular, the clavicle is usually absent, the humerus,

continued on next page

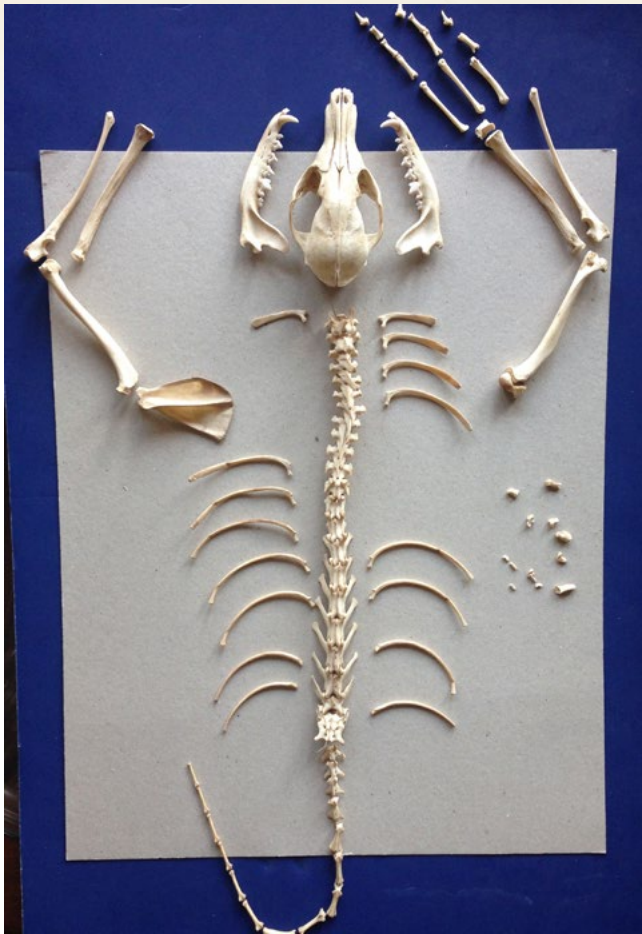

Photo of recovered fox bones in anatomical position.

radius and ulna are likely to be weight bearing bones and therefore more robust, and the thumb is small when present (Byers 2008).

Human remains are generally easier to identify than animal remains. The human bones most likely to be wrongly classified as non-human bones are bones of infants and small children. The most common areas of confusion include the presence of unfused epiphyses, which changes the bone count of the skeleton, and the fact that the bones of the hands, feet and clavicle may not be fused. The separated, unfused epiphyses may not appear to be human to the untrained observer. The long bones of infants are thin in cross section and the cranial bones may be separate and more uniform in thickness than they are in the adult. These immature human bones are most likely to be confused with the bones of small mammals such as rabbits, cats, raccoons and the bones of larger birds (Byers 2008).

When the animal pelt is not present with the remains, the skull is the best way to identify unknown animal species (Mengak and Moore 2012). In cases where the skull is absent, DNA analysis from mitochondrial DNA, genomic DNA or ribosomal RNA can be used to aid in the species identification (Melton and Holland 2007). DNA analysis, while very accurate, is more time and labor intensive than morphological or histological analysis (Crocker *et al.* 2009). DNA analysis includes but is not limited to: immunological analysis, protein

radioimmunoassay and polymerase chain reaction (PCR). Each species has unique DNA fragment lengths, different numbers of genes, and unique genes. Problems with this technique arise when trying to sequence an unknown sample or to work with DNA from badly degraded bone fragments (Crocker *et al.* 2009). Currently investigators seek to establish more accurate and elaborate reference points for use with control samples.

Identification of the species must precede any attempt to determine the age of an animal at death. Animals all have specific growth rates that vary depending on genetics, food and water supplies, and the availability of habitat. The most common methods employed to determine the age at death include analysis of suture and epiphyseal closers and analysis of tooth structure. The canine tooth sectioning method examines the presence of annuli in the cementum and dentine of the tooth. Using this method the age of a mammal can be narrowed down by counting the number of layers of cementum and adding a year of age for each layer (Jensen and Nielsen 1968). Dentine layers can also be counted in longitudinally sanded canine roots. This process avoids having to prepare histological samples and it is reliable in determining the age of red fox specimens that are more than a year old (Roulichova and Milos 2007).

The presence or absence of suture closers can be used for most mammals to determine the age of skeletal remains in animals up to two years of age (Johnston and Beauregard 1969). Sutures are scored as being open, closing or closed. Using red fox skulls, Markina (1962) found that most of the basioccipital-basisphenoid (BOBS) sutures closed between six months and a year of age. The presphenoid-basisphenoid (PSBS) suture takes much longer to close and is prone to more variations. It begins closing after 7 months and can take up to two years to fully close (Harris 1978). Another widely used aging method is examination of epiphyseal closure. Smith and Allock (1960) reported finding great similarity in the ossification of epiphyseal cartilage in the canine family. In the red fox the method can be used on individuals older than 3 weeks (Smith and Allock 1960). Ossification of the bones of the foot takes place at 22 weeks of age, the vertebral column ossifies at 27 weeks, and the limb bones ossify at 30 weeks. Following these ossifications, the scapula, ilium and ischium gradually ossify and the symphysis pubis takes shape (Harris 1978). To separate juveniles from adults, the formation of the tibial tuberosity (apophysis fusion) on the diaphysis of the tibia is the most useful bone marking. This fusion is usually complete by the time the fox is a year old. The distal epiphysis of the radius and ulna ossify at 8 to 9 months and the proximal epiphysis of the humerus remains unfused for about 9 months. Bone ossification and epiphyseal closers happen relatively rapidly in the fox population in the United States (Harris 1978).

continued on next page

Sex Determination

A human skeleton has many markers that can be used to identify the probable sex of remains, including the angle of the pubic arch, the robusticity of the brow arches and rugosity of the mastoid process. Other mammals do not have skeletal markers such as these or the skeletal markers have not yet been clearly identified. Differentiating female from male is much harder in fox species and in the canine family in general (Travini *et al.* 2000).

Identification of the sex of an animal is easiest when the animal is intact, or the genital tissue is present. Unfortunately in cases where the animal remains are in the later stages of decomposition, differentiating sex is much harder and often impossible. The teeth and skull are generally the most useful skeletal items in determining the sex of carnivore remains however, there is very little difference between female and male skeletal remains in the canine family. Travini *et al.* (2000) reported that male skulls are about 5% larger in the American culpeo fox, which is similar in size to the red fox. In many species of mammals the female is larger than the male due to the maternal duties of the female. The female is more invested in bearing and raising the young and therefore a larger size may increase survival of offspring (Ralls 1976, Travini *et al.* 2000, Travini and Delibes 1995).

Cause of Death

The cause of death is usually determined by an autopsy or necropsy but when the remains are skeletonized, examiners must use other techniques to determine the cause of death. All skeletal evidence must be collected, including any tissue that might lend itself to molecular examination. If the remains were removed from more than one site, DNA testing is required to make sure that they are from the same individual. Connective tissue is removed by boiling, washing or dermestid activity, and the skeletal components are displayed in anatomical position. The remains can then be examined for any abnormalities. Examiners look for signs of fracture, missing bones, bone fusions, bone lesions and bone fragmentation (Byers 2008).

Different types of fractures occur under different circumstances. A fracture is simply a break in the bone caused by an abnormal external force that is characterized by direction and focus (Ortner and Putschar 1981). The direction of the force depends on tension, compression, torsion, bending and/or shearing while the focus is categorized as narrow or wide, describing the impact surface area. A longitudinal fracture follows the long axis of the bone and runs parallel to the bone. A transverse fracture, also known as a stress fracture, is a break that goes straight across the bone usually as a result of a direct impact to the bone at the fracture site. Radiating fractures originate from a point of stress and extend out as the force dissipates through the bone. An oblique fracture is the result of a blow that comes in at an angle to

the bone causing a break to occur at an angle across the bone. A twisting force that causes an oblique fracture through and across the bone is called a spiral fracture. Comminuted fractures occur when the bone has been splintered or crushed into more than three pieces. Incomplete fractures, or greenstick fractures, are fractures that occur in softer bones of juveniles and do not extend all the way through the bone (Ortner and Putschar 1981, Ortner 2003).

Examiners must further classify bone fractures as antemortem, perimortem or postmortem. Antemortem injuries occurred prior to the time of death and may be in the process of healing. Abnormal bone growth or shape, callus formation, necrotic tissue or signs of infection are all indicative of past injuries (Ortner and Putschar 1981). If there are signs of bone remodeling, it takes about 1 to 3 weeks for the jagged edges of a fracture to become rounded, and at 6 weeks a bony callus begins to form (Sauer 1998). Perimortem fractures occur around the time of death and the bone may still be encased in fur, skin and muscle. Unlike antemortem fractures, perimortem skeletal injuries show no signs of healing. Postmortem fractures occur during the decomposition process. Depending on what decomposition stage the bone is in, the bone may be dry and the fractured bone ends may appear straight and have sharp edges. Postmortem radiating fractures are very rare because of the dry condition of the bone (Ortner and Putschar 1981).

Discussion: Investigation of the remains of an unknown mammalian quadruped

The remains of an unknown mammalian quadruped were found in the vicinity of Manassas, Virginia in the spring of 2014. There were no organs present, and most of the soft tissue was gone. The remains consisted of a collection of partially articulated bones, several teeth, claws, assorted ligaments, and a little fur. Forensic investigative techniques were used to determine the species, age and probable sex of these remains.

The remains were in the early skeletonization stage of decomposition when they were discovered. The bones were buried under a foot of mulch for the month of August 2014, to facilitate the decomposition of the remaining soft tissue and separation of the bones from the residual fur. Upon removal from the mulch, the bones were subjected to three ammonia washes to get rid of any remaining fat. Following the ammonia treatment, the remains were thoroughly rinsed in plain water prior to being dried and assembled in anatomical position. Missing bones, fractures, and abnormalities were carefully recorded at this time.

The skull was found fully intact and all the teeth were present except for two in the anterior mandible. Based on the size of the remains and the narrow morphology

continued on next page

of the skull the species possibilities were narrowed to either that of a fox or a dog. Animals of comparable size, such as cats and raccoons, have a more rounded skull. The northeast region of the United States is home to the both the gray fox and the red fox but the red fox population is greater in this region. The two species of fox are very similar in their morphology except for the skull, which in the red fox bears a clear “V” shaped indentation and in the grey fox bears a “U” indentation (Mengak and Moore 2012). (Figure 1)

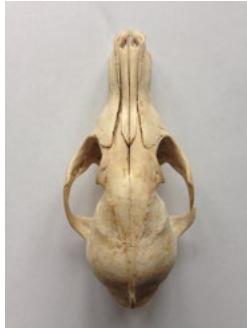

Figure 1 Fox skull showing “V” shaped indentation

As in humans, the age of a fox is determined using the degree of cranial suture closure, epiphyseal plate ossification, or tooth cemenyum/dentine morphology. Examination of the fox remains revealed that the basioccipital-basisphenoid (BOBS), which starts to close at six months (Harris 1978), was in the process of closing. The presphenoid-basisphenoid (PSBS) suture, which takes longer to close, had not yet begun to close in the fox skull. All of the foot bones recovered had signs of epiphyseal ossification, indicating that the fox remains were older than 22 weeks. The vertebral column completes ossification at about 27 weeks and the vertebrae in this animal were not all ossified. The coccyx and sacrum had not yet ossified, but some of the lumbar vertebrae had completed ossification. The limb bones, which complete epiphyseal ossification at 30 weeks (Harris 1978), were not yet ossified. (Figure 2) This puts the red fox remains at under six months

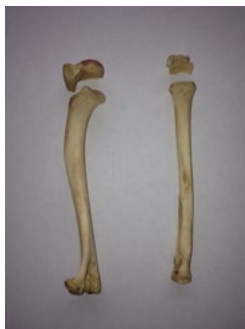

Figure 2 Limb bones of fox showing incomplete epiphyseal ossification.

of age. Tooth samples were not examined because of the availability of the excellent suture closure and epiphyseal ossification data that were gathered.

The skeletal remains found were in the skeletonization stage of decomposition; there was no pelt or genital tissue to compare and the remains of this animal had been subjected to animal scavenging which resulted in the removal of the pelvic bones. It was judged to be too difficult to determine the sex of the remains with

any degree of accuracy. The remains could be either a young male or a young female fox.

Determining the cause of death of the fox included examining the remains for any fractures and abnormalities. During the re-assembling process each bone was examined, a list of missing bones was made, and the bones were arranged in anatomical position. It was clear during the re-assembly process that scavenging had taken place. The pelvic bones, atlas and axis, coccyx, upper appendages, the right scapula, and several rib bones were missing. Refer to Table 1 for a complete inventory of the missing bones. Many of the ribs evidenced oblique and transverse simple fractures. (Figure 3) The positioning of the rib

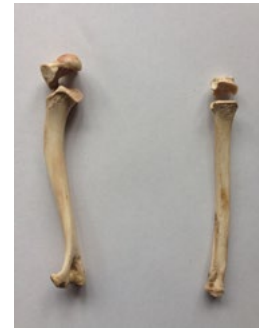

Figure 3 Fox bones showing areas of fracture.

fractures led to the hypothesis that the lower thorax and abdomen had suffered a crushing injury. The remaining scapula also had an oblique fracture about 3 mm in length located in the infraspinous fossa. The scapula fracture did not support or disprove the theory that the lower thoracic and abdominal area had been crushed.

While the injuries sustained suggested that the lower thorax and abdomen of the fox had been crushed it was clear that this injury did not immediately kill the fox. The fox had moved away from the site of the injury to die beside a little stream. By applying osteological techniques to unknown skeletonized remains it was possible to identify the exact species of the animal, determine the age of the skeletal remains and develop a scenario for the probable cause of death. The remains of the red fox, *Vulpes vulpes*, described in this article belonged to a juvenile less than six months of age that likely died as a result of a crushing injury secondary to an encounter with a predator or with a moving vehicle of some type. The gender of the fox could not be determined.

***Editors note:** The red fox is found throughout Virginia except for a few small areas in the extreme southeast corner of the state. It prefers less populated areas and gravitates towards farmland. Red foxes are omnivorous with a primary diet made up of rabbits and mice. The average red fox is the size of a small dog. The total length of the animal, including its tail, is from 39 to 41 inches and body weight ranges from nine to twelve pounds. The animal is characterized by the presence of large erect ears, a sharply pointed nose, and a

continued on next page

long, voluminous tail with a white tip. The fur is typically long and soft with the upper part colored reddish-yellow and the fur of the shoulders tipped with black. The breeding season is from December to February, with a peak in late January. A litter of 4-7 pups is born in a den in late March or early April. Red foxes are typically nocturnal and non-migratory and they usually live their whole life and die in the same geographic area. The average life span is about 5 years (Virginia Department of Game and Inland Fisheries 2015).

Photo credit: istock photo by Getty Images

Literature cited

- Byers, Steven M (2008) Introduction to Forensic Anthropology, 3/e New York. Pearson Publishing. p176-248.
- Crocker, S. L., Clement, J. G., and Donlon, D. (2009). A comparison of cortical bone thickness in the femoral midshaft of humans and two non-human mammals. *Journal of Comparative Human Biology* 60:551–565.
- Harris, Stephen (1978) Age determination in the Red fox (*Vulpes vulpes*)- an evaluation of technique efficiency as applied to a sample of suburban foxes. *J. Zool., London* (184) 91-117.
- Hillier, Maria L and Lynne S Bell (2007). Differentiating human bone from animal bone: a review of histological methods. *J Forensic Sci.* 52(2): 249-263.
- Jensen, Birger and Nielsen B (1968). Age Determination in the Red Fox (*Vulpes vulpes* L.) from Canine Tooth Section. *Danish Review of Game Biology*.(5):6.
- Johnston, D.H. Beauregard, M (1969). Rabies epidemiology in Ontario. *Bull. Wildl. Dis. Assoc* (5):357-370.
- Markina, AB(1962) Age craniology of the fox (*Vulpes vulpes* L.). *Trudy biol. Inst. Sib. Otd. Akad. Nauk SSSR* (8):171-179.
- Melton, T., and Holland C (2007). Routine forensic use of the mitochondrial 12S ribosomal RNA gene for species identification. *Journal of Forensic Sciences* 52:1305–1307.
- Mengak T and Michael Moore F. William (2012). Key to the Skulls of Adult Mammals of Georgia and that of Southeastern United States. Warnell School of Forestry and Natural Resources. University of Georgia. NHS p12-10.
- Ortner, D. and Putschar W (1981). Identification of pathological conditions in human skeletal remains. Washington, D.C. Smithsonian Institution Press. 28:488.
- Ortner, D. (2003) Identification of pathological conditions in human skeletal remains. 2nd edition. Amsterdam. Academic Press. p645.
- Roulichova, Jana and Andera Milos (2007) Simple method of age determination in red fox, *Vulpes vulpes*. *Folia Zool.* 56(4):440-444.

Sauer, NJ (1998). The timing of injuries and manner of death: distinguishing among antemortem, perimortem and postmortem trauma. In Reichs, K. (Ed.). *Forensic osteology: advances in the identification of human remains*. 2nd ed. Springfield, IL: Charles C Thomas. p321–332.

Smith, RN and Allcock, J (1960). Epiphysial fusion in the greyhound. *Vet. Rec.*72: 75-79.

Travaini, A., Delibes, M. (1995). Weight and external measurements of red fox (*vulpes vulpes*) from SW Spain. *Zeitschrift fur Saugetierkunde* 60:121-123.

Travaini, A. Juste, J. Novaro, A. Capurro, A. (2000) Sexual dimorphism and sex identification in the South American culpeo fox, *Pseudalopex culpaeus* (Carnivora:Candae). *Wildlife Research* 27(6):669 – 674.

Virginia Department of Game and Inland Fisheries
<http://www.dgif.virginia.gov/wildlife/information/?s=050049>, accessed March 21, 2015.

About the Authors




Olena has always been interested in anatomy, physiology and problem solving. She believes that working with unknown animal remains enables her to use both her skill and her passion. She hopes to find a job in the field of forensics where she can puzzle and piece together the truth using biological techniques of investigation.



Sarah Cooper is co-editor of the HAPS-EDucator. She has taught human anatomy and general biology at Arcadia University since 1981 and she serves as the pre-nursing adviser and coordinator of the interdisciplinary science program.



Dr. Jennifer Wood is an adjunct professor at University of Maryland University College where she teaches nonprofit management.



The HAPS Board of Directors has made a powerful commitment to the growth of the HAPS Foundation.

Beginning this year, the HAPS general fund is supporting \$5,000 in grants and scholarships annually, allowing all funds raised by the Foundation to accumulate towards the goal of \$100,000. The Foundation fund balance currently stands at \$50,132 - halfway there, but a long way to go!

The Society's \$5,000 contribution, in combination with our sponsored scholarship partners- ADInstruments, Primal Pictures, and Thieme Medical Publishers, means that HAPS will be able to grant over \$10,000 this year in grants, awards, and scholarships.

Since the last annual conference, the Foundation Committee members, led by Don Kelly, have recommended, and the HAPS Board of Directors has approved:

- **Two Robert Anthony Awards**
- **One Contingent Faculty Award**
- **Two Sam Drogo Technology Awards**
- **Two Graduate Student Travel Awards**
- **One Faculty Grant**
- **Four HAPS- I Scholarships**

Further grants will be announced soon. For descriptions of the HAPS grants and scholarships, [CLICK HERE](#)

Each year, the Foundation begins its fundraising with an appeal to the officers, directors, and steering committee members. We believe in leading by example.

This year, the leadership drive raised \$2,520!

NOW IT IS TIME FOR US TO APPEAL TO YOU, the membership, for your support in building the HAPS Foundation Fund.

DONATE NOW

The Nerve of it All: The Brachial Plexus in 3D. A Workshop Presentation at the Central Regional Conference in Cincinnati, OH

Christine Yu
Doctoral Candidate, Human Development
Learning and Developmental Sciences
Counseling and Educational Psychology Department
Indiana University Bloomington
cid@indiana.edu

I would like to thank the HAPS Grants and Scholarships Committee for selecting me as one of the recipients of the Graduate Student Travel award for my workshop, "The nerve of it all: The brachial plexus in 3D" for the 2015 Annual Meeting in San Antonio, TX. I would also like to extend my gratitude to Dr. Bonnie Richmond, the HAPS Central Regional Conference Coordinator, for extending an invitation for me to present this same workshop at the Central Regional Conference in Cincinnati, OH on March 7, 2015. Presenting my workshop at the Regional Conference allowed me to interact with HAPS members who will not be able to attend the Annual Meeting while also allowing me to assess my presentation and make refinements for the Annual Meeting in May.

I would be remiss if I did not mention that my journey as a new HAPS member is directly related to the guidance and encouragement of Dr. Valerie O'Loughlin, who has been professor and mentor extraordinaire. When Dr. O'Loughlin saw the 3-dimensional brachial plexus that I had created as a teaching tool for medical students at Marian University, she enthusiastically encouraged me to submit a proposal for my workshop for both conferences. Dr. O'Loughlin also assuaged my concerns that my workshop was unnecessary since I thought it might be perceived as a "silly art project". With some reticence, I applied and prepared to present my workshop in Cincinnati. Little did I know how many HAPS members were interested in using kinesthetic tools for learning and instruction, and I was welcomed with warm smiles and enthusiasm for my workshop.

Admittedly I felt like my workshop was a minor portion of the Conference, and I was intrigued by the larger entity of HAPS. I wondered whether or not I would "fit in" since my degree is in Developmental Psychology with a concentration in Anatomy. My concerns were immediately allayed as Dr. Laura Woollett began the Update Seminar with research from David Barker from the '80s that showed the relationship between low birth-weight, less than 5.5 pounds, and adult obesity, diabetes, and hypertension. "Woo-hoo!" I thought, "THIS information is what I teach in developmental psych courses!" As Dr. Woollett continued to discuss developmental programming and her research on the causes of abnormal fetal growth, I felt comfortable and had the realization that I "really do belong here."



Christine Yu and the brachial plexus model she constructed for her conference workshop.

The feeling of "really belonging here" continued as I went to the poster session and listened to Dr. Mary Tracy-Bee discuss the process of integrating creative, interactive strategies into the classroom. Dr. Tracy-Bee attended my workshop and advocated for me to create a video of my workshop for youtube while Dr. O'Loughlin suggested placing the video on the HAPS website. After acknowledging my anxiety and hesitant feelings, I made arrangements to digitally record my workshop over spring break and am working through the edits with my film colleague.

The afternoon workshop was particularly beneficial in highlighting deficiencies in my understanding of Team-Based Learning (TBL). I appreciated how the workshop itself was


formatted as a TBL so that we all experienced first-hand a well-executed TBL by Dr. April Hatcher and her team from University of Kentucky. I left that workshop with a renewed zeal to implement TBL into my future classroom's curricular design.

If it were only my expectations for the HAPS Central Regional Conference that were met, I believe I would have enjoyed a solid, worthwhile learning experience. I am thrilled that my expectations were not only met but blown out of the water by this amazing learning and restorative experience. The enthusiasm and kindness of the HAPS attendees and administrative staff impressed upon me the importance of genuine enthusiasm in anatomy education. This lesson is one that cannot be bought with money.

Thank you for the opportunity to share and learn together. I look forward to San Antonio in May.

About the Author

CHRISTINE YU, M.A., is a graduate student pursuing a Ph.D. degree in Human Development in the Counseling and Educational Psychology Department in the School of Education at Indiana University, Bloomington, Indiana. She has a minor concentration in Anatomy in the Medical Sciences Program at the Indiana University School of Medicine, Bloomington, Indiana. She is an associate instructor for undergraduate human anatomy at Indiana University Bloomington. She has been an associate instructor for early childhood development, adolescent development, and lifespan development at Indiana University Bloomington. She has worked at Marian University in Indianapolis, Indiana as a teaching assistant for gross anatomy. ■



Cincinnati Regional HAPS Conference, March 7, 2015

Bonnie L. Richmond, Ph.D.
Associate Professor
Galen College of Nursing
100 E. Business Way, Cincinnati, OH 45241
BRichmond@galencollege.edu | 513.475.3646 or 513.475.3600



Bonnie Richmond and her granddaughter, Maddy, at the Cincinnati Regional Conference.

The Cincinnati Regional Conference began on a beautiful sunny day, the first sunshine the area had seen in two weeks! There were fifty-six people in attendance from eleven states. We were especially pleased to welcome thirteen new HAPS members.

The morning session began with the first speaker, Dr. Laura Woolett, a professor at the University of Cincinnati School of Medicine. Laura's talk

was fantastic. She discussed her research in mice on the relationships between the multiparous female and increased obesity. Her research suggests that, in mice, as the number of pregnancies increases, the inflammatory response promoted during pregnancy also increases, resulting in changes in lipid metabolism and increased obesity of mom. These changes in inflammation and lipid metabolism in mom may result in increased risk factors for obesity in offspring with each subsequent pregnancy.

After Dr. Woolett's presentation, we broke for morning workshops and posters. All of the workshops and posters for both morning and afternoon sessions presented a wide variety of excellent pedagogical ideas and practices for increasing student engagement, understanding, and retention in both lecture and lab. There was also an excellent workshop on preparing better exam questions. I would like to thank to all of the presenters for a job well done.

Lunch provided lots of food accompanied by lively conversation. The afternoon speaker was Dr. Raymond Boissy, a professor and pigment cell biologist at the University of Cincinnati School of Medicine. Ray gave a very engaging and fascinating talk on the faulty intracellular trafficking of melanosomes, which results in loss of pigmentation in individuals with the genetic disorder of Hermansky Pudlak Syndrome. Individuals with HPS not only suffer from insufficient pigmentation, but also exhibit deficient blood clotting capabilities and the accumulation of lipofucian deposits in the lungs, which results in death. This indicates that the mutated proteins associated with melanosome trafficking are also involved with intracellular trafficking in other tissues.

The day ended with door prizes from the exhibitors and Galen College followed by an optional trip to the Mummies exhibits at the Cincinnati Museum Center. Ronn Wade gave an informative workshop on Mummies in preparation for the exhibit. The entire exhibit of mummies was fascinating, but the mummified anatomical specimens from the Burns Institute were particularly amazing.

I hope this was an informative and pleasant day for all participants and I would like to extend special thanks to everyone who supported the conference.



THERE WILL BE THREE REGIONAL MEETINGS IN THE FALL 2015:


**EASTERN REGIONAL MEETING -
Salisbury, MD - October 3, 2015**

**CENTRAL REGIONAL MEETING -
Milwaukee, WI - November 14, 2015**

**AUSTRALIA REGIONAL MEETING -
Melbourne - December 4-5, 2015**

About the Author

Bonnie Richmond is a professor at Galen College of Nursing in Cincinnati, Ohio, where she teaches anatomy and physiology. She particularly enjoys doing review sessions with upper level nursing students helping them to understand the body's systemic reaction to trauma and disease.





EDU-SNIPPETS

EDU-Snippets: Spring Snippets

EDU-Snippets – A column that survives because you - the members - send in your Snippets

Roberta M. Meehan
GMU

Phoenix, AZ

Edu-Snippets@hapsconnect.org

EDU-Snippets is a column designed to let you, the members of HAPS, share your “ways to make sure your students get it.” Since EDU-Snippets began, our members have been continuously amazed at how many teaching and demonstration ideas pop up and are easily transferred from one instructor to another through Snippets. This edition is no exception. As a matter of fact, you have come through with flying colors once again and we have an action packed synaptic column here. Our main theme was scheduled to deal with the endocrine system. In true HAPS fashion, however, all sorts of Snippets came in. That is just fine!!! So, our topic for this issue is Spring-Snippets.

Hopefully you will be able to utilize what our colleagues have submitted. Hopefully, too, some of the ideas presented here will spur you on so that you can either make alterations to fit your own needs or spark your imagination so that you can come up with your own Snippet idea, which you can then submit for publication.

I. Snippet Hormone

We did have one hormonally inclined Snippet. This sounds like a great idea for helping our students through the endocrine maze. Tom Lehman (Coconino Community College, tom.lehman@coconino.edu) explains what he does.

My lab has a stack of dry erase boards. We bought large sheets of this from the hardware store and had them cut it into 2 ft x 3 ft sizes. I have my students draw and list various things during lab (lecture and lab are in one block schedule).

For the endocrine system, I have a series of activities for them to reinforce the glands and hormones. First, I have them draw a gingerbread man and label the different endocrine glands in the body. Then, I have them list the secretory cells and hormones from each. Second, I have them draw arrows to connect related hormones. An example would be a set of arrows between the hypothalamus, the anterior pituitary gland, and the target gland. Then, I have them label the arrows in terms of hormones that work in series to increase the metabolic rate. I have them repeat the activity for “produce sperm”, “heal a bruised wrist”, and “enhance feminine characteristics”. The students respond that this helps them to cement the concepts in very nicely.

II. An Endochondral Ossification Snippet

It seems that Nina Zanetti (Siena College, zanetti@siena.edu) and Karen Groh (Good Samaritan College of Nursing and Health Science, Karen_Groh@trihealth.com) were discussing the problems connected with teaching endochondral ossification. They wanted to share their thoughts with HAPS. Nina began:

For endochondral ossification, I have the students do a short bit of “histo theater”. I call a few of them up, give each a piece of blue paper, and tell them that they are chondrocytes. I have them stand in a row | then walk up to the ones in the middle and tell them that their matrix has become calcified, so they have to die. As the students pretend like they are dying and walk away, I recruit a few new students, hand them a piece of pink paper, and tell them that they are osteoblasts and should go lay down bone (i.e. stand) in the space left by the “degenerated” cartilage cells. I then tell the “chondrocytes” nearer the ends of the line that they should proliferate, which they do by handing blue paper to a few new students who join the line. We repeat these steps several times, always balancing the “degeneration” of cartilage replacement by bone in the center with “proliferation” of cartilage near the ends. The students can clearly see how the line (the “bone”) grows in length and how the amount of cartilage remains constant. At some point,

continued on next page

I tell the “chondrocytes” that they can no longer proliferate, but keep prompting the acting out of cartilage degeneration and bone replacement, until all but the very ends of “cartilage” have been replaced by bone.

When we’re done, we talk about:

what aspects of endochondral ossification were well illustrated by the “play”?

what aspects (e.g. bony collar) were not?

Hmm, I wonder if this might have been a teaching tip? I never think of these things when the request for teaching tips goes out.

Anyway, my students LOVE “histo theater”, it doesn’t take very long, and I think it helps illustrate in a dynamic way the simultaneous cartilage proliferation and cartilage replacement by bone, a concept which is sometimes hard to put into words.

Karen added:

I also have a skeletal POGIL. I’ve discovered teacherspayteachers.com, a website where teachers sell teaching resources they have created. Most of the resources are geared to K-12, but some of the upper level ones are suitable for an introductory undergraduate A and P course. I’ve bought a couple of POGIL-like activities from there and modified them for my class.

But if anyone has any other good ideas or resources for teaching endochondral ossification, I’m interested. I don’t know why my students find that topic so difficult, but they do and I really need some new approaches for it.

III. Pennsylvania Snippets

David Evans (Penn College, devans@pct.edu) sent in three Snippets for this issue! All are well worth absorbing!

A. Immuno-Snippet

Need an exercise for the immune system that requires no equipment?

I give my students case history situations on cards and ask them to diagnose the immunity-related condition plus propose treatments. Each predicament will include vital signs, differential blood cell counts, and a little patient history — some of it having red herrings (just like real patients!). I do group work and allow the students free use of textbooks and the internet.

At the end of each round, the participants record their group decision and reasoning and then we trade off cases until every group has had a shot at all of the situations. At that end point, I choose one student to explain that group’s solution to the whole class. I always threaten to have the least-participating student do the presentation as a way of fostering complete involvement.

Here are some of the situations: Graves Disease, HIV/AIDS, hay fever, shingles, some leukemias, one or two parasitisms, a null case (turns out he is just a hypochondriac), and a few more.

B. Note-taking Snippet

I have long used the method of handing out printed lecture outlines as a means of helping students take more useful notes. Over the past several years I have started to use them as bases for slide shows. The outlines come with lots of space for the students to add their notes but I also supply in separate sections practice questions, puzzles, and A&P news.

The students get the handouts for a lecture block in advance as before. However, these days I take the original Word file and add links to relevant drawings or YouTube videos. There are many, many

great items on the internet but it can take a lot of patience to run through the potential images and videos. I then send the amended Word file attached to an e-mail to myself. When it comes to delivering the lecture, I log into my e-mail service and project the file onto the screen at the front of the classroom — the students have the lecture outline in front of them but with no links. When I get to the point where the link is in the slide show, I ctrl + right mouse button click and the image or video comes up and we can go through it together. If something strange happens, I can still highlight and copy the link into my separately open browser. Should a student want to review the illustrations, I can attach the whole file to an e-mail addressed to that person.

I feel that I have a lot more flexibility doing this with Word rather than PowerPoint, which I also use under special circumstances (e.g., my own animations). The students like the slide shows too which to me is quite valuable. Our evaluations have a question about “using alternative means of delivery for lectures” so this technique applies to that criterion according to Penn College. Naturally, I can do the same thing for labs if I have to give instructions at the beginning.

About using non-original figures: copied illustrations can get you into potential copyright issues (every lawyer says: “Stay out of court, David” even if you are in the right!). If you get your pictures/diagrams from a free image bank, they can still make the slide show files GINORMOUS so that is another reason to stick to links when you can.

Perhaps someone will publish with their own way(s) of helping students with their note-taking in coming issues of the *HAPS-EDUCATOR!*

C. A Snippet of Wisdom

Fibrin is like the back of a band aid—the fibers help to trap the blood cells.

continued on next page

IV. Melon / Pumpkin Bone Snippet

Krista Rompolski (Drexel University, klr94@drexel.edu) used a Pumpkin to demonstrate basic bone anatomy. She then realized some of the other bony possibilities for fruits.

While pumpkin carving with my husband last Halloween, I realized that the interior of a pumpkin is an excellent analogy for the interior of bone. That is what my students were then studying. This is what I explained to them....

I reminded them that all bone first forms as spongy bone, with a layer of cortical (compact) bone on its exterior to reinforce it. The spongy bone is arranged in trabeculae and houses either red or yellow bone marrow. The cortical bone is arranged in parallel osteons, which reinforces its strength. The interior of our long bones is mostly hollow, with just a thin wall of spongy bone remaining on the interior walls. Osteoclasts carved out the spongy bone in long bones during formation.

What does this have to do with pumpkins? Well....



Pumpkin innards make great spongy bone.



*Pumpkin walls make great compact bone.
The skin is the periosteum.*



*The finished bone --
complete with lighting effects.*

Note the first picture. That is spongy bone scooped from the inside of the pumpkin. It even looks like spongy bone, doesn't it?

The second picture is the shell of the pumpkin – the compact bone walls (after the soft interior is removed)!

And the skin of the pumpkin could be considered the periosteum!

The third picture shows the “bone” complete with lighting effects.

Finally, the last picture shows my husband and me enjoying our bony pumpkin. Notice how the carving is not all the way through. This gives the same 3D effect that a cut-away bone gives.

The more I thought about the pumpkin-bone from last Halloween, the more I realized that this could be done with any fruit with a hollowed out center. If you are teaching bones this summer, you might want to try it with a watermelon or a muskmelon or any number of similar fruits.



Krista Rompolski and her husband Dan Taney enjoy their pumpkin-bone.

V. Repeat Snippet – or how to put the left-over candy to good use

This Snippet came up in our last issue but it's a great teaching tool and really bears repeating. Based on the time of year, several people talked about what to do with leftover Easter candy. Use the candy to teach metabolism – any type of metabolism – or anything related, such as cholesterol values. Here is what Pat Bowne (Alverno College, pat.bowne@alverno.edu) sent in last fall. This would work equally well for leftover Easter candy, leftover Christmas candy, leftover Halloween candy, or leftover candy of any type. There are really so many things you can do with leftover candy – in addition to eating it.

You will need some bags – several different sizes. Determine the number by the size of your class.

The body eats the fat (candy) and passes it into the lacteals as chylomicrons (the large bag of candy).

The liver then receives the chylomicron and repackages it into VLDLs (smaller bags).

The VLDLs are passed around the class, each cell taking as much as it wants. The lipoproteins become smaller and less full of fat, becoming IDLs and finally returning to you as half-empty LDLs. You can emphasize that the LDLs are the leftovers, the unneeded fat.

If you want to, you can pass the LDLs around again and have people hide them away in the classroom, explaining how they will go bad there and cause problems. Then you can pass around some HDLs (near-empty bags) to collect them again and take them back to the liver.

VI. And We Hope You Will....

Keep those cards and letters coming (right to our new address)! Thank you all for your EDU-Snippet contributions. The influx

continued on next page


of Snippets has been good! Please keep it up because more are always needed! Your ideas are tremendous! If you have thoughts or ideas, or any other interesting ways – any inspirations at all, great or small – to help our students understand anatomy and physiology, EDU-Snippets would love to hear from you! Once again, EDU-Snippets encourages new submitters to submit – and regulars to keep on contributing! I would think that some of the super discussions lately on the HAPS-L list ought to generate some great

Snippet ideas for your own lecture or lab. If so, please share them with us.

For the next issue of the HAPS-Educator, send your EDU-Snippet experiences and ideas to Edu-Snippets@hapsconnect.org as soon as possible. You will also find a reminder on the HAPS-L list. Plan ahead. You can even submit your ideas now and maybe next issue you too will see your EDU-Snippet in print! Perhaps you even have a suggestion for a Snippet theme! If that sparks a challenge, send on a Snippet!!



Dr. Roberta Meehan is a semi-retired science educator presently involved in tutoring and professional writing. Among other literary endeavors, she has written 17 science books and manuals and two non-science books. She has also written for, edited, copy edited, and done various types of analyses for most of the major publishing houses. She has been on the HAPS Editorial Board for 14 years and has been involved with EDU-Snippets for almost that long. Roberta lives with her dachshunds in Phoenix, Arizona.



Current HAPS-I course offerings:

Current Issues in Obesity Prevention and Treatment

(2 credits)

Krista Lee Rompolski, Ph.D.

June 8, 2015 - August 2, 2015

Obesity is thought to be caused by the interaction of a genetically susceptible individual with the obesogenic environment. Significant advances in the treatment of obesity, whether behavioral, surgical or pharmacological, have been proven successful at the individual level. However, little success has been achieved in preventing weight gain or maintaining weight loss at a population level. Given obesity's recent classification as a disease state, it is imperative that instructors of human anatomy and physiology-based courses are familiar with the growing body of knowledge on obesity prevention and treatment. Therefore, the purpose of this course is to understand obesity with a multifactorial approach, addressing the genetic, biological, environmental, societal and multifactorial approach, addressing the genetic, biological, environmental, societal and behavioral aspects that interact on an individual and population level. Special emphasis will be placed on the integration of knowledge gained from discussion and critique of published clinical and epidemiological studies into an instructor's curriculum.

Anatomia Italiana: The Cultural History of Anatomy Along the Italian Peninsula (3 credits)

Dr. Kevin Petti

June 1 - August 31, 2015

This course is designed to provide college-level instructors with the opportunity to expand their understanding of the rich cultural heritage of anatomy education along the Italian Peninsula, and its connection with Renaissance art. This course is an international experience preceded by a series of readings in peer-reviewed journals and scholarly books intended to put the travel experience into context, and followed by the development of a teaching module. Readings will be discussed in online forums, experienced deeper through the international experience, and applied by way of incorporating the teaching module into an existing anatomy course.

After a four-week online component, students will participate in a 12-day visit to Italy. They will visit anatomy museums in Rome, Florence, Bologna and Padua that are important to the history of anatomy education. These museums include historic anatomy theaters and centuries old anatomical wax models. Traditional cultural sites that contain Renaissance masterpieces, such as the Vatican museums, will also be toured. These masterpieces will be considered within the context of how they were influenced by the dissections conducted by the masters. This interdisciplinary experience allows for students to connect art and anatomy in a unique manner. The result is a deeper and richer understanding of the historic and cultural underpinnings of anatomy education.

Students who have participated in the travel experience prior to participation in the HAPS-I course are eligible to enroll in this course by completing the remaining online component and submission of an interdisciplinary teaching module. Additional information can be found at Anatomiaitaliana.com.

Introduction to Educational Research Methods (1 credit)

Valerie Dean O'Loughlin, Ph.D.

May 3, 2015 - June 15, 2015

This course is for college level instructors who want to become more familiar with basic educational research methods. Participants will learn about metacognition, how people learn, the basics of quantitative versus qualitative educational research methods, how to search the educational literature database, the scholarship of teaching, and develop a foundation for implementing classroom research and assessment. Participants will learn the material through directed readings, online weekly synchronous discussion forums, and face-to-face instruction at the HAPS 2015 meetings (or additional online reading/assignment component, should the participant not be able to attend the HAPS 2015 conference). In addition, participants will apply the information they have learned in the independent development of an educational research question they want to examine in their own classroom.

REGISTER NOW:
[Graduate Credit](#) or
[Professional Development](#)

Courses are continually added, watch our Facebook and Google+ pages for the latest course announcements!


HAPS 29th Annual Conference

5/23/2015 to 5/28/2015

Where: Hyatt Regency
San Antonio Riverwalk
123 Losoya Street
San Antonio, Texas 78205
United States

Contact: HAPS Main Office
info@hapsconnect.org
Phone: 1-800-448-4277

HAPS
2015



SAN ANTONIO

UTSA The University of Texas at San Antonio™

Online registration is available until: 5/8/2015

REGISTER NOW

HAPS COMMITTEES AND BOARDS

ANIMAL USE

Robert Tallitsch, Chair

This committee is charged with developing, reviewing, and recommending policies and position statements on the use of animals in college-level A&P instruction.

rtallitsch@hapsconnect.com

CADAVER USE

Melissa Carroll, Chair

This committee is charged with developing, reviewing, and recommending policies and position statements on the use of cadavers for human anatomy and physiology education in colleges, universities and related institutions.

mcarroll@hapsconnect.org

COMMUNICATION

Wendy Riggs, Chair

This committee is tasked with helping HAPS establish its voice in a technological landscape shaped by social media. Committee members work closely with the Marketing Committee to facilitate connections within HAPS as well as recruiting potential members via social media.

wriggs@hapsconnect.org

CONFERENCE

Ellen Lathrop-Davis, Chair

This committee actively encourages HAPS members to consider hosting an Annual Conference. We provide advice and assistance to members who are considering hosting an annual conference.

elathrop@hapsconnect.org

CURRICULUM AND INSTRUCTION

Hiranya Roychowdhury, Co-Chair

Terry Thompson, Co-Chair

This committee develops and catalogs resources that aid in anatomy and physiology course development and instruction.

hroychow@hapsconnect.org

tthompson@hapsconnect.org

EXECUTIVE

Tom Lehman, President

Valerie O'Loughlin, Past President

Betsy Ott, President Elect

Composed of the HAPS President, President-Elect,

Past President, Treasurer and Secretary

tlehman@hapsconnect.org

voloughl@hapsconnect.org

bott@hapsconnect.org

EXECUTIVE DIRECTOR

Peter English

peter@hapsconnect.org

FOUNDATION OVERSIGHT

Bob Crocker, Co-Chair

Don Kelly, Co-Chair

The HAPS Foundation was established to create a mechanism by which donors could make tax-deductible contributions to projects that support professional development programs for A&P teachers and that enhance the quality of human A&P instruction.

dkelly@hapsconnect.org

rcrocker@hapsconnect.org

HAPS EDUCATOR

Sarah Cooper, Co-Editor

Jennelle Malcos, Co-Editor

This committee is responsible for publishing a quarterly edition of the HAPS-EDucator, the journal of the Human Anatomy and Physiology Society. The committee works closely with the Steering Committee and the President of HAPS.

scooper@hapsconnect.org

jmalcos@hapsconnect.org

HAPS INSTITUTE

Peter English, Chair

HAPS Institute oversees a program that offers graduate biology credit courses earned through Alverno College

peter@hapsconnect.org

MEMBERSHIP

Elizabeth Pennefather-O'Brien, Co-Chair

Kyla Ross, Co-Chair

This committee is charged with expanding our membership base to include all Human Anatomy and Physiology educators or those individuals, institutions and corporations crucial to the HAPS mission statement of "Promoting Excellence in the Teaching of Human Anatomy and Physiology."

eobrien@hapsconnect.org

kross@hapsconnect.org

NOMINATING

Betsy Ott, Chair

This committee recruits nominees for HAPS elected offices.

bott@hapsconnect.org

PRESIDENTS EMERITI ADVISORY BOARD

Dee Silverman, Chair

This committee consists of an experienced advisory group including all Past Presidents of HAPS. The committee advises and adds a sense of HAPS history to the deliberations of the BOD

dsilver@hapsconnect.org

SAFETY

Yuli Kainer, Co-Chair

Neal Schmidt, Co-Chair

This committee develops standards for laboratory safety. The committee maintains a variety of safety documents available for download.

ykainer@hapsconnect.org

nschmidt@hapsconnect.org

STEERING

Ron Gerrits, Chair

This committee consists of all committee chairs. It coordinates activities among committees and represents the collective committee activity to the HAPS BOD.

rgerrits@hapsconnect.org

TESTING

Curtis Defriez, Co-Chair

Eric Sun, Co-Chair

This committee has completed, tested and approved the HAPS Comprehensive Exam for Human A&P and is developing an on-line version of the exam.

cdefriez@hapsconnect.org

esun@hapsconnect.org

2015 CONFERENCE COORDINATORS

Jason LaPres, Co-Chair

Anita Moss, Co-Chair

The committee chairs invite input from HAPS members and willingly provide information on the activities of their committees.

jlapres@hapsconnect.org

amos@hapsconnect.org

[Click here to visit the HAPS committees webpage.](#)