

ORIGINAL ARTICLES

Morphology and Function

The Influence of Through-Plane Motion on Left Ventricular Volumes Measured by Magnetic Resonance Imaging: Implications for Image Acquisition and Analysis

J. T. Marcus,¹ M. J. W. Götte,² L. K. DeWaal,¹ M. R. Stam,¹
R. J. Van der Geest,³ R. M. Heethaar,¹ and
A. C. Van Rossum²

¹Department of Medical Physics and Informatics, University Hospital, Vrije Universiteit, Amsterdam, The Netherlands

²Department of Cardiology, Institute for Cardiovascular Research ICaR-VU, Vrije Universiteit, Amsterdam, The Netherlands

³Department of Radiology, Leiden University Medical Centre, Leiden, The Netherlands

ABSTRACT

In the evaluation of the left ventricular (LV) function using magnetic resonance imaging (MRI), a stack of parallel short-axis (SA) cine images is acquired that covers the whole LV. The aim of this study is to quantify the contribution to the LV volume parameters, provided by the most basal image plane that shows the LV wall only in end diastole (ED) but not in end systole (ES). In 57 healthy volunteers (31 men, mean body surface area 1.87 m²), a complete set of parallel SA images was acquired (10-mm slice distance) by breathhold segmented k-space cine MRI (7 k_y lines per beat). The LV end-diastolic volume (EDV), stroke volume (SV), ejection fraction (EF), and cardiac output (CO) were determined by slice summation. Calculations were performed both with and without inclusion of the most basal slice. With inclusion of the most basal slice, all parameters were significantly ($p < 0.001$) larger compared with the values obtained by excluding this slice. EDV was 134 ± 29 ml versus 113 ± 26 ml; SV was 93 ± 18 ml versus 72 ± 16 ml; EF was $70 \pm 4\%$ versus $64 \pm 4\%$; and CO was 5.3 ± 1.4 l/min versus 4.1 ± 1.1 l/min. The inclusion of the most basal slice leads to significantly larger values of LV volume parameters. Thus, this most basal SA image slice should be included in calculating the EDV. Whether or not this basal SA slice also contributes to the ES volume should be decided by using anatomical criteria on the ES image. The projection line onto the ES image of a long-axis view provides an additional criterion.

KEY WORDS: Heart, ejection fraction; Heart, function; Heart, ventricles; MRI.

Received March 25, 1998; Accepted May 11, 1998

Address reprint requests to J. T. Marcus.

INTRODUCTION

Accurate measurements of left ventricular (LV) volumes and ejection fraction are of prognostic value in patients with known or suspected heart disease (1). These parameters of global LV function can be obtained by using breathhold cine-magnetic resonance imaging (MRI). The usual approach is to acquire a stack of short-axis (SA) images covering the heart from base to apex and then measuring the end-diastolic (ED) and end-systolic (ES) volumes of the LV by slice summation. From these volumes, the stroke volume (SV), ejection fraction (EF), and cardiac output (CO) are derived. In this approach, no geometrical assumptions concerning the shape of the LV are necessary (2–4). An additional advantage of the stack of SA cines is that regional myocardial function also can be assessed by measuring wall thickening (5).

However, after processing the SA images, an as yet unaddressed problem occurs in the evaluation of the most basal image plane; in ED this plane clearly shows the basal part of the LV, but during systole this basal part moves through the image plane because of the longitudinal shortening of the LV (6,7). The effect of this most basal plane on the LV volume parameters may be considerable because of the large cross-sectional area of the LV included in this slice.

The aim of this study is to quantify the contribution of this most basal plane on the LV volume parameters. In addition, an imaging and analysis procedure is described that takes this contribution into account to obtain more accurate LV volume parameters.

MATERIALS AND METHODS

Subjects

Fifty-seven healthy volunteers (31 men) aged 19–69 yr (mean, 28 yr) were examined. The volunteers weighed 48–100 kg (mean, 71 kg), their height was 158–197 cm (mean, 177 cm), their body mass index ranged from 17.4 to 31.5 kg/m² (mean, 22.6 kg/m²), and their body surface area (BSA) ranged from 1.46 to 2.21 m² (mean, 1.87 m²).

Magnetic Resonance Imaging

Forty-seven subjects were scanned using a 1.0-T Siemens Impact Expert whole body system and 10 subjects were scanned using a 1.5-T Siemens Vision whole body system (Siemens Medical Systems, Erlangen, Germany). On both systems, a phased-array body coil was applied. Image acquisition was prospectively triggered by the R

wave of the electrocardiogram. The subject was instructed to hold his or her breath in moderate inspiration during all image acquisitions (thus also during “scout” imaging for localization of the heart). First, the horizontal long-axis (LA) view was determined in a late diastolic frame using a rapid black-blood prepared turboflash sequence (8). Then, a breathhold cine-acquisition was performed on this LA view. By using the ED cine frame of this LA view, a series of parallel SA image planes was defined starting at the base of the LV and encompassing the LV from base to apex. The most basal image plane was positioned close to the transition of the LV myocardium to the mitral valve leaflets (at a distance of half the slice thickness). This ensured that also the most basal part of the LV was covered. At every SA plane, a breathhold cine acquisition was then performed. Seven to 11 SA image planes were needed to encompass the entire LV from base to apex. For the cine-imaging, a gradient-echo pulse sequence was applied with segmented k-space, 7 k_y lines per heartbeat, and a temporal resolution of 80 msec. On the 1.5-T system, echo sharing was used, yielding a temporal frame at every 40 msec. The excitation angle was 25°. For the SA images, the field of view was 219 × 250 mm, matrix size was 126 × 256, slice thickness was 8 mm, and the interslice gap was 2 mm (yielding a slice distance of 10 mm). Heart rate was monitored during the acquisition of the SA images.

Image Analysis

The images were processed on a Sun Sparcstation (Sun Microsystems, Mountain View, CA) using the MASS software package (Dept. of Radiology, Leiden University Medical Center, Leiden, The Netherlands) (5). ED was defined as the first temporal frame directly after the R wave of the electrocardiogram. ES was defined as the temporal frame at which the image showed the smallest LV cavity area, usually 240–320 msec after the R wave. Epicardial and endocardial contours were manually traced, and the papillary muscles were excluded from the LV volume. The most basal slice was defined as the slice which at ED still showed wall thickness compatible with the LV and at ES showed wall thinning (due to atrial wall involvement). At ES, this most basal slice could also show a part of the LV outflow tract or the mitral valve leaflets. Thus, this basal plane contributed to the end-diastolic volume (EDV) but not to the end-systolic volume (ESV) of the LV. If the most basal image at ES was difficult to interpret (e.g., due to partial volume effects), then this most basal plane was projected on the ES frame of the LA cine images. The resulting projection line on this

LA view then provided the decisive cue on whether or not to include the ES SA image as a part of the LV.

EDV and ESV were calculated by summation of the product (area \times slice distance) for all slices. SV is then given by $SV = EDV - ESV$, and EF by $EF = (SV \div EDV) \times 100\%$. CO is heart rate \times SV. These calculations were performed both with and without inclusion of the most basal plane. Finally, all LV volume measures were also normalized for BSA. In the statistical analysis, the effect of inclusion of the most basal plane was tested by paired-samples *t*-testing.

RESULTS

Figure 1 illustrates the effect of through-plane motion for the most basal image plane. The projection line of the most basal SA image plane onto the LA plane demonstrates that at ED the most basal slice encompasses the upper part of the left ventricle, whereas at ES this basal slice no longer contains any part of the left ventricle. In addition, the anatomy of the most basal SA view at ES (Fig. 1, middle right) provides evidence that the LV wall is not presented anymore but rather the LV outflow tract or the left atrium.

In Table 1, the LV volume parameters and CO are given calculated with and without inclusion of the most basal slice. The third column presents the difference between these two approaches. After calibration for BSA, the volume results are given in units per square meter. The mean heart rate during image acquisition was 57 ± 9 beats/min.

For all parameters, the difference between inclusion and exclusion of the basal slice was highly significant ($p < 0.001$). Also, the magnitude of the difference, expressed as percentage of the exclusion data, was considerable. This relative difference was +19% for EDV, +29% for SV, and +29% for CO. For the EF, the difference between inclusion and exclusion was +6%.

DISCUSSION

In earlier reports on healthy subjects, a mean longitudinal shortening of the LV of 12 mm was found during systole (7). In our study, the SA images were acquired at 10-mm slice distance. This explains why at least one more slice is needed at ED than at ES to encompass the whole LV.

It seems likely that in earlier studies the most basal slice was not included. Sechtem et al. (9) reported an EDV index in normal subjects of 57 ± 9 ml/m², and

Soldo et al. (10) reported an EDV index of 59 ± 10 ml/m². This compares well with our EDV index, excluding the basal slice, of 60 ± 11 ml/m².

The impact of the most basal slice on the LV parameters, as shown in Table 1, is considerable. Conventions on dealing with this basal slice are thus required for differentiating accurately between dysfunction and normal function and also for comparing results between different MRI centers. These conventions should focus on MRI acquisition and on postprocessing.

MRI Acquisition

Imaging should start with acquiring a breathhold cine in the horizontal LA view (a cine in the vertical LA view may be as useful). The planning of the stack of parallel SA cine images should then be implemented on the ED cine frame of the LA view, starting close to the transition of LV myocardium to the mitral valve leaflets (at a distance of half the slice thickness). Breathhold command and temporal resolution should be identical in the LA and SA acquisitions.

The SA slice distance in our study was 10 mm. Near the base of the heart, where it is very critical whether or not to accept an imaged slice as part of the LV, the accuracy may be further improved by choosing a smaller slice thickness and smaller slice distance. However, more SA image planes are then necessary, resulting in a longer investigation time.

Postprocessing of the Most Basal Slice

The proper handling of the most basal slice in ES may be hampered by suboptimal contrast between blood pool and the heart wall at this location. Also, partial volume effects of the mitral valves, the LV outflow tract, and the left atrium may contribute to problems in interpretation. Some criteria for considering the basal slice in ES as *not* being part of the LV may be the lack of wall thickening or the recognition of the left atrial wall because of its thin appearance. Probably the best decisive cue is given by the projection line of the most basal image plane onto the ES frame of the LA cine. This application of the LA view is most accurate, when breathhold command and temporal resolution are identical for the LA and SA acquisition.

With regard to clinical applications, the longitudinal shortening of the LV should *not* be an a priori assumption. After myocardial infarction, this shortening can be smaller (e.g., only 5.5 mm total displacement in the ante-

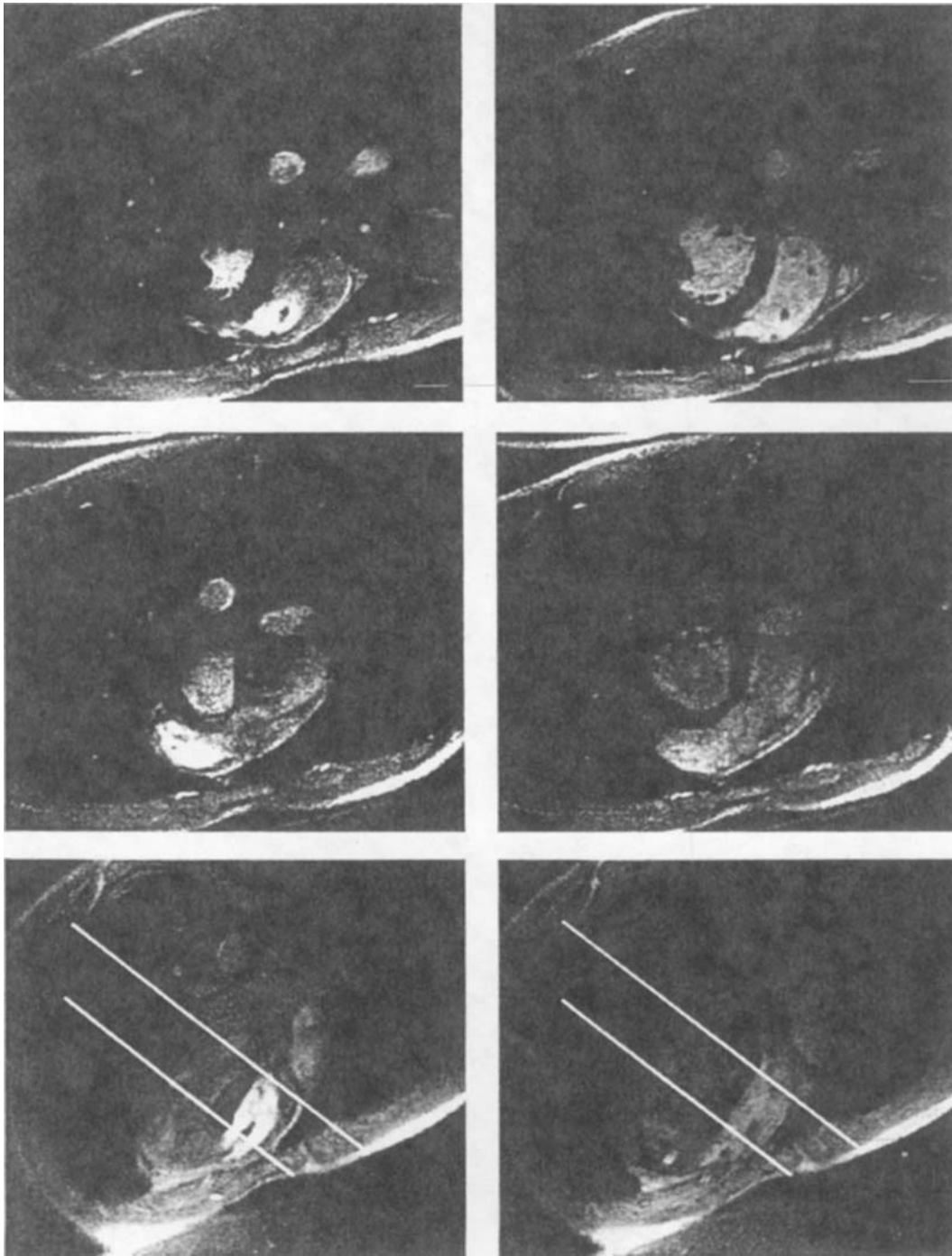


Figure 1. Top: Horizontal long-axis view. Middle and bottom: Short-axis views at basal and mid levels, respectively. Left, Views at end diastole; right, views at end systole (280 msec after the R-wave trigger). The lines on the long-axis views represent the projections of the basal and the mid short-axis image planes onto the long-axis image plane.

Table 1

Left Ventricular EDV, SV, EF, and CO

	Exclusion Basal Slice	Inclusion Basal Slice	Inclusion – Exclusion
EDV (ml)	113 ± 26	134 ± 29	21 ± 4
EDVi (ml/m ²)	60 ± 11	71 ± 11	11 ± 2
SV (ml)	72 ± 16	93 ± 18	21 ± 4
SVi (ml/m ²)	38 ± 7	49 ± 7	11 ± 2
EF (%)	64 ± 4	70 ± 4	6 ± 1
CO (l/min)	4.1 ± 1.1	5.3 ± 1.4	1.2 ± 0.3
CI [(l/min)/m ²]	2.2 ± 0.6	2.8 ± 0.6	0.6 ± 0.1

Data from 57 subjects with exclusion and with inclusion of the most basal short-axis slice. Inclusion – Exclusion denotes the difference between the inclusion and exclusion results. The data indexed for BSA are given per m² and denoted by EDVi, SVi, and CI (CI is cardiac output, indexed for BSA). Values are means ± SD.

rior basal region after an infarct related to the left anterior descending coronary artery [11]).

LV Regions near the Mitral and Aortic Valves

It is possible that at the basal end of the LV, there is an SA slice that partly contributes to LV volume and partly to left atrial volume because of the shape of the mitral valve plane. In these cases, the projection line of this SA slice onto the corresponding temporal frame of the LA cine may provide a cue for quantifying the partial contribution to the LV volume. Another potential problem is the handling of a small region of the LV volume below the aortic valves, which is omitted so far.

To overcome these problems near the mitral and aortic valves, Bloomgarden et al. (12) acquired radially distributed LA images (“rotating planes”) to provide better definition of the valve planes. However, it is difficult to define the LV LA in cases of deformed LVs. Another disadvantage of the LA images is the poorer contrast (as compared with SA views) between myocardium and blood because of less through-plane blood flow.

CONCLUSIONS

Because of the longitudinal shortening of the LV during systole, usually one more SA image plane is needed at ED than at ES for a complete coverage of the LV. Neglecting this most basal slice would result in a considerable underestimation of the EDV, SV, EF, and CO.

In the MRI acquisition of a stack of parallel SA images, the most basal SA image plane should be positioned

on the ED frame of a breathhold LA cine series as close as half a slice thickness near the transition of LV myocardium to the mitral valve leaflets. In judging whether or not to consider the basal SA ES frame as a part of the LV, the anatomical information of this ES frame should be used. If this anatomy is not clear enough, then the projection line on the ES frame of the LA cine should be decisive.

ACKNOWLEDGMENT

The MASS software package was kindly provided by Rob J. Van der Geest, MSc, and Prof. J. H. C. Reiber, PhD, Leiden University Medical Centre, Dept. of Radiology, Div. of Image Processing, Leiden, The Netherlands.

REFERENCES

1. White HD, Norris RM, Brown MA, Brandt PWT, Whitlock RML and Wild CJ. Left ventricular end-systolic volume as the major determinant of survival after recovery from myocardial infarction. *Circulation*, 1987; 76: 44–51.
2. Van Rossum AC, Visser FC, Sprenger M, Van Eenige MJ, Valk J and Roos JP. Evaluation of magnetic resonance imaging for the determination of left ventricular ejection fraction and comparison with angiography. *Am J Cardiol*, 1988; 62:628–633.
3. Cranney GB, Lotan CS, Dean L, Baxley W, Bouchard A and Pohost G. Left ventricular volume measurement using cardiac axis nuclear magnetic resonance imaging: Validation by calibrated ventricular angiography. *Circulation*, 1990; 82:154–163.

4. Mogelvang J, Lindvig K, Sondergard L, Saunamaki K and Hennedriksen O. Reproducibility of cardiac volume measurements including left ventricular mass determined by MRI. *Clin Physiol*, 1993; 13:587-597.
5. Van der Geest RJ, de Roos A, van der Wall EE and Reiber JHC. Quantitative analysis of cardiovascular MR images. *Int J Card Im*, 1997; 13:247-258.
6. Pattynama PMT, Doornbos J, Hermans JO, Van der Wall EE and De Roos A. Magnetic resonance imaging evaluation of regional left ventricular function: Effect of through-plane motion. *Invest Radiol*, 1992; 27:681-685.
7. Rogers WJ, Shapiro EP, Weiss JL, Buchalter MB, Rademakers FE, Weisfeldt ML and Zerhouni EA. Quantification of and correction for left ventricular systolic long axis shortening by magnetic resonance tissue tagging and slice isolation. *Circulation*, 1991; 84:721-731.
8. Marcus JT, Vonk Noordegraaf A, De Vries PMJM, Van Rossum AC, Roseboom G and Heethaar RM. MRI protocol for evaluation of the right ventricular function in chronic obstructive pulmonary disease. In *Proceedings of the 4th Meeting of ISMRM*. New York, 1996, p. 142.
9. Sechtem U, Pflugfelder PW, Gould RG, Cassidy MM and Higgins CB. Measurement of right and left ventricular volumes in healthy individuals with cine MR imaging. *Radiology*, 1987; 163:697-702.
10. Soldo SJ, Norris SL, Gober JR, Haywood LJ, Colletti PM and Terk M. MRI-derived ventricular volume curves for the assessment of left ventricular function. *MRI*, 1994; 12:711-717.
11. Marcus JT, Götte MJW, Van Rossum AC, Kuijjer JPA, Heethaar RM, Axel L and Visser CA. Myocardial function in infarcted and remote regions early after infarction in man: Assessment by magnetic resonance tagging and strain analysis. *Magn Res Med*, 1997; 38:803-810.
12. Bloomgarden DC, Fayad ZA, Ferrari VA, Chin B, Sutton MG and Axel L. Global cardiac function using fast breathhold MRI: Validation of new acquisition and analysis techniques. *Magn Res Med*, 1997; 37:683-692.