

PERFUSION/HYPERAEMIA

Assessment of Reactive Hyperaemia Using Real Time Zonal Echo-Planar Flow Imaging

Raad H. Mohiaddin,^{1,*} Peter D. Gatehouse,¹ James C. C. Moon,¹ Mohammed Youssuffidin,² Guang Z. Yang,³ David N. Firmin,¹ and Dudley J. Pennell¹

¹Cardiovascular Magnetic Resonance Unit and ²Department of Cardiology Unit, Royal Brompton Hospital, Sydney Street, London SW3 6NP, UK

³Department of Computing, Imperial College of Science, Technology and Medicine, London, UK

ABSTRACT

The measurement of limb blood flow at rest and during reactive hyperaemia has potential as a marker of vascular health and endothelial function because it is the stimulus that causes flow-mediated dilatation, commonly measured as brachial arterial reactivity. Because the flow increases are short lived, they represent a significant challenge for measurement by cardiovascular magnetic resonance. In this study we used a real time, single shot zonal echo-planar imaging method (ZEPI) to study reactive hyperaemia in the femoral artery of five healthy volunteers. Flow velocity was measured every 78 msec. Changes in peak forward flow velocity during systole (580 vs. 390 mm/sec, $p < 0.01$) and minimum flow velocity (160 vs. 100 mm/sec, $p < 0.01$) were shown. With progressing improvement in spatial resolution, this technique will allow the accurate noninvasive determination of total flow, flow profile, and peak velocities in real time.

Key Words: Real time; Blood flow; Echo-planar imaging

INTRODUCTION

Changes in peripheral blood flow following occlusion of blood supply to a limb for a limited time (reactive

hyperaemia) or in response to the infusion of vasoactive agents indicate peripheral vasoregulation. Peripheral vasoregulation is mediated, in part, by the vascular endothelium. Endothelium-dependent vasoregulation is

*Corresponding author. Fax: 44 207 351 8816; E-mail: r.mohiaddin@rbh.nthames.nhs.uk

impaired in the presence of risk factors for coronary artery disease even before the clinical manifestations of atherosclerosis and changes occur in other pathological states such as heart failure and hypertension. Peripheral blood flow and the associated flow mediated dilatation reflect coronary and overall vascular health (1). Venous occlusion plethysmography is the most commonly used technique for measuring peripheral blood flow, but it has a number of limitations (2). We were interested in determining whether cardiovascular magnetic resonance (CMR) could be used for the assessment of this phenomenon. Although reactive hyperaemia itself lasts sufficiently long for segmented FLASH studies, there may be much more rapid variation of velocity waveforms during this time. In this study, we applied the ultrafast technique of zonal echo-planar imaging (ZEPI) (3) to study the reactive hyperaemic response in the femoral artery of healthy volunteers.

MATERIALS AND METHODS

Five healthy male volunteers were studied (age range 27–55 years) using a Picker Edge 1.5 T scanner (Cleveland, OH) (gradients: peak 27 mT/m, slew rate 72 mT/m/msec) with ECG gating and an 8 cm diameter circular surface coil. The subjects were placed in the magnet with a pressure cuff placed around the right thigh. During inflation, the cuff was pressurised to 250 mmHg for 5 min. Multiple gradient echo images were initially acquired for localization, followed by ZEPI flow measurement in a plane perpendicular to the femoral artery (Fig. 1).

Each ZEPI image used a 2D-selective RF pulse for 30° excitation of a Gaussian profile 10 mm full width half maximum (FWHM) thick by 30 mm FWHM height, to become the slice-select and phase-encode directions of the EPI image. The 2D-selective RF pulse might be understood by first reconsidering the method of the ordinary slice-selective RF pulse. Recalling the link between magnetic field gradient–time product (area, or zero moment) and spatial frequencies within the patient, a typical sinc-shaped slice-selective pulse excites the spatial frequencies along the slice-select axis in the proportions suitable to form a rectangular slice profile by their superposition. The 2D-selective pulse extends this principle by applying gradients in two directions as the RF pulse proceeds (4,5), enabling it to excite spatial frequencies in two dimensions and, therefore, excite a cylindrical region rather than a plane. This procedure must complete rapidly to be robust with respect to off-resonance errors. For this ZEPI application, the cylinder

had a rectangular cross-section of 10 mm × 30 mm, with its axis along the same direction as the EPI readout gradient; the 10 mm dimension could be achieved only by using the EPI-type path for the 2D-selective pulse as well as the imaging readout. Furthermore, a forward-echo-only EPI path was necessary for the 2D-RF pulse to perform reliably in oblique planes (5,7).

By exciting only the 30 mm narrow zone instead of a whole slice, the phase-encode field of view (FOV) could be reduced to less than whole-body size with only very faint wraparound artefacts (4,5), while the reduction in number of phase-encode steps permitted a trade-off of reducing overall image time against slowing the EPI readout waveform for smaller readout pixels. This work used a 22-echo single-shot EPI acquisition with 32 cm FOV in the frequency-encode direction along the axis of the 2D-RF pulse and 4 cm FOV in the phase-encode direction (6) (Figs. 2 and 3). The acquired data resolution was 1.5 mm along the frequency-encode and 1.8 mm along the phase-encode direction; although this is a high resolution for single-shot imaging, its limitations are pointed out in the Discussion. Each 2D-selective RF pulse was preceded by a chemical-shift selective fat saturation pulse to avoid chemical shift artefacts. The repetition time was 78 msec, with 6–10 images per cardiac cycle depending on R–R interval. Gradient performance rather than signal-to-noise ratio or data-handling limitations prevented faster repetition. Reference images were acquired before inflation of the cuff and velocity-encoded images (1 m/sec velocity sensitivity along the slice-select axis) as follows: 10 cycles before cuff inflation (baseline), 10 cycles with cuff inflated, 40 cycles immediately after release of the cuff, and 10-cycle batches every minute thereafter for 5 min. The

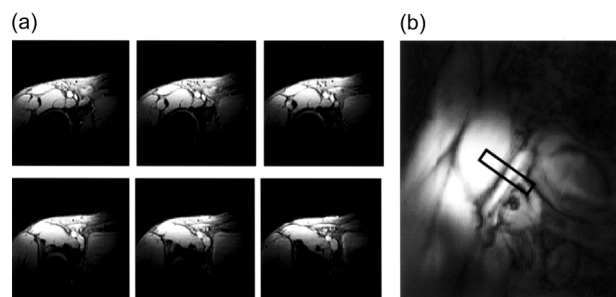


Figure 1. (a) Transverse gradient-echo multislice pilot images used for 3-point piloting to obtain (b) an inplane image of the femoral artery, from which a plane for ZEPI flow measurement perpendicular to the femoral artery is derived. The black rectangle represents the 10 mm × 40 mm cross-section of the ZEPI imaging.

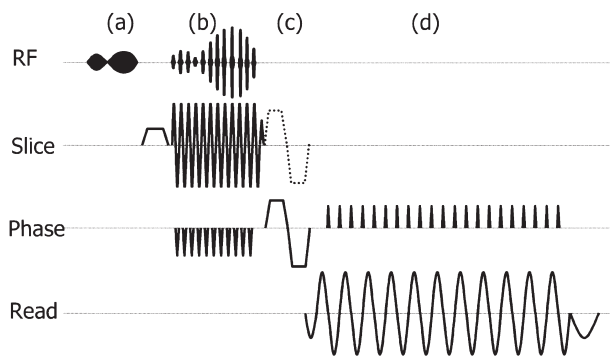


Figure 2. The zonal EPI pulse sequence. (a) Chemical-shift selective fat saturation and dephase pulse. (b) 2D-RF pulse selecting 10 mm × 30 mm using forward-only design for robustness. (c) Velocity-encoding (dotted line) added on slice-select axis during velocity measurement images only, concurrent with phase-encode dephasing velocity-compensated for the time of central *k*-space acquisition. (d) EPI data acquisition.

reference phase images were subtracted from the velocity-encoded phase images to obtain the phase velocity maps, which were further corrected (see Discussion) by the manual positioning of static reference points (Fig. 4). The protocol was approved by the local ethics committee, and informed consent was obtained from all subjects. As explained further in the Discussion, the application of a single ROI around the femoral artery, without moving or resizing during the intervals in the imaging, was used for all of the velocity maps of each volunteer.

Results are expressed as mean ± SD. Velocities were compared using the Student's *t*-test.

RESULTS

Following the release of the pressure cuff, the time-related velocity curves in the femoral artery were markedly

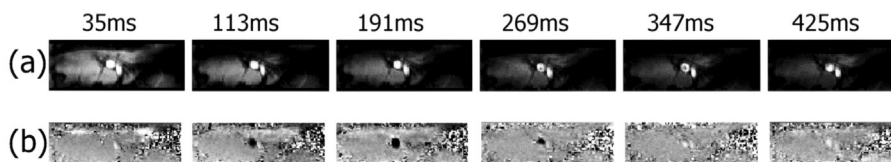


Figure 4. Real-time zonal EPI images from one cardiac cycle (above: delay from R-wave to velocity-encoding). The artery has a circular cross-section, and the oval vein lies adjacent. (a) Magnitude images: the drop in blood signal in the last frames may be caused by diastolic reverse flow returning saturated blood to the image plane. Piloting of the plane perpendicular to the vessel ensured minimal blood signal loss or distortion during systole. (b) Velocity images: midgrey = 0 cm/sec, with through plane velocities shown darker (− 1 m/sec = black) and brighter (+ 1 m/sec = white). Systolic forward arterial flow (black) reverses in diastole (white), with steadier venous return flow (faint white).

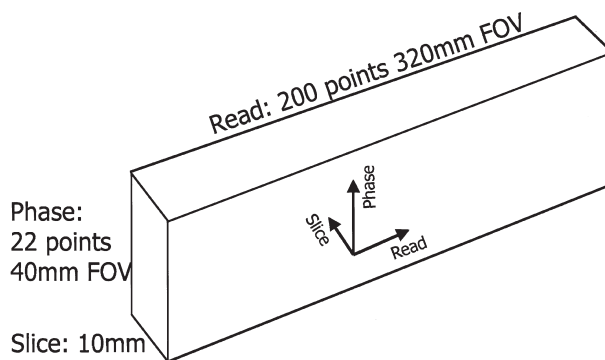


Figure 3. Each EPI image covered a 320 mm × 40 mm × 10 mm FOV with 200 × 22 acquired data points, reconstructed as 256 × 64 image pixels. The use of a 2D-RF selection rather than conventional slice selection enabled this narrow zonal imaging matrix with zeroed wraparound artefacts.

different from baseline (Fig. 5). Considerable increases in peak forward flow velocity during systole (580 ± 100 mm/sec vs. 390 ± 70 mm/sec, $p < 0.01$) and minimum flow velocity during diastole (160 ± 40 mm/sec vs. -100 ± 60 mm/sec, $p < 0.01$) were recorded. The diastolic flow velocity following the deflation of the cuff was always positive (forward), while at baseline was always negative (backward). The mean increase in peak systolic and minimum diastolic flow velocities were 190 ± 80 mm/sec and 260 ± 80 mm/sec, respectively.

DISCUSSION

We have applied a single-shot ZEPI real-time technique for peripheral blood flow and velocity measurement and demonstrated the feasibility of studying the reactive hyperaemic response. The CMR increasingly is being used clinically for peripheral angiography, and this technique demonstrates its potential for real-time peripheral

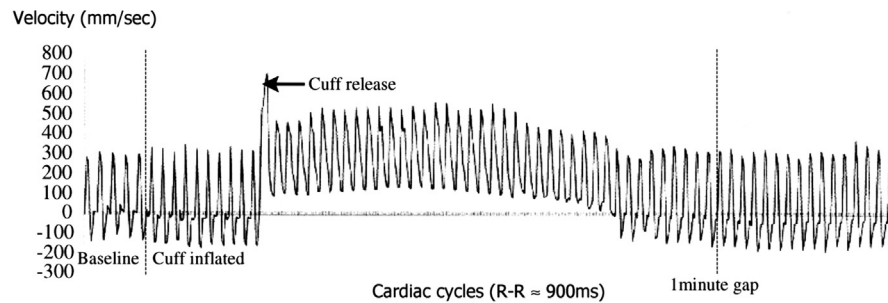


Figure 5. Mean velocity in real-time shown graphically for 72 cardiac cycles. The first five cardiac cycles are before cuff inflation. Imaging was suspended for cuff inflation and a 5 min delay. The next 10 cycles were acquired with the cuff inflated and show a shorter forward peak (i.e., reduced forward flow) in the waveform although the peak velocity does not reduce. The occlusion cuff was placed >10 cm distal to the imaging plane. Please note the increased reverse flow during the occlusion. After the release of the cuff, the forward peak is longer and the reverse flow changes to forward flow. Both effects recover to the baseline after approximately 40 sec.

hemodynamic assessment. Evaluation of reactive hyperaemia by CMR has been demonstrated but the techniques used were slow, requiring up to 25 sec for each flow measurement, which is too long for examination of the acute response (8). The method used in this report obtains a velocity measurement every 78 msec and, therefore, is much more suitable for measurement of short-lived physiological changes such as reactive hyperaemia. The change of flow features following the release of obstruction described in this study is well known and reflects the changes in the peripheral resistance of the femoral artery vascular bed. Changes in flow rate can be computed from arterial cross sectional area and mean velocity. However, accurate measurement of small changes in the cross-sectional area would be difficult at the current $1.8 \text{ mm} \times 1.5 \text{ mm}$ spatial resolution of ZEPI, and the technique awaits expected improvements in gradient performance in order to improve spatial resolution for accurate measurement of dilatation and flow. Alternatively, the technique has the potential to be combined with segmented FLASH imaging with the same surface coil to assess arterial cross-sectional area changes (9) and, hence, arterial reactivity on a longer timescale than zonal EPI. Thus, CMR could be used for a complete assessment of the stimulus, flow, and the arterial dilatation reactivity. With repeat measurement after vasoactive agents such as glyceryl trinitrate (GTN), nitric oxide dependent and independent vasodilation and, hence, endothelial function could be derived.

There was a risk of movement during the delay between acquiring the reference phase images and the velocity-encoded images in this work. In the volunteer imaging, no motion occurred and no type of image reregistration was implemented during the phase-image subtraction. Faster imaging performance and more

flexible sequence programming environments should permit reference and velocity-encoded images to be interleaved more closely in time, and eliminate this risk.

Background phase correction was similar to that of conventional field-echo velocity mapping, and there were no particular trade-offs required by the zonal EPI approach: phase errors in the velocity images were assessed using regional measurements over tissues known to be stationary, in this situation the thigh muscles, followed by linear interpolation over the entire FOV and subtraction from the blood flow velocity image (obtained by subtracting the reference phase images from the velocity-encoded phase images). The proximity of the small surface coil gave a high SNR for the ZEPI technique. Piloting of the ZEPI image to be perpendicular to the flow was important in order to minimize flow-related signal loss.

CONCLUSION

The feasibility of assessing reactive hyperaemic response in real time using single-shot ZEPI has been demonstrated. Further improvement of spatial and temporal resolution is required in particular to reduce the effects of residual temporal blurring of velocities within the 78 msec acquisition window and is expected with improved gradient performance.

ACKNOWLEDGMENTS

This work was supported by the Wellcome Trust and by CODA, the heart charity. JCCM is supported by an unrestricted grant from SmithKline Beecham.

REFERENCES

1. Rosenberger, G.; Fichtlscherer, S. Analysis of Forearm Circulation—A Substitute for Diagnosis of Coronary Atherosclerosis? *Herz* **1998**, *23*, 130–134.
2. Corbally, M.T.; Brennan, M.F. Noninvasive Measurement of Regional Blood Flow in Man. *Am. J. Surg.* **1990**, *160*, 313–321.
3. Hardy, C.J.; Cline, H.E. Broadband NMR Pulses with Two-Dimensional Spatial Selectivity. *J. Appl. Phys.* **1989**, *66*, 1513–1516.
4. Feinberg, D.A.; Hoenninger, J.C.; Crooks, L.E.; Kaufman, L.; Watts, J.C.; Arakawa, M. Inner Volume MR Imaging: Technical Concepts and Their Application. *Radiology* **1985**, *156* (3), 743–747.
5. Feinberg, D.A.; Turner, R.; Jakab, P.D.; von Kienlin, M. Echo-Planar Imaging with Asymmetric Gradient Modulation and Inner-Volume Excitation. *Magn. Reson. Med.* **1990**, *13* (1), 162–169.
6. Heid, O. Fourier Spliced Pencil Imaging. Proceedings of the 3rd Annual Meeting of SMR, 1995; 488.
7. Yang, G.Z.; Gatehouse, P.D.; Keegan, J.; Mohiaddin, R.H.; Firmin, D.N. Three-Dimensional Coronary MR Angiography Using Zonal Echo Planar Imaging. *Magn. Reson. Med.* **1998**, *39*, 833–842.
8. Silber, H.A.; Bluemke, D.A.; Ouyang, P.; Du, Y.P.; Post, W.S.; Lima, J.A.C. A Novel Technique for Assessing Endothelial Function: Phase Contrast Magnetic Resonance Angiography. *J. Cardiovasc. Magn. Reson.* **1999**, *1*, 382–383, (Abstract).
9. Sorensen, M.; Ong, P.; Hayward, C.S.; Webb, C.M.; Gatehouse, P.D.; Collins, P.; Pennell, D.J. Gradient Echo Magnetic Resonance Imaging of the Brachial Artery: A Novel Method for Assessing Vascular Reactivity. *Circulation* **1999**, *100* (Suppl), 1–49, (Abstract).

Received March 6, 2001

Accepted October 26, 2001