

VENTRICULAR FUNCTION

Evaluation of Myocardial Volume Heterogeneity During End-Diastole and End-Systole Using Cine MRI

Cory Swingen, Xiaoen Wang, and Michael Jerosch-Herold, Ph.D.*

Department of Radiology, University of Minnesota, Minneapolis, Minnesota, USA

ABSTRACT

The aim of this study was to examine the difference in the myocardial volume between end-diastole and end-systole in 24 human volunteers, using steady-state free precession gradient-echo cine imaging of both long- and short-axis views of the left ventricle and a newly developed three-dimensional (3D) analysis method. In addition, we examined retrospectively the cine magnetic resonance imaging (MRI) studies from 20 of the subjects that included a stack of short-axis views, from base to apex, suitable for a standard two-dimensional (2D) analysis. With the 3D analysis method, no significant variance in the myocardial volume was found (mean difference = $0.1\% \pm 9.1\%$, $p=0.88$) between end-diastole (ED) and end-systole (ES), while the 2D technique yielded significantly larger values for the LV myocardial volume at ES than ED (mean difference = $14.7\% \pm 16.8\%$, $p < 0.0001$). ED myocardial volumes correlated closely in subjects belonging to both groups (3D: 122.81 ± 27.58 mL vs. 2D: 129.0 ± 37.21 mL, $p=0.29$), while the 2D myocardial volumes were significantly larger at ES (3D: 123.01 ± 28.65 mL vs. 2D: 150.47 ± 47.29 mL, $p=0.002$). The findings of this study support the notion that myocardial volume does not change during the cardiac cycle and any discrepancies between muscle volume at ED and ES can be eliminated by exact tracking of the mitral valve plane over the cardiac cycle, using a generalized, 3D analysis method that includes long-axis views of the heart.

Key Words: Cine MRI; Left ventricle; Myocardial volume; 3D.

INTRODUCTION

The evaluation of cardiac mass is an important indicator for the diagnosis of various forms of congenital

and acquired heart disease (Goldstein et al., 1998) and for prognosis. Accurate and reproducible values of myocardial mass are also an important marker for the quantitative evaluation of responses to therapy through

*Correspondence: Michael Jerosch-Herold, Ph.D., Department of Radiology, University of Minnesota, Mayo Mail Code 292, 420 Delaware St. SE, Minneapolis, MN 5545, USA; E-mail: jeroschh@ohsu.edu.

serial assessments of the left ventricle (LV) (Anand et al., 2002a; Pfeffer and Braunwald, 1990; Senior et al., 1999). Cine MRI represents one of the most accurate methods for the assessment of left ventricle (LV) myocardial volume, providing mass estimates accurate to within 5% of the true value (Florentine et al., 1986; Keller et al., 1986; Shapiro et al., 1989; Shors et al., 2004; Wiesmann et al., 1998). This widely accepted technique involves multiple cine acquisitions of short-axis slices from the atrioventricular ring to the apex, followed by the segmentation of the endocardial and epicardial borders in the end-diastolic (ED) and end-systolic (ES) frame. This method is sufficient for estimates of the global function of the LV, as well as the myocardial volume at both ED and ES time points in the cardiac cycle. With two, or multiple, measurements of the LV mass during different phases of the cardiac cycle, a decision must be made as to which value (ED or ES mass) should be reported, if not both, or even an average. The appropriate choice depends on the underlying physiologic behavior of myocardium throughout the cardiac cycle. Many studies in human volunteers and patients have suggested there is a significant difference between the myocardial volume at ED and ES (Diethelm et al., 1989; Radtke, 1985; Wachspress et al., 1988; Yin et al., 1996), which has raised the hypothesis that the myocardial tissue is compressible. Other studies, however, have indicated that LV myocardial volume is preserved throughout systole and diastole (Fieno et al., 2002; Sacks and Chuong, 1993; Tsuiki and Ritman, 1980). In view of these uncertainties about the changes of myocardial volume over the cardiac cycle, a consensus opinion emerged that LV mass measurements are to be reported at ED (Pennell, 2002).

The goal of this study was to accurately evaluate the myocardial volume at multiple cardiac phases to test the hypothesis that this volume does not change significantly. For precise tracking of apex and mitral valve plane throughout the cardiac cycle, a newly developed 3D approach that incorporates both long- and short-axis views of the LV was used in this study. Ventricular volumes are determined from a 3D model of the heart, without use of Simpson's method, which involves summing the ventricular volumes in short-axis slices. Nevertheless, for comparison the same quantities

were also measured with the standard 2D technique involving only short-axis images.

METHODS

Patients

Twenty-four subjects (19 males, 5 females, age 66 ± 11 years) with no known or suspected cardiovascular disease were included in the study following written informed consent. Retrospectively, cine MRI studies of 20 subjects (17 males, 3 females, age 67 ± 10 years) from the first group were analyzed with the conventional 2D method for comparison.

Image Acquisition

The study was performed in a 1.5 T system (Magnetom Sonata, Siemens Medical Systems, Iselin, NJ) using a four-element phased-array coil with two anterior and two posterior coil elements. Cine MRI was acquired with an electrocardiographic (ECG) trigger during repeated breath-holds, using a segmented TrueFISP (Carr, 1958) sequence to achieve 16–20 images covering the entire cardiac cycle.

In twenty-four subjects, a cine-imaging protocol for a 3D analysis consisting of 2 long-axis views and 4–6 short-axis slices was performed. In this data set, referred henceforth to as "3D group," two slices were obtained per breath-hold, by using view sharing of k-space segments to maintain adequate temporal resolution, less than 40 ms. The cine MRI sequence parameters were the following: field of view (FOV) 265×340 mm², acquisition matrix 160×256 , slice thickness 8 mm, TR=3.14 ms, TE=1.57 ms, bandwidth per pixel=930 Hz, k-space lines per segment=24, breath-hold duration 10 seconds for 2 slices, or ~5 seconds per slice. Following acquisition of both long-axis cines, in the horizontal (HLA) and vertical (VLA) long-axis orientation, pairs of short-axis cines (4–6 slices total) were acquired covering the central 2/3 of the ventricle, omitting the base and apex.

A retrospective analysis of cine MRI studies was performed for a study group consisting of 20 subjects

Table 1. LV myocardial volume (mean \pm SD) with 95% confidence intervals.

Technique	ED myocardial volume (mL)	ES myocardial volume (mL)	<i>p</i> value
3D (<i>n</i> =24)	118.13 \pm 26.17 (107.65–128.59)	118.27 \pm 26.55 (107.64–128.89)	0.88
2D (<i>n</i> =20)	122.86 \pm 35.45 (107.32–138.39)	143.29 \pm 45.04 (123.55–163.03)	<0.0001

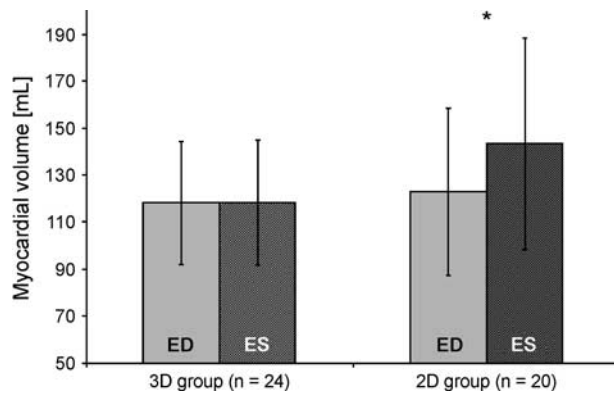


Figure 1. Bar graphs displaying the average LV myocardial volume \pm SD at ED and ES phase for the analysis method using a 3D model (left) and the 2D method utilizing short-axis images only (right). The ES myocardial volume group marked with an **asterisk** is significantly ($p < 0.0001$) different from the corresponding ED measurement.

from the 3D group. The mean time between studies was 11 ± 3 months. In this group a contiguous stack of 10–12 short-axis slices (one slice per breath hold) was acquired from the LV base to apex, using the same MRI cine protocol. We refer to this group as “2D-group.”

Image Analysis

Two-dimensional analysis was completed on a PC Linux workstation using the MASS version 4.2

software (MEDIS Medical Imaging Systems, Leiden, The Netherlands). Consistent with the standard method for determining LV volumes from contiguous short-axis cines (Lorenz et al., 1999; Pennell, 2002), endo- and epicardial contours were manually drawn in all images containing LV. The basal slice was carefully selected at both ED and ES to avoid the inadvertent inclusion of atrial tissue or volume in the measurement of the LV parameters.

Three-dimensional analysis was performed with a custom-written cardiac MR analysis program, CARMA (University of Minnesota, Minneapolis, MN, USA), on a PC workstation running in the MATLAB (MATLAB release 12.1, The Mathworks, Natick, MA) environment. Using this technique, contours were created in the images using editable user-placed guide points (Young et al., 2000). Guide points were placed along the endo- and epicardial borders in the short-axis images and long-axis images up to the mitral valve position, to ensure complete coverage of the LV from base to apex during each cardiac phase, and to account for systolic motion of the atrioventricular ring. Three-dimensional models of the LV were constructed from these contours, and the volumes of the LV were calculated from the model, as described previously (Swingen et al., 2003).

In all cases, and for both methods, myocardial volume was calculated at ED and ES phases. In five subjects from the 3D group, myocardial volumes were measured at each cardiac phase between ED and ES. Papillary muscle was included in the myocardial volume and excluded from the blood pool in both

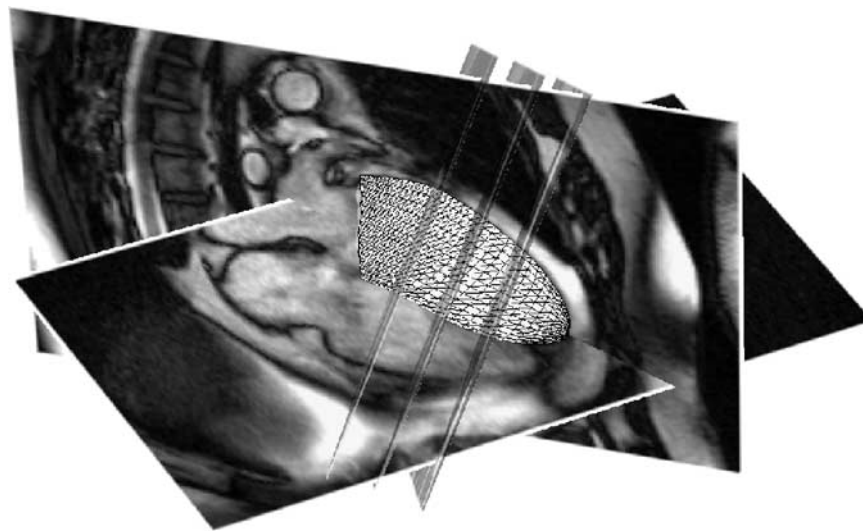


Figure 2. Set of TrueFISP slices using the 3D analysis protocol with co-registered long- and short-axis images (3 of 6 short-axis images shown for clarity) analyzed using 3D model of the LV.

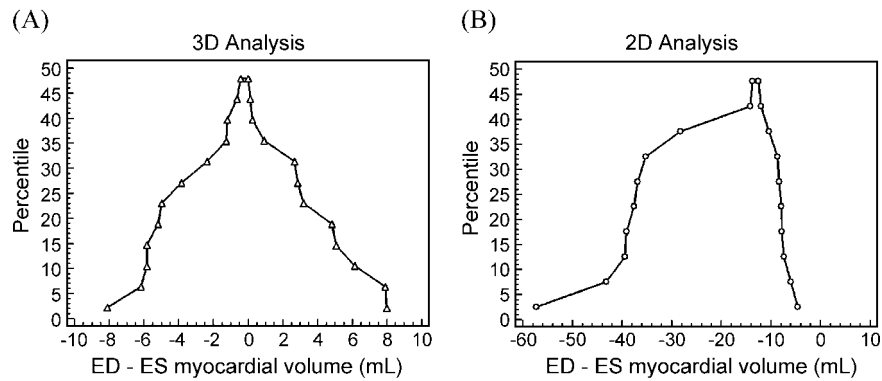


Figure 3. Mountain plots of myocardial volume difference [mL] at ED and ES for (A) the 3D analysis method and (B) 2D technique which shows a clear bias towards larger myocardial volumes measured during ES.

analysis methods for the most accurate determination of myocardial volume (Francois et al., 2004).

Statistical Analysis

All values of myocardial volume were presented as mean \pm SD. A paired two-tailed Student's T-Test and Bland-Altman analysis were used to examine the differences between the myocardial volume at ED and ES. A p -value of less than 0.05 was considered to indicate a significant difference. The differences between myocardial volumes were also plotted as cumulative distribution, or "mountain" plots, to observe the distribution of the ranked differences in the myocardial volume at ED and ES (Krouwer and Monti,

1995). Cumulative distribution plots were created from each group for the comparison of both methods.

RESULTS

The calculated values for the myocardial volumes at ED and ES are summarized for both techniques in Table 1 and Fig. 1. The ED and ES myocardial volumes values were markedly different in the 2D group, with the ES myocardial volume 14% greater than the ED myocardial volume ($14.7\% \pm 16.8\%$, $p < 0.0001$). No significant difference was seen in the myocardial volumes for ES and ED in the 3D group ($0.1\% \pm 8.0\%$, $p = 0.88$). Figure 2 shows a representative

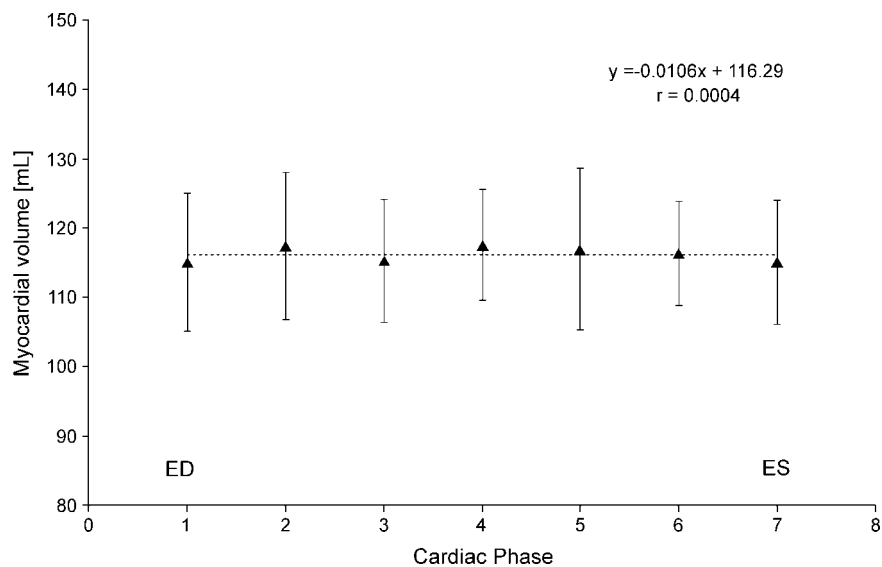


Figure 4. Average myocardial volume throughout the cardiac cycle, illustrated in 5 subjects imaged with the 3D technique.

image data set acquired in this study for the 3D group consisting of two long-axis images and a small stack of short-axis images covering the mid-ventricular region and the 3D model constructed from the contours for these images. From the volunteers belonging to both the 3D and 2D groups, there was no significant difference in myocardial volume at ED (3D: 122.81 ± 27.58 mL vs. 2D: 129.0 ± 37.21 mL, $p=0.29$), while at ES the myocardial volume was considerably larger in the 2D group (3D: 123.01 ± 28.65 mL vs. 2D: 150.47 ± 47.29 mL, $p=0.002$).

Mountain plots were used to examine the distribution of the myocardial volume differences for each case. Figure 3A reveals that the difference between the ED and ES myocardial volumes for the 3D group is uniformly distributed around zero; it can be seen in the 2D group (Fig. 3B) the ES volume was greater than the ED volume in all cases. Approximately half of all subjects in the 2D group had ES myocardial volumes at least 10 ml larger than at ED. The variation in myocardial volume during phases of the cardiac cycle between ED and ES is shown in Fig. 4, for five of the subjects imaged using the 3D protocol, illustrating the constancy of the myocardial volume during contraction of the cardiac muscle. The difference in myocardial volume at each phase was not significant compared to ED and linear regression analysis showed there was no correlation between myocardial volume and cardiac phase number ($r=0.0004$, 95% CI for linear coefficient = -0.76 to 0.74 , $p=0.96$).

DISCUSSION

LV mass is an important clinical parameter for the assessment of cardiovascular disease and remodeling (Anand et al., 2002b). This underscores the need for accurate measurements of myocardial volume, which has proven feasible with cine MRI (Fieno et al., 2002). In this study, we found that the measured volume of the LV, during ED and ES, in human subjects varied by less than 1% with no statistical difference using a new 3D analytical approach. In contrast, however, we found that the standard and widely accepted 2D measurement of myocardial volume was significantly greater (15%) during ES than ED.

The limited number of short-axis slices (Radtke, 1985; Shors et al., 2004; Wiesmann et al., 1998) acquired during routine clinical scans may preclude the accurate measurement of LV myocardial volumes, particularly during ES, when the position of the mitral valve plane may be difficult to track on short-axis views, and a short-axis slice at the base may easily

encompass same partial atrial volume (Lorenz et al., 1999; Pennell, 2002). In a study by Fieno et al. (2002), comparison of postmortem LV mass to computed values using the True-FISP cine imaging showed that systolic images provided the most accurate results, although as many as 18 short-axis slices were acquired to minimize partial volume effects near the mitral valve plane. To achieve this accuracy in the clinical setting would require significantly more scanning time, as well as analysis time. It is current clinical practice to report LV mass as measured during the ED phase. Our observations between the 3D and 2D analysis groups from this study indicate that myocardial volumes do not change significantly between ED and ES, if the mitral valve plane and the apex are tracked accurately by including long-axis views in the analysis. It is also possible with the 2D method to force agreement between myocardial volumes at ED and ES by including or excluding slices at the base of the heart that may include some partial atrial volume. We have learned through personal communications from some cardiac MRI investigators that this practice is not uncommon, but in our view it does not represent a satisfactory solution.

The 3D approach overcomes many of the problems associated with the short-axis, multislice approach. Most importantly, the crucial positions of the mitral valve and the apex are clearly defined by the long-axis images and reproduced with the 3D model at each time point during the cardiac cycle. This benefit means that the analysis results become less observer-dependent and the analysis is more rapid, while at the same time one can forgo the requirement to scan the entire length of the heart with short-axis slices. Additionally, as shown previously (Swingen et al., 2003), this 3D method eliminates any problems resulting from incorrect angulations of the short-axis slices, an added advantage when easily reproducible techniques are increasingly important to determine the efficacy of drug and surgical therapies. During repeated studies using only short-axis cuts, the orientation and positioning of the short-axis slices are essential to achieve the most reliable and reproducible results, so any inconsistencies would otherwise degrade the effectiveness of monitoring by MRI.

While the 3D method is suitable for a wide variety of ventricular shapes and irregularities, remarkable deformities may yield inaccurate results due to the inherent surface interpolation involved. In such cases, the 3D model will have to be refined by including a greater number of short-axis slices in the analysis.

The 3D analysis used in the study indicates that the myocardial volume remains approximately constant

over the cardiac cycle. Therefore, the results of this study are consistent with the notion that myocardium is, within the measurement accuracy of cine MRI, incompressible. The observations from this study do not exclude the possibility that myocardium is regionally compressed, for example, in the subendocardial layer, which could have important implications for the phasic variation of myocardial blood flow.

Based on the findings in this study, we conclude that the myocardial volume of the LV at end-diastole and end-systole is the same, and this agreement should be taken into consideration during routine analysis of cine studies of cardiac function.

ACKNOWLEDGMENTS

This work was supported in part by R01 HL65394-01 from the National Heart, Blood and Lung Institute (NIH/NHLBI).

REFERENCES

- Anand, I. S., Florea, V. G., Fisher, L. (2002a). Surrogate end points in heart failure. *J. Am. Coll. Cardiol.* 39(9):1414–1421.
- Anand, I. S., Florea, V. G., Solomon, S. D., Konstam, M. A., Udelson, J. E. (2002b). Noninvasive assessment of left ventricular remodeling: concepts, techniques, and implications for clinical trials. *J. Card. Fail.* 8(6 Suppl.):S452–S464.
- Carr, H. Y. (1958). Steady-state free precession in nuclear magnetic resonance. *Phys. Rev.* 112(5):1693–1701.
- Diethelm, L., Simonson, J. S., Dery, R., Gould, R. G., Schiller, N. B., Lipton, M. J. (1989). Determination of left ventricular mass with ultrafast CT and two-dimensional echocardiography. *Radiology* 171(1):213–217.
- Fieno, D. S., Jaffe, W. C., Simonetti, O. P., Judd, R. M., Finn, J. P. (2002). TrueFISP: assessment of accuracy for measurement of left ventricular mass in an animal model. *J. Magn. Reson. Imaging* 15(5):526–531.
- Florentine, M. S., Grosskreutz, C. L., Chang, W., Hartnett, J. A., Dunn, V. D., Ehrhardt, J. C., Fleagle, S. R., Collins, S. M., Marcus, M. L., Skorton, D. J. (1986). Measurement of left ventricular mass in vivo using gated nuclear magnetic resonance imaging. *J. Am. Coll. Cardiol.* 8(1):107–112.
- Francois, C. J., Fieno, D. S., Shors, S. M., Finn, J. P. (2004). Left ventricular mass: manual and automatic segmentation of true FISP and FLASH cine MR images in dogs and pigs. *Radiology* 230(2):389–395.
- Goldstein, S., Ali, A. S., Sabbah, H. (1998). Ventricular remodeling. Mechanisms and prevention. *Cardiol. Clin.* 16(4):623–632. vii–viii.
- Keller, A. M., Peshock, R. M., Malloy, C. R., Buja, L. M., Nunnally, R., Parkey, R. W., Willerson, J. T. (1986). In vivo measurement of myocardial mass using nuclear magnetic resonance imaging. *J. Am. Coll. Cardiol.* 8(1):113–117.
- Krouwer, J. S., Monti, K. L. (1995). A simple, graphical method to evaluate laboratory assays. *Eur. J. Clin. Chem. Clin.* 33:525–527.
- Lorenz, C. H., Walker, E. S., Morgan, V. L., Klein, S. S., Graham, T. P. Jr. (1999). Normal human right and left ventricular mass, systolic function, and gender differences by cine magnetic resonance imaging. *J. Cardiovasc. Magn. Reson.* 1(1):7–21.
- Pennell, D. J. (2002). Ventricular volume and mass by CMR. *J. Cardiovasc. Magn. Reson.* 4(4):507–513.
- Pfeffer, M. A., Braunwald, E. (1990). Ventricular remodeling after myocardial infarction. Experimental observations and clinical implications. *Circulation* 81(4):1161–1172.
- Radtke, W. (1985). Myocardial imaging by digital subtraction angiography for left ventricular mass measurement. *Herz* 10(4):215–219.
- Sacks, M. S., Chuong, C. J. (1993). A constitutive relation for passive right-ventricular free wall myocardium. *J. Biomech.* 26(11):1341–1345.
- Senior, R., Basu, S., Kinsey, C., Schaeffer, S., Lahiri, A. (1999). Carvedilol prevents remodeling in patients with left ventricular dysfunction after acute myocardial infarction. *Am. Heart J.* 137(4 Pt. 1):646–652.
- Shapiro, E. P., Rogers, W. J., Beyar, R., Soulen R. L., Zerhouni, E. A., Lima, J. A., Weiss, J. L. (1989). Determination of left ventricular mass by magnetic resonance imaging in hearts deformed by acute infarction. *Circulation* 79(3):706–711.
- Shors, S. M., Fung, C. W., Francois, C. J., Finn, J. P., Fieno, D. S. (2004). Accurate quantification of right ventricular mass at MR imaging by using cine true fast imaging with steady-state precession: study in dogs. *Radiology* 230(2):383–388.
- Swingen, C., Seethamraju, R. T., Jerosch-Herold, M. (2003). Feedback assisted three-dimensional reconstruction of the left ventricle with MRI. *J. Magn. Reson. Imaging* 17:528–537.
- Tsuiki, K., Ritman, E. L. (1980). Direct evidence that

- left ventricular myocardium is incompressible throughout systole and diastole. *Tohoku J. Exp. Med.* 132(1):119–120.
- Wachspress, J. D., Clark, N. R., Untereker, W. J., Kraushaar, B. T., Kurnik, P. B. (1988). Systolic and diastolic performance in normal human subjects as measured by ultrafast computed tomography. *Cathet. Cardiovasc. Diagn.* 15(4):277–283.
- Wiesmann, F., Gatehouse, P. D., Panting, J. R., et al. (1998). Comparison of fast spiral, echo planar, and fast low-angle shot MRI for cardiac volumetry at .5T. *J. Magn. Reson. Imaging* 8(5):1033–1039.
- Yin, F. C., Chan, C. C., Judd, R. M. (1996). Compressibility of perfused passive myocardium. *Am. J. Physiol.* 271(5 Pt. 2):H1864–H1870.
- Young, A. A., Cowan, B. R., Thrupp, S. F., Hedley, W. J., Dell'Italia, L. J. (2000). Left ventricular mass and volume: fast calculation with guide-point modeling on MR images. *Radiology* 216(2):597–602.

Submitted October 18, 2003

Accepted April 7, 2004