

CORONARY ANGIOGRAPHY

A new approach for rapid assessment of the cardiac rest period for coronary MRA

COSIMA JAHNKE,^{1,2,*,#} INGO PAETSCH,^{1,#} KAY NEHRKE,³ BERNHARD SCHNACKENBURG,¹ AXEL BORNSTEDT,¹ ROLF GEBKER,¹ ECKART FLECK,¹ and EIKE NAGEL¹

¹Department of Internal Medicine/Cardiology, German Heart Institute Berlin, Germany

²Department of Cardiology, University of Freiburg, Germany

³Philips Research Laboratory, Hamburg, Germany

Background. Effective suppression of cardiac motion is crucial for MR coronary angiography (MRCA). Thus, we evaluated a new technique for rapid and automatic detection of the cardiac rest period in comparison to the conventional visual assessment of the coronary artery rest periods. **Methods.** One hundred and thirty-five consecutive cardiac patients were examined (Philips Intera CV 1.5 T, Best, The Netherlands). Visual assessment of the left and right coronary rest periods was done using a cine-SSFP scan with a transversal slice orientation (retrospective gating, 40 phases/cardiac cycle); the coronary rest period was defined as the duration of the coronary artery being completely within a region of interest placed on the outer edge of the cross-section of the vessel. Common coronary rest period as determined from visual assessment was defined as the intersection of both coronary artery rest periods. For comparison, an automatic technique was applied: using the position of the shim volume to define a correlation kernel, the cross-correlations of consecutive cine images were registered and displayed in a graph. Based on these cross-correlation values, the cardiac rest period was detected. The correlation between the visual and automated analysis was assessed. **Results.** A high correlation between the automatically and visually determined starting points for the coronary artery rest periods and the cardiac rest period was found. The automatically assessed cardiac rest period was significantly shorter in comparison to the visually assessed left and right coronary artery rest period (103 ± 46 ms vs. 158 ± 72 ms and 117 ± 52 ms, respectively; $p < 0.001$). However, the common coronary rest period demonstrated excellent agreement with the cardiac rest period ($r = 0.93$, $p < 0.001$) without a significant difference in duration (109 ± 52 ms vs. 103 ± 46 ms). **Conclusions.** Automated analysis of the cardiac rest period yielded similar results compared to the visual analysis. This rapid assessment of a cardiac acquisition window may be most helpful for MRCA, especially when aiming at 3-dimensional coverage of the whole coronary arterial tree during a single scan.

Key Words: Magnetic resonance coronary angiography; Cardiac rest period; Coronary motion

1. Introduction

One of the major problems of magnetic resonance coronary angiography (MRCA) is the effective suppression of coronary motion due to respiration and cardiac contraction. To compensate for cardiac movement, data acquisition is generally limited to the coronary artery rest period mainly found during mid-diastole. In order to minimize blurring and ensure complete “freezing” of the coronary vessels, a careful selection of the acquisition window during the cardiac cycle plays a pivotal role.

For routine MRCA, the rest periods of the left and right coronary arteries are either determined separately by visual assessment (1) or estimated from empirical, electrocardiogram-based formulas (2). The visual approach adapts to the individual patient and, thus, is more accurate when compared to a general formula (3); however, the visual analysis is somewhat subjective and time consuming. Most investigators have used separate imaging volumes for different parts of the coronary arterial tree (4) and optimized each acquisition to the rest period of each coronary artery. Yet, recent developments allow imaging of the whole coronary arterial tree within a single measurement (5, 6) with the necessity to use cardiac rather than single (left and right) coronary artery rest periods.

In a previous study, a calibration scan based on navigator echoes was introduced (3) allowing for an automatic detection of the rest period, but requiring a careful geometrical planning of the navigator position and, hence, additional user interaction. Additionally, the temporal resolution of the

Received 7 July 2004; accepted 11 November 2004.

*Address correspondence to Cosima Jahnke, M.D., Department of Internal Medicine/Cardiology, University of Freiburg, Hugstetter Str. 55, 79106 Freiburg, Germany; Fax: +49-761-270-3767; E-mail: jahnke@med1.ukl.uni-freiburg.de

[#]Both authors contributed equally to the work.

navigator is limited when compared to that of cine scans, which are used for visual assessment.

In the present study we evaluated a new, automatic measurement of the cardiac rest period using an image-based global cross-correlation of multi heart-phase cine-scans in comparison to visual assessment.

2. Methods

2.1. Subjects

One hundred thirty-five consecutive routine cardiac patients (92 male; mean age 60 ± 10 yrs, range 21–86 yrs) referred to our institution for diagnostic cardiac MR imaging. Patients with contraindications to MR imaging (noncompatible biometallic implants or claustrophobia) were excluded from the study. Written informed consent was obtained from all patients.

2.2. Magnetic resonance imaging

All patients were examined in the supine position using a 1.5 T whole body MR system (Philips Intera CV, Best, The Netherlands) equipped with a PowerTrak6000 gradient system (23 mT/m; 219 μ sec rise time) and specifically

designed software (Release 9 and BACCHUS-patch). A five-element cardiac synergy coil was used for signal reception. Cardiac synchronization was performed using four electrodes placed on the left anterior hemithorax (vector-ECG) and scans were triggered on the R-wave of the ECG (7). A rapid gradient echo sequence as multistack, multislice survey (steady-state free precession (SSFP); TR/TE/flip angle: 4.0 ms/1.3 ms/55°) allowed for localization of the heart in the three standard planes (transverse, sagittal, and coronal).

2.1.1. Visual assessment of the coronary artery rest periods

A cine-SSFP scan with an in-plane resolution of 2.1×2.1 mm and 8-mm slice thickness (TR/TE/flip angle: 2.7 ms/1.4 ms/60°; retrospective gating, 40 phases/cardiac cycle) was conducted using a transversal slice orientation (horizontal long-axis view). This scan imaged the cross-sections of the left and right coronary arteries within the left and right atrioventricular groove. An observer unaware of the results of the automatic analysis placed a region of interest (ROI) on the outer edge of the cross-section of each coronary artery to individually determine the left and right coronary artery rest period (Fig. 1A). The duration of the coronary artery cross-section being completely within the ROI was defined as the rest period enabling measurement of the starting point and duration. Usually, a rest period was found during end-systole

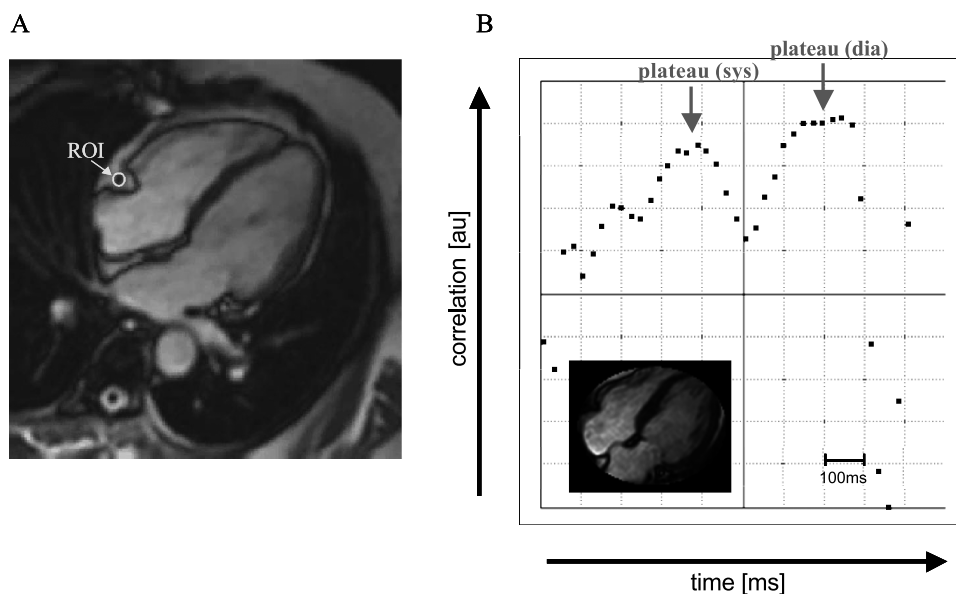


Figure 1. A: Visual evaluation of the rest period of the RCA. A region of interest (ROI) was manually placed on the outer edge of the cross-section of the respective coronary artery, facilitating measurement of the individual coronary artery rest periods. The example represents an end-diastolic view and the cross-section of the RCA is completely located inside the ROI; thus the given phase image belongs to the right coronary rest period. B: Automatic detection of the cardiac rest period. The graph demonstrates the cross-correlations between consecutive heart phases within a mask defined by the shim volume (inlay). The vertical gridlines correspond to 100-ms steps. The horizontal axis shows the correlation in arbitrary units (au) and with arbitrary offset. Maximal correlation values in the graph represent least motion of the heart between consecutive phase images; the cardiac rest period is defined as the plateau phase showing the highest correlation values. In the example given, the cross-correlation curve indicates a short end-systolic rest period (plateau sys) between 340 ms and 410 ms and a longer mid-diastolic rest period (plateau dia) between 640 ms and 780 ms (red arrows).

and mid-diastole with the longer of the two being used for the analysis. Individual heart rate was noted.

The common rest period of the left and right coronary arteries was determined as the intersection of the individual visual measurements of both vessel rest periods (i.e., the time period between the later starting point and the earlier end point of either of the two vessels).

2.2.2. Automatic assessment of the cardiac rest period

An automatic detection of the cardiac rest period was performed using the same cine-SSFP dataset as used for the visual assessment. This allowed to exclude potential influence e.g., due to variations of the heart rate. The shim volume, placed around the heart to optimize main field homogeneity, was additionally used to define a correlation kernel in order to mask the images of the cine-SSFP scan (Fig. 1B). The volume covered within the mask was displayed after scanning (Fig. 1B, inlay), which allowed to check and—if necessary—to correct its position. The position of the shim volume was considered to be optimal in case of coverage of the entire heart during a whole cardiac cycle without inclusion of surrounding tissue. The cross-correlations between consecutive heart phases within the mask were determined using the following formula:

$$S_k = \frac{\sum_{(i,j) \in \text{mask}} p_{ijk} \cdot p_{ijk+1}}{\sqrt{\sum_{(i,j) \in \text{mask}} p_{ijk}^2 \cdot \sum_{(i,j) \in \text{mask}} p_{ijk+1}^2}}$$

where p_{ijk} denotes the pixel value in row i and column j of heart phase image k , and S_k the corresponding global correlation value. The calculation was performed automatically on the console computer without noticeable delay after image data acquisition and reconstruction, and the results were displayed in a graph showing the correlation values over time, i.e., one complete cardiac cycle (see Fig. 1B). The higher the correlation, the lower the cardiac motion between two consecutive heart phases with the maxima corresponding to the most quiescent heart-phases. The cardiac rest period was defined as the plateau period with the highest correlation values showing < 2% deviation with reference to the total variation range observed in the cardiac cycle (empirical threshold). Again, rest periods were found during end-systole

and mid-diastole and the longer rest period was chosen for evaluation.

2.3. Statistical analysis

Data analysis was performed using SPSS for Windows 11.5 (SPSS Inc.). For all continuous parameters mean ± standard deviation are given. The paired Student’s t-test and one-way ANOVA were used to assess statistical significance of continuous variables. Pearson’s correlation was used to test statistical coherence between the visually assessed coronary artery rest periods and the automatically detected cardiac rest period. Bland-Altman analysis was done to compare the visual and the automatic approach with regard to starting point and duration of the rest periods; the degrees of agreement between these two methods were determined as mean absolute difference, 95% confidence interval of the mean difference and mean relative difference (difference of two techniques divided by their mean value) (8). All tests were two-tailed; $p < 0.05$ was considered statistically significant.

3. Results

3.1. Visual assessment of the coronary artery rest periods

Average heart rate was 72 ± 13 bpm. The rest period of the left coronary artery was significantly longer ($p < 0.001$) and began significantly earlier ($p < 0.001$) during the cardiac cycle in comparison to the right coronary artery (Table 1). The corresponding intersection of the coronary artery rest periods was significantly shorter ($p < 0.001$) and started significantly later during the cardiac cycle ($p < 0.001$) in comparison to both, the left and right coronary artery rest period. The data is given in Table 1.

3.2. Automatic assessment of the cardiac rest period

Automatic detection of the cardiac rest period was successful in all study subjects.

The automatically detected cardiac rest period was significantly shorter ($p < 0.001$) and started significantly later during the cardiac cycle ($p < 0.001$) when compared to

Table 1. Characteristics of visually assessed coronary artery rest periods in comparison to automatically detected cardiac rest period

	Visual			Automatic
	LCA	RCA	Common (LCA/RCA)	Cardiac
Rest period starting point [ms]	514 ± 144	533 ± 156	539 ± 155	542 ± 149
Correlation to automatic approach (r)	0.98 ^a	0.99 ^a	0.99 ^a	
Rest period duration [ms]	158 ± 72	117 ± 52	109 ± 52	103 ± 46
Correlation to automatic approach (r)	0.84 ^a	0.91 ^a	0.93 ^a	

^a $p < 0.001$.

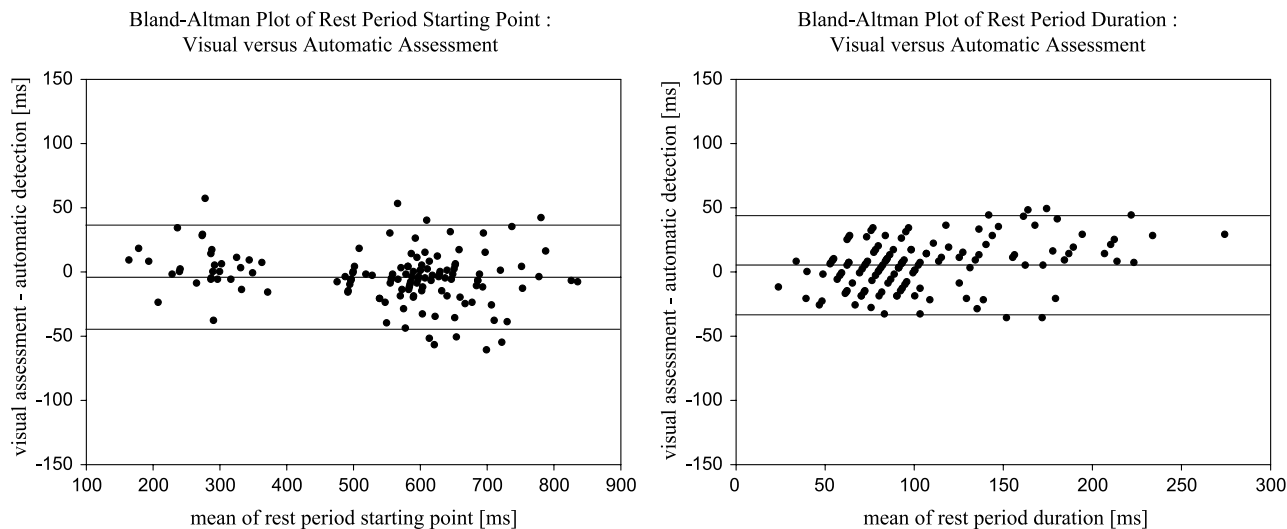


Figure 2. Bland-Altman plots for visually assessed common coronary rest period vs. automatically assessed cardiac rest period (starting point and duration). In each plot the central horizontal line indicates the mean absolute difference; upper and lower lines represent 95% confidence intervals.

the individual, visual assessment of the left and right coronary artery rest periods. A strong correlation, though, was found between the automatically assessed cardiac and the visually assessed common coronary rest period (Table 1).

For the comparison of the automatically assessed cardiac vs. the visually assessed common coronary rest period, excellent agreement with regard to the determination of the starting point and duration of the rest period was found (see Fig. 2).

4. Discussion

The presented cross-correlation method allowed for a fully user independent determination of the cardiac rest period. The automated technique was successfully performed in an unselected patient population and showed excellent agreement with the visually assessed common coronary rest period. However, the cardiac and common coronary rest periods were significantly shorter than the separately determined coronary artery rest periods.

The importance of optimal coronary motion suppression for MRCA has previously been recognized (4, 9). Currently, two approaches are used for determination of the imaging acquisition window: first, heart-rate corrected values based on the ECG (2) and secondly, the more recently introduced individual determination of coronary artery rest periods (1). The latter has been shown to be advantageous with regard to image quality (3), though, the investment of time before the actual imaging procedure can be started should be taken into account.

Recently, the operator independent detection of the cardiac rest period was introduced using a calibration scan based on navigator echoes (3). However, this approach was tested in a small number of healthy volunteers only and still required

user interaction during a sophisticated planning of the navigator position with limited information resulting from a one-dimensional navigator.

It has recently been reported that the cross-correlations between images of consecutive heart phases may be used to characterize cardiac motion (10). Our automated, completely user independent approach is technically easy to perform (integrated in a standard cine scan) and the cardiac rest period can be determined at a glance from a graph, which is displayed on the console of the scanner. In addition, the shim volume coverage (=mask) is shown and allows to check for its correct positioning; an extensively large shim volume might result in an underestimation of the cardiac rest period.

The close correlation and high agreement between visual and automated measurements allow to abandon time-consuming evaluation or planning procedures and the proposed new algorithm can easily be integrated into a routine coronary artery MR examination.

Currently, most centers perform coronary imaging using two separate volumes for the left and right coronary arteries; newer techniques, though, do allow to cover the whole coronary arterial tree with a single scan (5, 6). For the latter approach the cardiac rest period—rather than the coronary artery rest periods—must be used.

The proposed automated approach determines the cardiac rest period, and is thus applicable for both separate volume and whole heart imaging. Yet, when separate volume imaging is preferred, the investigator should take into account that the cardiac rest period is significantly shorter than each of the coronary rest periods alone and, thus, its use will result in a shorter acquisition window with the consequence of a prolonged total scan duration.

In addition, future implementations of the cross-correlation algorithm may either allow determination of the left and right

coronary rest periods separately with a targeted geometry covering the respective coronary artery only or even determination of the rest periods of different coronary segments.

5. Conclusion

The automatic approach facilitates a rapid and user independent assessment of the optimal cardiac acquisition window for MRCA. This method is especially advantageous when applying new MRCA strategies that aim at the visualization of the whole coronary arterial tree during a single scan.

Acknowledgment

This work was supported by a grant from the Stifterverband für die Deutsche Wissenschaft.

References

1. Jahnke C, Paetsch I, Schnackenburg B, Bornstedt A, Gebker R, Fleck E, Nagel E. Coronary MR angiography with steady-state free precession: individually adapted breath-hold technique versus free-breathing technique. *Radiology* 2004; 232(3):669–676. Epub 2004 Jul 29.
2. Stuber M, Botnar RM, Danias PG, Kissinger KV, Manning WJ. Submillimeter three-dimensional coronary MR angiography with real-time navigator correction: comparison of navigator locations. *Radiology* 1999; 212(2):579–587.
3. Wang Y, Watts R, Mitchell I, Nguyen TD, Bezanson JW, Bergman GW, Prince MR. Coronary MR angiography: selection of acquisition window of minimal cardiac motion with electrocardiography-triggered navigator cardiac motion prescanning—initial results. *Radiology* 2001; 218(2):580–585.
4. Kim WY, Stuber M, Kissinger KV, Andersen NT, Manning WJ, Botnar RM. Impact of bulk cardiac motion on right coronary MR angiography and vessel wall imaging. *J Magn Reson Imaging* 2001; 14(4):383–390.
5. Maintz D, Ozgun M, Hoffmeier A, Quante M, Fischbach R, Manning WJ, Heindel W, Botnar RM. Evaluation of free-breathing balanced fast field echo whole heart MR angiography. *JCMR* 2004; 6(1):93–94.
6. Weber OM, Martin AJ, Higgins CB. Whole-heart steady-state free precession coronary artery magnetic resonance angiography. *Magn Reson Med* 2003; 50:1223–1228.
7. Fischer SE, Wickline SA, Lorenz CH. Novel real-time R-wave detection algorithm based on the vectorcardiogram for accurate gated magnetic resonance acquisitions. *Magn Reson Med* 1999; 42:361–370.
8. Bland JM, Altman DG. Statistical methods for assessing agreement between two methods of clinical measurement. *Lancet* 1986; 1:307–310.
9. Wang Y, Vidan E, Bergman GW. Cardiac motion of coronary arteries: variability in the rest period and implications for coronary MR angiography. *Radiology* 1999; 213:751–758.
10. Nehrke K, Bornert P, Netsch T. Automatic selection of cardiac acquisition window using an image-based global cross-correlation of multi heart phase cine scans. *Proc Int Soc Magn Reson Med* 2003; 11:1623.