

VIABILITY

Standardizing the definition of hyperenhancement in the quantitative assessment of infarct size and myocardial viability using delayed contrast-enhanced CMR

OLGA BONDARENKO, M.D.,^{1,*} AERNOUT M. BEEK, M.D.,¹ MARK B. M. HOFMAN, PH.D.,² HARALD P. KÜHL, M.D.,¹ JOS W. R. TWISK, PH.D.,³ WILLEM G. VAN DOCKUM, M.D.,¹ CEES A. VISSER, M.D., PH.D.,¹ and ALBERT C. VAN ROSSUM, M.D., PH.D.¹

¹Department of Cardiology, VU University Medical Center, Amsterdam, The Netherlands

²Department of Physics and Medical Technology, VU University Medical Center, Amsterdam, The Netherlands

³Department of Clinical Epidemiology and Biostatistics, VU University Medical Center, Amsterdam, The Netherlands

Purpose. To evaluate a standardized definition of delayed hyperenhancement in the analysis of contrast-enhanced cardiac magnetic resonance (ceCMR) imaging. **Patients and Methods.** CeCMR was performed in 15 patients with chronic ischemic heart disease. Delayed hyperenhancement was analyzed both by visual analysis by an experienced team of observers, and after thresholding the window setting of the images at 2, 3, 4, 5, and 6 SD above the mean signal intensity of remote, normal myocardium in the same slice. In each patient, total infarct size (TIS) and segmental infarct extent (SIE) were calculated. **Results.** TIS and SIE were 22.9 ± 12.2 mL and $32 \pm 28\%$ after visual analysis. Thresholding the window setting at 2, 3, 4, and 6 SD above signal intensity of remote caused a 40%, 31%, and 17% increase ($p < 0.007$) and a 7% decrease ($p = \text{NS}$) in TIS, and a 75%, 41%, and 16% increase and 22% decrease in SIE ($p < 0.001$), respectively. There was no difference between visual analysis and analysis after thresholding at 5 SD. **Conclusion.** Analyzing ceCMR with a standardized definition of hyperenhancement related to the signal of remote, nonenhanced myocardium may result in considerable overestimation of infarct size at the usual cut-off of 2 SD.

Key Words: Cardiac MRI; Delayed contrast-enhanced MRI; Chronic myocardial infarction; Image processing

1. Introduction

Inversion recovery delayed contrast-enhanced cardiac magnetic resonance (ceCMR) imaging accurately visualizes regional myocardial necrosis in ischemic heart disease (1). Infarcted regions are easily identified as regions of high signal intensity within noninfarcted, remote myocardium. By planimetry of the hyperenhanced regions, both the transmural extent and the total size can be quantified and expressed as a percentage of segmental area or total left ventricular mass, respectively. The size of the hyperenhanced regions is influenced by the image window settings (center and width), that reflect the personal preference of the analyst/observer. An objective, standardized definition of hyperenhancement would increase reproducibility, facilitate quantification, and allow

comparison of results from different centers. Experimental studies have defined hyperenhancement by using the signal intensity of remote, noninjured myocardium with low contrast concentration (1–4). Regions were defined as hyperenhanced when signal intensity was higher than mean signal intensity plus 2 or 3 standard deviations (SD) of remote, and an excellent correlation was found with histological data. However, the 2–3 SD cut-off point may not be appropriate in the patient setting, with different scan parameters and image resolution. The large majority of patient studies have not used a standardized definition of hyperenhancement (5–10), and several reports have suggested that the difference in signal intensity between infarcted, hyperenhanced and noninfarcted, nonenhanced myocardium is considerably larger in patients (5, 11). In a previous study, we found that visual analysis and standardized analysis using image thresholding at 6 SD both predicted functional recovery of stunned myocardium in patients with a recently revascularized myocardial infarction (12). However, this study did not systematically compare standardized and visual analysis.

In the present study, we hypothesized that the use of 2 or 3 SD of remote as a cut-off to define hyperenhancement would

Received 17 June 2004; accepted 16 December 2004.

*Address correspondence to Olga Bondarenko, M.D., Department of Cardiology, VU University Medical Center, De Boelelaan 1117, Amsterdam HV 1081, The Netherlands; Fax: +31-20-4443395; E-mail: o.bondarenko@vumc.nl

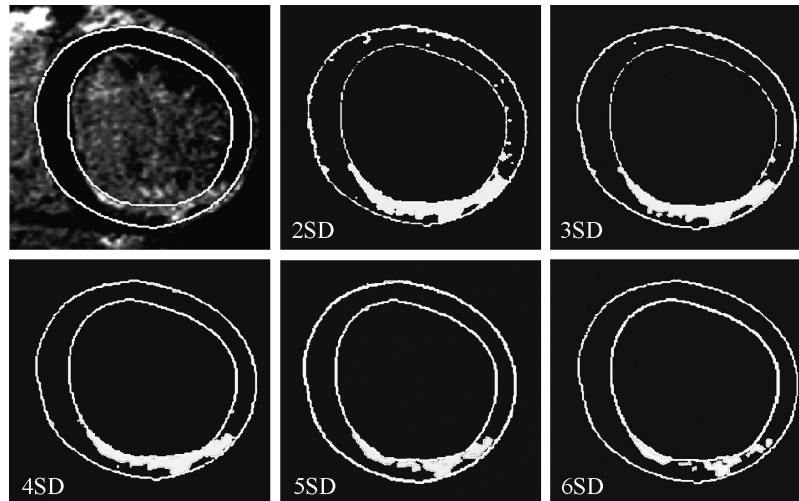


Figure 1. Typical contrast-enhanced image before and after thresholding the window setting at 2 to 6 SD above the signal intensity of normal myocardium in the same slice.

overestimate the area defined by visual analysis by an experienced team of observers. By using a range of thresholds related to the signal intensity of remote, noninfarcted myocardium, we sought to provide an objective equivalent to subjective, visual analysis.

2. Methods

2.1. Study population

Fifteen patients with a history of chronic (older than 2 months) myocardial infarction were included in this study. The Committee on Research Involving Human Subjects of the VU University Medical Center, Amsterdam, approved of the study protocol. All patients gave written informed consent.

2.2. MRI

Imaging was performed on a 1.5 T scanner (Sonata, Siemens, Erlangen, Germany) with the patient in a supine position using a four-element phased array cardiac receiver coil. Scout images were acquired in long-axis and short-axis orientations for planning of the final short-axis views. ECG-gated cine images were acquired using a breath-hold segmented steady-state free precession sequence. Eight to ten short-axis views per patient were obtained every 10 mm starting from the mitral valve insertion and covering the entire left ventricle. A gadolinium-based contrast agent (Magnevist, Schering AG, Berlin, Germany; 0.2 mmol/kg) was then administered intravenously through a power injector in a peripheral vein. After 15 minutes, contrast-enhanced images were acquired in the same orientation as the cine images, using a 2D segmented inversion recovery gradient-echo pulse sequence triggered to mid-diastole (repetition time/echo time = 9.6/4.4 ms, flip angle 25°, number of excitations = 1, matrix 208 × 256, typical voxel size of 1.6 × 1.3 × 5.0 mm,

receiver bandwidth 130 Hz/pixel). The inversion time was set to null the signal of normal myocardium, and was typically in the range of 250–300 ms.

2.3. Data analysis

All data were analyzed on a separate workstation (Sun Microsystems, Inc., Santa Clara, CA) using a dedicated software package (Mass 5.0, Medis, Leiden, The Netherlands). Cine and contrast-enhanced images were matched by using slice position. Cine images were used as a reference of diastolic wall thickness during interpretation of contrast-enhanced images. Endocardial and epicardial borders in contrast-enhanced images were traced manually, excluding trabeculations and papillary muscles. Hyperenhancement was defined first by visual analysis during which the window setting could be freely adjusted to the personal preference of

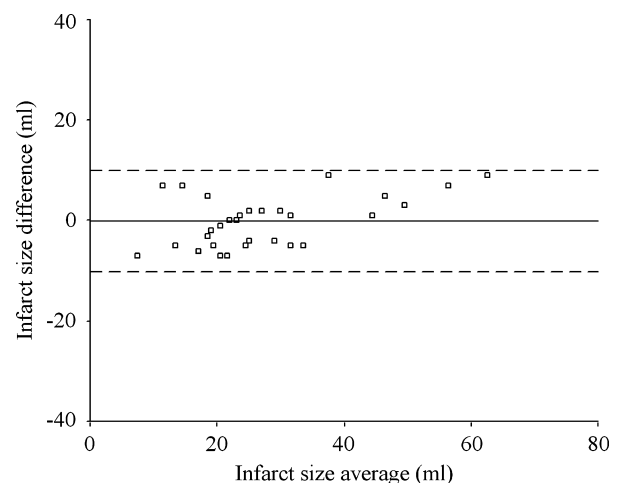


Figure 2. Intraobserver agreement, showing overall bias (solid line) and 95% limits of agreement (dashed lines).

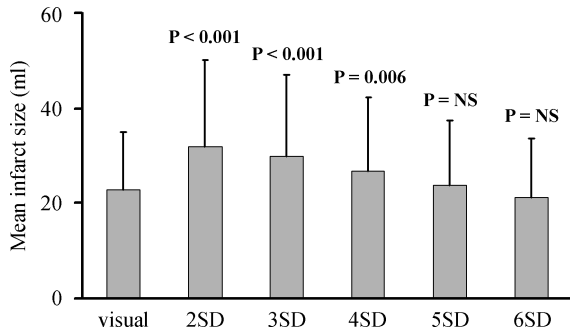


Figure 3. Mean infarct size according to visual and standardized assessment. Probability values summarize the paired-sample *t* test, which was used to compare means between visual and standardized analysis.

the observers. Hyperenhanced regions were manually contoured, and both segmental infarct extent (SIE, expressed as percentage of segmental area, in a five-slice, 60-segment model) and total volume of hyperenhancement were computed in each slice. For each patient, the total infarct size (TIS) was calculated by summation of all slice volumes of hyperenhancement. The analysis of slices that showed hyperenhancement was then repeated after subsequently thresholding the window setting at 2, 3, 4, 5, and 6 SD above the mean signal intensity of remote, normal myocardium in the same slice. Normal myocardium was defined by the combination of normal regional wall thickening and the absence of any regional contrast enhancement at visual assessment. Mean signal intensity and SD were then determined by placing a region of interest in the central part

of the wall. To test intraobserver variability, both visual and standardized analyses were repeated after 2 weeks in five patients. Inter-observer agreement (O.B., A.M.B.) for the assessment of hyperenhancement has been previously published and equaled 87% ($\kappa = 0.76$) (12).

2.4. Statistical analysis

All values are expressed as mean \pm SD. Bland-Altman analysis and intraclass correlation coefficients were used for the comparison of visual and standardized analysis and for the assessment of intraobserver variability (13, 14). Paired-samples *t*-tests, adjusted for the nonindependence of segmental data, were used to compare means between standardized and visual analysis. P values of less than 0.05 were considered statistically significant.

3. Results

CeCMR demonstrated regional hyperenhancement in all 15 patients. The changes in size and shape of the hyperenhanced areas caused by the various window settings are illustrated in Fig. 1. Figure 2 represents the Bland-Altman analysis of the intraobserver variability. The intraclass correlation coefficient for intraobserver variability was 0.93.

3.1. Infarct size

Mean TIS was 22.9 ± 12.2 mL after visual analysis. Thresholding the window setting at 2, 3, and 4 SD above signal

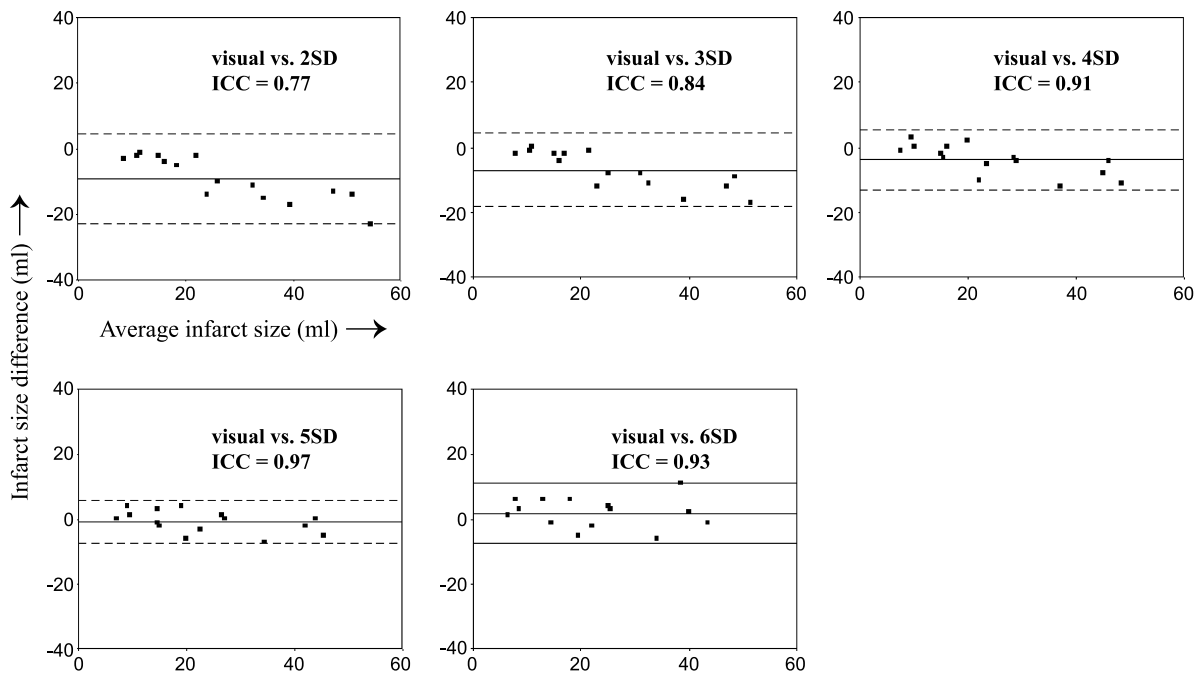


Figure 4. Agreement between visual and standardized analysis, showing overall bias (solid line) and 95% limits of agreement (dashed lines). ICC = intraclass correlation coefficient.

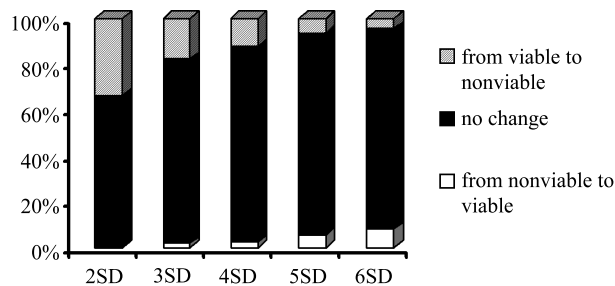


Figure 5. Change in viability status of 314 visually assessed segments after thresholding the images. Segments were considered viable if segmental extent of hyperenhancement was less than 50%.

intensity of remote, normal myocardium caused a 40%, 31%, and 17% increase in mean infarct size, respectively ($p < 0.007$). Thresholding the images at 5 and 6 SD yielded a nonsignificant 4% increase and 7% decrease in infarct size, respectively (Fig. 3). Figure 4 shows TIS agreement between visual and standardized analysis and the intraclass correlation coefficients.

3.2. Segmental infarct extent

SIE was assessed in 314 segments with regional hyperenhancement at visual analysis. Mean SIE was $32 \pm 28\%$ after visual analysis. Standardized analysis with window setting at 2, 3, 4, and 6 SD above remote caused a 75%, 41%, and 16% increase, and a 22% decrease in SIE, respectively ($p < 0.001$). Analysis with signal intensity thresholded at 5 SD above remote caused a 0.8% decrease in SIE ($p = \text{NS}$). For the evaluation of myocardial viability, SIE is generally divided in five categories: 0%, 1–25%, 26–50%, 51–75%, and 76–100%. The likelihood of functional recovery of stunned or hibernating myocardium after successful revascularization decreases with each category. The change in viability category as a result of standardized analysis was only evaluated in segments with $> 25\%$ change in SIE, to avoid inclusion of segments that changed category because of very small changes in SIE (e.g., from 24% to 26%). Standardized analysis with SD increasing from 2 to 6 caused a change in category in 44%, 24%, 20%, 17%, and 19% of the segments, respectively. Figure 5 shows the change in viability status, with segmental viability defined as $< 50\%$ SIE.

4. Discussion

The present study evaluated the use of a standardized definition of delayed hyperenhancement using a range of thresholded window settings related to the signal intensity of remote, nonscarred myocardium. Defining hyperenhancement with the generally accepted cut-off of > 2 SD above the signal intensity of remote resulted in gross overestimation of the amount of nonviable, scarred myocardium compared to analysis by an experienced team of observers. Mean infarct

size increased by 40%, and mean segmental extent of hyperenhancement by 75%, causing more than a third of the segments presumed to be nonviable. Thresholding the images at 3 and 4 SD above remote still led to considerable overestimation of the hyperenhanced area. Analysis at 6 SD resulted in a generally nonsignificant underestimation, while the closest agreement was found after thresholding at 5 SD.

In patients with myocardial infarction there is no direct comparison available with the histological gold standard of myocardial necrosis. Therefore, we used visual analysis by an experienced team of observers, with high intra- and interobserver reproducibility, as the reference method. In previous studies, we have shown that the visual analysis of delayed hyperenhancement in our institution corresponded well to other clinical and diagnostic standards of viability assessment (8, 12). In a high-resolution ex vivo study, Kim et al. (1) used a threshold of 2 SD above remote, and demonstrated that the spatial extent of hyperenhancement by ceCMR was identical to spatial extent of myocardial necrosis, as defined by triphenyltetrazolium chloride (TTC) staining. In patients, partial volume effects and blurring by cardiac motion during the acquisition may lead to a relative increase of signal intensity in pixels in the border zone of the infarct compared to remote, thus resulting in overestimation of myocardial necrosis area. During visual, “free” window setting, observers tend to suppress the signal from these minimally enhanced parts. However, mean signal intensity and SD of remote (purposely suppressed) myocardium are so low, that signal intensity in the infarct border will still be considerably higher than the generally applied cut-off of 2 or 3 SD. The only comparison between ceCMR and histology data in patients comes from a recent report on a patient with hypertrophic cardiomyopathy, who needed transplantation because of advanced heart failure (15). Defining hyperenhancement as > 2 SD of remote, the authors found a significant relation between the segmental extent of hyperenhancement and the amount of collagen. However, these results cannot be extrapolated to our study population due to different etiology of myocardial fibrosis.

5. Limitations

Although the intra- and interobserver reproducibility in our institution is high, and we have previously reported good correlations between visual analysis and other standards of myocardial viability (8, 12), other institutions may have different “visual” standards. Also, the standard deviation in remote myocardium primarily depends on the signal-to-noise ratio of the acquisition, which is influenced by imaging protocol and RF receiver coil set-up. Although 5 SD can be considered a valid threshold for standardization in our institution, it may not be directly applicable in centers with other types of scanners or imaging protocols (e.g., 3D acquisition).

Prior to image thresholding and quantification, an initial visual assessment will still be required to define endo- and epicardial contours, and a (general) region of interest, to avoid the erroneous inclusion of other regions of high signal intensity such as in-folding or motion artifacts, fat, or pericardial effusion. Also, a visual preassessment will help to identify and include regions of low signal intensity caused by microvascular obstruction, as may be seen in patients with recent myocardial infarction (16–18).

6. Conclusion

Analyzing ceCMR with a standardized definition of hyperenhancement using a cut-off of 2 or 3 SD considerably overestimated total infarct size and segmental infarct extent compared to visual analysis by an experienced team of observers. In our study group, the optimal relation between standardized and visual analysis was found with window setting thresholded at 5 SD above mean signal intensity of remote, nonenhanced myocardium. Standardized analysis using this threshold will further increase reproducibility and facilitate (semi)automated quantification.

Acknowledgment

This work was supported by grant No. 2001.158 from the Netherlands Heart Foundation.

References

- Kim RJ, Fieno DS, Parrish TB, Harris K, Chen EL, Simonetti O, Bundy J, Finn JP, Klocke FJ, Judd RM. Relationship of MRI delayed contrast enhancement to irreversible injury, infarct age, and contractile function. *Circulation* 1999; 100(19):1992–2002.
- Fieno DS, Kim RJ, Chen EL, Lomasney JW, Klocke FJ, Judd RM. Contrast-enhanced magnetic resonance imaging of myocardium at risk: distinction between reversible and irreversible injury throughout infarct healing. *J Am Coll Cardiol* 2000; 36(6):1985–1991.
- Hillenbrand HB, Kim RJ, Parker MA, Fieno DS, Judd RM. Early assessment of myocardial salvage by contrast-enhanced magnetic resonance imaging. *Circulation* 2000; 102(14):1678–1683.
- Gerber BL, Rochitte CE, Bluemke DA, Melin JA, Crosille P, Becker LC, Lima JA. Relation between Gd-DTPA contrast enhancement and regional inotropic response in the periphery and center of myocardial infarction. *Circulation* 2001; 104(9):998–1004.
- Kim RJ, Wu E, Rafael A, Chen EL, Parker MA, Simonetti O, Klocke FJ, Bonow RO, Judd RM. The use of contrast-enhanced magnetic resonance imaging to identify reversible myocardial dysfunction. *N Engl J Med* 2000; 343(20):1445–1453.
- Choi KM, Kim RJ, Gubernikoff G, Vargas JD, Parker M, Judd RM. Transmural extent of acute myocardial infarction predicts long-term improvement in contractile function. *Circulation* 2001; 104(10):1101–1107.
- Klein C, Nekolla SG, Bengel FM, Momose M, Sammer A, Haas F, Schnackenburg B, Delius W, Mudra H, Wolfram D, Schwaiger M. Assessment of myocardial viability with contrast-enhanced magnetic resonance imaging: comparison with positron emission tomography. *Circulation* 2002; 105(2):162–167.
- Kuhl HP, Beek AM, van der Weerd AP, Hofman MB, Visser CA, Lammertsma AA, Heussen N, Visser FC, van Rossum AC. Myocardial viability in chronic ischemic heart disease: comparison of contrast-enhanced magnetic resonance imaging with (18)F-fluorodeoxyglucose positron emission tomography. *J Am Coll Cardiol* 2003; 41(8):1341–1348.
- Van Hoe L, Vanderheyden M. Ischemic cardiomyopathy: value of different MRI techniques for prediction of functional recovery after revascularization. *Am J Roentgenol* 2004; 182(1):95–100.
- Wellnhofer E, Olariu A, Klein C, Grafe M, Wahl A, Fleck E, Nagel E. Magnetic resonance low-dose dobutamine test is superior to scar quantification for the prediction of functional recovery. *Circulation* 2004; 109(18):2172–2174.
- Kwong RY, Schussheim AE, Rekhraj S, Aletras AH, Geller N, Davis J, Christian TF, Balaban RS, Arai AE. Detecting acute coronary syndrome in the emergency department with cardiac magnetic resonance imaging. *Circulation* 2003; 107(4):531–537.
- Beek AM, Kuhl HP, Bondarenko O, Twisk JW, Hofman MB, van Dockum WG, Visser CA, van Rossum AC. Delayed contrast-enhanced magnetic resonance imaging for the prediction of regional functional improvement after acute myocardial infarction. *J Am Coll Cardiol* 2003; 42(5):895–901.
- Bland JM, Altman DG. Statistical methods for assessing agreement between two methods of clinical measurement. *Lancet* 1986; 1(8476):307–310.
- Shrout P, Fleiss J. Intraclass correlations: uses in assessing rater reliability. *Psychol Bull* 1979; 86:420–428.
- Moon JC, Reed E, Sheppard MN, Elkington AG, Ho SY, Burke M, Petrou M, Pennell DJ. The histologic basis of late gadolinium enhancement cardiovascular magnetic resonance in hypertrophic cardiomyopathy. *J Am Coll Cardiol* 2004; 43(12):2260–2264.
- Wu KC, Kim RJ, Bluemke DA, Rochitte CE, Zerhouni EA, Becker LC, Lima JA. Quantification and time course of microvascular obstruction by contrast-enhanced echocardiography and magnetic resonance imaging following acute myocardial infarction and reperfusion. *J Am Coll Cardiol* 1998; 32(6):1756–1764.
- Wu KC, Zerhouni EA, Judd RM, Lugo-Olivieri CH, Barouch LA, Schulman SP, Blumenthal RS, Lima JA. Prognostic significance of microvascular obstruction by magnetic resonance imaging in patients with acute myocardial infarction. *Circulation* 1998; 97(8):765–772.
- Gerber BL, Rochitte CE, Melin JA, McVeigh ER, Bluemke DA, Wu KC, Becker LC, Lima JA. Microvascular obstruction and left ventricular remodeling early after acute myocardial infarction. *Circulation* 2000; 101(23):2734–2741.