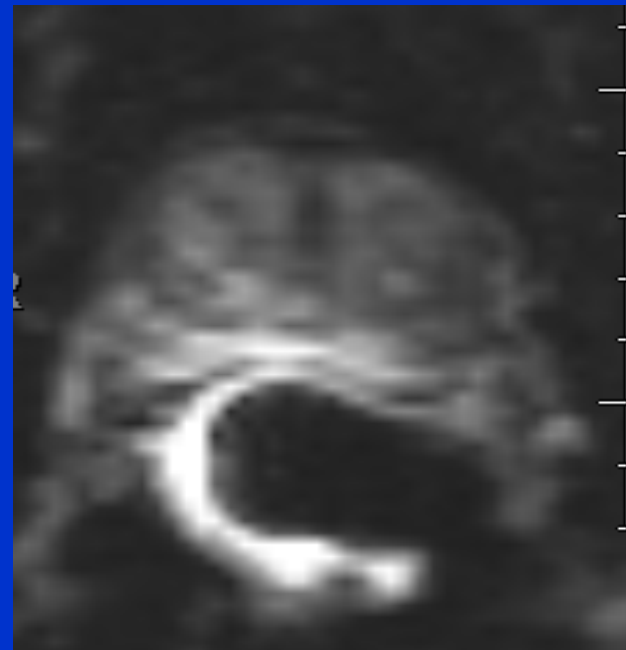
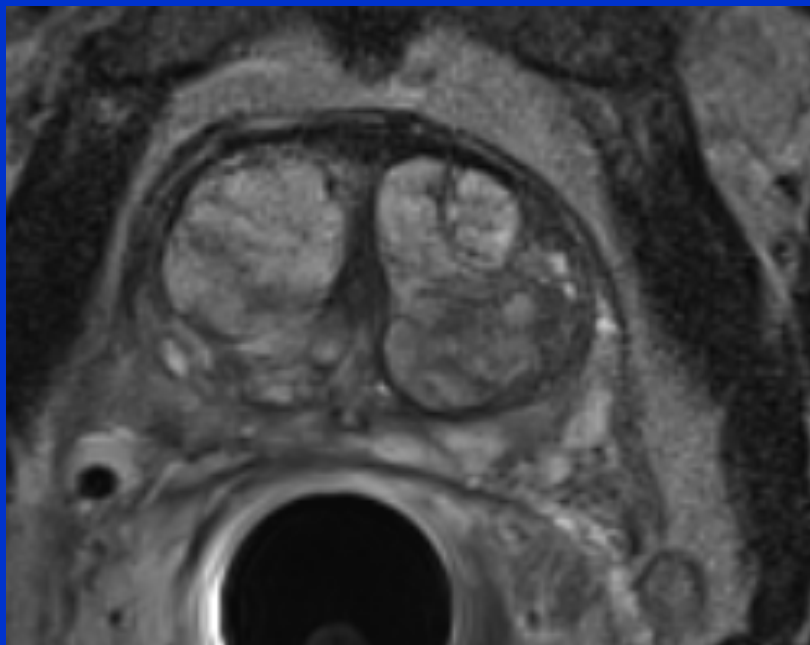


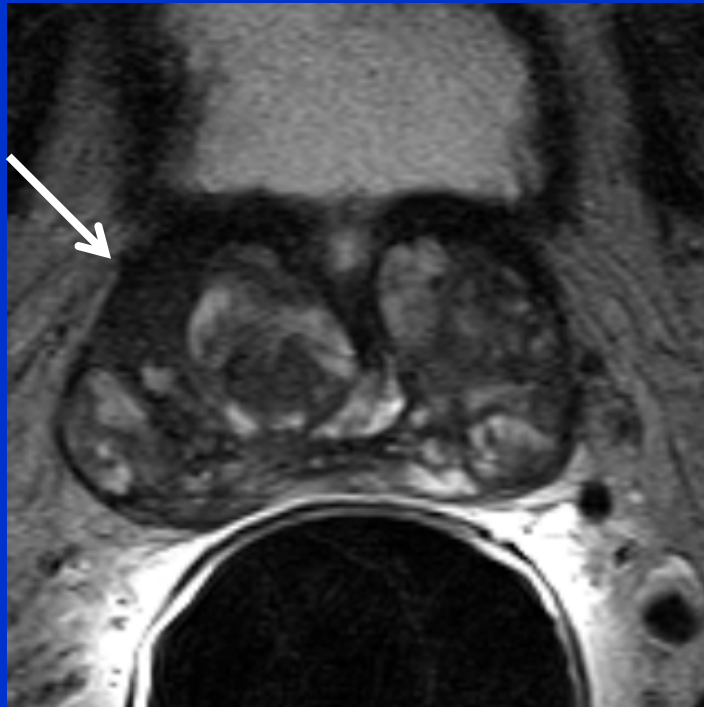
70 yr. old with history of elevated PSA

- 11/14: PSA 7.4

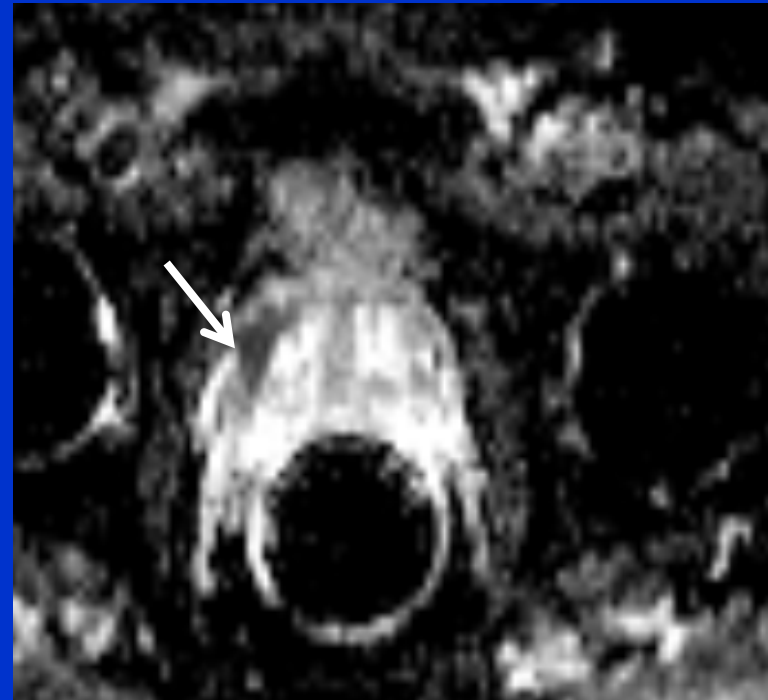


MRI 2014: No focal lesions reported

- Repeat MRI performed 2015
- PSA 21
- New Pi- rad 4 lesion localized right anterior fibromuscular stroma



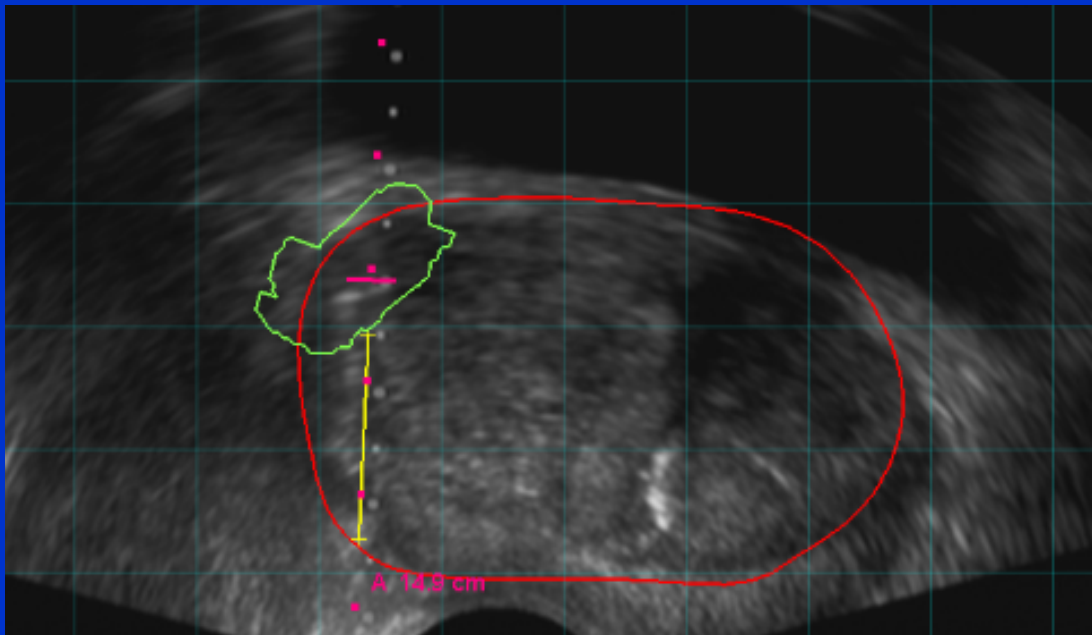
T2



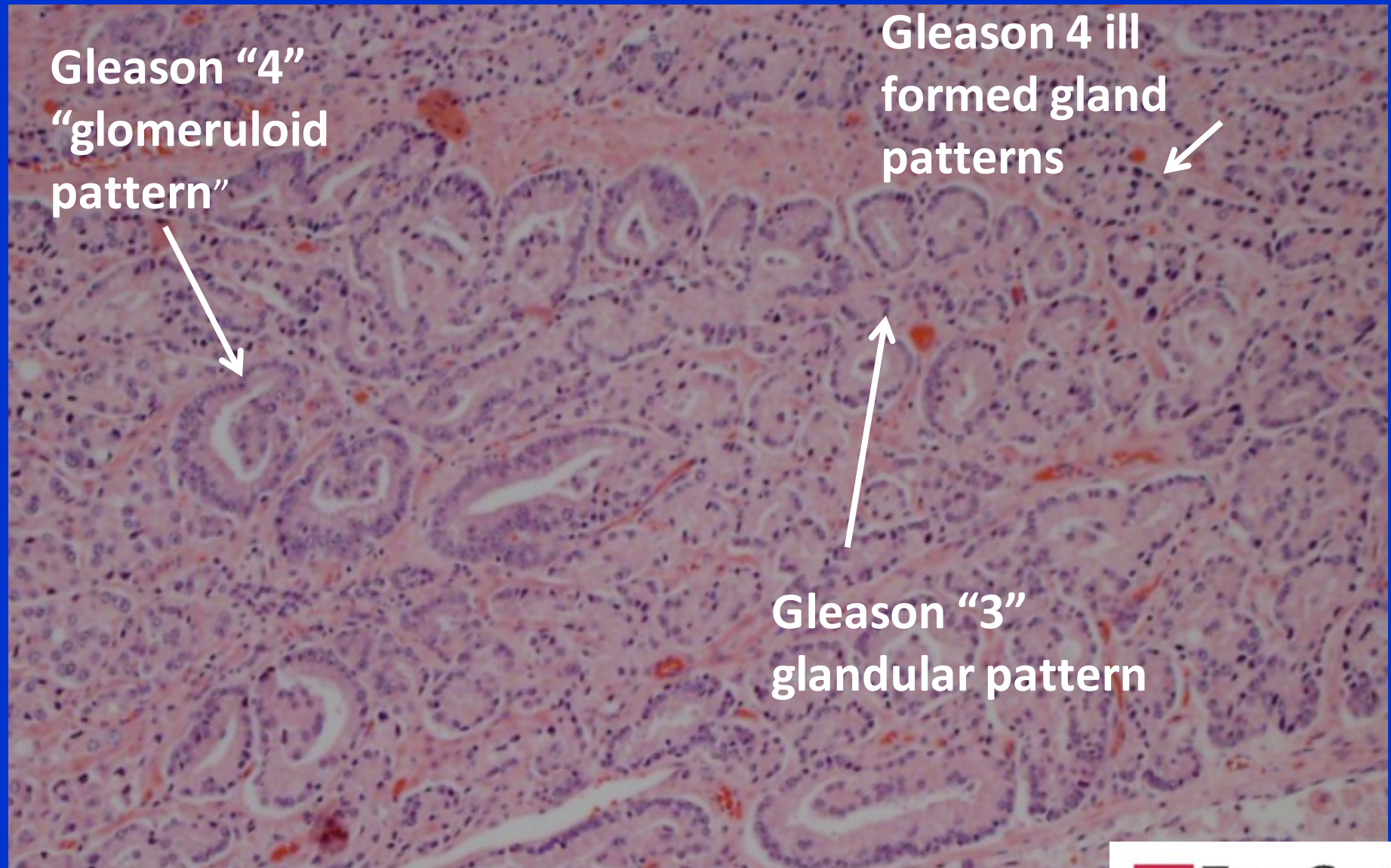
ADC

Navigational biopsy performed

- Gleason 7 (4+3)



Pathology core biopsy targeted lesion



Gleason 7 (4+3)

Comments

- The tumor was not seen even in retrospect
- This lesion could have been missed with standard 12 core biopsies
- Patient scheduled for prostatectomy