

ESSENTIALS OF MRI: SPINE

VINTON L. ALBERS, DC drvalbers.com

Reference Textbook: *Musculoskeletal MRI, 2nd Edition*, Helms

Earth's magnetic field strength: 0.5 Gauss (0.3-0.6). 10,000 Gauss = 1 Tesla (T).

MRI magnetic field strength: 0.2, 0.3, 0.6, 1, 1.5, 3 Tesla

High-field MRI: 1T, 1.5T, 3T

MRI uses radiofrequency (RF) pulses on tissues in a magnetic field and displays images in any plane desired without the use of ionizing radiation. Most magnets used have strength of about 0.2-1.5 Tesla (1 Tesla is 10,000 Gauss). Radiofrequency pulses cause deflection of these particles' nuclear magnetic moments, resulting in an image. The use of surface coils decrease the signal-to-noise ratio. Body coils are used for large joints, smaller coils are available for other studies. Sequences have been developed to demonstrate the differences in T1 and T2 relaxation between tissues. T1 images are weighted toward fat: T2 images are weighted toward water. Typically, T1 weighted images have TR (time to repetition) values <1000, and T2 images have TR values >1000. Some tissues appear differently on T1 and T2 weighted scans. Water, CSF, acute hemorrhage, and soft-tissue tumors appear dark on T1 studies and bright on T2 studies. Other tissues remain basically the same intensity on both images. Cortical bone, rapidly flowing blood, and fibrous tissue are all dark; muscle and hyaline cartilage are gray; and fatty tissue, nerves, slowly flowing (venous) blood, and bone marrow are bright.

T1 images best demonstrate anatomic structure (high signal-to-noise ratio).

T2 images are most useful for contrasting normal and abnormal tissues.

TR Repetition Time

TE Echo Time

TR and TE are measured in milliseconds.

Signal Intensity

High signal → bright

Low signal → dark

Fast Spin Echo (FSE) or Turbo Spin Echo (TSE)

Shorter scan times

MRI SEQUENCES

T1 Weighted Images T1WI

Fat weighted

Fluids: Dark

Fat: Bright

Pathological processes are usually dark on T1 and bright on T2

T1 Fat Saturation T1FS

Suppresses the signal from normal adipose tissue

Fat: Dark

T2 Weighted Images T2WI

Water weighted

Fluids: Bright

Pathological processes are usually bright on T2WI and dark on T1WI

Pathological processes usually increase the water content in tissue

Proton Density PD

Tissues with higher concentration or density of protons (hydrogen atoms) appear brightest on the image

Fat: Bright

Fluids: Bright

Bone: Dark

White Matter: Darker than bright gray

Gray Matter: Bright gray

Used for brain and spinal cord injury because of great white matter-gray matter contrast

STIR

Short Tau inversion recovery

Used for fat suppression

Fluids: Very bright

Bone/bone marrow: dark

Pathological processes are usually bright on STIR

MEDIC (Merge)

Multiple Echo Data Image

Used for cervical imaging: Axial images

Fluids: Bright

Spinal cord: Gray

Bone marrow: Dark

Muscle and fat: Gray

FLAIR

Inversion recovery sequence

Fluids appear dark, lesions and pathological processes appear bright

Used for brain imaging

STIR Short T1 Inversion Recovery

Used to suppress the signal from fat (fat suppression)

Inversion Recovery

Fat saturation technique, resulting in decreased signal intensity from fat and increased signal from fluid and edema. Useful to depict bone marrow and soft tissue pathology.

This technique results in excellent fat suppression and high signal intensity from areas of fluid or edema. It is extremely sensitive for detecting many types of acute pathology.

MRI with Enhancement

Gadolinium - rare earth metal. Chelated to diethylenetriamine pentaacetic acid (DTPA). Gadolinium-based contrast agents: Magnevist (gadopentetate dimeglumine), MultiHance (gadobenate dimeglumine), Omniscan (gadodiamide), OptiMARK (gadoversetamide), ProHance (Gadoteridol)

Paramagnetic contrast augments signal intensity from the magnetized tissue. When paramagnetic ions are placed in a strong external magnetic field, their large magnetic dipole moments influence nearby protons by changing their relaxation times. The most pronounced effect of decreased relaxation is seen in the T1 signal. When paramagnetic ions are introduced into tissues with very similar relaxation times, the relaxation times will not be equally affected. Signal differences become more pronounced and there will be more contrast between the tissues.

Reduces hydrogen proton relaxation times. Induces increased signal intensity and enhancement of T1-weighted images. Aids in the visualization of lesions with abnormal vascularity or those thought to cause an abnormality in the blood-brain barrier. Administered intravenously. Rapidly excreted by the kidneys. Enhancement is determined by three factors: blood supply, leaky capillary endothelium and an extravascular space. Most common-adverse reactions: Headache and injection-site coldness.

Nephrogenic Systemic Fibrosis

NSF is a progressive disorder associated with chronic kidney disease. Gadolinium-based contrast agents increase the risk for NSF in patients with acute or chronic severe renal insufficiency. NSF leads to excessive formation of connective tissue in the skin and internal organs. NSF is progressive and may be debilitating or fatal. The skin thickens and becomes hard, rigid, and coarse, which severely restricts movement of the joints. It can also lead to widespread fibrosis of internal organs involving lungs, heart, diaphragm, esophagus, and skeletal muscle, and in some cases may lead to death.

The serum creatinine test is used to diagnose impaired renal function.
>4 mg/dl indicates serious renal impairment.

Disc Desiccation

Loss of water content from disc, most noticeable in the nucleus pulposus. Normal discs are well hydrated, the nucleus containing 80-85% water and the annulus about 80%. Degeneration of the disc is accompanied by a loss of water content. This results in decreased signal intensity on T2-weighted MR images.

With aging and degeneration, the intervertebral discs lose hydration, lose proteoglycans, and gain collagen as they become more fibrous. Eventually, there is diffuse decreased signal intensity on T2W images from the increased collagen content in the nucleus. The disk progressively loses height with increasing degrees of degeneration .

Intranuclear Cleft

Central band of low signal intensity, due to fibrous transformation. The intranuclear cleft is a horizontal, low signal intensity line that divides the disc into upper and lower halves on T2W sagittal images.

Tarlov Cyst Perineural/perineurial or meningeal cyst

Are dilated nerve root sleeves filled with CSF. Often multiple. Walls contain nerve fibers. The cysts are common, but are usually asymptomatic. Most common at the S2 and S3 levels. Scalloping of the sacrum is common.

Symptoms:

- Pain in the low back and tailbone that radiates to the legs. Difficulty sitting, feeling of sitting on a rock. Pulling and burning sensation in the tailbone area, especially when bending.
- Pain as above with sexual dysfunction and dysfunctional bladder. Vaginal, rectal, pelvic and/or abdominal pain.
- Pain that radiates across hips to lower abdomen.
- No pain, just sexual dysfunction and dysfunctional bladder.

Conjoined Nerve Roots

Two nerve roots emerge from a common dural sheath. L5 and S1 are most frequently conjoined and are often mistaken for an extruded disc fragment. Conjoined nerve roots have been reported in 1% of lumbar disc operations and 8% in anatomic specimens.

Synovial Cyst

A cystic mass that usually communicates with the facet joint. Related to degenerative facet disease. Females over 60 years of age. Most common at the L4-5 level. Patient may have a degenerative spondylolisthesis at the L4 level. Symptoms include LBP, radicular symptoms and neurogenic claudication. May have acute pain from hemorrhage into the cyst.

Typically, there is minimal pain if the patient is seated. Pain with standing or walking.

Modic Changes

Signal intensity changes in vertebral body marrow adjacent to the endplates of degenerated discs.

Modic Type I: Low T1 signal and high T2 signal. Disruption and fissuring of the endplate with vascularized fibrous tissues within the adjacent marrow.

Modic Type II: High T1 and high T2 signals. Disruption and fissuring of the endplate with yellow marrow replacement in the adjacent vertebral body. Type I changes often progress to Type II change over time.

Modic Type III: Low T1 and T2 signal. Extensive bony sclerosis.

Pain of Somatic Origin

Anatomic structures supplied by nociceptive nerve endings (nerve endings sensitive to tissue damage). Nociceptors may be stimulated by mechanical, thermal, or chemical means.

Structure innervated by the ventral ramus

- Referred pain from structures innervated by nerves of the lumbar plexus
- Psoas muscle
- Quadratus lumborum muscle
- Intertransversarii muscles (lateral divisions)

Structures innervated by the dorsal ramus

Medial branch

- Deepest back muscles
- Zygapophyseal joints
- Periosteum of posterior vertebral arch
- Interspinous, supraspinous, and intertransverse ligaments, ligamentum flavum
- Skin (upper cervical, middle cervical, and thoracic dorsal rami)

Lateral branch

- Erector spinae muscles
- Splenius capitis and cervicis muscles (cervical region)
- Skin

Structures innervated by the recurrent meningeal nerve (sinuvertebral nerve of von Luschka)

- Periosteum of posterior aspect of vertebral bodies
- Internal vertebral (epidural) veins and basivertebral veins
- Epidural adipose tissue
- Posterior aspect of IVD
- PLL
- Anterior aspect of spinal dura mater

Structures innervated by nerves associated with the sympathetic trunk and the gray rami communicantes

- Periosteum of the anterior and lateral aspects of the vertebral bodies
- Lateral aspects of IVD
- Anterior aspects IVD
- ALL

Cramer GD, Basic and Clinical Anatomy of the Spine, Spinal Cord, and ANS

Recurrent Meningeal Nerve (sinuvertebral nerve of von Luschka)

Peripheral annulus fibrosus and posterior longitudinal ligament supplied with nociceptors (small unmyelinated nerve fibers with free of small capsular-type nerve endings). Nociceptors connect to recurrent meningeal nerve and/or to somatic afferent nerves carried within the sympathetic chain to the upper lumbar levels which lead to

dorsal root ganglion in spinal nerve root. The recurrent meningeal nerve originates from the most proximal portion of the ventral ramus. Receives a branch from the nearest gray communicating ramus of the sympathetic chain before traversing the IVF.

Somatic Referred Pain

Nociception generated by a skeletal or related structure (muscle, ligament, zygapophyseal joint), which is felt in an area distant to the structure generating the nociception.

Distinguishing Features of Somatic Referred Pain:

- Dull ache
- Difficult to localize
- Rather constant in nature

Radicular Pain

Pain arising from the dorsal root or the dorsal root ganglion; usually causes pain to be referred along a portion of the course of the nerve or nerves formed by the affected dorsal root. This is known as a dermatomal pattern.

Structures and conditions that can irritate the dorsal roots (or ganglia):

- Disc lesion
- Abscess (osteomyelitis and tuberculosis)
- Tumor of the spinal canal
- Spondylolisthesis
- Malformation of the vertebral canal
- Malformation of the spinal nerve root and its sheath
- Miscellaneous diseases of bone
- Histamine-like chemicals released from degenerating intervertebral disc

Mechanism of Radicular Pain:

- Pressure on dorsal root or dorsal root ganglion,
- Edema within the nerves
- Further edema and hemorrhage within the dorsal root ganglion
- Ischemia of neural elements. Ischemia perceived as PAIN

Distinguishing Features of Radicular Pain:

- Sharp, shooting type of pain along the distribution of the nerve(s) supplied by the affected dorsal root
- Long radiation into the upper or lower extremity (although this does not necessarily have to be the case)
- Pain coursing along a fairly thin band
- Pain accompanied by paresthesia, hypesthesia, and decreased reflexes
- Pain may be accompanied by motor weakness (as a result of compromise of the ventral roots)

Lumbar Sympathetic Afferents and Low Back Pain

Pain from a lower lumbar disc is transmitted nonsegmentally by visceral sympathetic afferent fibers, mainly from the L2 spinal nerve root. This results in referred pain in the L2 dermatome. Convergence projection theory is based upon the idea that visceral and somatic afferent fibers both synapse in the posterior horn.

Nakamura S-1, Takahashi K, Takahashi Y, et al: The afferent pathways of discogenic low-back pain: Evaluation of L2 spinal nerve infiltration. J Bone Joint Surg (Br) 78B:606-612, 1996.

Convergence Theory of Conscious Somatotopic Localization and Pain Referral

Peripheral afferent fibers from visceral sources and somatic sources converge at the level of the spinal cord on the same cord neuron, producing a cerebral perception of pain located to the initiating sources (vertebra), as well as within the site of referral.

Discogenic Pain

There is anatomic evidence that the disc can be a source of pain (nociceptor) because of the innervation that exists along the outer annulus from the ventral nerve roots that provide branches anteriorly (grey ramus communicans) and posteriorly (sinuvertebral nerve). There are many other structures in and around the spine that may be nociceptors and is often difficult for the clinician to differentiate these potential sources of pain.

Degenerative discs are thought to cause pain in several ways including mechanical instability (stretching of pain fibers) compressive impingement on adjacent nerves (radiculopathy) and biomechanical irritation via release of inflammation mediators.

Internal disc disruption describes pathologic changes of the internal structure of the disc. Internal disc disruption and degeneration involve a physiochemical change in the glycosaminoglycans of the NP, which act to bind water; over time this water-binding capacity diminishes. Disc degeneration is usually heralded by loss of hydration and thus decreased T2 signal on MR imaging.

Disc Herniation - Mechanism of Symptom Production

1. Mechanical neural compression: Studies have established that larger disc herniations are more likely to be symptomatic, that extrusions are more likely to be associated with symptoms and are rarely seen in asymptomatic individuals whereas protrusions can often be seen in asymptomatic individuals.

2. Chemical irritation: A substance (phospholipase A₂, matrix metalloproteinases, nitrous oxide, cytokines, tumor necrosis factor alpha, and free glutamate) incites a biochemical cascade that results in excessive macrophages in the vicinity of the nerve with subsequent abnormal nerve conduction and resultant pain.

If the patient's symptoms are predominantly those of **conduction block** (numbness and weakness), then mechanical compression would seem more likely to be the cause of symptoms. If the patient's symptoms are predominantly those of **radicular pain**, then chemical irritation would seem likely to be the cause of the symptoms.

Chemical Radiculitis

Leaking nucleus pulposus through an annular tear contains chemicals that are inflammatory, neurodegenerative, and in the acute stages, neuroexcitatory. Result in chemical stimulation of small unmyelinated nerve fibers in the annulus or nearby neural elements. Inflammation-induced nociception stimulation and pain resulting from annulus fissure or disc herniation.

Painful Disc Herniations

Symptomatic disc herniations have both a mechanical and a chemical component. The chemical component results in sensitization of the nerve root as a result of a series of complex biologic reactions. A pro-inflammatory compound, tumor necrosis factor alpha (TNF-alpha), appears to play a central role in the biologic reactions that result in nerve damage and symptoms following a disc herniation.

Herniated disc material attracts macrophages, fibroblasts and lymphocytes – inflammatory chemicals are produced by these cells or the disc material itself.

These chemicals include: phospholipase A2, metalloproteinases, prostaglandin E2, leukotriene B4, thromboxane, nitric oxide, interleukin – 6, 8, 12 and tumor necrosis factor alpha (TNF-alpha).

Inflammation – Role In Pain

Awareness that chemical factors are required for production of pain. This changes prior perception of mechanical compression and structural dysfunction as sufficient causes. Lesion size, therefore, need not always correlate directly with extent of pain in discogenic pain production. Patients with significant findings and complaints of lumbar radiculopathy may be found on scans or surgery to have minimal neural compression because symptoms are of an inflammatory etiology. Patients frequently improve well in advance of anticipated or documented morphologic disc change because of improvement in chemical factors.

Spontaneous Herniated Disc Resorption

Intervertebral disc cells produce proinflammatory cytokines TNF-alpha (tumor necrosis factor-alpha) and IL-1beta (interleukin-1beta). Initiators of inflammatory response and are, therefore, referred to as “proinflammatory cytokines” or “alarm cytokines”. Stimulate the production of MCP-1 in the intervertebral disc cells resulting in macrophage infiltration in herniated discs. The infiltrating macrophages also produce MCP-1, amplifying the macrophage infiltration into the discs. Finally, infiltrating macrophages absorb disc materials due to their powerful phagocytic activity and the release of neutral metalloproteinases.

Leaking Nuclear Material Causes Radiating Leg Pain (Radiculopathy)

Peng, BG: et al. Chemical Radiculitis. PAIN 127 (1-2). JAN 2007. p.11-16

To prove by clinical study that an annular tear of a painful disc proved by discography is the cause of radiating leg pain (radiculopathy) in patients with discogenic low back pain.

A significant positive correlation between the site of annular tear and the side of the radiation pain was found. The studies indicated that leakage of chemical mediators or inflammatory cytokines, which are produced in the painful disc, into epidural space through annular tear could lead to injury to adjacent nerve roots, and it might constitute the primary pathophysiologic mechanism of radiating leg pain in patients with discogenic low back pain but with no disc herniation.

Lumbar Herniated Disc Causes Chemical Inflammation of Nerve Root on Opposite Contralateral Side

Nakagawa, Y; et al. Posterior endoscopic surgery for lumbar disc herniation with contralateral symptoms – A report of two cases. MINIMALLY INVASIVE NEUROSURGERY 49 (5). OCT 2006. p.282-285

Two cases of lumbar disc herniation with contralateral nerve root involvement, surgically treated with a microendoscopic discectomy system are reported. Endoscopic observation revealed inflammatory findings of the nerve root on the symptomatic side, such as fibrosis, adhesion, redness and swelling. In contrast, on the non-symptomatic side (ipsilateral side of the disc herniation), the nerve root had been merely compressed by the herniated disc but did not demonstrate any inflammatory findings.

Disc Contour Abnormalities

Normal Disc

The disc contour does not extend beyond the margin of the vertebral body by more than 1-2mm.

Intervertebral discs consist of a central gelatinous nucleus pulposus composed of water and proteoglycans. The nucleus pulposus is surrounded by the annulus fibrosus. The inner portion of the annulus is composed of fibrocartilage, whereas the outer fibers are made of concentrically oriented lamellae of collagen fibers. The annulus is anchored to the adjacent vertebral bodies by Sharpey's fibers.

On MRI, the ideal normal disc is low signal intensity on T1W images, being slightly lower signal than adjacent normal red marrow, and very similar to muscle. T2W images show diffuse high signal intensity throughout the disc, except for the outer fibers of the annulus, which are homogeneously low signal intensity. Distinction between the nucleus pulposus and the inner annulus fibrosus is not possible by MRI.

Normal discs typically do not extend beyond the margins of the adjacent vertebral bodies; however, diffuse extension beyond the margins by 1 to 2mm may certainly occur in some histologically normal discs. The posterior margins of discs tend to be mildly concave in the upper lumbar spine, straight at the L4-5 level, and slightly convex at the lumbosacral junction.

Disc Bulge

A generalized extension of the disc beyond the vertebral body margin. The contour abnormality involves at least 180 degrees (50%) of the disc circumference.

Uniform, generalized protrusion of the annulus fibrosus beyond the vertebral margin. Gradual desiccation of the nucleus pulposus leads to decreased turgor, permitting a decrease in disc space height. The annulus fibrosus develops fissuring, hyaline degeneration and increased pigmentation. The annulus loses elasticity and bulges in a generalized fashion beyond the adjacent body margins. A diffusely bulging disc extends symmetrically and circumferentially by more than 2mm beyond the margins of the adjacent vertebral bodies. The annulus can be considered as lax, and a decrease in disc height and disc signal usually is present on MRI. There are tears in the annulus when there is disc bulging, although they may not be evident on MRI.

Disc Protrusion

A localized abnormality of disc contour wherein the base of the abnormality measured along the circumference of the disc is greater than the extension beyond the circumference, measured perpendicular to the base. Focal protrusions involve <25% of the disc circumference, whereas broad-based protrusions involve between 25% and 50% of the disc contour.

This is a focal, asymmetric extension of disc tissue beyond the vertebral body margin, usually into the spinal canal or neural foramen. The base (the mediolateral dimension along the posterior margin of the disc) is broader than any other dimension. Some of the outer annular fibers remain intact, and some people refer to this as a contained disc. The protruded disc does not extend in a cranial or caudal direction from the parent disc.

Disc Extrusion

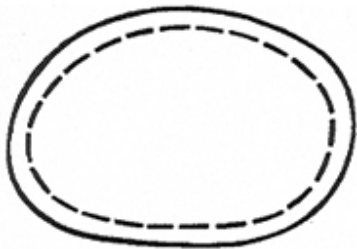
A localized abnormality of disc contour wherein the base of the abnormality measured along the circumference of the disc is greater than the extension beyond the circumference, measured perpendicular to the base.

An extruded disc is a more pronounced version of a protrusion and often is responsible for symptoms. There is disruption of the outer fibers of the annulus, and the disc abnormality usually is greater in its anteroposterior dimension than it is at its base (mediolateral dimension). The extruded disc may migrate up or down behind the adjacent vertebral bodies, but maintains continuity with the parent disc. These also may be referred to as noncontained discs. MRI shows the described contour abnormalities and, because of a significant inflammatory reaction that may occur in response to the extruded disc material, there may be high-signal intensity on T2W and contrast-enhanced T1W images in or surrounding the disc.

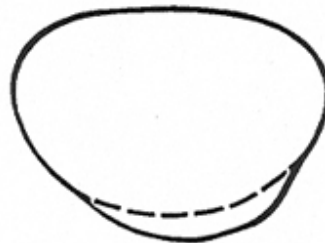Spontaneous reduction in size of disc extrusion and protrusions that were managed conservatively has been well documented with imaging. The larger the disc extrusion, the greater the amount of regression in size of the extruded fragment with time. The regression in disc size may not be the reason for reduction in pain. Much of the pain from extruded discs is probably from the inflammatory response to them, rather than from compression of neural elements from the mass effect.

Sequestered Disc

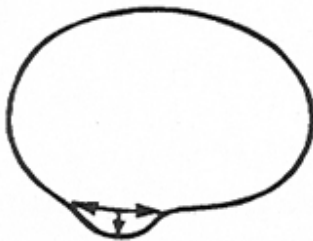
Disc material that is no longer attached to the parent disc and is thus free in either the epidural (commonly) or subarachnoid (rarely) space. When extruded disc material loses its attachment to the parent disc, it is called a sequestered fragment. These may migrate in a cranial or caudal direction with equal frequency and generally remain within about 5mm of the parent disc. They may be located between the posterior longitudinal ligament and the osseous spine or extend through the posterior ligament into the epidural space. They almost always remain in the anterior epidural space, but occasionally the fragment may migrate into the posterior epidural space. The fragment of disc material that migrates from the parent disc often shows peripheral or diffuse high-signal intensity on T2W and contrast-enhanced T1W images, caused by the inflammatory reaction within or surrounding it.




Disc Bulging



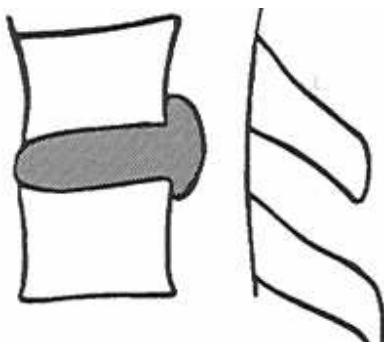
Broad-based Disc Protrusion



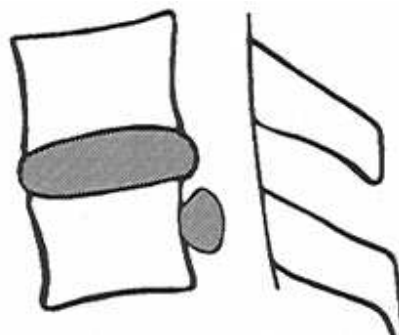
Focal Disc Protrusion



Disc Extrusion



Disc Extrusion



Sequestered Disc

Nomenclature and Classification of Lumbar Disc Pathology
 David F. Fardon and Pierre Milette
 Spine Volume 26, Number 5, pp E93-E113, 2001

Percentage (%) of Height Compared to Normal Level

Mild 75-99
 Moderate 50-74
 Severe <50

Disc Herniation Size

	Lumbar (mm)	Cervical (mm)
Small	<5	<2.5
Moderate	6-10	2.6-5.0
Large	>10	>5.0

Neural Compression Definitions

Mild: 75-99% of normal diameter of the structure maintained
 Moderate: 50-75% of the diameter of the structure maintained
 Severe: <50% of the diameter of the structure maintained

Location of Disc Contour Abnormalities

Central: In the mid-posterior disc. Left or right central may be used if the disc contour abnormalities favor one side or the other
 Subarticular: Lateral to a parasagittal plane through the medial edge of the articular facet but medial to a parasagittal plane through the medial aspect of the ipsilateral pedicle
 Foraminal: Along the foraminal portion of the disc; that is, between the parasagittal planes defined by the medial and lateral aspects of the pedicle

Extraforaminal (or "far lateral"): Lateral to the foramen (lateral border of the pedicle)

Spinal Canal Stenosis Grading Scheme

Mild: The spinal canal has 75-99% of the AP dimension of a normal level.
 Moderate: The spinal canal has 50-74% of the AP dimension of a normal level.
 Severe: Severe spinal canal stenosis. The spinal canal has <50% of the AP dimension of a normal level.

Subarticular Recess Stenosis Grading Scheme

Mild: The subarticular recess has 75-99% of the AP dimension of a normal level, and the traversing nerve root has ample surrounding CSF, without displacement or compression of the nerve root.
 Moderate: The subarticular recess has 50-74% of the AP dimension of a normal level.
 Severe: The subarticular recess has <50% of the AP dimension of a normal level. There is no visible CSF around the nerve root at the level of severe stenosis.

Foraminal Stenosis Grading Scheme

Mild: The neural foramen has 75-99% of the AP and cephalocaudad dimension of a normal level, and the traversing nerve root has ample surrounding

CSF or perineural fat, without displacement or compression of the nerve root.

Moderate: The neural foramen has 50-74% of the AP and cephalocaudad dimension of a normal level.

Severe: The neural foramen has <50% of the AP dimension of a normal level. There is no visible perineural fat around the nerve root at the level of maximal stenosis.

Disc abnormalities are frequent in asymptomatic patients. 20% of subjects younger than 60 years old and 36% of patients over 60 years old have one or more focal disc abnormalities of the lumbar spine, but no symptoms. Only 1% of asymptomatic patients have evidence of a disc extrusion by MRI. Thus, extrusions are much more likely to be significant and cause symptoms.

Disc Tears-Radial

Aging and biochemical changes in the discs are associated with the development of multiple, focal annular tears. Three types of annular tears have been described, but only one type is of practical interest, and that is the radial type of tear.

Radial tears (fissures) involve either part or the entire thickness of the annulus from the nucleus to the outer annular fibers. Radial tears run perpendicular to the long axis of the annulus and occur more commonly in the posterior half of the disc, usually at L4-5 and L5-S1. It may be a pain source because vascularized granulation tissue grows into the tear and causes painful stimulation of nerve endings that also extend into the defect from the surface of the disc; this would result in discogenic pain. It also may be a pain source because of the instability of the disc that accompanies these fissures, and the chemical as well as mechanical irritation to the nociceptive fibers that normally exist in the annulus.

Peripheral Annular Tear (Fissure)

High Intensity Zone or HIZ

Hyperintensity Zone (HIZ) Annular Tear/Fissure

The hyperintensity zone is a localized region of high signal intensity on T2-weighted MRI within the annulus fibrosus. The histopathology of these lesions represents replacement of the normal lamellar structure by a disorganized, vascularized granulation tissue, consisting of small round cells, fibroblasts, and newly formed blood vessels around tears extending from the nucleus pulposus to the outer region of the annulus fibrosus.

MRI of annular tears shows focal areas of high signal intensity on T2W images or on contrast-enhanced T1W images. High signal on T2-weighted images indicates the presence of fluid. Localized inflammation and neovascularization. Irritated or inflamed annular tear.

The presence of an HIZ correlates with an annular tear and an approximately 85% chance that there will be concordant pain reproduced at discography. An HIZ may enhance after contrast administration reflecting the fibrovascular ingrowth into the area of the annular tear.

Carrino J A and Morrison W B, Discography: Current concepts and techniques, Applied Radiology, August 2002

Cervical Disc

1. A thinner posterolateral disc annulus- predisposes toward posterolateral herniation of disc material.
2. Differences in composition of the nucleus. The amount of nuclear material and its fluidity, particularly in any spine past juvenile development, is greatly decreased relative to the lumbar spine.
3. Uncinate processes and joints of Luschka. Osteophytic spurring along these joints narrows the intervertebral nerve root canals, contributing to neural compression. This makes small disc protrusions more likely to be symptomatic because of decreased capacity within the intervertebral nerve root canals and at the same time more difficult to diagnose because of the smaller size of the foramen.
4. The spinal cord is immediately adjacent to the disc margin. Compression of the spinal cord may produce symptoms of myelopathy, particularly if this compression is acute or severe.

Cervical Disc Herniation

Lifting, straining, motor vehicle accident or sports injury. Neck pain and muscle spasm, together with arm pain and sensory symptoms. C5-6 and C6-7 are the most common levels of involvement (C5-6, C6-7, C4-5, C3-4 and C7-T1).

Symptoms (Henderson): 1. Arm pain (99%); 2. Neck pain (80%); 3. Scapular pain (50%); 4. Chest pain and headache are less common. 20-50 years of age. Direction of herniation: Posterolateral - radiculopathy; lateral-radiculopathy; central - less common and may present with less specific neurological findings such as neck pain or intermittent signs of radiculopathy or myelopathy.

Cervical spondylosis: Patients may present with neck pain and a combination of radicular or myelopathic findings often bilateral and usually involving multiple levels. The history of symptoms is usually longstanding. Lower extremity signs and symptoms frequently predominate over those of the upper extremity.

Cervical Nerve Root Syndromes

C3 Nerve Root, C2-3 Disc

Pain and numbness in the back of the neck, particularly around the mastoid process and pinna of the ear. No upper extremity weakness or reflex change.

C4 Nerve Root, C3-4 Disc

Pain and numbness in the back of the neck, radiating along the levator scapulae muscle and occasionally down the anterior chest. No upper extremity weakness or reflex change.

C5 Nerve Root, C4-5 Disc

Pain radiating from the side of the neck to the shoulder top; numbness over the middle of the body of the deltoid muscle (axillary nerve distribution), weakness of extension in the arm and shoulder, particularly above 90 degrees; atrophy of the deltoid muscle; no reflex change.

C6 Nerve Root, C5-6 Disc

Pain radiating down the lateral side of the arm and forearm, often into the thumb and index finger; numbness of the tip of the thumb or on the dorsum of the hand over the first dorsal interosseous muscle. Weakness of the biceps muscle; depression of the biceps reflex.

C7 Nerve Root, C6-7 Disc

Pain radiating down the middle of the forearm, usually middle finger, although the index and ring fingers may be involved. Weakness of the triceps muscles; depression triceps reflex.

C8 Nerve Root, C7-T1 Disc

Pain radiating down the medial aspect of the forearm to the ring and small finger; numbness can involve the small finger and the medial portion of the ring finger. Numbness rarely extends above the wrist. Weakness of the triceps and small muscles of the hands; no reflex change.

Thoracic Disc Herniation

Thoracic disc herniations may cause cord compression and result in myelopathy. Disc herniations of the thoracic spine are less frequent than those of the cervical and lumbar spine and are often accompanied by Scheuermann's disease.

Can occur at any level but are more common at T8-9, T9-10, T10-11 and T11-12. Fourth and Fifth Decades.

The prevalence of degenerative disk disease, both thoracic and lumbar, is higher in subjects who have Scheuermann's disease.

Generally, when the spinal canal is fairly large and has no exaggerated kyphosis, small herniations can exist without manifestations; a marked kyphosis or stenosis predisposes the cord to earlier and more severe injury.

T1 root compression syndrome consists of pain in the neck, medial border of the scapula, anterior chest, and medial aspect of the upper arm and forearm. There may be hypesthesia along the ulnar aspect of the forearm, weakness in the intrinsic hand muscles, and Horner's syndrome.

The discs from T2 to T9 may be associated with pain around the scapula and tip of the shoulder as well as the chest wall that is at times mistaken for gallbladder disease, disorders of other abdominal organs, or diseases of the scapula or shoulder joint. Most patients have a slowly evolving myelopathy.

Signs of thoracic cord compression consist of the following: contraction of the paravertebral muscles, sensory disturbances, and motor weaknesses.

Those with T11-12 and T12-L1 herniation may also have a conus syndrome (i.e., lumbar neuropathy with bladder and rectal sphincter disturbances).

Lumbar Disc Herniation

Level of disc herniations: L5-S1 (50-54%), L4-5(38-45%), L3-4(5-8%)

Direction of lumbar disc herniation: 85-90% posterolateral (paramedian or paracentral), 5-12% central (posterior midline), 5% lateral into the intervertebral canal (IVF).

Central disc herniation typically compresses the thecal sac while sparing the individual nerve root. This leads to low back pain due to sensory innervation to the meninges, posterior longitudinal ligament and outer layers of the annulus fibrosus.

Posterolateral disc herniations may cause nerve root compression leading to back pain that progresses and radiates into the buttock, thigh and leg in the distribution pattern of the involved nerve.

Lateral disc herniations extend into or beyond the neural foramen. It may compress a nerve root as the nerve exits the neural foramen.

Lumbosacral Nerve Root Syndromes

L1 Nerve Root

Back to trochanter and groin. Hip flexion. Associated reflex -cremasteric

L2 Nerve Root

Back. Anterior thigh to the level of the knee. Hip flexion and. adduction. Associated reflex - cremasteric and adductor.

L3 Nerve Root

Back. Upper buttocks to the anterior thigh. Medial lower leg. Knee extension. Associated reflex - patellar.

L4 Nerve Root

Pain - Lower back, hip, posterolateral thigh, across patella, anteromedial aspect of leg. Numbness - Anteromedial thigh and knee. Weakness - Knee extension. Atrophy - Quadriceps. Reflexes - Knee jerk diminished (patellar and gluteal).

L5 Nerve Root

Pain- Sacroiliac region, hip, posterolateral thigh, anterolateral leg. Numbness - Lateral leg, first web space. Weakness - Dorsiflexion of great toe and foot. Atrophy - Minimal anterior calf. Reflexes - None or absent posterior tibial tendon reflex (tibialis posterior and gluteal).

S1 Nerve Root

Pain - Sacroiliac region, hip, posterolateral thigh/leg. Numbness - Back of calf, lateral heel, foot and toe. Weakness - Plantar flexion of foot and great toe. Atrophy - Gastrocnemius and soleus. Reflexes - Ankle jerk diminished or absent (ankle and hamstring).

Toe walk: mostly S1

Toe flexion: S1

Heel walk: L5 and some L4

Dorsiflexion of great toe: L5

Squat and rise: Quadriceps muscles mostly L4

Ankle jerk: Mostly S1

Knee jerk: Most L4

Neither tests the L5

Babinski or Plantar reflex: up-going great toe – the other toes fan out
Normal in children up to 2 years of age

Symptoms of Cauda Equina Syndrome

- Low back pain
- Unilateral or bilateral sciatica
- Saddle and perineal hypoesthesia or anesthesia
- Bowel and bladder disturbances
- Lower extremity motor weakness and sensory deficits
- Reduced or absent lower extremity reflexes

Urinary Manifestations of CES

1. Retention
2. Difficulty initiating micturition
3. Decreased urethral sensation
4. Typically, urinary manifestations begin with urinary retention and are later followed by an overflow urinary incontinence

Bowel Disturbances of CES

1. Incontinence
2. Constipation
3. Loss of anal tone and sensation

Conjoined Nerve Roots

Two nerve roots emerge from a common dural sheath. L5 and S1 are most frequently conjoined and are often mistaken for an extruded disc fragment. Conjoined nerve roots have been reported in 1% of lumbar disc operations and 8% in anatomic specimens.

Synovial Cyst – Facet Joint

A cystic mass that usually communicates with the lumbar facet joint. Related to degenerative facet disease. Females over 60 years of age. Most common at the L4-5 level. Patient may have a degenerative spondylolisthesis at the L4 level. Symptoms

include LBP, radicular symptoms and neurogenic claudication. May have acute pain from hemorrhage into the cyst.

Failed Back Surgery Syndrome

The most common causes: recurrent disc herniation, lateral spinal stenosis, central spinal stenosis, arachnoiditis, epidural fibrosis, residual disc herniation, meningocele formation, nerve injury, wrong-level surgery, and remote phenomena that are unrelated to the spine itself.

Recurrent Disc Herniation vs. Epidural Fibrosis

Surgical removal of a scar usually has a poor outcome, often resulting in further scarring, while surgery for recurrent disc herniation has a good prognosis. Epidural fibrosis usually enhances early on post-enhanced MRI. Recurrent herniated disc does not enhance early or enhances around the periphery only. Utilized pre- and post-contrast MRI to evaluate FBSS.

Failed Back Surgery Syndrome:

- Less than one week following surgery: postoperative hemorrhage, residual disc herniation, and lateral recess stenosis.
- One week to one month: recurrent disc herniation, spondylitis or meningomyelitis.
- More than one month (chronic): recurrent disc herniation, adhesive arachnoiditis and perineural scarring with or without chronic, sterile neural inflammation.

Lumbar Spinal Stenosis

Narrowing of the spinal canal, whether on a congenital, developmental or degenerative basis, is referred to as spinal stenosis.

Congenital stenosis

- Idiopathic
- Achondroplastic

Acquired Stenosis

- Degenerative
 - Central portion of the spinal canal
 - Lateral portion of the spinal canal
 - Degenerative spondylolisthesis
- Combined - any combination of congenital, degenerative and disc herniations
- Spondylolytic, spondylolisthetic, iatrogenic
 - Postlaminectomy
 - Postfusion
- Postchemonucleolysis
- Post-traumatic
- Miscellaneous
 - Paget's disease
 - Fluorosis

Central (Canal) Stenosis

The cauda equina or spinal cord is involved. The patient will most often be male with a history of gradually progressive, chronic back pain prior to developing leg pain. The symptoms can be relieved by sitting, bending forward (flexion sign) (stoop test), squatting or lying down with hips flexed.

Neurogenic Intermittent Claudication

Extension of the spine during walking increases circumferential mechanical compression of the cauda equina. The subarachnoid space is obliterated and congestion of neural blood vessels leads to intraneural edema. This leads to an increase in pressure within the spinal nerves and degenerative of nerve cells. The increase in pressure within the nerves may result in a compartment syndrome causing ischemia of the cauda equina and the onset of neurogenic claudication. Relieved by assuming flexed or hunched posture while walking or by sitting down.

Compression of cauda equina. The patient will complain of leg pain, paresthesias, numbness and weakness initiated or aggravated by standing or walking. They may describe the sensations of numbness, tingling, burning, or a feeling of "heavy, tired" legs and, frequently, anterior thigh pain. There may also be pain at rest, night cramps and restless legs.

Vascular Intermittent Claudication

Decreased blood flow, hypoxia of muscles, cramping and pain.

Lateral Stenosis

Nerve root involvement:

- Subarticular (lateral) recess
- Intervertebral canal (foraminal, nerve exit canal)
- Far lateral (extraforaminal, "far out")
- Lateral spinal stenosis will affect one nerve root level. Pain in the buttock, in the region of the greater trochanter and down the back of the thigh to the knee will be described. Sometimes the pain is down the back or lateral part of the calf to the ankle. Pain is exacerbated by activity and is relieved by rest. The leg feels heavy or weak.

Subarticular stenosis can be fixed or dynamic.

Central Spinal Stenosis Imaging Findings

- Decreased AP diameter of the spinal canal
- Short, thick pedicles
- Thickened laminae
- Vertebral osteophytes
- Hypertrophy of the articular process
- Hypertrophy of the ligamentum flavum
- Generalized disc bulging

Myelopathy

Functional disturbances and/or pathological changes in the spinal cord. Spinal cord compression and ischemia. Cervical myelopathy is a consequence of pressure, tension, and torsion of the spinal cord.

Myeloradiculopathy: Combination of Myelopathy and Radiculopathy,

Causes of Myelopathy

Cord compression, spinal stenosis, OPLL, disc herniation with congenitally narrow spinal canal, tumor, radiation, AIDS, vascular malformations, toxic/metabolic (alcoholism, vitamin B12 deficiency), congenital spinocerebellar degeneration syndromes, infection, post-vaccination, autoimmune (SLE, MS).

Myelopathic symptoms originating at a cervical level include any combination of spastic gait and incoordination, bilateral upper and lower extremity weakness, paresthesias with diminished sensation in the hands, increased DTRs, and upgoing toes. In clinical practice, cervical spondylosis causing extrinsic cord compression is the most common etiology. Less common causes include demyelinating disease, degenerative disease, and inflammatory, infectious, vascular, and neoplastic diseases.

Cervical myelopathy may result when large degenerative spurs or, less commonly, a central HNP occurs in combination with a small cervical canal. The classical clinical triad in these patients includes 1) painful stiff neck, 2) brachialgia, and 3) spastic leg weakness with ataxic gait. There is poor correlation between the presence and severity of these symptoms and the anteroposterior dimension of the spinal canal. There is also an incomplete correlation between the presence of cord compression at MR and myelopathic symptoms.

Cervical Myelopathy

The classical clinical triad in these patients includes 1) painful stiff neck, 2) brachialgia and 3) spastic leg weakness with ataxic gait.

Myelopathic symptoms originating at a cervical level include any combination of spastic gait and incoordination, bilateral upper and lower extremity weakness, paresthesias with diminished sensation in the hands, increased DTR's, and upgoing toes.

Electric sign of Lhermitte (neck bending sign or barber's chair sign): Flexion of neck results in sensation of shock, electricity, and paresthesia with pain and tingling running down the spine or into arms and legs.

Myelomalacia: Cord gliosis and edema. Increased signal intensity within the spinal cord due to demyelination or myelomalacia secondary to chronic compression.

Chiari Malformations

Chiari malformation is a complex congenital anomaly of the posterior fossa accompanied by cerebellar ectopia. The severity of the malformation is dependent on the extent of cerebellar herniation through the foramen magnum. Three types of Chiari malformation are described. Chiari Type I: herniation of the cerebellar tonsils below the

foramen magnum. Chiari Type II: caudal displacement of the cerebellar tonsils, inferior vermis, fourth ventricle, and medulla oblongata, with subsequent cervical cord kinking. Hydrocephalus and syringohydromyelia are commonly associated anomalies. Chiari Type III: herniation of the cerebellum into a cervical-occipital encephalocele.

Chiari I: Inferior displacement of the cerebellar tonsils into the cervical spinal canal. Mild ectopia (less than, 3mm below, the foramen, magnum) is usually of no clinical significance. When tonsils extend more than 5mm below the foramen magnum, the incidence of clinical symptoms rises. Low-lying, pointed (triangular-shape, not round), “peg-like” tonsils.

Up to 50% asymptomatic. May mimic multiple sclerosis. Chiari I “spells”: cough/headache/sneeze/syncope. Symptomatic brain compression and symptomatic syringohydromyelia.

Causes of:

1. Dysgenesis, the cerebellar tonsils are large. Associated anomalies: occipitalization of the atlas, Klippel-Feil anomalies.
2. Tonsillar ectopia as a result of intrauterine hydrocephalus (tonsillar herniation).
3. Acquired deformities of the foramen magnum (platybasia and basilar invagination).

Syringohydromyelia

Cavitation of spinal cord with accumulation of fluid. 20-25% of Chiari I malformations have.

Syrinx: Cavity in the spinal cord. Syrinx may be primary or secondary. Primary: idiopathic or in conjunction with Chiari I malformation. Secondary: Tumor, inflammatory, or trauma.

Hydromyelia: Dilatation of the central canal of the spinal cord.

Syringomyelia: Cavitation of the spinal cord.

Treatment would include suboccipital craniectomy and upper cervical laminectomy, cord cavity drained.

Cysts associated with spinal cord tumors:

1. Tumoral cyst: degeneration, necrosis, and liquefaction within the neoplasm. Contains a mixture of differing elements, such as protein, old hemorrhage, and necrotic tumoral tissue.
2. Rostral or caudal cysts: occur above and/or below the tumor. contain either hemorrhagic or xanthochromic fluid.
3. Reactive dilatation of the central canal, most likely related to partial obstruction of the central canal

Atypical Idiopathic Scoliosis

Atypical clinical or radiographic features: Early onset or rapid progression of scoliosis, presence of pain or Other neurologic symptoms or signs, kyphosis, pedicle thinning, convex left thoracic or thoracolumbar curve, and associated syndromes. Approximately one third of these cases had abnormalities demonstrated on MR studies. Hydrosyringomyelia and Chiari I malformation were the most common findings. Pain is a frequent early presenting symptom in children with intramedullary spinal cord symptoms. Young patient (less than 11 years of age). Severe or rapidly progressing thoracic/ thoracolumbar scoliosis (particularly left-sided). No family history of scoliosis. Unusually rigid scoliosis in a young patient. Scoliosis which is associated with pain and is unresponsive to conservative treatment.

Abnormal neurological findings: Muscular weakness and/or atrophy, sensory loss (particularly pain and temperature), bladder/bowel dysfunction, unexplained/ painless swollen joint (Charcot's joint), abnormal superficial abdominal wall reflex, abnormal deep tendon reflexes (increased or decreased), and cranial nerve abnormality.

Abnormal radiographic findings: Segmentation defects, platybasia, basilar impression, increased spinal canal diameter, posterior body scalloping, and pedicle widening.

White Matter Diseases in Adults

Multiple sclerosis (MS) and variants

- Acute disseminated encephalomyelitis

- Hurst hemorrhagic leukoencephalitis

Vascular disorders

- Ischemic arteriolar disease (microangiopathy)

- Boundary zone ischemia (unilateral carotid disease)

- Arteritis (eg, systemic lupus erythematosus (SLE), sarcoidosis)

Infectious/immune disorders

- Acquired immune deficiency syndrome (AIDS) related disorders

- Progressive multifocal leukoencephalopathy

- Lyme disease

Vasogenic edema

Traumatic shear injury

Radiation injury/necrosis

Metabolic disorders

- Central pontine myelinolysis

- Marchiafava-Bignami disease

- Adult leukodystrophies

Multiple sclerosis is the most common white matter disease and is related to focal areas of demyelination with reactive gliosis in the white matter of the brain, spinal cord, and the optic nerves.

Clinical Presentation: Exacerbations and remissions of multifocal neurologic deficits. Impaired or double vision. Fatigue, weakness, numbness, tingling, and gait disturbances. Loss of sphincter control, blindness, paralysis and dementia. Onset 20-40. More common in persons of Western European lineage who live in

temperate zones.

Individuals who migrate in early childhood from a low-risk to a high-risk area have the same risk of developing MS as those in the area they move to. If the same move is made after adolescence, the risk remains low.

- Familial incidence.
- HLA antigens: HLA-A3, HLA-B7, HLA-DR2.
- Cerebrospinal Fluid: Mild lymphocytosis, slightly elevated protein, and oligoclonal immunoglobulin bands of IgG on immunoelectrophoresis.
- Visual, auditory and somatosensory evoked responses.
- Lhermitte's Sign: Electric-like shocks spreading down the body on forceful flexion of the head and neck.

Neoplasms of Nerve Roots, Dura and Spinal Cord

- Extradural
- Intradural extramedullary
- Intramedullary

Incidence of Intraspinial Neoplasms

- Schwannomas 30%
- Meningiomas 26%
- Gliomas 23%
- Sarcomas 11%
- Hemangiomas 6%
- Other 4%

Schwannomas

The most common primary intraspinal tumor is the schwannoma. Schwannomas are extramedullary-intradural tumors composed of Schwann's cells, which arise from spinal nerves at any level (cervical, thoracic, lumbar or cauda equina) and most often arise from a posterior (sensory) nerve root. The most common initial symptom therefore is pain in a radicular distribution. Schwannomas grow slowly and pain may be present for years before the correct diagnosis is made, especially when the schwannoma is in the relatively spacious lumbosacral region. Schwannomas of nerve roots in the relatively tight cervical region compress the spinal cord early in their course. Neurofibromas are composed of Schwann's cells and fibroblasts.

Meningiomas

Meningiomas are the second most common primary intraspinal tumor. Spinal meningiomas have a marked propensity to occur in the thoracic area, and they are rare below the midlumbar level. Like schwannomas, meningiomas are slow-growing, extra-medullary-intradural tumors. The clinical picture usually evolves over months to years before the diagnosis is made. Thoracic area, fifth and sixth decades, women 80%.

Astrocytomas and Ependymomas

The most common intramedullary spinal tumors are the gliomas, which comprise mainly ependymomas and astrocytomas. The ependymomas predominate in the cauda equina and lumbar region; the astrocytomas in the cervical region. The clinical syndrome

produced by these tumors is usually indistinguishable from that produced by extramedullary tumors. Spinal gliomas are slow-growing tumors, and a history of deficits of several years duration is common. Children - astrocytomas 60%, ependymomas 30%. Adults - ependymomas 55-60%, astrocytomas 30-40%

Ependymoma: Lower cord, conus and filum. Third to sixth decades. Myxopapillary tumor of filum (young adults).

Astrocytoma: More common in children (60% of intramedullary tumors). Cervical or thoracic areas (rostral more common in children)

Approximately 60% of intramedullary spinal tumors are associated with syrinx.

Bone Tumors

Most common primary malignancies of bone: 1-MM, 2-osteosarcoma, 3-chondrosarcoma. Most common malignancy of bone: MCa.

Most common primary bone tumors in children: 1-osteosarcoma, 2-Ewing's sarcoma. "Round cell tumors: Ewing's sarcoma, MM, and non-Hodgkin's lymphoma (reticulum cell sarcoma).

Metastatic Carcinoma

80% from: breast, prostate, lung, kidney. 75% lytic: lung, kidney, breast, thyroid, GI, neuroblastoma. 15% blastic: prostate, breast, bladder, GI (stomach, carcinoid) lung, medulloblastoma. 10% mix: Breast, lung, prostate, bladder, neuroblastoma. Involve axial skeleton, proximal humerus, and proximal femur. Acral metastasis (distal to elbow and knee) are rare and usually due to lung carcinoma. Solitary metastasis: lung, thyroid, kidney. Expansile, bubbly lesion (blow-out): renal, thyroid. Ivory vertebra: osteoblastic MCa, Paget's, Hodgkin's. Pedicle destruction: one-eye vertebra (winking owl) Cancer incidence: male-prostate, lung; female - breast, lung. Cancer deaths: male and female - lung.

Lab: ESR increased. Lytic: urinary calcium increased, serum calcium and phosphorous normal or increased, serum alkaline phosphatase normal to increased. Blastic: serum calcium normal, urinary calcium low, serum alkaline phosphatase usually increased. Carcinoma of prostate: increased serum acid phosphatase with local extension or distal spread, PSA increased in 80%.

MRI: infiltration of marrow by tumor cells, decreased signal on T1-weighted images.

Multiple Myeloma

Malignant proliferation of plasma cells. 50-70 years of age. Male 2:1. Back pain, anemia, repeated bacterial infections. Lab: anemia, increased ESR, increased serum calcium, serum alkaline phosphatase normal or slightly increased, uric acid increased in 60%, elevated serum total protein (increased globulins), reversal of A/G ratio, electrophoresis of serum and urine - monoclonal protein spike, Bence Jones proteinuria (35-50%), bone marrow aspiration (20-50% plasma or myeloma cells). Skull, vertebral bodies, ribs, proximal appendicular skeleton. X-ray: multiple round lytic lesions (punched-out) or generalized osteopenia with compression fractures (vertebra plana).

Raindrop skull. Plasmacytoma: solitary form. Expansile, geographic pattern. Vertebral bodies, pelvis, femur, humerus. Progresses to multifocal disease.

Hemangioma

Most common benign tumor of the spine. 10-11% at autopsy. Thoracolumbar (L1-L3). Asymptomatic in most cases. Composed of newly formed blood vessels. X-ray: coarse, vertical striations interspersed with areas of radiolucency (corduroy cloth appearance, striated vertebra, jailhouse vertebra).

Spinal Infection

Children, 3:1 males, Staphylococcus aureus most common. Drug abusers have increased incidence of Pseudomonas, Klebsiella, Enterobacteria and Serratia osteomyelitis. Sickle cell patients have increased incidence of Salmonella. Routes of involvement: Direct penetrating wound, contiguous spread from adjacent soft tissue to bone and hematogenous spread. Latent period: 10 days in the extremities, 2-8 weeks in the spine. Cause: GU tract - 72%, lung infection - 14%, dermal infection - 14%. Lumbar spine most commonly involved. GU infections are a frequent source of spine infection. The infection starts in the subchondral portion of the body, then extends to the disk and adjacent vertebral end-plate. Decrease in disc height with adjacent end-plate abnormalities (irregularity and loss of cortex). Staphylococcus aureus, Salmonella, back pain, fever, leukocytosis, increased ESR.

Osteoporosis Risk Factors

- Being female
- Small, thin frame
- Advanced age
- Family history of osteoporosis
- Early menopause
- Amenorrhea
- Anorexia or bulimia
- Diet low in calcium
- Use of certain medications (steroids, excessive thyroid hormones, etc.)
- Low testosterone levels in men
- Sedentary lifestyle
- Cigarette smoking
- Excessive alcohol intake

Some of the risk factors linked to osteoporosis include: increasing age, female gender, White or Asian ethnicity, family history, estrogen deficiency, calcium deficiency, Vitamin D deficiency, low body weight for height, sedentary lifestyle, alcoholism, and smoking.

Most of these risk factors are strongly associated with low bone mineral density, which in turn is a strong predictor of fracture risk. In general, each standard deviation drop in bone mineral density below the young-adult mean increases the risk of fracture two to three times. Some bone loss occurs with aging in both men and women, but there

appears to be an acceleration of loss that coincides with menopause. Loss tends to occur in the axial or central skeleton where there is a greater proportion of trabecular bone.

Generally speaking, the risk of osteoporotic fractures increases dramatically with, increasing age, and the incidence of fractures is greater among women than men. Not surprisingly, fractures tend to occur at sites of the most bone loss, namely those containing large amounts of cancellous or trabecular bone. The hip, spine and wrist are most common fracture sites associated with osteoporosis.

The lifetime risk of any one of the most common fractures - hip, vertebral or wrist - is almost 40% in white women and 13% in white men age 50 and older. All osteoporosis-related fractures incur significant morbidity and mortality. The consequences of these fractures can include chronic disability, loss of independence and decreased ambulation. Approximately half of those who are able to walk unaided before experiencing a hip fracture cannot walk unassisted afterward.

Hip fractures are the most serious of the osteoporosis-related fractures with respect to mortality. They are associated with reduced expected survival rates of 12% or more, with the greatest risk for mortality occurring 3 to 4 months after the fracture. Low bone mass is the single most important determinant of risk of fragility fracture.

T Score

The World Health Organization (WHO) recently introduced diagnostic criteria for osteoporosis based on measured bone mass and optimal peak adult bone mass. The unit of measurement for these criteria is the T score, with a T score of 0 being the mean for peak adult bone mass, and -1.0 being 1SD below this mean. WHO defines normal bone mass as any T score between +1 and -1. Low bone mass (osteopenia) is indicated by a T score between -1 and -2.5. A patient with a T score of -2.5 or lower is classified as having osteoporosis. Severe disease is defined as osteoporosis complicated by fragility fractures.

Z Score

Refers to the number of standard deviations above or below the mean for persons of the same age. The average Z score for any age group (for example, age 70) is 0. Thus, the Z score for an individual whose BMD is 1 standard deviation below the mean for other people her age would be -1.

Osteoporotic Compression Fractures

Age-related osteoporotic compression fractures occur in more than 500,000 patients a year (USA). May cause persistent often excruciating pain which impairs mobility and reduces the patient's quality of life.

Vertebroplasty

Percutaneous injection of polymethylmethacrylate bone cement (PMMA) into vertebral bodies. Strengthening osteoporotic vertebral bodies and improving the integrity of vertebral compression fractures

Kyphoplasty

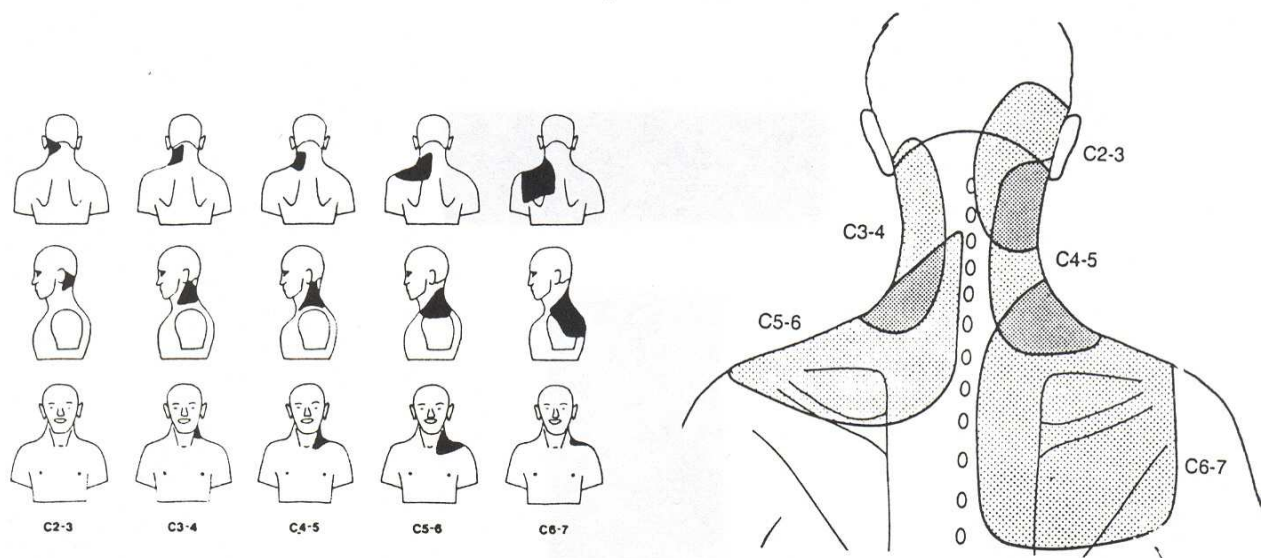
Spine fractures reduced by inflatable bone tamp (balloon), followed by vertebroplasty.

Zygapophyseal Joint Pain After Whiplash

Neck pain due to post-traumatic arthropathy. Headache from referred pain.

Cervical Zygapophyseal Joints

Innervated by articular branches derived from the medial branches of the dorsal rami. Ascending branch innervates joint above and descending branch innervates joint below (dual innervation)



Lin, RM. Characteristics of Sagittal Vertebral Alignment in Flexion Determined by Dynamic Radiographs of the Cervical Spine. Spine 2001;26:256-261.

Using flexion x-rays of the cervical spine, nearly all the intervertebral differences of angular motion were less than 7 degrees and those of translation were less than 0.6mm.

Alteration of Motion Segment Integrity (AOMSI)

Cervical spine: is assessed by plain film flexion-extension radiographs only. A diagnosis of AOMSI in the cervical spine by translation measurements requires greater than 20% anterior or greater than 20% posterior relative translation of one vertebra on another, on flexion or extension radiographs, respectively. Or angular motion of more than 11° greater than each adjacent level on the flexion radiograph.

A diagnosis of AOMSI in the thoracic spine by translation measurements requires at least 2.5mm anterior or 2.5mm posterior translation of one vertebra on another, on flexion or extension radiographs respectively.

A diagnosis of AOMSI in the lumbar spine (L1-L5) by translation measurements requires greater than 8% anterior or greater than 9% posterior relative translation of one vertebra on another, on flexion or extension radiographs respectively. In the lumbosacral spine (L5-S1), it requires greater than 6% anterior or greater than 9% posterior relative translation at L5-S1 of L5 on S1 on flexion or extension radiographs, respectively.

A diagnosis of AOMSI in the lumbosacral spine by angular motion measurements requires greater than 15° at L1-2, L2-3, and L3-4; greater than 20° at L4-5, or greater than 25° at L5-S1 (compared with adjacent level angular motion).