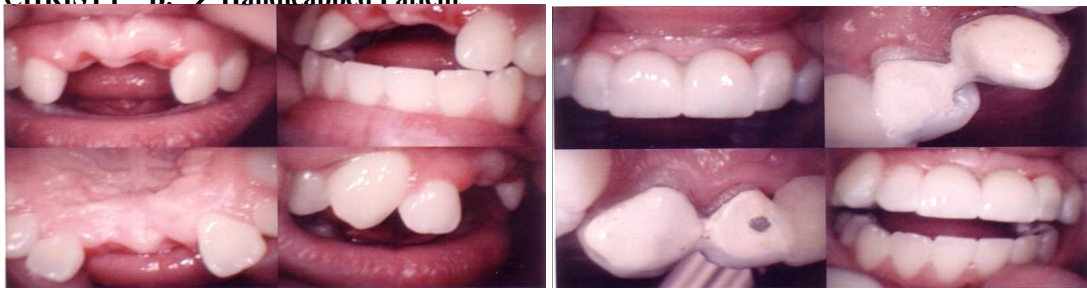


Case Study 12

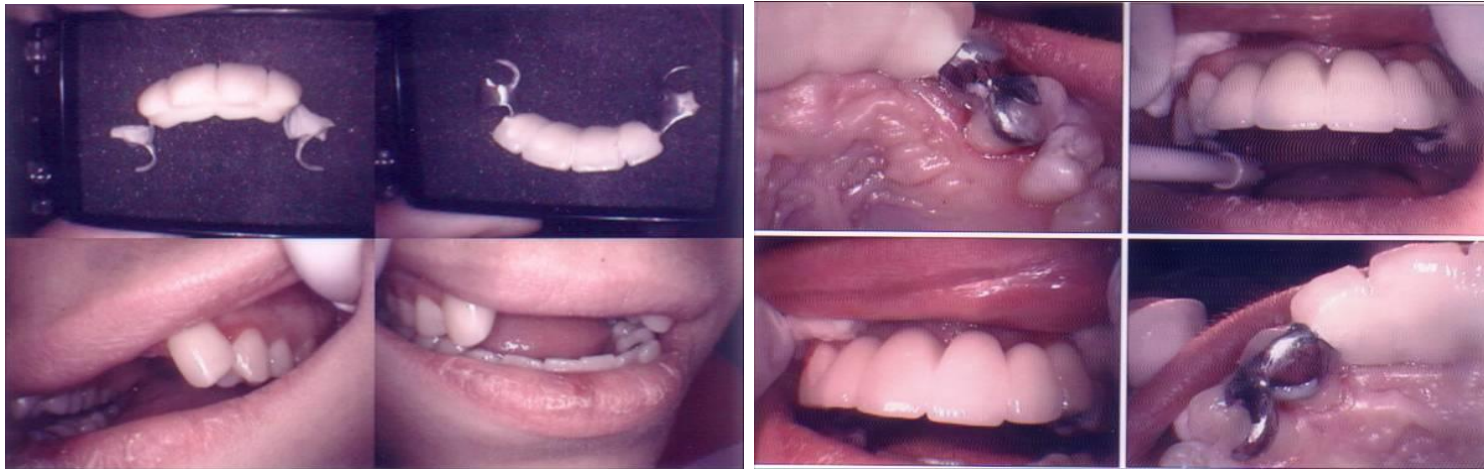
T. Bob Davis, DMD

CASE REPORT - INSTALLMENT #12
CHRISTY B. → Handicapped Patient



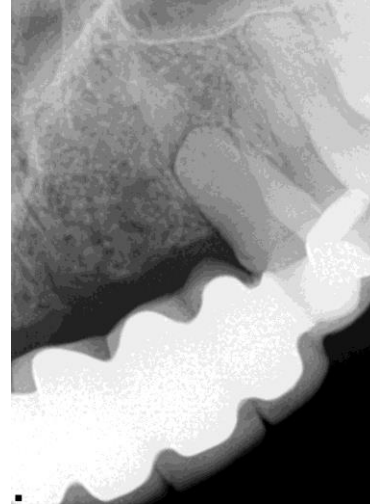
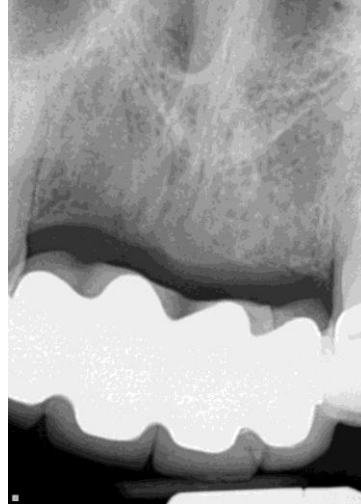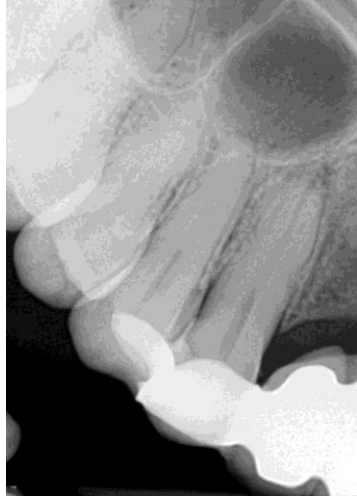Now 36 years old- mental age +4. At age 4, she had the croup and a local hospital failed to intubate her adequately until she had stopped breathing 4 -5 minutes. Christy went through braces and wisdom teeth extractions as a teenager. Her bite and ortho result was beautiful. Due to incompetent lips and a series of falls, her bite opened up anteriorly and she broke out her two maxillary anterior front teeth. It was a bad fall and her parents took her to a nearby oral surgeon who removed the two teeth, sewed up her gums and told her to come back for implants in three or four months. I felt implants were risky for her due to the bone loss and potential for more seizures and falls. The parents agreed on a MB and we made the first one 4/22/97. Seated with Enforce - 6,7 double abutment as well as 10 & 11. It looked and fit great. We even put porcelain on the lingual wings. In a year she started her vertigo problems in full bloom. They tried restraining straps on her wheelchair, on her seat at home, even a helmet to wear often. Naturally, you can't sleep in a helmet, nor shower and go to the bathroom in a restrainer or helmet. She has experienced an average of once a year falling that has knocked the bridges out over the 19 years they have been used.

- Fell 3/10/98 - rebonded RelyX ARC
- Fell 4/17/01 - rebonded RelyX ARC
- Fell 5/27/03 - Chipped porcelain- refired porcelain repair. Rebonded RelyX ARC
- Fell 8/18/03 - Broke out MB and lost #10. Made a new MB
- Fell 11/06/03 - Fell out of wheelchair and I thought maybe the metal was bad. Remade it.
- Fell 8/17/05 - lasted 2 years and she fell and hit her face hard and tore tooth #7 almost out and bent MB badly. We remade and on 10/13/05 resealed with RelyX ARC 6x11,12 double abutment
- Fell 4/03/06 - hit bathroom counter - resealed with RelyX ARC
- Fell 12/4/08 - Again in middle of night. She gave parents her MB in a baggie next morning and told them she had fallen out of bed. Resealed with RelyX ARC
- Fell 3/23/09 - This time in her MD's office - had a seizure and hit mouth. We made a new one this time double abutting 5/6 and 11/12. Remarkably, #11 is still hanging in there with little bone around it. Rebonded with RelyX ARC
- Fell 5/27/09 - Hanging up her clothes. Again bruised face and lips. Resealed RelyX ARC.
- Fell 9/3/09 - Again bruised face and eye and cheeks. Resealed with RelyX ARC.
- Fell 12/30/09 - Again on bathroom counter. #11 very loose/sore. Bent abutments . Lab adjusted. Rebonded RelyX ARC
- Fell 6/7/10- Knocked bridge out 5x12. Wound on upper and lower lips required two sutures. Lab cleaned and re-etched 6/14/10- Resealed with RelyX ARC
- Fell 1/26/11- Fractured porcelain #10, broke bridge out. 4 sutures in upper lip. Lab repaired.
- 2/8/11- Seated 5x12 with RelyX ARC
- 1/10/12- Maryland Bridge came out, etched and rebonded with RelyX ARC
- Fell 2/27/13- Knocked out MB, re-etched and rebonded with RelyX ARC
- 12/16/13- Area 5-6 was loose, re-etched and rebonded with RelyX ARC
- 7/7/14- Added RelyX ARC to facial and occlusal #5 & #6. Patient now wears soft cushion helmet all the time and uses a wheelchair and walker.



We remove the old composite resin off the teeth and send the bridge to lab. They return it in a couple hours and we reseat with RelyX ARC. Imagine if you had a traditional bridge there. You'd have a mess on your hands. Snapped off roots, porcelain off at least, probably root canal needs on abutments. Even worse, imagine having chosen implants as the Oral Surgeon proposed! What a mess her lips, cheeks and other teeth would have been in! How long would replacements take if the implants got knocked out with bone? Unthinkable. And why not put a removable partial denture? No way could she keep up with it. They'd be lost and broken too! So this MB treatment is my Break-Away-Basketball-Net Solution. The upper alginate impressions are very easy on our patient, the teeth are not offended by alginate and it is accurate enough in a traumatized situation like this. Not only is this a reasonable repair, it is a compassionate repair. Done in a couple hours for reseating or remade in 2 weeks, long enough for lips, cheeks, eye and gums to heal before rebonding new one. Now that she has no incisal capacity we don't need anything more than a Blue Moose bite - no opposing impression needed. Christy and I are best of friends and her parents drive her up to two hours in bad traffic to see me. They take the 2nd and 4th worst congested freeways in Texas to come to our office. We've maintained Christy's beautiful smile and self-image in what would have been a true compromise by any other treatment modality!

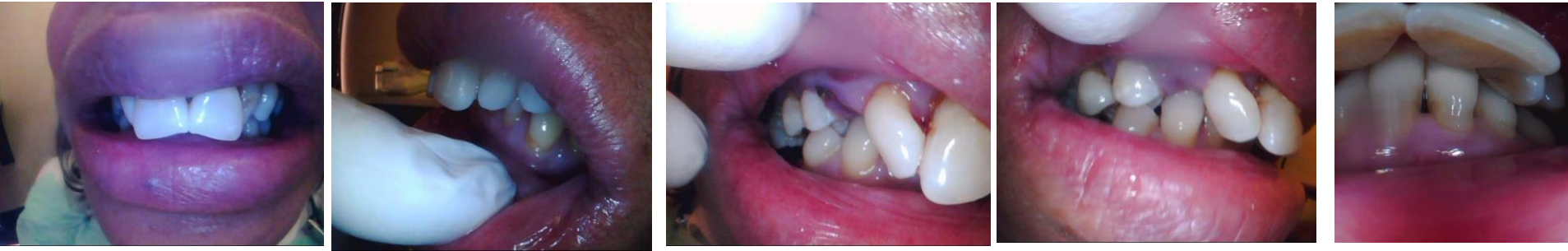This case has been one of the most rewarding personally of any Maryland Bridge case. Rewarding by the appreciation of parents and patient plus the knowledge that we have kept her smiling through some of the most traumatic and challenging years of her life. THAT is one of the many reasons I continue to thoroughly enjoy dentistry!!!



Christy's X-rays
April 2, 2015

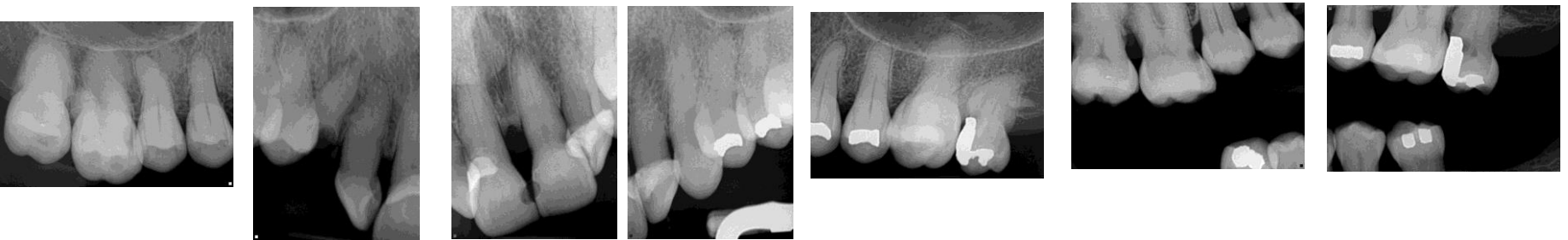
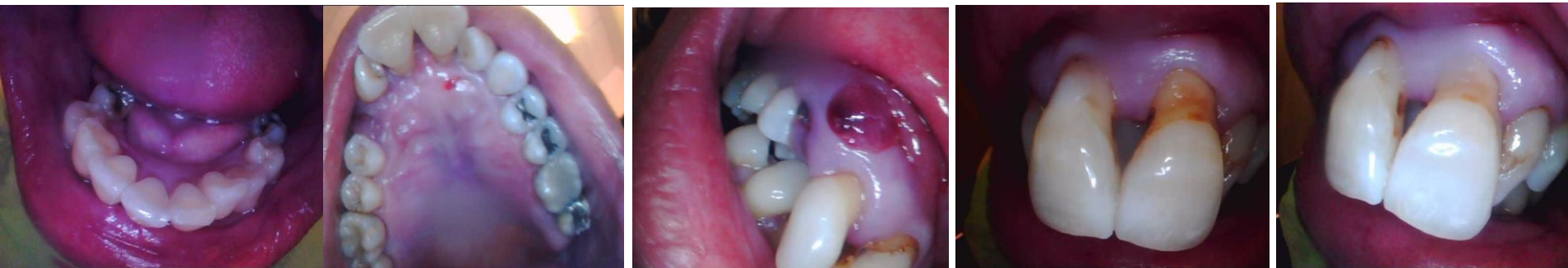Daralyn A

This patient was referred to our office because of compromised esthetics due to maxillary protrusion/proclination of all upper anterior teeth, hyper mobility due to gum loss/ abscesses, severe crowding/rotations, the inability to eat or speak adequately, which all together were preventing her from getting a job. A rehabilitation group for women in crisis made the referral with a request that we provide the charity care, with support of a local dental lab that would do lab procedures free. Our first examination revealed a larger problem in that the lower posterior molars had been removed previously and #29 was rotated and totally lingually positioned.



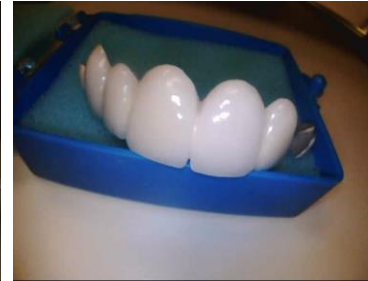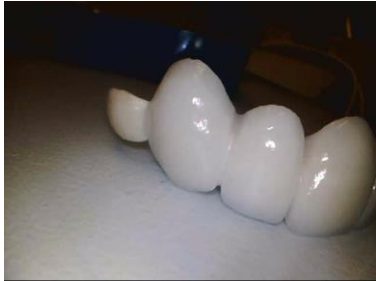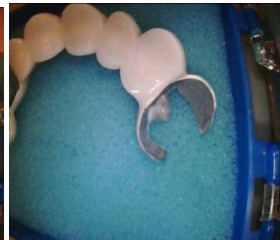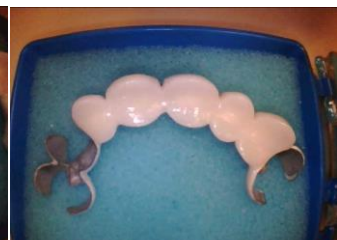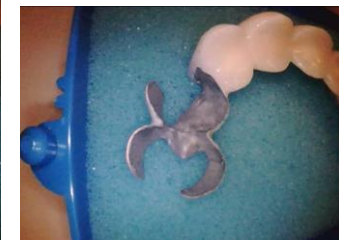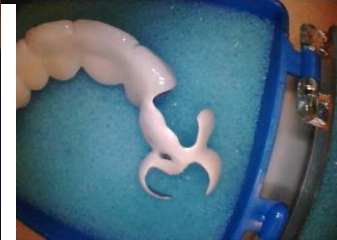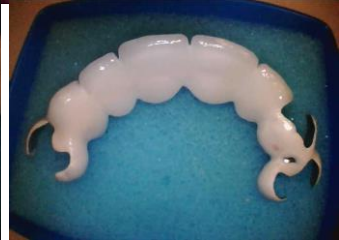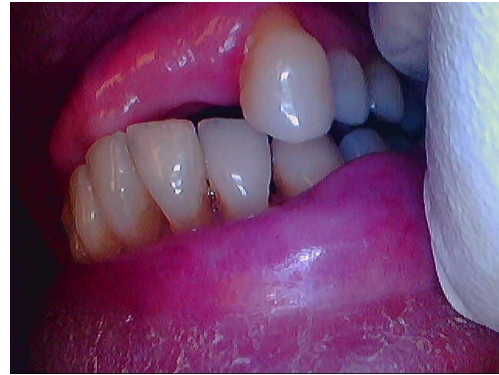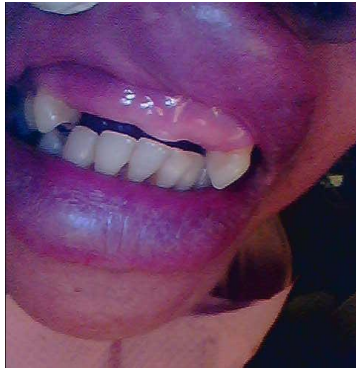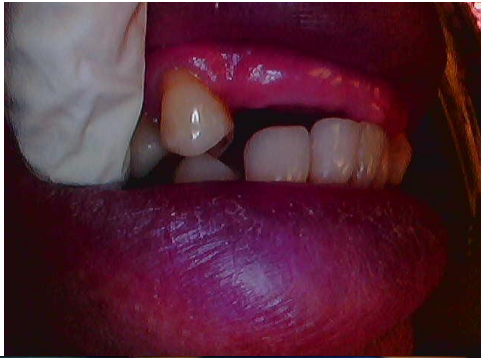Without lower to upper posterior support and occlusion, clearly she would benefit very little from just replacing the upper anteriors. Our diagnosis suggested she should keep #29 by our orthodontically rotating it and repositioning it into occlusion with the upper teeth, followed by a new lower cast metal frame/acrylic teeth that would provide her with the ability to chew her food and return to some degree of physical health.

The lower anterior teeth were reasonably positioned and safe from harm. The upper anterior teeth #6,7,8,9, 10 were hopelessly non useable in any treatment plan! Her upper lip was incompetent and did not let her adequately close her mouth with those teeth in place. Extraction was the only option.

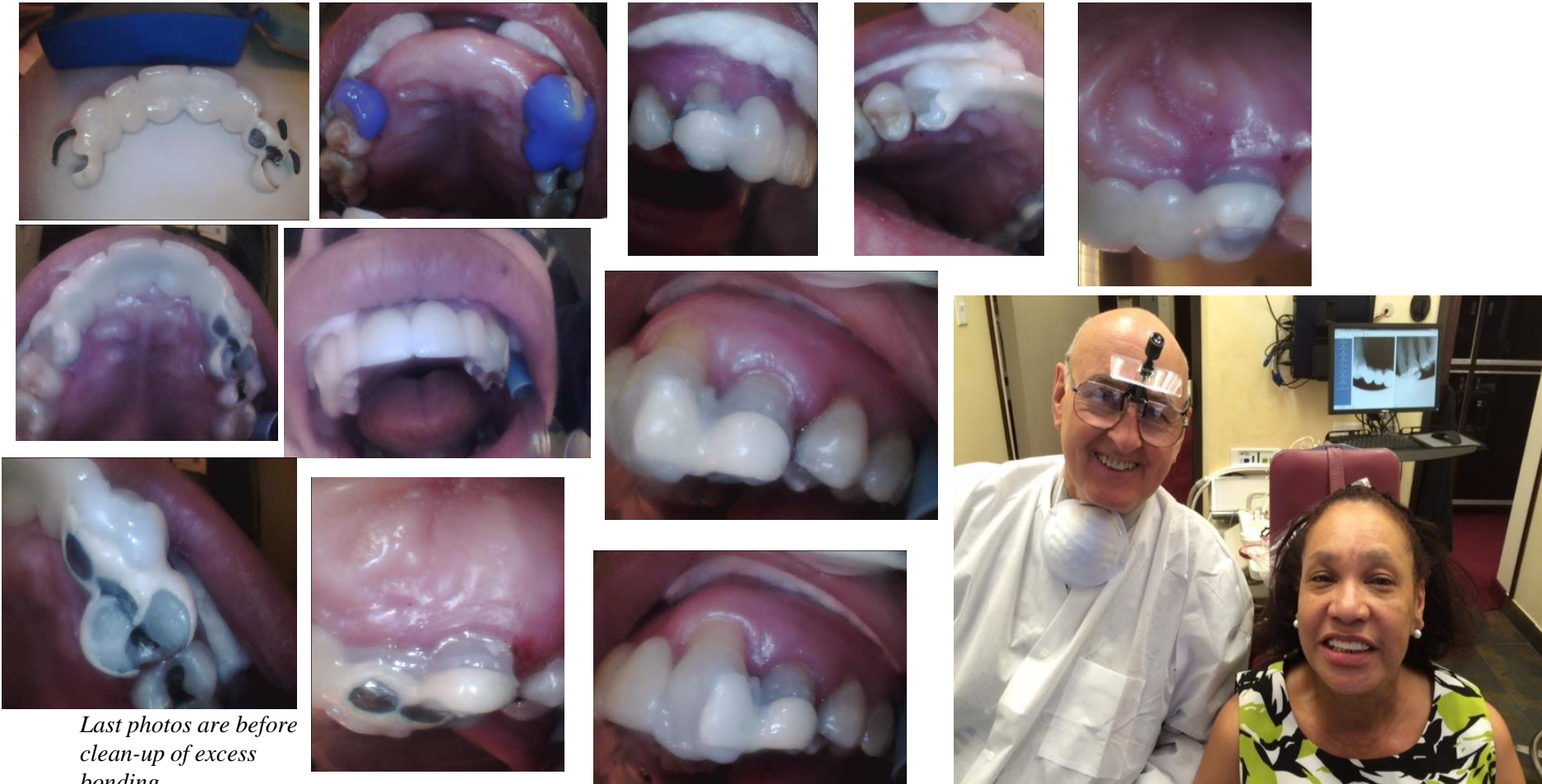

As charity, we spent months in uprighting the lower right 2nd bicuspid with removable appliances and used a temporary maxillary Hawley appliance with the replacements of extracted upper anteriors. This system looked adequate and gave her the ability to get a job and start supporting herself financially, for which we were all pleased. Once the lower partial was placed, she had gained a lot of self confidence and was functioning quiet well as best we could determine.

However, the upper Hawley was bulky, not ideal, and had to be held in with the addition of Polygrip daily. We discussed the possibilities of making a five pontic Maryland Bridge for the missing teeth and she was starting to save up for our offer of a steeply discounted permanent etched resin bonded metal to porcelain bridge...only to drop her little upper partial in the car and crushed it into unrepairable status. Thus, another crisis. This time she was confident that she could handle it and she gathered together the much reduced cash price and paid up front for the new Maryland Bridge.



Note the beautiful esthetics, functional occlusal and lateral movements available, and the prospects of improving the occlusals and esthetics in the posterior with composite bonding, an alternative to very long term and expensive standard orthodontics she could not afford. She is feeling awesome and so ecstatic with a renewed smile, ability to speak properly, chew normally, and function as a respectable member of her new found profession of working with end of life patients as a caregiver!



Last photos are before clean-up of excess bonding

The value of this case represents the very best of dentistry; taking a person who is unemployable, down on their life, with low self esteem, sharing the responsibility of rehabilitating with an outside group, going the extra mile of doing what is better than minimal, and seeing to fruition through thick and thin in relationships the beautiful, healthy, and happy end... which is really new beginnings! Our whole profession of dentistry promotes such altruism coupled with individual responsibility.