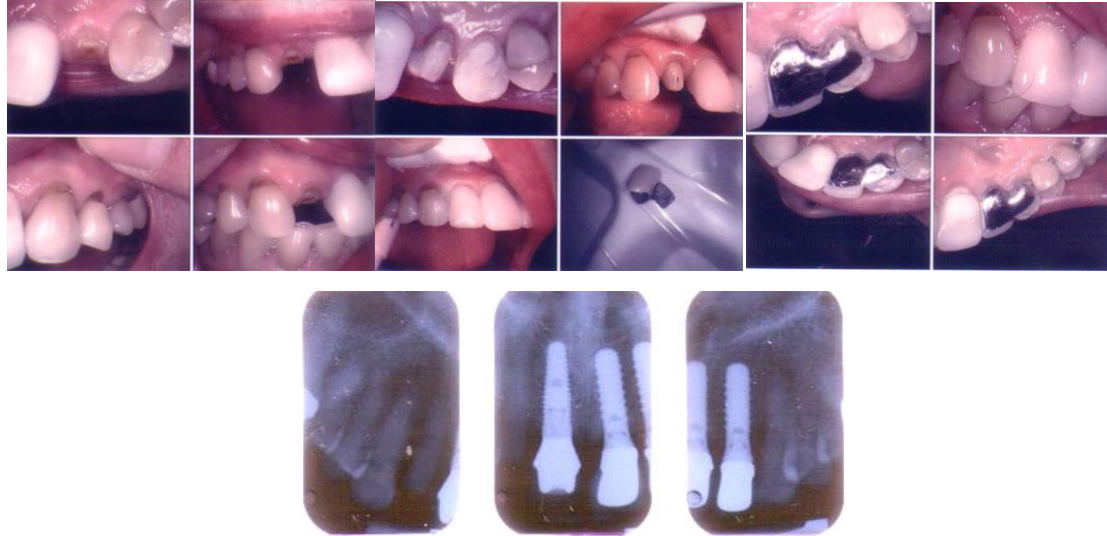


# Case Study 11

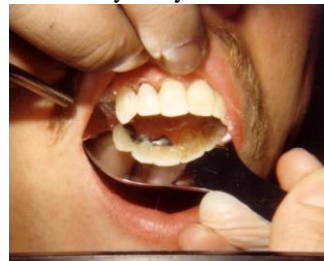T. Bob Davis, DMD

**CASE REPORT – INSTALLMENT #11**  
**Stabilizing Maryland Bridges**

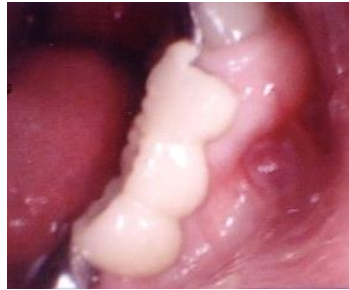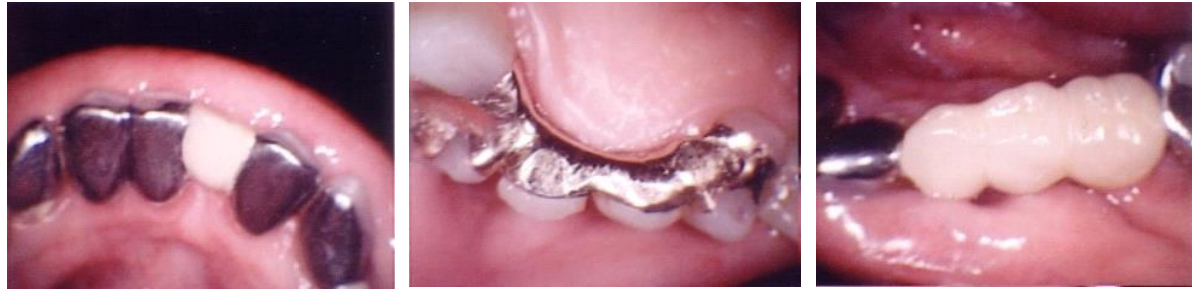**GLEND A W.** – Patient came to me after implant dentist told her he could not place implant in area #7 . Root still present when she arrived, healthy but sheared off at gum line. After discussing options, patient chose to have a build-up on root (no root canal needed), a porcelain fused to metal crown with a stabilizing MB wing to bond to #6. Excellent esthetics and match for neighbor implant crowns! Severe abrasion, abfraction, erosion. Glenda has experienced 7 years success. Highland Lab.



**BOB H.** – This patient arrived in our practice with periodontal disease, mobile loose teeth, especially #7, and lots of decay. We reestablished periodontal health over time and did full mouth rehabilitation. #7 was crowned on a core build-up with porcelain fused to metal crown and a MB wings low down on the lingual gingival thirds of #6 and #8. This periodontal stabilization lasted from 2/23/1983 until 8/30/2005, 22 years with one rebond of #8 on 10/20/1984 and #6 on 8/7/1992. In 2005, I replaced system with single porcelain fused to metal crown #7 without wings due to perio stability. No more mobility! Mission accomplished! Point made! Stabilization works! MB wings can fit every periodontists' need for select cases! Note mirror view of lingual wings and crown – also beautiful esthetics of #7 crown facially. 22 years success until no longer needed!

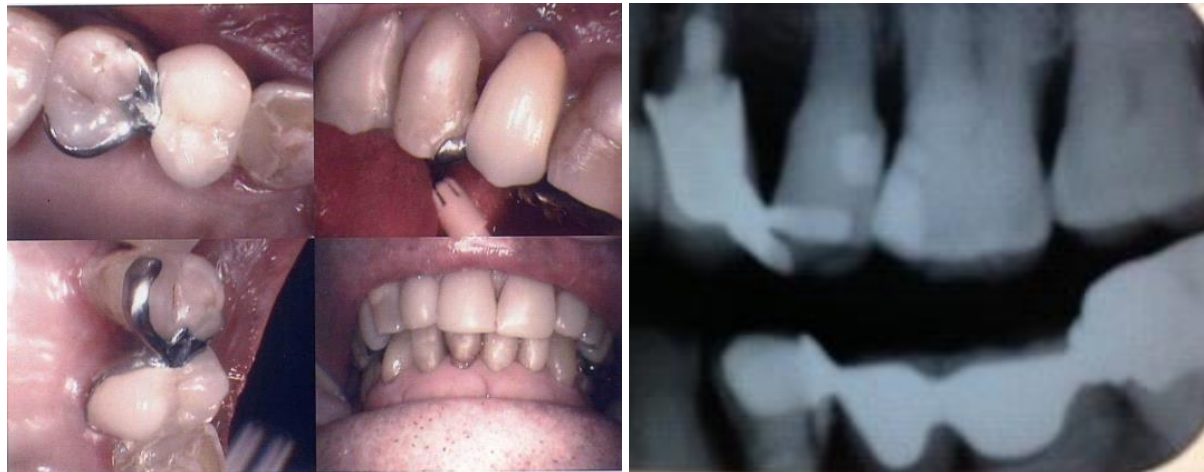

**GEORGETTE Z.**



Lower anteriors were periodontally mobile from decades of a lower partial use that broke and needed two MBs in posterior and one anterior. Splinting the lower anteriors while replacing one missing tooth with a pontic resulted in 13 years of excellent success until patient died.

**HOMER C.**



Mr. C. at age 89 had a very short root and long crown on #12 that was mobile. By attaching a MB wing on the healthy and stable tooth #13 we were able to maintain #12 safely for eight years later.