

*Evaluation & Management of the
Crossed Syndromes*

Richard Schuster, DO

Shawn R. Kerger, DO, FAOASM

- Philip Greenman, DO, FAAO
- P. Gunnar Brolinson, DO, FAAFP, FAOASM
- Paul Tortland, DO, FAOASM
- Albert Kozar, DO, FAOASM

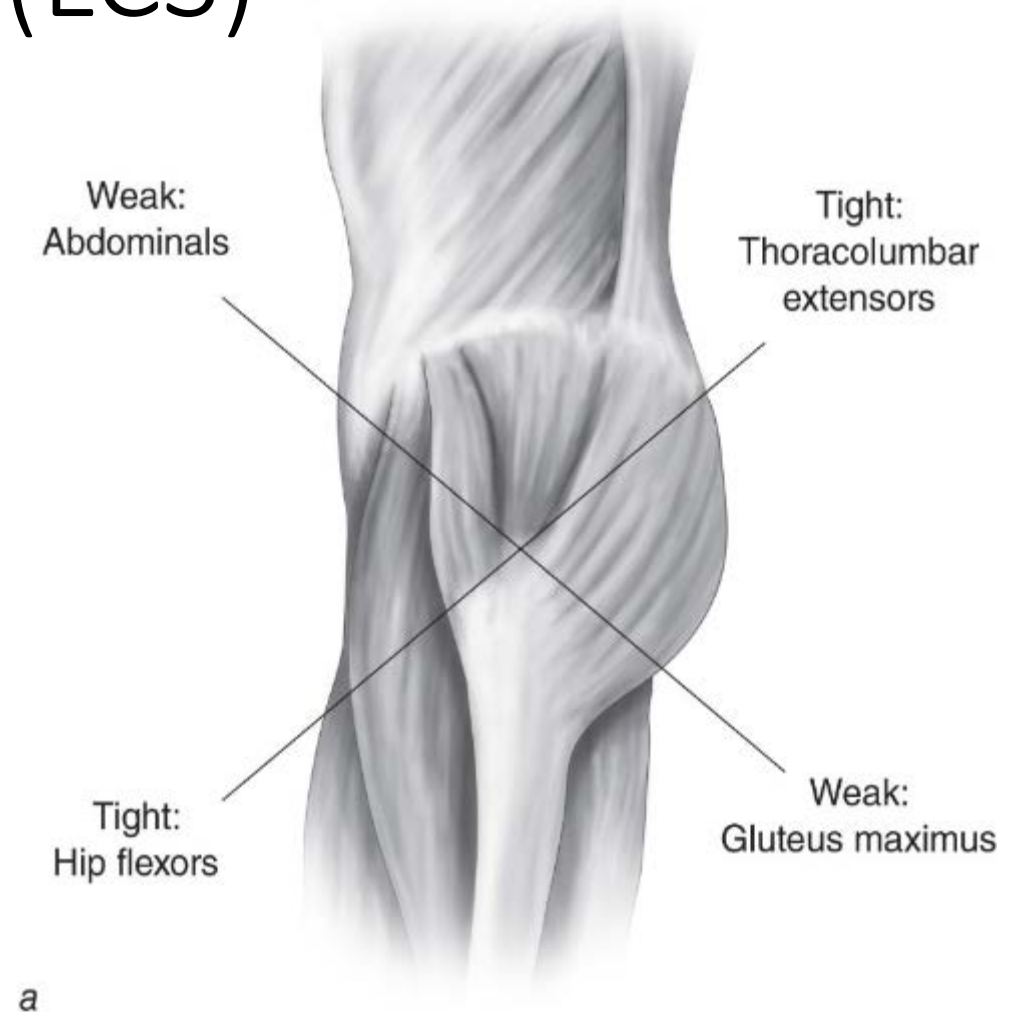


Lower Crossed Syndrome

(aka, Distal or Pelvic Crossed Syndrome)

Lower Crossed Syndrome (LCS)

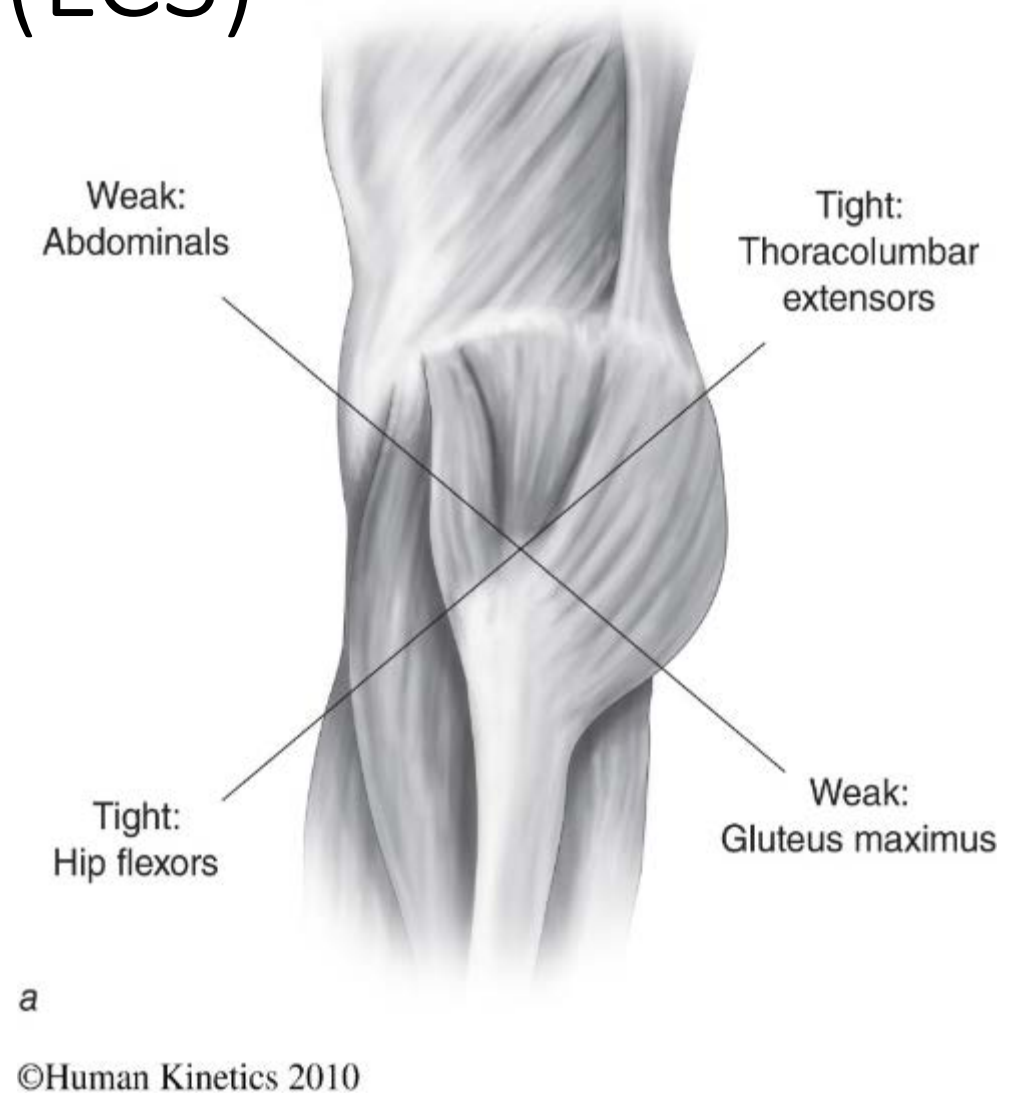
- Characterized by the imbalance between:
 - Shortened/tight hip flexors & lumbar erector spinae, and
 - Weakened/inhibited gluteal & abdominal muscles.
 - Altered hip kinetics that are reversible with correction of the above.
- You MAY also have an arthrokinetic reflex of the hip capsule.



©Human Kinetics 2010

Lower Crossed Syndrome (LCS)

- This imbalance can impair both static posture & dynamic function of this region, notably during walking – many patients/athletes can adapt around this temporarily...until they cannot.
- May present as low back or hip pain, but frequently is found in chronic/recurrent LE complaints, or even as the underlying basis for musculoskeletal complaints more cephalad / later in kinetic chains.



Lower Crossed Syndrome - Postures

- This imbalance promotes a forward pelvic tilt, increased lumbar lordosis & a slightly flexed position of the hip. The hamstrings are frequently tight.
- The consequence is then the overstress of the L/S segments, the hips, & the thoracolumbar junction (due to compensation).

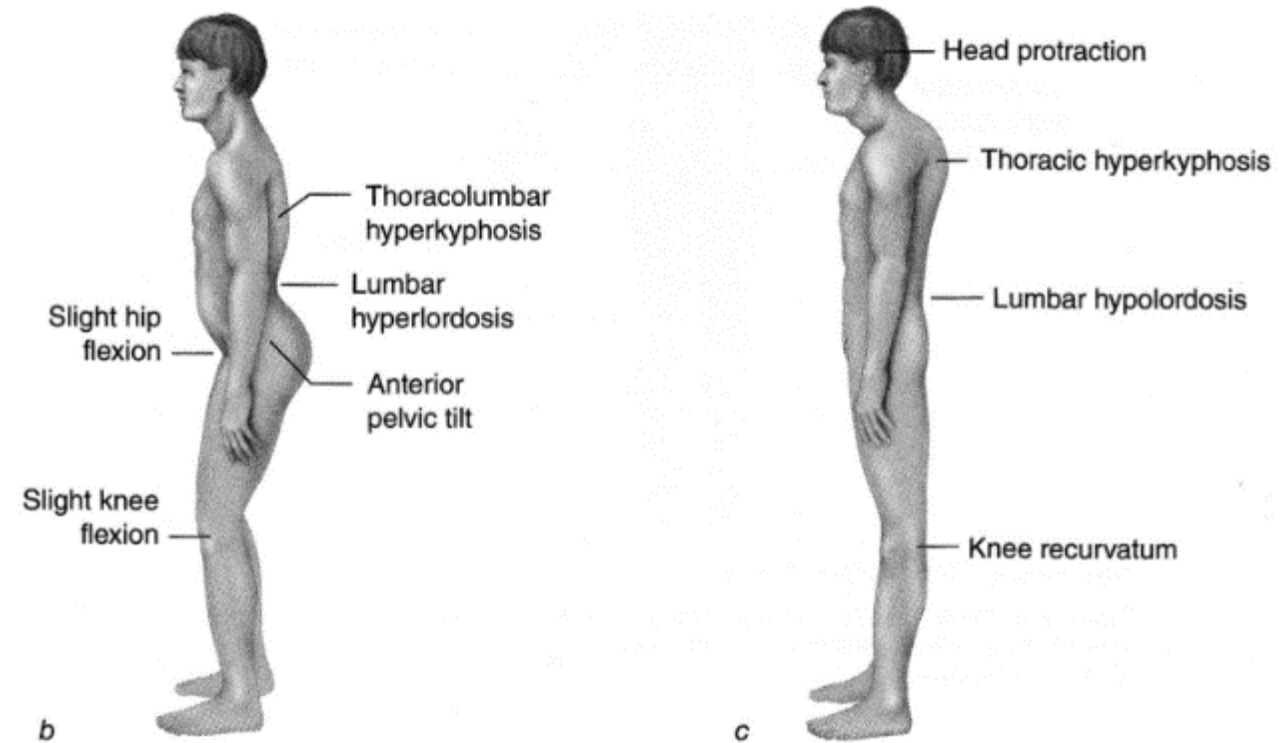


Figure 4.3 (a) LCS and two types of posture in the LCS: (b) type A posture and (c) type B posture.

Assessment & Treatment of Muscle Imbalance, pg. 53

LCS – Arthrokinetic Reflex

- Capsule or ligament becomes stretched beyond what its programming allows for as a normal ROM (or if too rapid a motion occurs), inhibitory signals are sent to the agonist muscle responsible for loading the joint in the plane in question & stimulatory signals to the antagonist musculature.

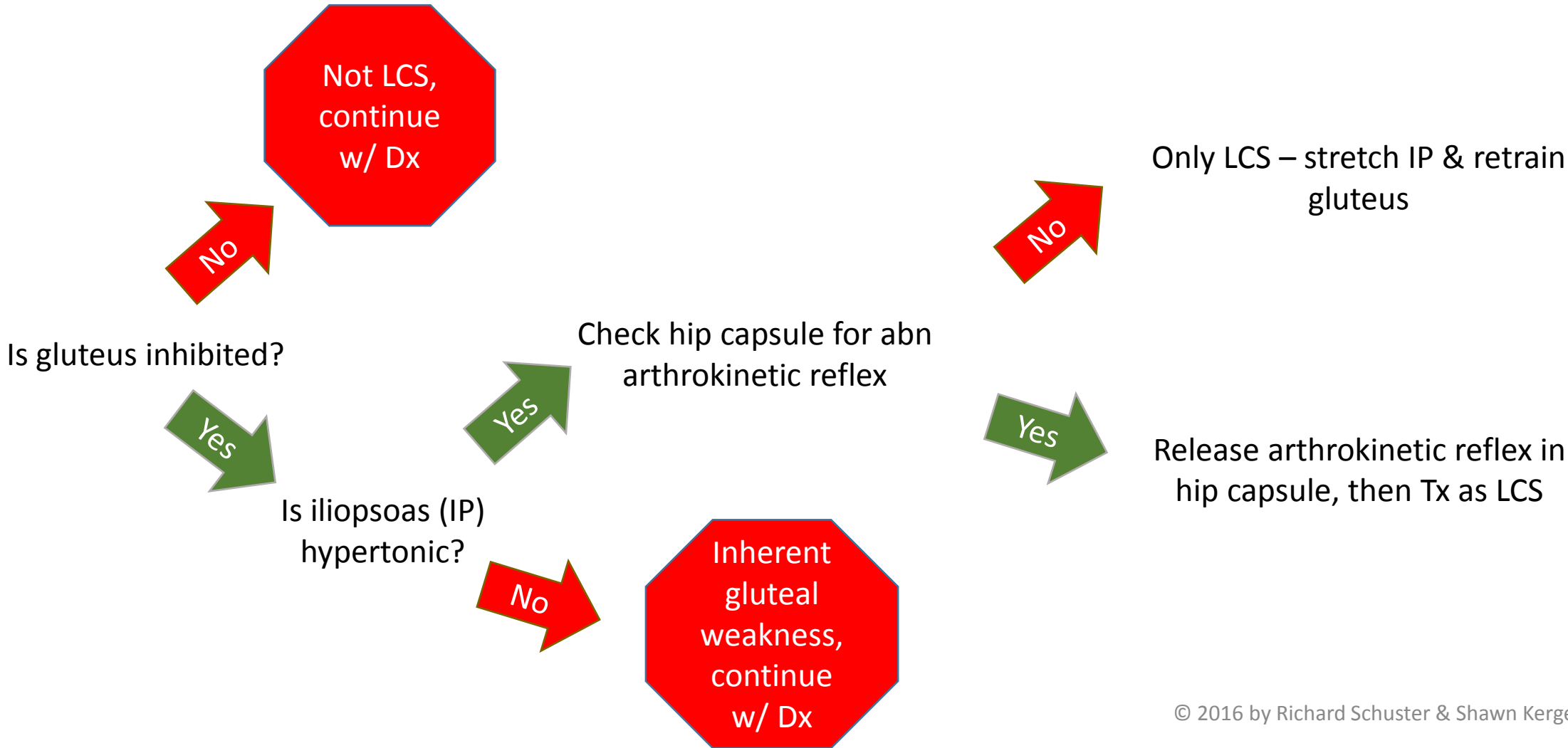


LCS – Arthrokinetic Reflex

- E.g., Anterior hip capsule is stretched more than its programming allows:
 - Gluteal muscles receive an inhibitory signal
 - Hip flexor muscles will be stimulated.
- This is the case in both healthy and dysfunctional states, with the difference being when this process is activated.
- Will *prevent* normal stretching...



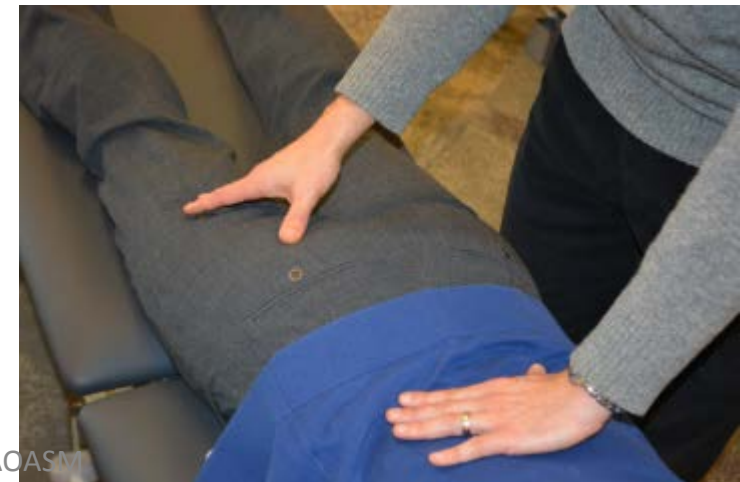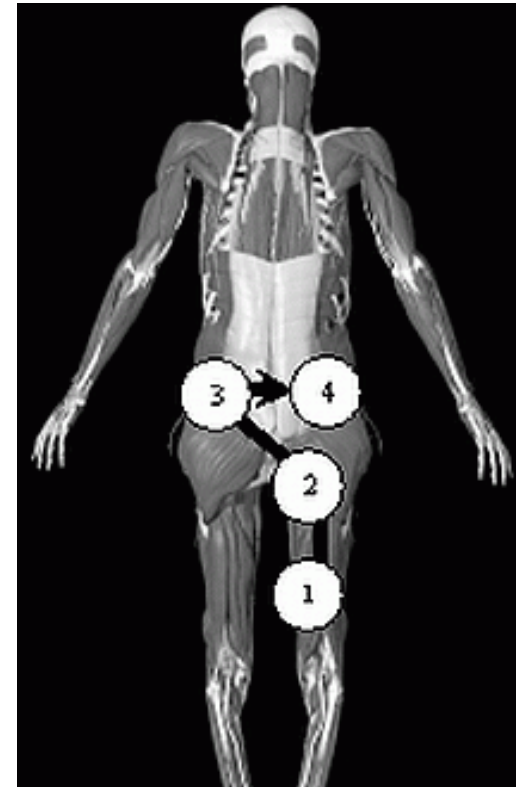
Testing for Lower Crossed Syndrome



Testing for Lower Crossed Syndrome

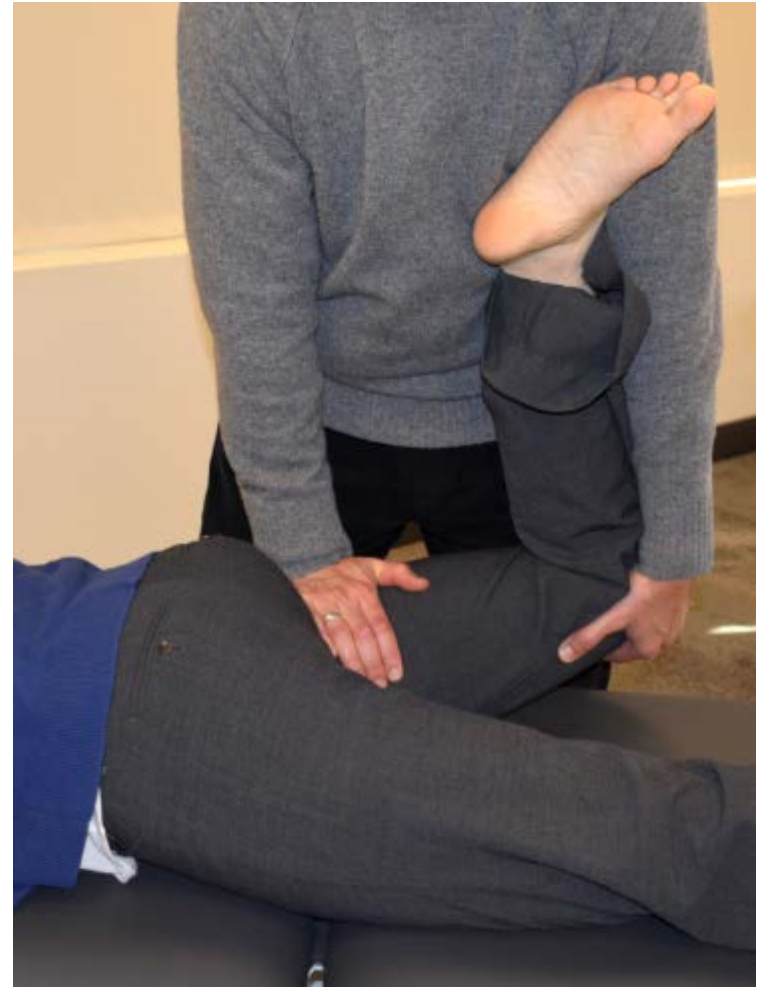
Test hip extension firing pattern (upper picture) – it should proceed in a “7” pattern (see figure to right) as follows:

- Hamstring
- Gluteus
- Contralateral Quadratus Lumborum
- Ipsilateral Quadratus Lumborum



Testing for Lower Crossed Syndrome

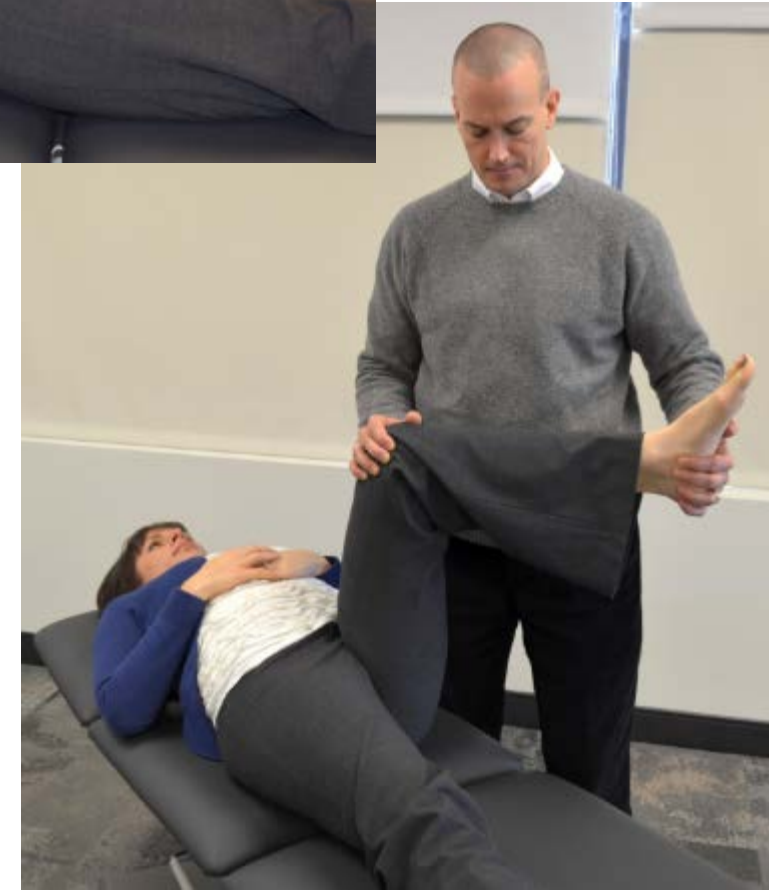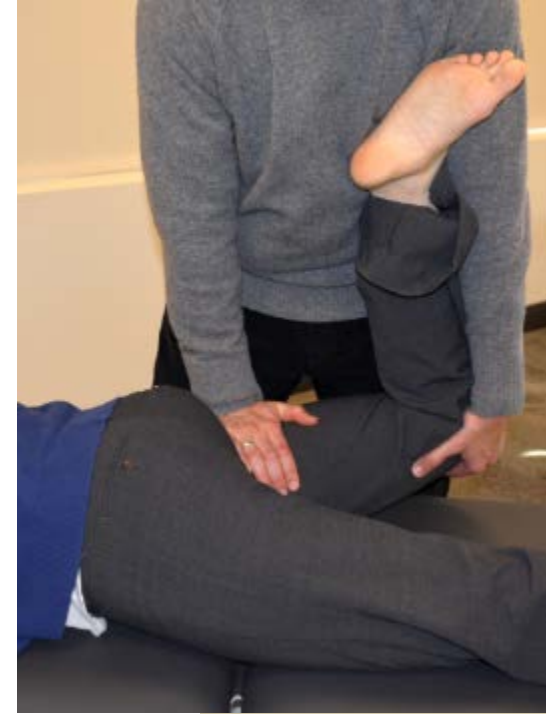- With patient prone, extend hip while stabilizing below gluteal fold (see picture) & compare sides for range of motion and end-feel
- If tight iliopsoas and inhibited gluteus pairing noted, suspect lower crossed syndrome



Arthrokinetic Reflex – Dx

Anterior Hip Capsule Restriction

- Suspect when you find multidirectional restrictions with ligamentous/articular end-feel in extension & internal rotation
- Commonly misdiagnosed as femoroacetabular impingement (FAI) or osteoarthritis



Treatment Order for Crossed Syndromes

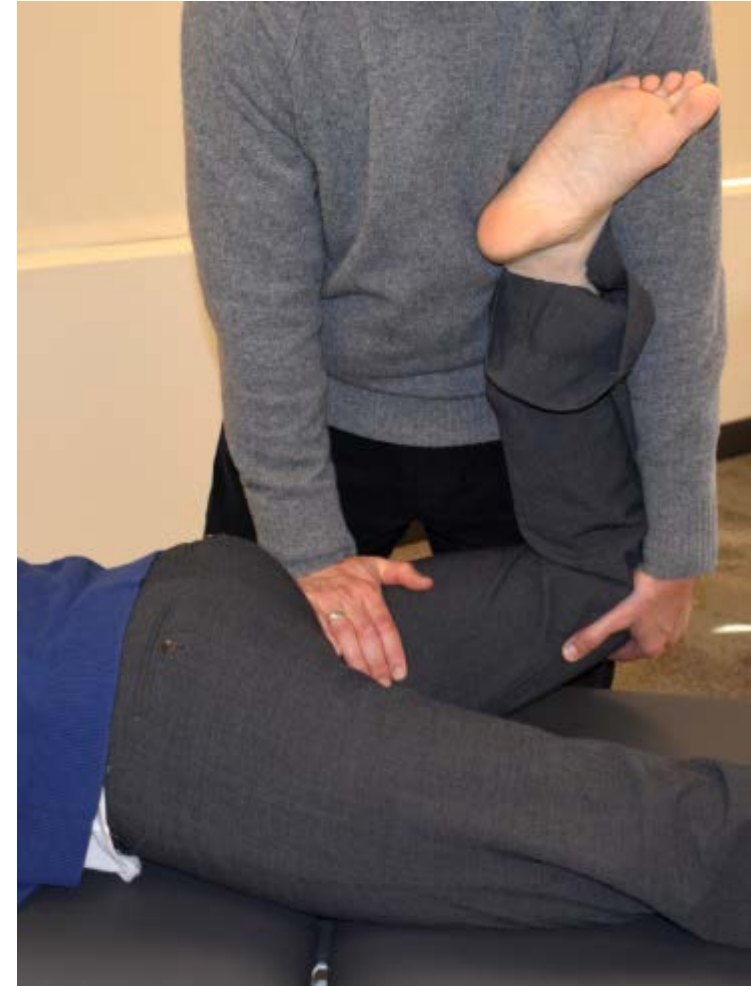Need to treat in the following sequence:

1. Release ligamentous capsule with arthrokinetic technique (**if needed**) - this allows the muscle to adapt it's length from a neuromuscular standpoint (via ME or SCS)
2. Muscle energy (or SCS – but usually ME due to chronicity) to bypass any neuromuscular tone issues & allow stretch
3. Passively stretch any hypertonic muscles to address any remaining muscle fiber or fascial restrictions.
4. Now you can retrain the inhibited muscle...

Arthrokinetic Reflex - Tx

Anterior Hip Capsule Restriction

- With patient prone & knee flexed, place your cephalad hand on the upper part of the femur, just below the gluteal fold.
- Extend the hip using the cephalad hand as a fulcrum to maintain the upper femur position.
- Once moderate tension has been reached, the knee is stabilized & a moderately-strong oscillatory posterior-anterior force is given with the cephalad hand, adding adduction as the slack is created (but not extension)
- Recheck your findings



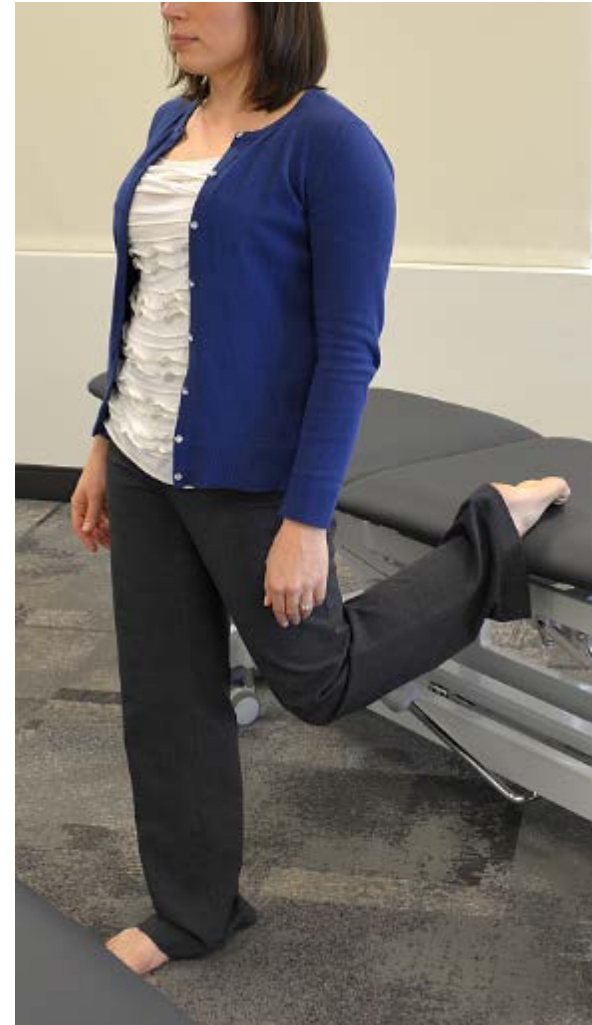Exercise Prescription For LCS – Iliopsoas Stretch

- Kneeling w/ affected side down, foot neutral or ER.
- Start in less than vertical posture (hip flexed a bit) & do 12 o'clock tilt, while tightening gluteus.
- Move forward into more upright/lunge position until early/mild stretch in hip flexor felt.
- Hold for 15-30 secs then move to new barrier, or do other side and repeat until no further progress is made, or there is pain.
- Can add flexion or ER contraction of hip in this position, if you wish.



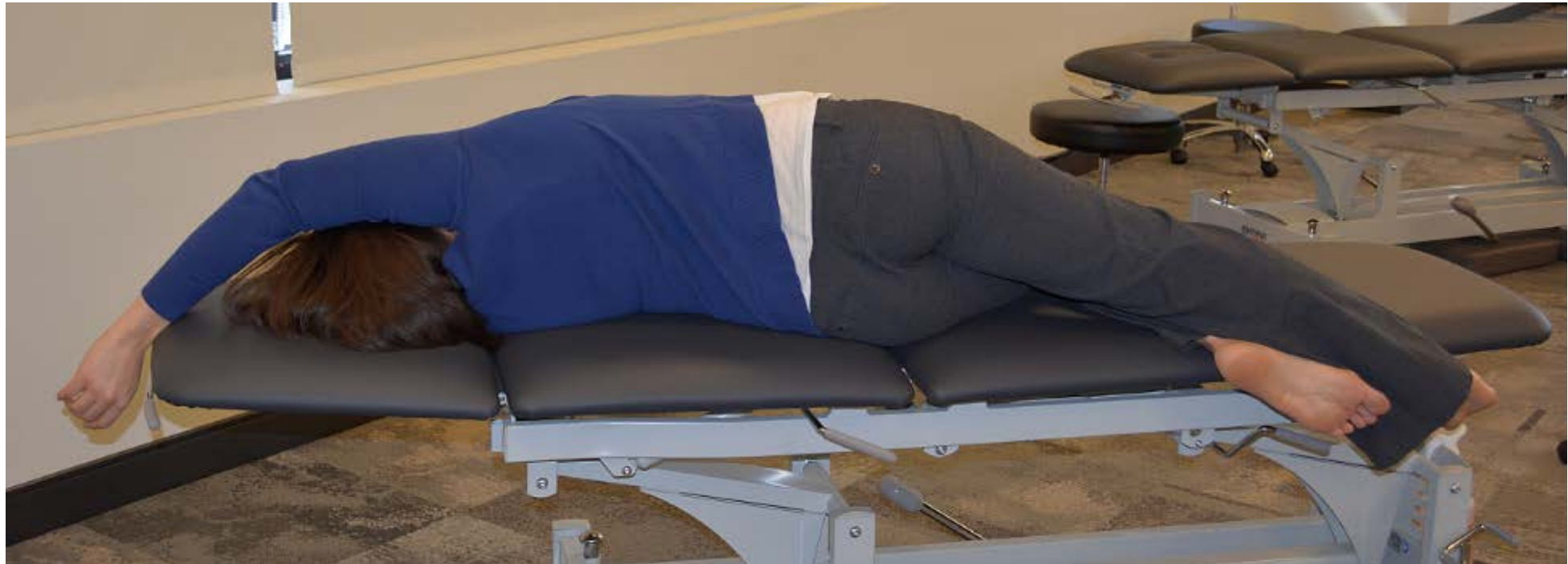Exercise Rx For LCS – Rectus Femoris Stretch

- Standing w/ affected foot on horizontal surface.
- Engage 12 o'clock tilt, while tightening gluteus
- Squat until early/mild stretch in rectus femoris felt.
- Hold for 15-30 secs then move to new barrier, or do other side and repeat until no further progress is made, or there is pain.
- Can add knee extension, if you wish.



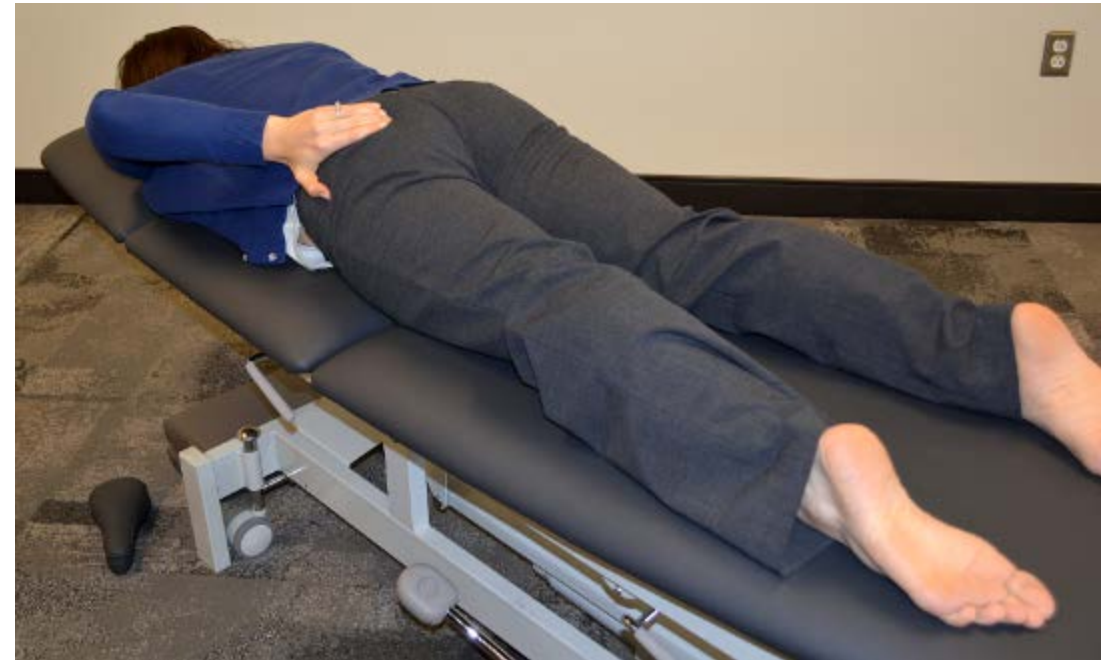Exercise Rx For LCS – Quadratus Lumborum Stretch

Picture shows it all – lie on the unaffected side and drop arm over your head on one side, with the ipsilateral foot off a table/couch, behind you. Hold for 20-30 seconds.



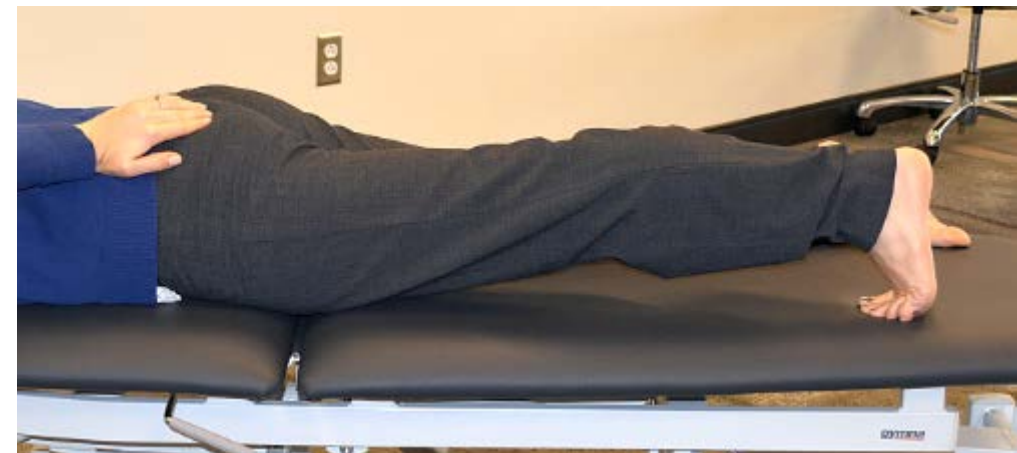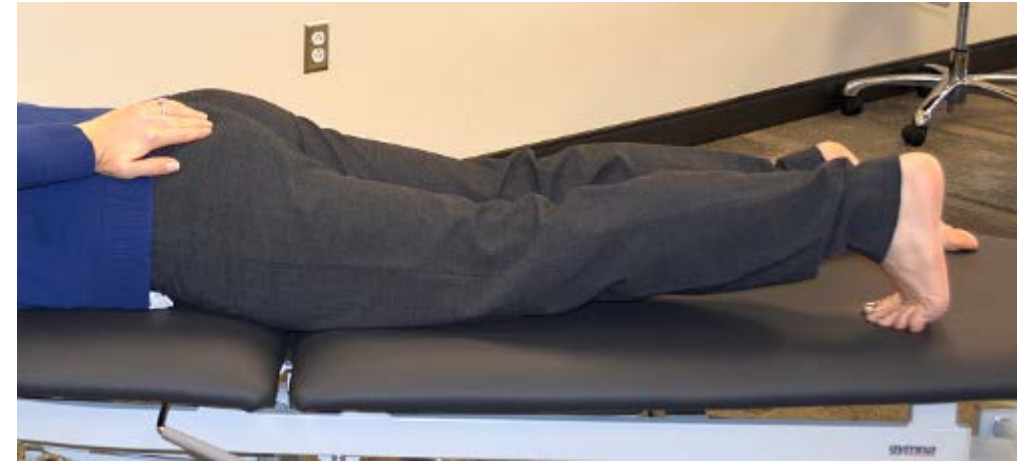Exercise Rx For LCS – Gluteus Maximus Retraining - I

- Prone w/ ipsilateral hand monitoring the glut max muscle belly, isometrically contract the gluteus without activating the erector spinae or quadratus lumborum.
- Hold for 5-7 secs, then relax.
- Repeat as often as you can perform a good, isolated contraction – up to 10 repetitions (not more than 2-3x/day).
- When you can do 10 strong, isolated contractions – move on to Phase II training.



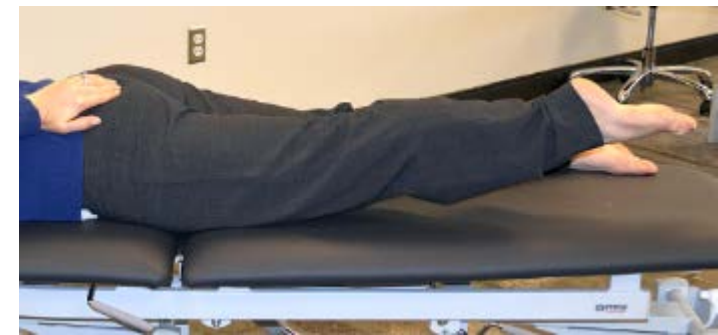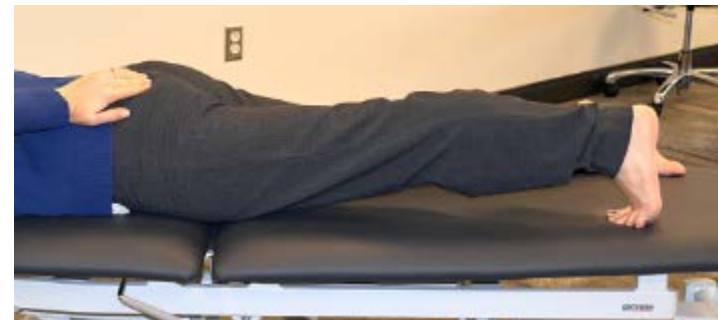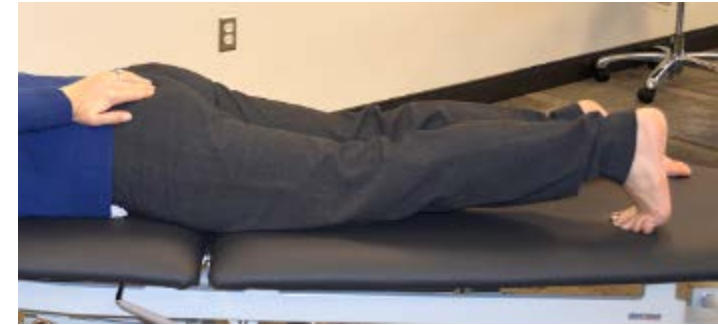Exercise Rx For LCS – Gluteus Maximus Retraining - II

- Start in same position, but with toes pointing into table or floor.
- Following same contraction of glut, extend the knee but keep toes down.
- Hold for 5-7 secs – then return knee back to table, keeping gluteus contracted until knee returned. Rest 3-4 seconds.
- Repeat as often as you can perform a good, isolated contraction – up to 10 repetitions (not more than 2-3x/day).
- When you can do 10 strong, isolated contractions – move on to Phase III training.



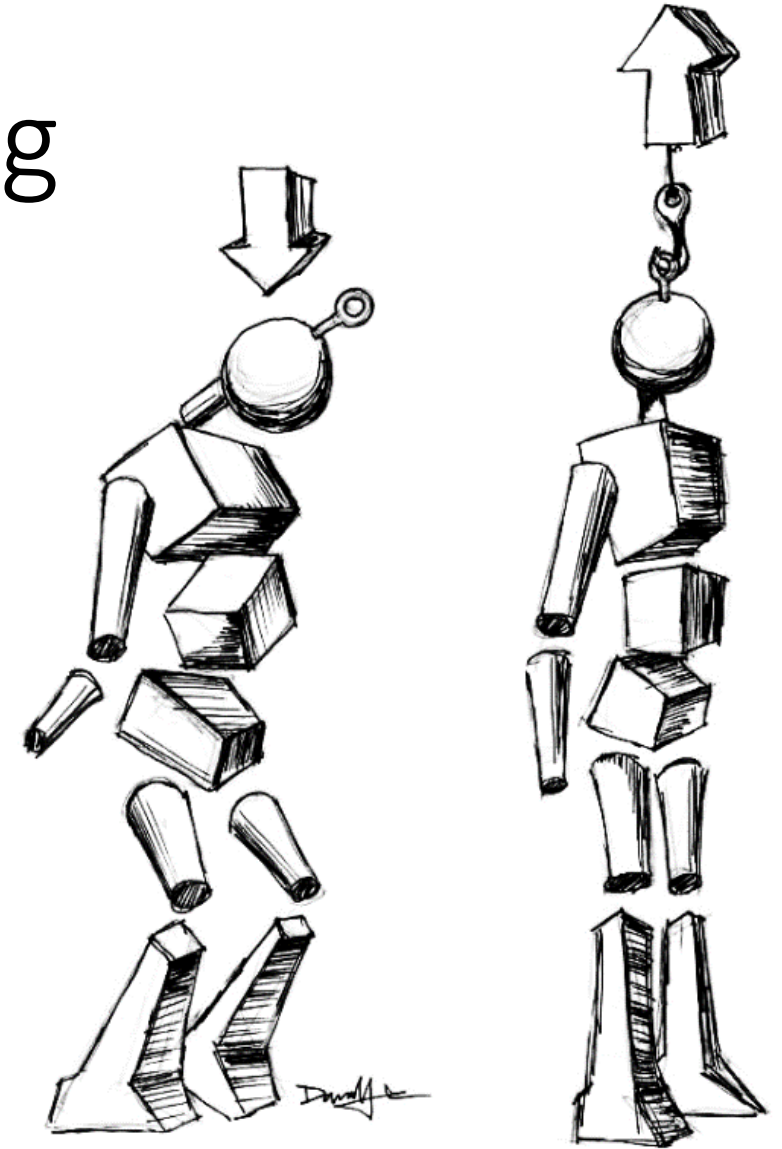
Exercise Rx For LCS – Gluteus Maximus Retraining - III

- Perform Phase II retraining, only now at the glut contracted / knee extended phase, you point the toe plantarly.
- Hold for 5-7 secs – then return leg back to table, keeping gluteus contracted until leg returned. Rest 3-4 seconds.
- Repeat as often as you can perform a good, isolated contraction – up to 10 repetitions (not more than 2-3x/day).
- Then move on to more standard gluteal retraining (squats, hip extensions, etc).



Exercise Rx – Postural Retraining

- Imagine a cord coming up from the crown of your head (not the very top/middle of your head, but slightly toward the back directly over the foramen magnum). Imagine someone pulling that cord upward – your chin drops toward your Adam's apple & your spine elongates.
- Maintain the most upright of this posture as feels somewhat natural. Over weeks-months, your range of natural posture will move toward this ideal posture. Do NOT attempt to progress too quickly, you will make things worse.
- Use visual cues to remind yourself of this posture – use them anywhere you stand or sit for long periods of time (>10-15').

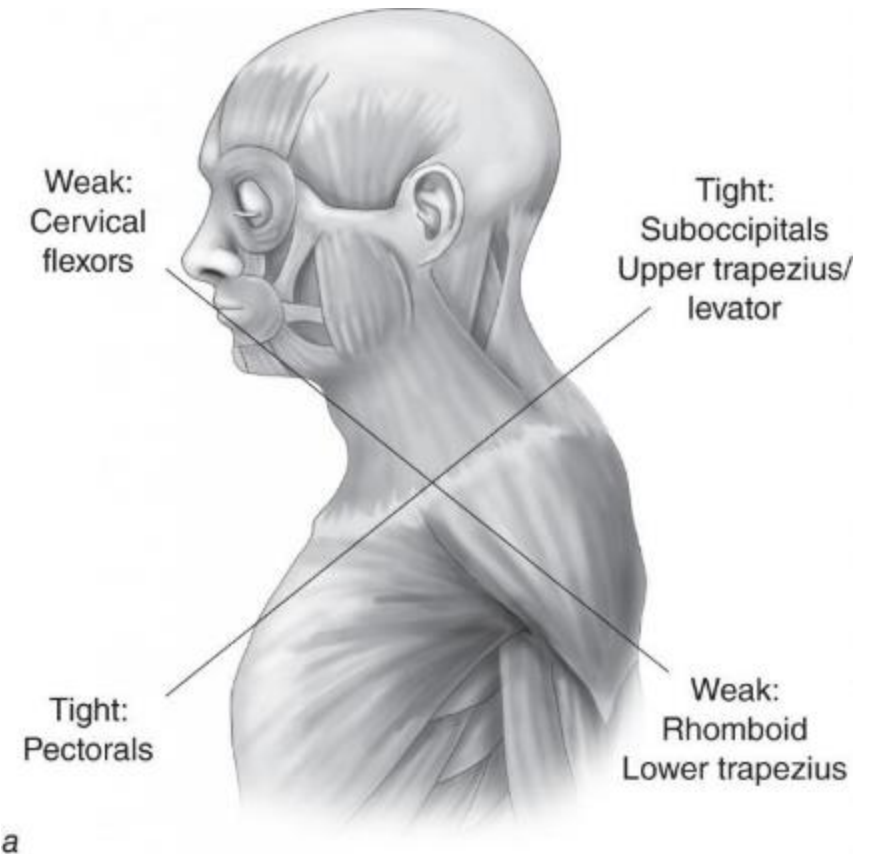


Upper Crossed Syndrome

(aka, Proximal or Shoulder Girdle Crossed Syndrome)

Upper Crossed Syndrome (UCS)

- Characterized by:
 - Shortened/tightened levator scapulae, upper trapezius & pectorals
 - Weakened/inhibited lower stabilizers of the scapula (rhomboids, serratus anterior, middle and lower trapezius) and deep neck flexors (longus colli and scalenes).
- This syndrome produces typical changes in posture:
 - Elevation and protraction of shoulders
 - Winged scapulae
 - Push-forward position of the head

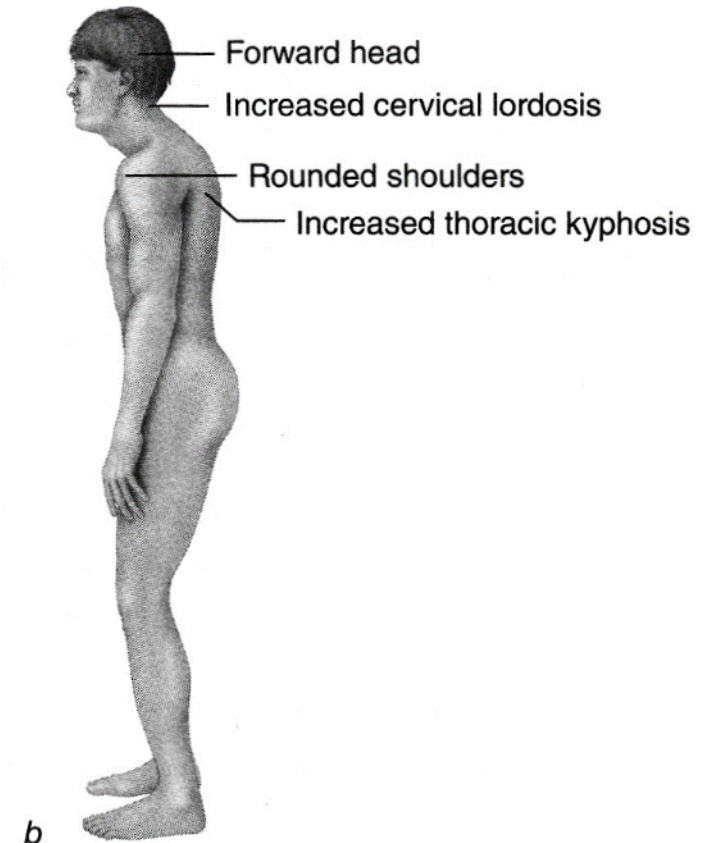


©Human Kinetics 2010

<http://www.muscleimbalancesyndromes.com/janda-syndromes/upper-crossed-syndrome/>

Upper Crossed Syndrome - Postures

- This syndrome produces typical changes in posture:
 - elevation & protraction of shoulders
 - winged scapulae
 - push-forward position of the head
- Leads to impingement syndromes & cervical / upper thoracic complaints.



Assessment & Treatment of Muscle Imbalance, Fig. 4.2b, pg. 52

Scapular & Thoracic Dysfunction

- May be separate from UCS!
- Latissimus, pectorals, upper trapezius & levator scapula are commonly hypertonic or tight
- Lower trapezius, rhomboid, rotator cuff muscles and serratus anterior are commonly hypotonic, weak, or inhibited
- Diagnosis by palpation of points of increased tension and tenderness, or through other exams (as we'll cover)
- Tender points may be similar to “trigger points”

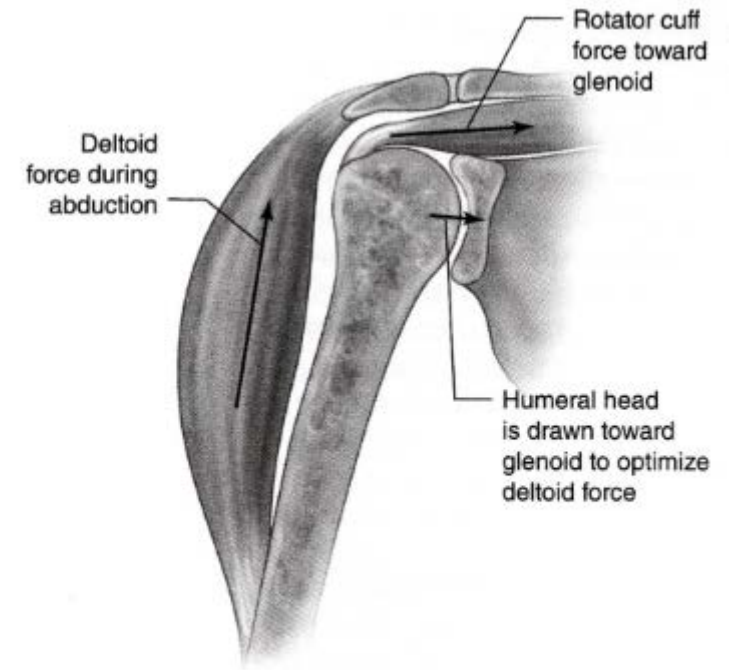


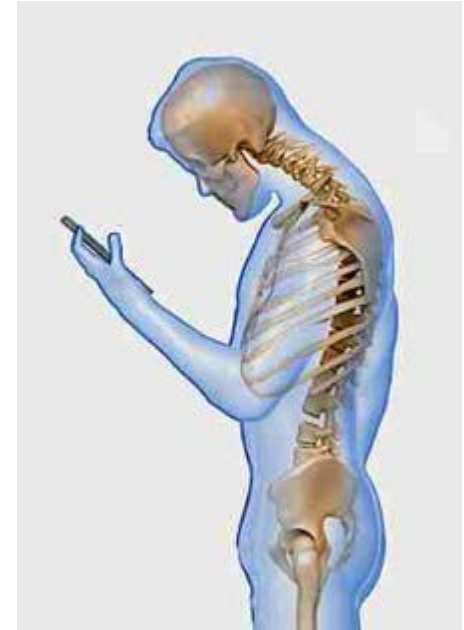
Figure 13.1 Rotator cuff force couples.

Assessment & Treatment of Muscle Imbalance, pg. 192

Functional Thoracic Kyphosis

- Pectoralis and latissimus dorsi muscle hypertonicity
- Rhomboid and lower trapezius inhibition and/or weakness
- Result ... internally rotated, flexed and adducted position
- “Stress Posture” = Texting!

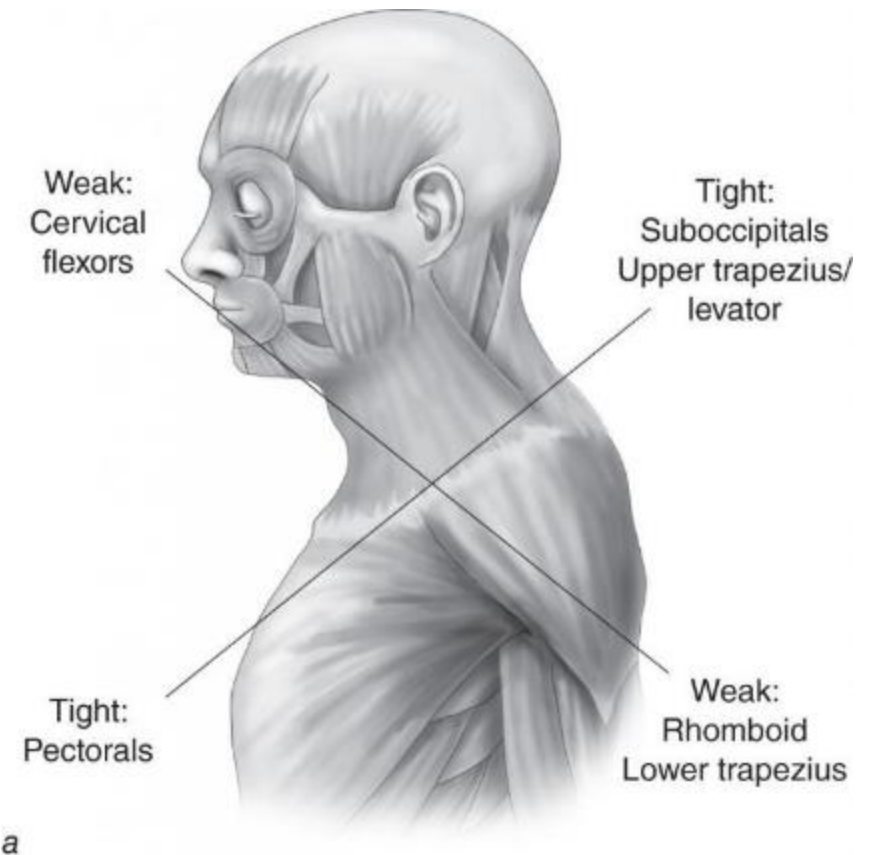
<https://static.pexels.com/photos/48566/pexels-photo-48566.jpeg>



<http://www.stethnews.com/wp-content/uploads/2014/12/Texting-Posture-Back-Pain-Problem.jpg>

Upper Crossed Syndrome (UCS)

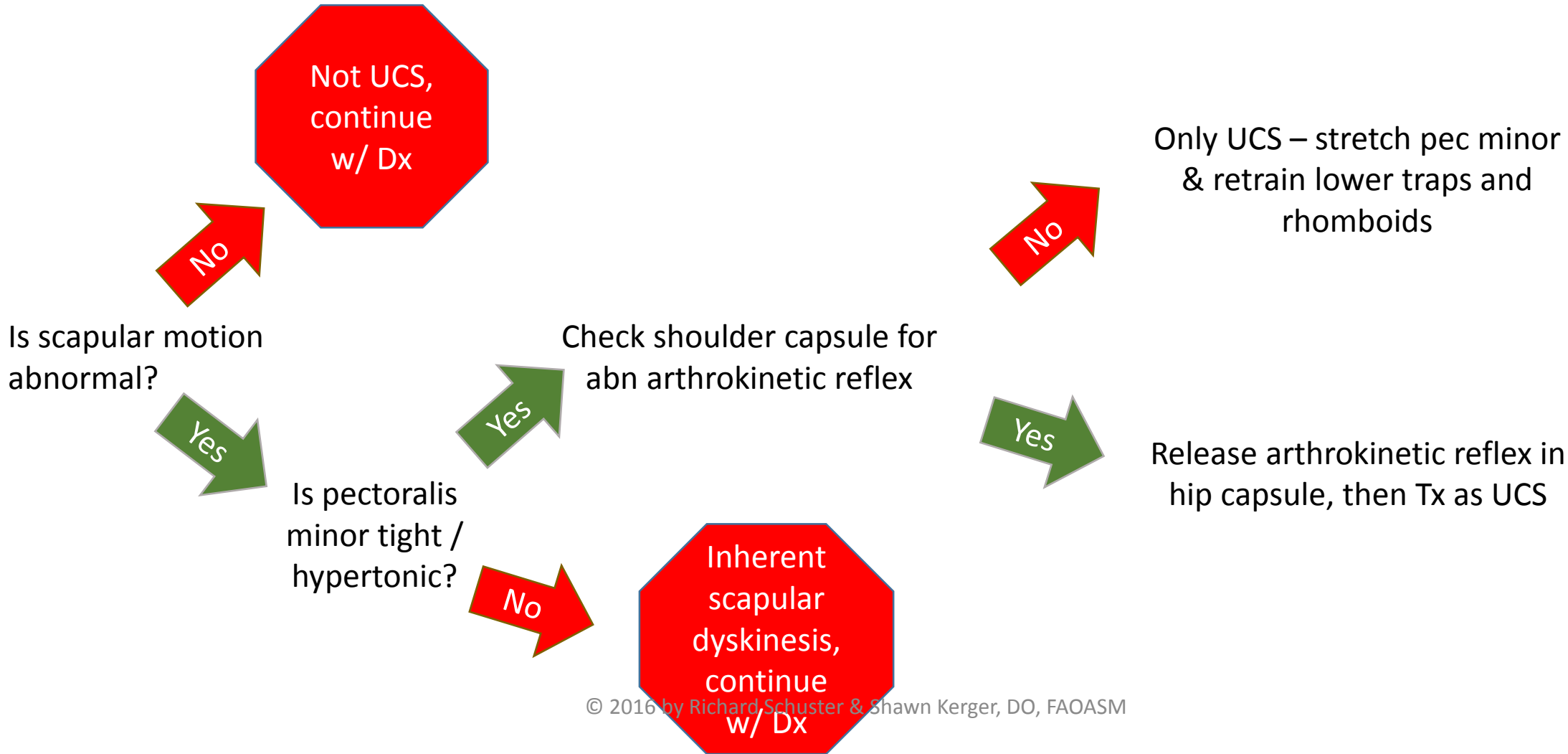
- In order to diagnose UCS, you find:
 - Tight pairs of pectorals & upper traps / suboccipital muscles
 - Inhibited cervical flexors & lower traps / rhomboids
 - Altered scapular kinetics that are reversible with correction of the above.
- You MAY also have a tight anterior G-H capsule, setting up an arthrokinetic reflex.



©Human Kinetics 2010

<http://www.muscleimbalancesyndromes.com/janda-syndromes/upper-crossed-syndrome/>

Testing for Lower Crossed Syndrome

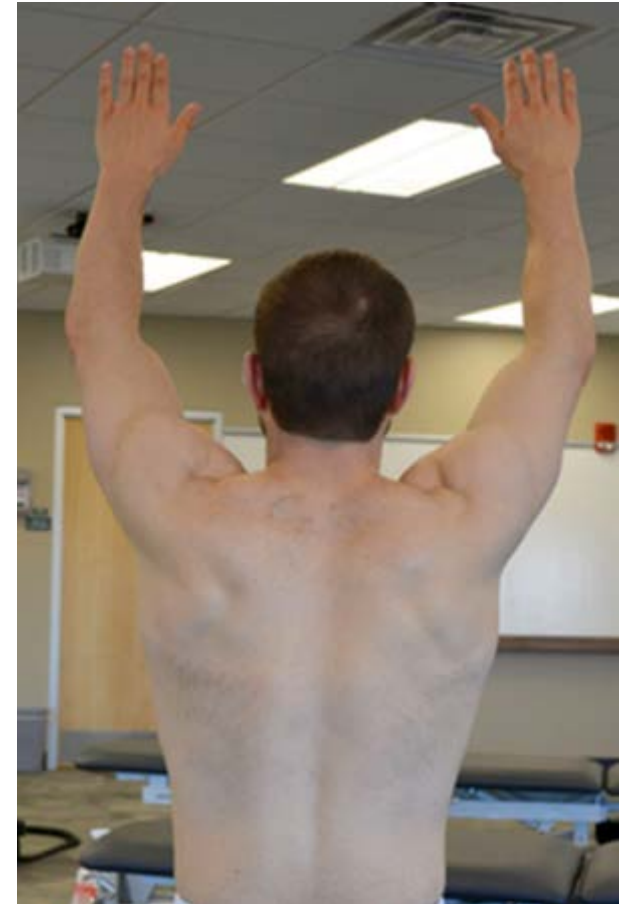


Testing for Upper Crossed Syndrome

- Check scapular ROM to flexion and abduction – look for:
 - ROM
 - Congruity of motions b/n scapulae
 - Firing patterns of upper trap vs. lower and middle trap
 - Winging of scapula
 - Pain reports
- If abnormal, or your index of suspicion based on history is high – then check for anterior shoulder capsule restriction (arthrokinetic reflex early activation)

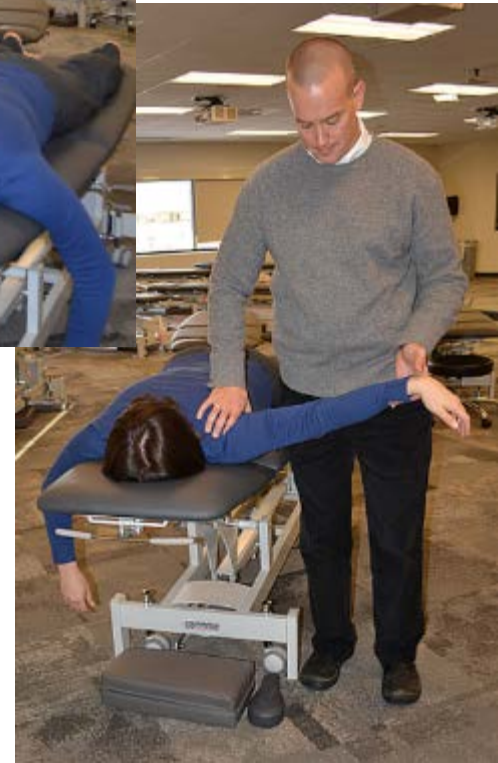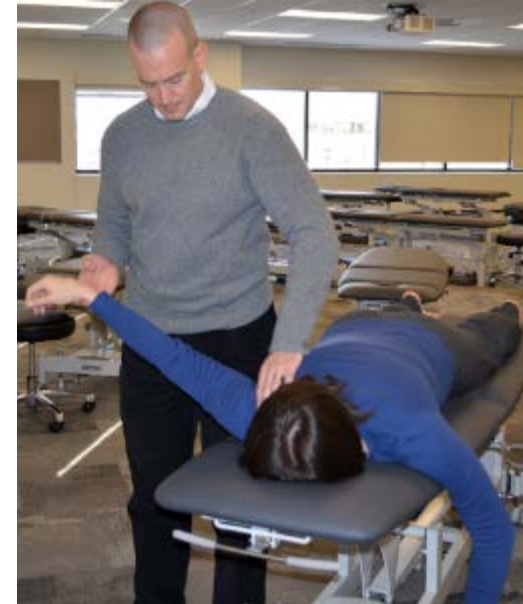Active Flexion / Abduction

- Ask the patient to flex both arms overhead – can just watch or palpate scapula to assist you
- Repeat with abduction
- Range of motion and influence of pain is noted
- Look for congruence between scapulae
- Normal: 0-180°



Arthrokinetic Reflex – Dx

- Stabilize the scapula posteriorly
- Passively horizontally abduct the arm at 90 degrees of abduction w/ elbow extended
- Should get 40-45 degrees (minimum) of extension before mild-moderate resistance encountered
- Also evaluate the end-feel...



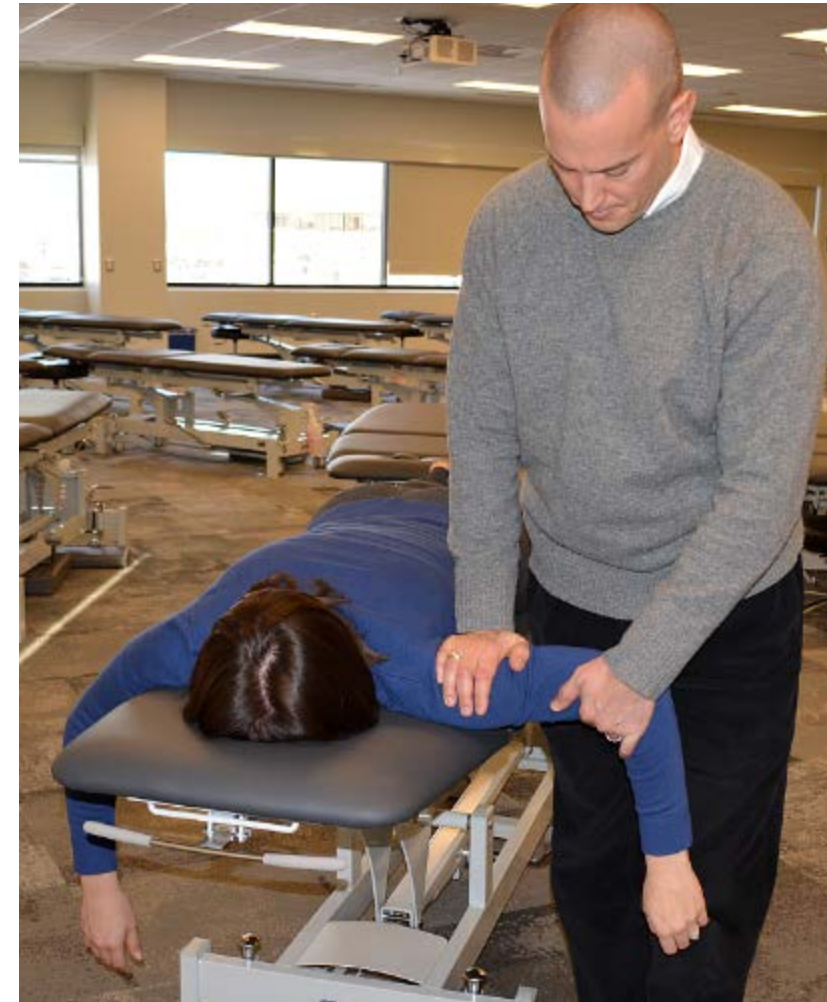Treatment Order for UCS & LCS

Need to treat in the following sequence:

1. Release ligamentous capsule with arthrokinetic technique (**if needed**) - this allows the muscle to adapt it's length from a neuromuscular standpoint (via ME or SCS)
2. Muscle energy (or SCS – but usually ME due to chronicity) to bypass any neuromuscular tone issues & allow stretch
3. Passively stretch any hypertonic muscles to address any remaining muscle fiber or fascial restrictions.
4. Now you can retrain the inhibited muscle...

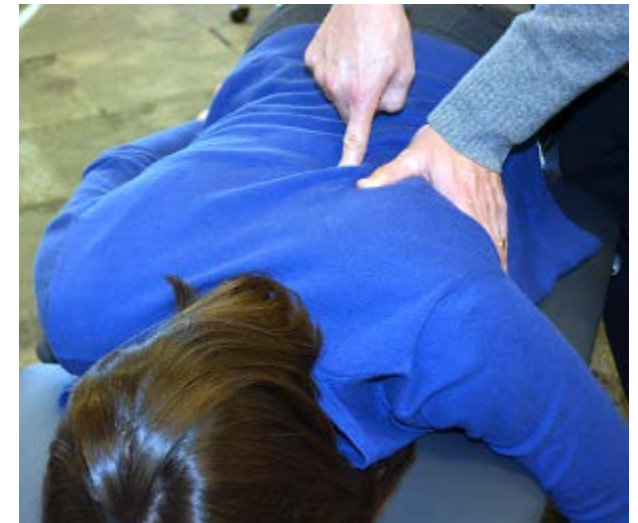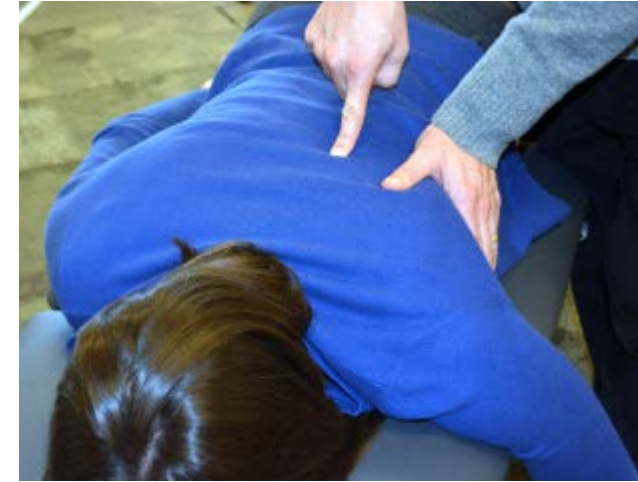Arthrokinetic Reflex - Tx

- W/ pt prone and medial hand posterior to the proximal humerus but off the scapula **completely**, horizontally abduct the shoulder until moderate resistance is encountered.
- With a moderate amount of force (10-20#), rhythmically apply a translatory force anteromedially through the glenohumeral joint without releasing initial tension point
- Abduct/adduct where resistance is met again, & continue until loose.
- Recheck findings.



Exercise Rx For UCS – Lower Trap Retraining - I

- With pt prone & arm hanging off table, ask patient to draw/pull the scapula inferiorly and toward the spine, using lower trap and avoiding contraction of lat or upper trapezius.
- Pt might need monitoring of, or even pressure on, muscle to help locate the appropriate portion of the trap.
- Hold for 5-7 seconds, then slowly let scapula return by releasing lower trap steadily. Rest for 4 seconds.
- Repeat as often as you can perform a good, isolated contraction – up to 10 repetitions (not more than 2-3x/day).
- Then move on to Phase II training.



Exercise Rx For UCS – Lower Trap Retraining - II

- Pt seated & forming a triangle with both thumbs and forefingers, ask patient to draw/pull the scapula & arms toward the spine, using lower trap and avoiding contraction of lat or upper trapezius.
- Hold for 5-7 seconds, then slowly return to starting position. Rest for 4 seconds.
- Repeat as often as you can perform a good, isolated contraction – up to 10 repetitions (not more than 2-3x/day).
- Then move on to more standard lower trap and rhomboid strengthening (e.g., rows).



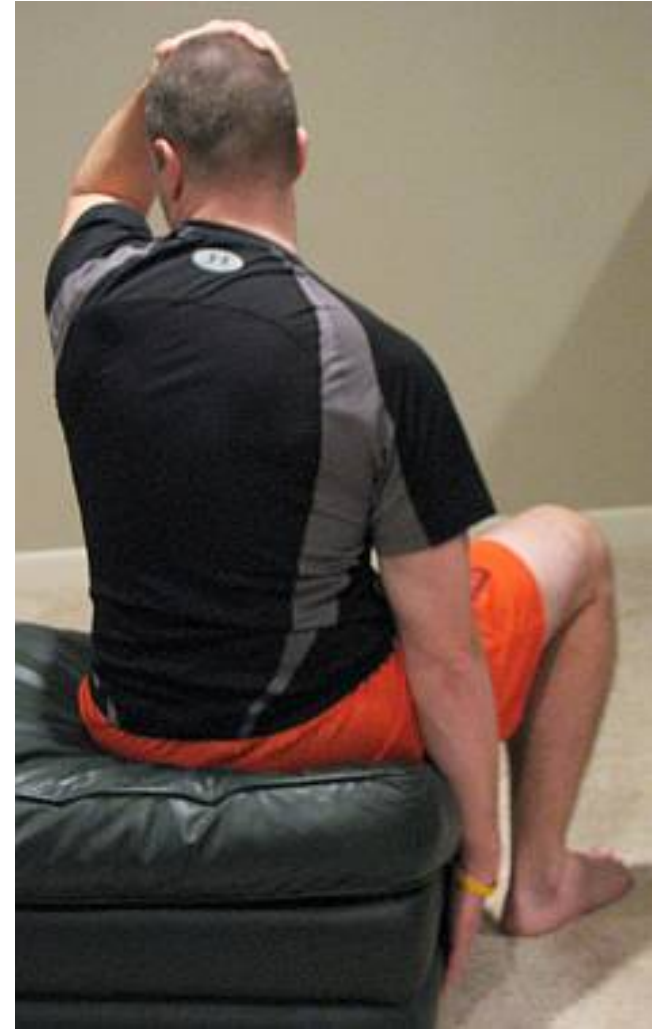Exercise Rx For UCS – Pectoralis Stretch

- Standing w/ affected limb at approximately shoulder height, same side foot against wall.
- Gently contract scapula inferomedially toward T₁₀
- W/ opposite hand holding body away from wall, slowly lean into the wall until early/mild stretch in pec minor is felt. If chest touches wall before stretch is felt, rotate trunk away from affected side & repeat.
- Hold for 10-15 secs then move to new barrier, or do other side and repeat.
- Can add adduction at shoulder toward wall to engage desired stretch. Can also raise or lower arm to augment stretch in desired portion of pectoralis.



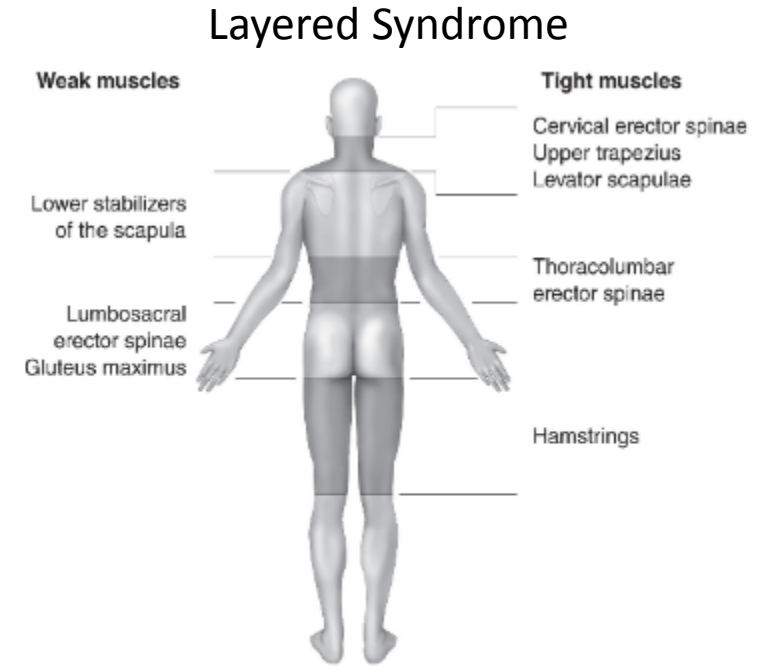
Exercise Rx For UCS – Levator Scapula Stretch

- Seated w/ affected limb holding bottom of chair or rung below.
- W/ opposite hand holding head flexed, sidebent and rotated away from affected limb until early/mild stretch in lev. is felt.
- Hold for 10-15 secs then move to new barrier, or do other side and repeat.
- Can add sidebend/rotate/extend neck toward affected side to engage desired stretch.



Layered syndrome

- Layered syndrome is the most severe expression of generalized muscle imbalance which resulted already into an altered shape of the body. Observing the standing patient from the back, “layers” (strata) of hyper- and hypotrophied muscles can be noticed.
- The hamstrings are hypertonic, gluts and L-S spinal erectors hypotonic, T/L junction hypertonic, interscapular, region hypotonic and upper trapezius, and deep neck extensors hypertonic.
- In principle, this syndrome is a combination of both crossed syndromes, and usually represents a long-standing problem...



©Human Kinetics 2010. Based on G. Jull and V. Janda, 1987, Muscles and motor control in low back pain. In *Physical therapy for the low back*, edited by L.T. Twomey and J.R. Taylor (Oxford, United Kingdom: Churchill Livingstone).

http://www.muscleimbalance.com/wp-content/uploads/2010/11/fig04_04.jpg

References – including images

1. http://www.muscleimbalancesyndromes.com/wp-content/uploads/2010/11/fig04_03a.jpg
2. Page P, Frank C, et al. *Assessment and Treatment of Muscle Imbalances: The Janda Approach*, Benchmark Physical Therapy, Inc., 2010.
3. https://3.bp.blogspot.com/-Asv-ZGz-zig/VmB_iFi18EI/AAAAAAAAACCU/MR1PJp3gfWQ/w800-h800/Funny-cartoon-Dyslexic-CPR.jpg
4. http://karenoosterbaan.com/wp-content/uploads/2012/11/David_Yu_feature_alexander_technique_t6301.jpg
5. <https://static.pexels.com/photos/48566/pexels-photo-48566.jpeg>
6. <http://www.stethnews.com/wp-content/uploads/2014/12/Texting-Posture-Back-Pain-Problem.jpg>
7. <http://www.muscleimbalancesyndromes.com/janda-syndromes/upper-crossed-syndrome/>

Credits

Special thanks to :

- Fran Adkins, OMS-IV
- Bren Nolan, OMS-IV
- Abby Huck, OMS-IV
- Zach Daniels, OMS-III
- Mark Riley, OMS-III