

Acquired Bilateral Nevus of Ota-like Macules (Hori's Nevus): A Case Report and Treatment Update

Jamie Hale, DO,* David Dorton, DO,** Kaisa van der Kooi, MD***

*Dermatology Resident, 2nd year, Largo Medical Center/NSUCOM, Largo, FL

**Dermatologist, Teaching Faculty, Largo Medical Center/NSUCOM, Largo, FL

***Dermatopathologist, Teaching Faculty, Largo Medical Center/NSUCOM, Largo, FL

Abstract

This is a case of a 71-year-old African American female who presented with bilateral periorbital hyperpigmentation. After failing treatment with a topical retinoid and hydroquinone, a biopsy was performed and was consistent with acquired bilateral nevus of Ota-like macules, or Hori's nevus. A review of histopathology, etiology, and treatment is discussed below.

Introduction

Acquired nevus of Ota-like macules (ABNOM), or Hori's nevus, clinically presents as bilateral, blue-gray to gray-brown macules of the zygomatic area. It less often presents on the forehead, upper outer eyelids, and nose.¹ It is most common in women of Asian descent and has been reported in ages 20 to 70. Classically, the eye and oral mucosa are uninvolved. This condition is commonly misdiagnosed as melasma.¹ The etiology of this condition is not fully understood, and therefore no standardized treatment has been established.

Case Report


A 71-year-old African American female initially presented with a two week history of a pruritic, flaky rash with discoloration of her face. She stated she had a mask placed on her face during a facial one week prior, but the discoloration was present prior to the facial treatment. She denied any use of new products and stated her only new medication was ciclesonide nasal aerosol, prescribed by her allergist. Her past medical history was only significant for hypertension. The patient denied a family history of similar lesions or facial discoloration. Her current medications included amlodipine, aspirin, flax seed oil, glucosamine, hydrochlorothiazide, omega 3 fish oil, and vitamin B12.

On physical exam, she was noted to have very

Figure 2

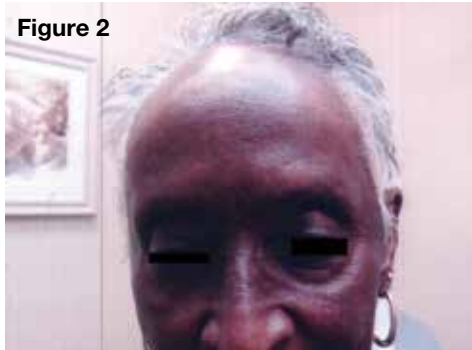

Figure 3



well demarcated hyperpigmentation affecting the majority of her forehead and periorbital region with Fitzpatrick type IV skin (Figures 1-3). The patient was sent for labs including TIBC, iron, ACTH, and free and total testosterone, and all were within normal limits. She was given a recommendation to see her allergist regarding the possibility of her new medication causing the hyperpigmentation. She was also advised to try skin-lightening products, including kojic acid and hydroquinone 2% cream, as well as to wear sunscreen and protective clothing to avoid UV exposure. The patient was also notified that amlodipine can cause skin pigment changes, and HCTZ can cause photosensitivity, but was told not to discontinue any medications without speaking with her primary care physician.

Six months later, the patient presented for re-evaluation. Her hyperpigmentation remained unchanged with topical hydroquinone 2%

cream and tretinoin 0.05% gel. At this visit, a punch biopsy of her left zygoma was performed. Histopathology reported sparse proliferation of irregularly shaped, haphazardly arranged melanocytes extending from the superficial reticular dermis to mid-deep reticular dermis

Figure 4

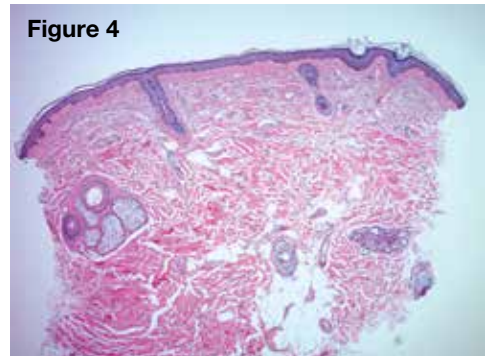


Figure 5

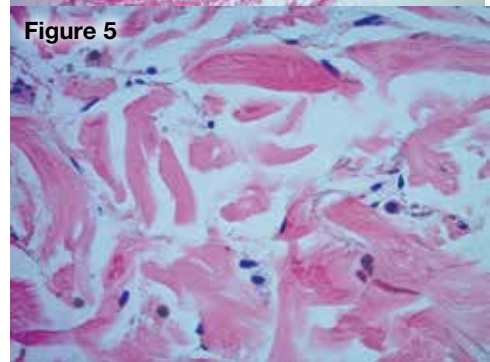
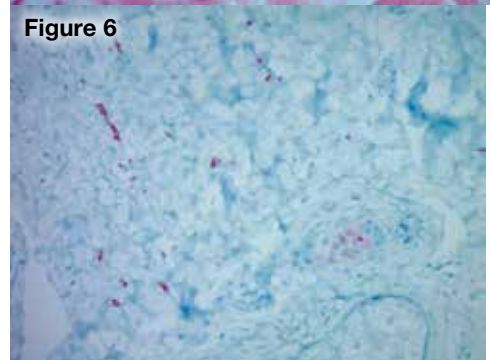
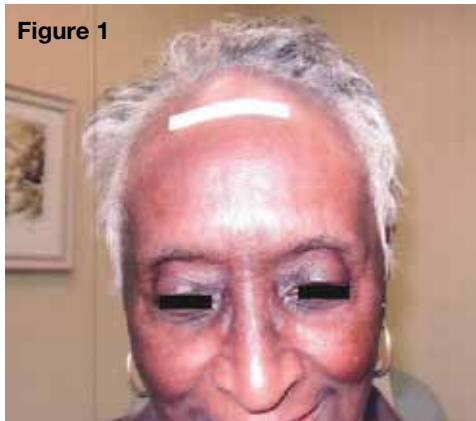


Figure 6



(Figures 4, 5). A Mart-1 (Figure 6) and S100 stain were used to confirm the presence of dermal spindled melanocytes. Due to its acquired bilateral presentation, it was most consistent with Hori's nevus.

Figure 1



Discussion

ABNOM was first described by Hori et al. in 1984, and its alternate designations include nevus fusco-caeruleus zygomaticus and acquired circumscribed dermal facial melanocytosis.² Histologically, it is characterized by irregularly shaped, bipolar melanocytes in the papillary and mid dermis without disruption of the normal skin architecture. On electron microscopy, the melanosomes of ABNOM are mainly singly dispersed and in stages II, III, and IV. ABNOM differs clinically from nevus of Ota, as it often presents in late adulthood, is bilateral, may be speckled or confluent, and does not involve the mucosa.³ In addition to nevus of Ota, the differential diagnosis of ABNOM includes melasma, lentigines, and dark circles under the eye.⁴

Despite the relatively common occurrence, the pathogenesis of ABNOM is not well understood. There are currently several mechanisms that have been described to account for the origin of the melanocytes. The first, described by Hori et al., states that the melanocytes descend from the epidermis to the dermis to create the darker bluish-gray hue.² Dermal inflammation or atrophy could potentially be reactivating preexisting melanocytes, which would explain the presence of dermal melanocytes in uninvolved skin near the pigmented macules.⁵ Another potential etiology is the migration of hair bulb melanocytes.⁶ Pistone et al. used confocal microscopy to describe melanocytes of the hair follicle proliferating and appearing to migrate up the outer root sheath, later repopulating interfollicular epidermis. Their study further stated that these melanocyte stem cells appear to have the capability to enter vacant niches, including migration to the epidermis.⁷

Multiple factors have been considered to induce ABNOM, including UV light, the most probable cause, as well as sex hormone changes. Murakami et al. reported cases of ABNOM induced by atopic dermatitis, which further points to chronic inflammation playing a causal role as well as the possibility of histamine and stem cell factor (SCF) involvement.⁸ This hypothesis was supported by Lee et al., whose study described increased expression of the SCF/c-kit pathway between dermal fibroblasts and dermal melanocytes. This study also highlighted the lack of epidermal pigmentation involved in the condition, supporting the idea that topical bleaching treatment may be unnecessary prior to laser therapy.⁹ A study by Long et al. demonstrated that a significant percentage of ABNOM expressed androgen receptor; however, estrogen-receptor and progesterone-receptor expression was not identified despite previous theories stating their involvement in the

pathogenesis. This will require further studies to confirm, but it raises the possibility of topical use of selective androgen-receptor modulators as targeted therapy for some patients.¹⁰ There has been no direct genetic locus described, but case series with family history and genetic associations have been documented.¹¹

Treatment of ABNOM can be difficult, and many modalities have been described including cryotherapy, dermabrasion, chemical peeling, topical agents, and laser therapy. Topical treatments used to treat ABNOMs with varying success include hydroquinone, tretinoin, corticosteroids, glycolic acid, and azelaic acid.¹² The disappointing results of topical therapies are likely due to the deep-seated nature of the melanocytes in this condition. Therefore, laser therapy is often required for treatment. Noted in the literature is the use of Q-switched ruby, Q-switched alexandrite, and Q-switched Nd:Yag lasers.¹³ Location of these lesions, as well as the prevalence in higher Fitzpatrick skin types, poses therapeutic dilemmas. Often, multiple laser treatments are needed to achieve desired results.¹³ Manuskiatti et al. described the efficacious use of Q-switched ruby laser following a scanned CO2 laser with no long-term adverse sequelae and decreased number of treatments required.¹⁴ Post-inflammatory hyperpigmentation is often problematic in this patient population and can be reduced by applying corticosteroids immediately post laser.¹² Therapeutic response is also largely dependent on the baseline and predominant color of the nevus.¹⁴

Conclusion

To-date, our patient has elected to treat only with topical tretinoin and hydroquinone. She was advised that laser therapy would be the best option should she desire more aggressive treatment. Hori's nevus, or ABNOM, is a relatively common entity with an etiology that is not well understood but includes possible inflammatory, hormonal, and ultraviolet stimulation. It is commonly misdiagnosed as other entities including melasma or solar lentigines. A multi-modality, patient-specific and lesion-specific treatment approach is necessary to achieve optimal results. Finally, when treating with laser therapy, multiple treatment sessions and multiple lasers may be necessary.

References

1. Bologna J et al. *Dermatology*. 3rd edition. Missouri: Elsevier Saunders; c2012. Chapter 112, Benign Melanocytic Neoplasms; p. 1858-1859.
2. Hori Y, Kawashima M, Oohara K, et al. Acquired bilateral nevus of ota-like macules. *J Am Acad Dermatol*. 1984;10(6):961-964.

3. Park J, Tsao H, Tsao S. Acquired bilateral nevus of Ota-like macules (Hori nevus): Etiologic and therapeutic considerations. *J Am Acad Dermatol*. 2009;61(1):88-93.
4. Cho S, Lee S, Chung W, et al. Acquired bilateral nevus of Ota-like macules mimicking dark circles under the eyes. *J Cosmetic Laser Ther*. 2010;12(3):143-144.
5. Mizushima J, Nogita T, Higaki Y, et al. Dormant melanocytes in the dermis: do dermal melanocytes of acquired dermal melanocytosis exist from birth? *Br J Dermatol*. 1998;139(2):349-350.
6. Wang B, Shen Z, Fei Y, et al. A population-based study of acquired bilateral nevus-of-ota-like macules in Shanghai, China. *J Invest Dermatol*. 2011;131:358-362.
7. Pistone G, Doukaki S, Rizzo D, et al. Reflectance mode confocal microscopy and digital image analysis of naevus of Hori and pathogenetic evaluation. *Br J Dermatol*. 2012;167:692-705.
8. Murakami F, Soma Y, Mizoguchi M. Acquired symmetrical dermal melanocytosis (naevus of Hori) developing after aggravated atopic dermatitis. *Br J Dermatol*. 2005;152:903-908.
9. Lee J, Kim E, Kim K, et al. Acquired bilateral naevus of Ota-like macules: an immunohistological analysis of dermal melanogenic paracrine cytokine networks. *Br J Dermatol*. 2010;164:580-585.
10. Long T, Liu L, He L, et al. Androgen, estrogen and progesterone receptors in acquired bilateral nevus of Ota-like macules. *Pigment Cell Melanoma Res*. 2009;23:144-146.
11. Ee H, Wong H, Goh C, et al. Characteristics of Hori naevus: a prospective analysis. *Br J Dermatol*. 2005;154:50-53.
12. Lee W, Han S, Chang S, et al. Q-switched Nd:YAG laser therapy of acquired bilateral nevus of Ota-like macules. *Ann Dermatol*. 2009;24(3):255-260.
13. Kunachak S, Leelaudomlapi P, Sirikulchayanonta V. Q-switched ruby laser therapy of acquired bilateral nevus of Ota-like macules. *Dermatol Surg*. 1999;25:938-941.
14. Manuskiatti W, Sivayathorn A, Leelaudomlapi P, et al. Treatment of acquired bilateral nevus of Ota-like macules (Hori's nevus) using a combination of scanned carbon dioxide laser followed by Q-switched ruby laser. *J Am Acad Dermatol*. 2003;48(4):584-591.

Correspondence: Jamie Hale, DO; Largo Medical Center, 201 14th St SW, Largo, FL 33770; Ph: 727-588-5200; F: 727-608-4531; jamiedhale@gmail.com