

# Successful Use of Liposomal Amphotericin B for Cutaneous Leishmaniasis in a Young Male Patient Treated with a TNF-alpha Inhibitor

John R. Moesch, BA,\* Caryn Bern, MD, MPH,\*\* Vincent A. Laufer, BA,\*\*\* Robin H. Dretler, MD, FIDSA\*\*\*\*

\*Medical student, 4th year, Philadelphia College of Osteopathic Medicine, Suwanee, GA

\*\*Medical epidemiologist, Department of Epidemiology and Biostatistics, University of California, San Francisco, CA; Division of Parasitic Diseases and Malaria, Centers for Disease Control and Prevention, Atlanta, GA

\*\*\*Medical student, 4th year, University of Alabama School of Medicine, Birmingham, AL

\*\*\*\*Infectious disease physician, Infectious Disease Specialists of Atlanta, P.C., Decatur, GA

Disclosures: None

Correspondence: John R. Moesch; johnmoe@pcom.edu

## Abstract

We present a case of cutaneous leishmaniasis caused by the species *L. panamensis* in a young male patient with juvenile idiopathic arthritis (JIA), who was being treated with tumor necrosis factor- $\alpha$  inhibitor adalimumab. He had recently returned from traveling in Colombia. The patient was successfully treated with liposomal amphotericin B. We also discuss the most current diagnostic work-up and treatments for cutaneous, mucocutaneous, and visceral leishmaniasis.

## Introduction

Leishmaniasis is a disease caused by an intracellular parasite of the genus *Leishmania*. The disease is endemic to every continent except Australia and Antarctica. Twenty disease-causing *Leishmania* species (Old World and New World) can be transmitted to mammalian hosts via the bite of a female sand fly (Table 1, p. 26).<sup>1</sup> Once transmitted, the extracellular flagellated motile leishmanial promastigotes are taken up by macrophages, where they transform into intracellular, aflagellate amastigotes and multiply within the phagolysosome of the macrophage by binary fission (Figure 1). Depending on the species and host response, the resultant leishmanial infection can lead to cutaneous, mucocutaneous, or visceral syndromes.

Cutaneous leishmaniasis (CL), caused by several leishmanial species, is endemic to many

areas of Latin America.<sup>3</sup> The most common clinical picture is that of one or several gradually expanding nodules or plaques that become ulcerated or verrucous. The lesions are most commonly painless unless secondarily infected or overlying a joint due to the restricted mobility it causes during and after the healing process.<sup>3,4</sup> The lesions commonly heal spontaneously over a period of several months and typically leave behind atrophic, cribriform scars with a hyperpigmented halo. The most common sites are the face, neck, arms, and legs.<sup>3</sup> The most severe cutaneous form is diffuse (disseminated) leishmaniasis. It consists of many non-ulcerating, keloid-like lesions on the face and limbs and is seen in patients with defects in the cellular immune response.<sup>5</sup> Nasal infiltration and ulceration can occur; however, nasal septum destruction does not occur in CL.<sup>3</sup> The clinical severity of cutaneous leishmaniasis varies widely,

depending on diverse factors, including the immune system-pathogen interaction, host genetic factors, acquired resistance to infection, age, and skin temperature.<sup>6</sup> *Leishmania* parasites may persist in healed CL scars and lymph nodes despite adequate initial treatment. This subclinical colonization can result in reactivation during periods of immunosuppression.<sup>1</sup>

Mucocutaneous leishmaniasis, usually due to parasites of the *L. braziliensis* complex, is much less frequent than localized CL. Mucocutaneous leishmaniasis presents as nasal congestion, bleeding, and mucosal erosions. Unlike diffuse leishmaniasis, it can cause destruction of the nasal septum, palate, and other mucosal structures.<sup>2,3</sup> It commonly has an incubation period anywhere from a few months to more than 20 years. It may present years after cutaneous lesions have healed, making follow-up important for the patient. In some patients, tissue loss can become so extensive in the mouth and nose region that it causes a very characteristic "tapir face" known as espundia.<sup>3</sup>

Visceral leishmaniasis (VL), or kala-azar, results from diffuse spread of the parasite in the bone marrow, liver, and spleen. The typical patient will present clinically with fever, wasting, cough, lymphadenopathy, and hepatosplenomegaly. Visceral disease may progress abruptly or follow a more insidious course. Complications that can lead to death in untreated patients include oronasal and gastrointestinal hemorrhage, pneumonia, nephritis and enteritis.<sup>3</sup> Cutaneous findings are most commonly nonspecific in visceral disease. An interesting sequela of untreated VL is post-kala-azar dermal leishmaniasis. It appears clinically as diffuse hypopigmented macules, malar rash, papules, nodules, and plaques throughout all areas of the body. This complication is found almost exclusively in India and East Africa.<sup>3</sup>

The efficacy of monoclonal tumor necrosis factor- $\alpha$  (TNF- $\alpha$ ) inhibitors has spurred fast-growing clinical use for a variety of indications, a trend that promises to continue.<sup>7</sup> However, the immune inhibition that makes TNF- $\alpha$  blockers so effective also results in increased susceptibility to a range of bacterial, fungal, viral,

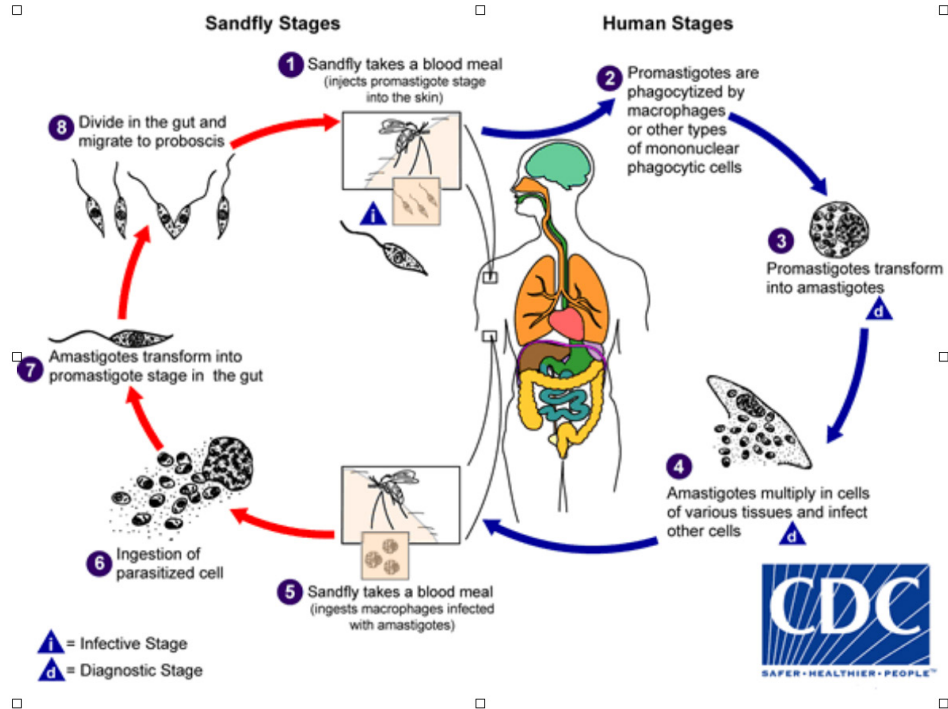


Figure 1. CDC leishmanial life cycle<sup>21</sup>

and protozoan opportunistic infections as well as various cancers.<sup>8-11</sup>

We report a case of rapidly progressive cutaneous leishmaniasis in a young traveler who was taking adalimumab for juvenile idiopathic arthropathy (JIA). After diagnosis, the patient's cutaneous disease rapidly improved on a short course of liposomal amphotericin B.

## Case Presentation

An otherwise healthy, 14-year-old male with a history of mild idiopathic JIA presented to the infectious disease clinic with multiple skin ulcers. The patient had been treated with adalimumab for six months. The lesions first appeared four weeks after traveling to Colombia. Initially, cutaneous manifestations were limited to a painless, pruritic papule on the right ankle. Over the next week the patient developed adenopathy in his groin and axillae, the original ankle papule ulcerated, and additional ulcers appeared on his extremities, torso, and face. The patient was treated three times with TMP-SMX during the course of one month by other practitioners for presumed resistant *Staphylococcus aureus* abscesses, without improvement of symptoms.

On presentation, the patient denied any fatigue, night sweats, or weight loss. Vital signs were stable. Clinical examination revealed 12 painless ulcers with granulation tissue. The initial ulcer, located on his right ankle, was the most prominent (**Figure 2**). Based on clinical exam, he was presumed to have cutaneous leishmaniasis (CL). Tissue specimens were collected for examination by the Centers for Disease Control and Prevention (CDC). The patient was instructed to apply silver alginate dressings daily and was placed on an initial course of fluconazole 200 mg once daily to treat the potential cutaneous leishmaniasis infection.

Ten days later, the pathology was reported to be consistent with but not diagnostic of leishmaniasis, showing overlying epidermal hyperplasia with mixed areas of granulomatous inflammatory infiltrate and stromal fibrosis. Acid-fast bacilli stains were negative, ruling out infection with mycobacterial species. The nasal swab and two fresh skin biopsies sent to the CDC for polymerase chain reaction (PCR) and culture with isoenzyme analysis identified *L. panamensis* in both skin and nasal mucosa.

While awaiting diagnostic confirmation, the patient's lesions had enlarged, and an additional lesion occurred on his chin. He had also developed increasing rhinitis with sinus congestive symptoms. Because of the worsening cutaneous lesions and concern for mucocutaneous leishmaniasis, the patient was started on liposomal amphotericin B, and he showed rapid improvement. A total dose of 27 mg/kg was administered (3 mg/kg per day on days 1 through 7, 14 and 21). All lesions healed in four weeks without recurrence.

## Discussion

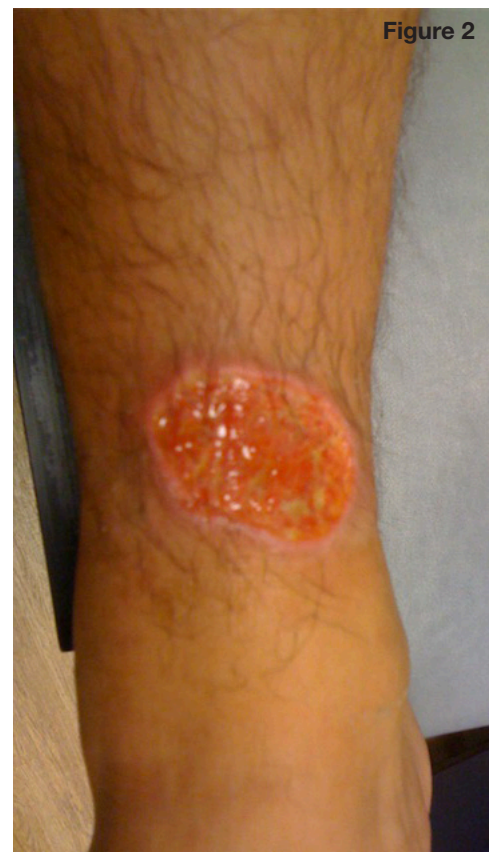Confirming the diagnosis of leishmaniasis can be difficult. The best results are obtained through a combination of clinical history, physical exam findings (including dermatoscopy), and specimen collection. A suggested algorithm for diagnosing a patient with suspected cutaneous leishmaniasis, according to CDC recommendations, is presented in **Figure 3** and goes as follows:

A detailed history is obtained from the patient concerning possible sand fly bites or travel in endemic areas. A detailed medication reconciliation and past medical history will help target those patients at increased risk for leishmaniasis due to immunosuppression.

Next, a thorough clinical examination is performed. There is a broad spectrum of clinical findings in CL. Localized cutaneous disease caused by New World and Old World species usually presents as a small, well-circumscribed papule at the site of inoculation. The lesion may slowly enlarge over several weeks into a nodule or plaque that can further progress to an ulcerated or verrucous lesion. While solitary lesions are most common, multiple lesions do occur and can distribute along a sporotrichoid pattern. Visual examination of the lesions with a dermatoscope can increase the practitioner's accuracy of diagnosing leishmaniasis. A 2015 review of 127 cutaneous leishmaniasis cases observed by dermoscopy revealed characteristic findings including erythema, vascular structures, keratin plugging, and a white starburst pattern.<sup>12</sup> The most commonly seen vascular structures were comma-shaped vessels (73%), linear irregular vessels (57%), dotted vessels (53%), polymorphous vessels (26%), hairpin vessels (19%), and arborizing telangiectasia (11%). A combination of two or more vascular structures was seen in 88% of cutaneous lesions.

After establishing that leishmaniasis is high on the differential, the next step is to contact the CDC to obtain specialized media used for culturing the highly fastidious organism. The specialized culture medium is a sterile buffered medium with a neutral pH (7-7.4). Commonly used culture media include Novy-MacNeal-Nicolle medium (NMN), brain heart infusion (BHI), Evan's modified Tobie's medium (EMTM), Schneider's Drosophila medium, and Roswell Park Memorial Institute medium (RPMI). The CDC provides free isoenzyme analysis and polymerase chain reaction (PCR) testing of cultured organisms. In addition, it reviews the impression smear and pathology reports. While fresh tissue biopsy is most commonly used for impression smear and histopathology slides, needle aspirates can be used for culture and PCR testing, and dermal scrapings can be used for thin smear preparations.

Finally, if visceral leishmaniasis is suspected, one should obtain the rK39 serologic testing. The rK39 ELISA test detects circulating antibodies against the recombinant K39 protein. Recombinant K39 protein is an epitope present on amastigotes of *Leishmania* species that causes visceral infection. Research in India has shown an



**Figure 2.** Ulceration on ankle due to leishmaniasis.

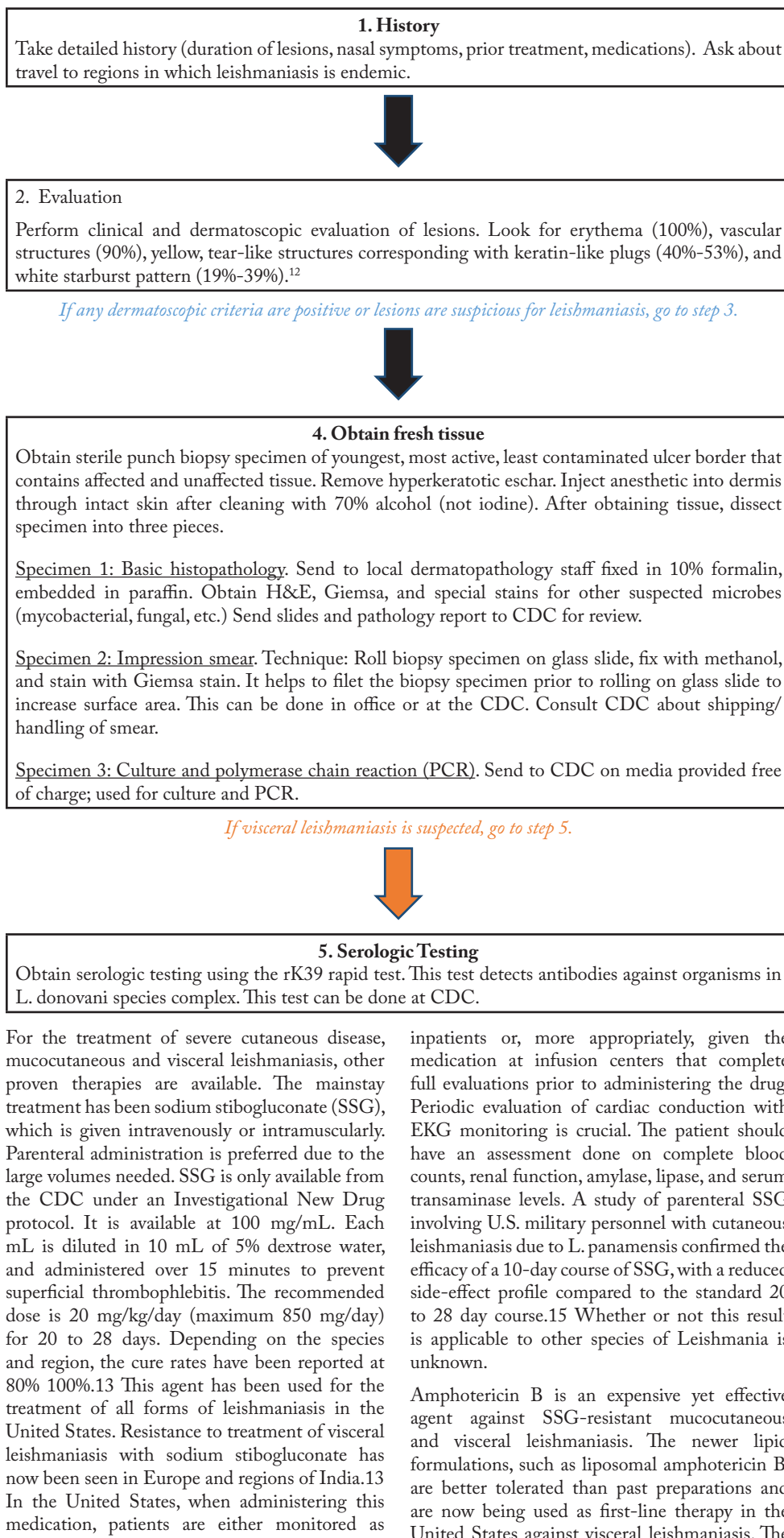
estimated sensitivity of 100% and specificity of 97% for detecting active visceral infection.<sup>13</sup>

Treatment of leishmaniasis is challenging. Due to the large number of *Leishmania* species, along with the variable efficacy and toxicity of many of the pharmacologic agents used to treat infections due to these species, systematic clinical-trial data is lacking.<sup>3</sup> Preventing sand fly bites is crucial to avoid infection. In addition, due to the increasing use of immunosuppressant medications, it is prudent to warn patients that they must be cautious about traveling to leishmaniasis-endemic regions; and if travel to these countries cannot be avoided, to wear protective clothing made of fine-mesh netting, use N,N-Diethyl-meta-toluamide (DEET), and remain in well ventilated areas.<sup>1,13</sup>

While mild forms of cutaneous leishmaniasis commonly heal spontaneously and do not require treatment, visceral, mucocutaneous, and severe forms of cutaneous leishmaniasis have increased morbidity and should be treated. *L. braziliensis* complex members (*L. braziliensis*, *L. guyanensis*, *L. panamensis*, and *L. peruviana*) have the potential to progress into mucocutaneous leishmaniasis and should be treated.<sup>13</sup>

There are several treatment options for cutaneous disease. In addition to oral and parenteral medications, local therapies used on some forms of cutaneous leishmaniasis include cryotherapy, intralesional injection of .4 mL to .8 mL sodium stibogluconate, local heat therapy at 40 degrees Celsius to 42 degrees Celsius, and various topical paromomycin preparations (not readily available in United States).<sup>13</sup>

**Figure 3. Diagnostic algorithm for cutaneous leishmaniasis work-up**



standard dose for immunocompetent patients suffering from visceral disease is 3 mg/kg IV on days 1 through 5, 14, and 21. Response to liposomal amphotericin B may be suboptimal in patients with HIV because of increased immunosuppression, so the recommended dose for those patients is 4 mg/kg IV.<sup>17</sup> An open-label study performed by Sundar et al. found that a single infusion of 5 mg/kg liposomal amphotericin B was as effective in the treatment of visceral leishmaniasis as a five-day course of once daily 1 mg/kg infusions. Past research on cutaneous disease has shown a mixed response to amphotericin B treatment.<sup>13</sup> Our case offers further evidence of the success of liposomal amphotericin B in the treatment of cutaneous leishmaniasis.

One of the most significant breakthroughs in the management of leishmaniasis was the development of miltefosine, an affordable, orally administered and well-tolerated treatment for all forms of leishmaniasis. Phase II and III drug studies in India showed that miltefosine, at 2.5 mg/kg/day given for four to six weeks, was 95% to 97% effective in curing Indian visceral leishmaniasis.<sup>13</sup> A 2011 phase IV trial from Bangladesh found a 28-day course of miltefosine to be effective for treatment of visceral leishmaniasis.<sup>18</sup> In addition, a study in Colombia showed a 91% cure rate of infections caused by *L. panamensis*.<sup>13</sup> In March 2014, the FDA approved the use of oral miltefosine for visceral leishmaniasis due to *L. donovani*, cutaneous leishmaniasis due to *L. braziliensis*, *L. guyanensis*, and *L. panamensis*, and mucosal leishmaniasis due to *L. braziliensis*. The medication includes a black box warning against use during pregnancy because of risk of fetal harm.

Oral ketoconazole, itraconazole, fluconazole, allopurinol, and dapsone can be used to accelerate the healing of cutaneous lesions that do not progress to mucosal disease and will likely self-resolve.<sup>13</sup> These agents have limited adverse effects and are a reasonable approach to patients with uncomplicated cutaneous disease. In addition to pharmacologic therapies, treatment of other negative factors including malnutrition, concurrent systemic illness, location secondary infection, and immunosuppressive medications must be addressed.<sup>1</sup>

TNF-alpha inhibitors are increasingly reported in the literature as a risk factor for leishmaniasis infection. Despite extensive research on this topic, the leishmaniasis immune response is not completely understood.<sup>22</sup> While research aimed at examining the importance of TNF-alpha's role in protecting individuals from leishmaniasis has produced mixed finding, most of the literature points to a protective role. Specifically, experiments done on mice revealed that TNF-alpha deficient mice were more likely to die from *L. major* compared to non-deficient TNF-alpha mice.<sup>23</sup> Other research revealed higher mortality rates in those without TNF-alpha production and that TNF-alpha persisted in tissues after healing, indicating a role in preventing disease relapse.<sup>24</sup> The TNF signaling pathways generate

an inflammatory response and mediate resistance to infection by intracellular pathogens. One of the most important mechanisms by which TNF-alpha protects against this organism is by helping generate a pathway that produces nitric oxide, which kills the intracellular amastigotes.<sup>25</sup>

due to the 2014 FDA approval of the first successful oral medication (miltefosine) for leishmaniasis, we will likely see increasing use of this medication at the expense of previously used parenteral agents.

## Conclusion

Leishmaniasis is an increasingly common diagnosis in the United States due to an increase in international travel by U.S. citizens. Military personnel have been disproportionately affected in recent years. More than 2,000 laboratory-confirmed cases of cutaneous leishmaniasis and five laboratory-confirmed cases of visceral leishmaniasis were seen in American soldiers serving in Iraq and Afghanistan between 2003 and 2008.<sup>13</sup> With cases on the rise, it is imperative that the U.S. dermatologist understand the diagnostic work-up and treatment of this disease in order to prevent morbidity and mortality.

This report adds to the literature suggesting that anti-TNF-alpha monoclonal antibodies may increase severity of leishmaniasis, and provides an additional case supporting the effectiveness of liposomal amphotericin B for CL. Although sodium stibogluconate is the traditional therapy for relatively severe CL, there is a recent trend to use liposomal amphotericin B based on known efficacy in VL, its good safety profile, and increasing information from cases series in the published literature.<sup>19,20</sup> Our patient improved rapidly on liposomal amphotericin B after discontinuation of adalimumab. Furthermore,

**Table 1. *Leishmania* species<sup>1-4</sup>**

Species	Clinical Features Cutaneous (C); Diffuse cutaneous (DC); Mucocutaneous (MC); Visceral (V)	Warrants Treatment
New World*		
<i>Leishmania mexicana</i> complex		
<i>L. mexicana</i>	C, DC (rare)	
<i>L. amazonensis</i>	C, DC, MC, V (rare)	
<i>L. venezuelensis</i> , <i>pifanoi</i> , <i>garnhami</i>	C, DC (rare)	
<i>Leishmania (Viannia) braziliensis</i> complex		
<i>L. braziliensis</i>	C, MC, V	X
<i>L. guyanensis</i>	C, MC	X
<i>L. panamensis</i>	C, MC	X
<i>L. peruviana</i>	C	X
Old World**		
<i>Leishmania donovani</i> complex		
<i>L. donovani</i>	C, V	
<i>L. infantum</i>	C, V (children), MC (rare)	
<i>L. chagasi</i>	C, MC (rare), V (rare)	
<i>Leishmania tropica</i> complex		
<i>L. tropica</i>	C, MC (rare), V (rare)	X
<i>L. major</i>	C, MC (rare)	X
<i>L. aethiopica</i>	C, DC	

\*Western Hemisphere, extending from central Texas to Central and South Americas (excluding Chile and Uruguay)

\*\*Eastern Hemisphere, endemic in Asia, Africa and southern Europe

## References

1. Kevric I, Cappel MA, Keeling JH. New World and Old World Leishmania Infections. *Dermatol Clin*. 2015;33(3):579-93.
2. Reithinger R, Dujardin JC, Louzir H, Pirmez C, Alexander B, Brooker S. Cutaneous Leishmaniasis. *Lancet Infect Dis*. 2007;7:581-96.
3. Nelson S, Warschaw KE. *Dermatology*. 3rd ed. China: Elsevier Saunders; c2013. Chapter 82, Protozoa and Worms; p. 1391-7.
4. Hall J, Hall B. *Skin. Skin Infections: Diagnosis and Treatment*. Cambridge: Cambridge University Press; c2009. Chapter 9, Parasitology; p.117-122.
5. Carvalho EM, Barral A, Costa JM, Bittencourt A, Marsden P. Clinical and immunopathological aspects of disseminated cutaneous Leishmaniasis. *Acta Trop*. 1994;56:315-25.
6. Weigle K, Saravia NG. Natural history, clinical evolution, and the host-parasite interaction in New World cutaneous Leishmaniasis. *Clin Dermatol*. 1996; 14: 433-50.
7. Nelson AL, Dhimolea E, Reichert JM. Development trends for human monoclonal antibody therapeutics. *Nat Rev Drug Discov*. 2010; 9: 767-74.
8. Mueller MC, Fleischmann E, Grunke M, Schewe S, Bogner JR, Loscher T. Relapsing cutaneous leishmaniasis in a patient with ankylosing spondylitis treated with infliximab. *Am J Trop Med Hyg*. 2009; 81: 52-4. 2006
9. Winthrop KL. Risk and prevention of tuberculosis and other serious opportunistic infections associated with the inhibition of tumor necrosis factor. *Nat Clin Pract Rheumatol*. 2006; 2: 602-10.
10. Zanger P, Kotter I, Kreamsner PG, Gabrysch S. Tumor necrosis factor alpha antagonist drugs and Leishmaniasis in Europe. *Clin Microbiol Infect*. 2012; 18: 670-6.
11. Rosenblum H, Amital H. Anti-TNF therapy: safety aspects of taking the risk. *Autoimmun Rev*. 2011; 10: 563-8.
12. Ayhan E, Ucmak D, Baykara S, Akkurt Z, Arica M. Clinical and dermoscopic evaluation of cutaneous Leishmaniasis. *Int J Dermatol*. 2015; 54: 193-201.
13. Stark C, Chandrasekhar PH, Wang N, Weina PJ, Wells M, Windle ML. Leishmaniasis [Internet]. *Medscape*; 2014 May [ cited 2016 Feb 8]; [ about 8 screens]. Available from: <http://emedicine.medscape.com/article/220298-treatment>
14. Reithinger R, Mohsen M, Wahid M, Bismullah M, Quinnell RJ, Davies CR, et al. Efficacy of chemotherapy to treat cutaneous Leishmaniasis caused by *Leishmania tropica* in Kabul, Afghanistan: a randomized, controlled trial. *Clin Infect Dis*. 2005 Apr 15; 40(8):1148-55.
15. Wortmann G, Miller RS, Oster C, Jackson J, Aronson N. A randomized, double-blind study of the efficacy of a 10- or 20-day course of sodium stibogluconate for treatment of cutaneous Leishmaniasis in United States military personnel. *Clin Infect Dis*. 2002 Aug 1; 35(3): 261-7.
16. Sundar S, Agrawal G, Rai M, Makharia MK, Murray HW. Treatment of Indian visceral Leishmaniasis with single or daily infusions of low dose liposomal amphotericin B: randomised trial. *BMJ*. 2001 Aug 25; 323(7310):419-22.
17. Sundar S, Sinha PK, Rai M, Verma DK, Nawin K, Alam S, Chakravarty J, Valiant M, Verma N, Pandey K, Kumari P, Lal CS, Arora R, Sharma B, Ellis S, Strub-Wourgaft N, Balasegaram M, Oliaro P, Das P, Modabber F. Comparison of short-course multidrug treatment with standard therapy for visceral Leishmaniasis in India: an open-label, non-inferiority, randomised controlled trial. *Lancet*. 2011 Feb 5; 377 (9764): 477-86.
18. Rahman M, Ahmed BN, Faiz MA, Chowdhury MZ, Islam QT, Sayeedur R, Rahman MR, Hossain M, Banali AM, Islam MN, Mascie-Taylor CG, Berman J, Arana B. Phase IV trial of miltefosine in adults and children for treatment of visceral Leishmaniasis (kala-azar) in Bangladesh. *Am J Trop Med Hyg*; 2011 Jul. 85(1):66-9.
19. World Health Organization. Control of the leishmaniasis. *World Health Organ Tech Rep*. 2010; Ser: xii-xiii, 1-186, back cover.
20. Wortmann G, Zapor M, Ressler R, Fraser S, Hartzell J, Pierson J, Weintrob A, Magill A. Liposomal amphotericin B for treatment of cutaneous Leishmaniasis. *Am J Trop Med Hyg*. 2010; 83: 1028-33.
21. Parasites-Leishmaniasis; [ Internet]. Atlanta: DPDx. 2015 Nov 2 [2016 Feb 6]; Biology [ about 1 screen]. Available from: <http://www.cdc.gov/parasites/Leishmaniasis/biology.html>
22. Neumayr A, Morisot G, L Visser, Lockwood D, Beck B, Schneider S, Bellaud G, Cordoliani F, Foulet F, Laffitte E, Buffet P, Blum J. Clinical aspects and management of cutaneous Leishmaniasis in rheumatoid patients treated with TNF-a antagonists. *Travel Med Infect Dis*. 2013 Nov-Dec; 11 (6):412-20.
23. Wilhelm P, Ritter U, Labobow S, Donhauser N, Rollinghoff M. Rapidly Fatal Leishmaniasis in resistant C57BL/6 Mice Lacking TNF. *J Immunol*. 2001; 166: 4012-4019.
24. Leonardis D, Govoni M, Lo Monaco A, Trotta F. Visceral Leishmaniasis and anti-TNF-a therapy: case report and review. *Clin Exp Rheumatol*. 2009 May-Jun; 27 (3):503-506.
25. Liew F, Li S, Millott S. Tumor necrosis factor in Leishmaniasis. *Immunology*. 1990 Dec; 71(4):556-509. 2009;100(1):61-4. Spanish.
23. Nanda A, Al-aradi I, Ali MT, Alsaleh QA. Anterior cervical hypertrichosis (hairy throat): is it a sign to worry about?. *Clin Exp Dermatol*. 2007;32(1):112-4.
24. Trueb RM. Causes and management of hypertrichosis. *Am J Clin Dermatol*. 2002;3:617-27.
25. Chandrakumar A, Martyn-simmons CL. Anterior cervical hypertrichosis with associated developmental delay and learning difficulties in two sisters. *J Dermatol*. 2012;39(12):1061-2.
26. Reddy S, Antaya RJ. Two cases of isolated anterior cervical hypertrichosis. *Pediatr Dermatol*. 2010;27(5):531-3.
27. Garcia-Cruz D, Figuera LE, Cantu JM. Inherited hypertrichoses. *Clin Genet*. 2002;61(5):321-9.
28. Cantu JM, Ruiz C. On atavisms and atavistic genes. *Ann Genet*. 1985;28(3):141-2.