

The Adaptability and Utility of the Bilobed Transposition Flap

Christopher Mancuso, MHS,* Jason Mammino, BS,* Logan Holman, BS,* Joseph K. Francis, MD**

*Medical Student, 2nd year, Nova Southeastern University College of Osteopathic Medicine, Fort Lauderdale, FL

**Adjunct Clinical Assistant Professor, University of Florida Department of Dermatology, Gainesville, FL

Disclosures: None

Correspondence: Christopher Mancuso, MHS; cm2447@nova.edu

Abstract

The bilobed transposition flap began as a technique to repair the nasal tip. The purpose of our review is to catalogue the successes of the bilobed flap since it was first described by Esser in 1918, as well as the modifications created by other physicians since then. A PubMed Search from 1900 to 2015 for the words "bilobed flap" yielded 150 results. In the 35 cases described, there were new developments in the design and use of the bilobed flap. Varying the angle of rotation, length, and width of the flaps allowed for variability to meet the demands of different anatomical locations. Each of the cases demonstrated the benefits of the bilobed flap technique in allowing for ample blood supply, proper healing, and preservation of anatomy. The functional and aesthetic results achieved further validate the use of the bilobed flap in locations other than the nasal tip.

Introduction

The bilobed flap was first described in German literature in 1918 by Dr. Johannes Esser as a two-pedicle flap.¹ All later variations maintain the same general principle of utilizing a double transposition in areas where a single transposition flap is not adequate.² Bilobed flaps are used in reconstructive surgeries that require both recruitment of skin from a site with more tissue laxity³ and a low-tension closure to improve healing and scar aesthetics.⁴ When designing a bilobed flap, it is crucial to the survival of the flap to maintain an adequate blood supply with a sufficient pedicle.⁵ What makes the bilobed flap highly useful is its ability to utilize a common pedicle to move skin from an area of further distance and greater laxity to the site of a defect with limited mobility.⁶ This strategy is similar to that of the rhombic transposition flap with a Z-plasty, but transposes a greater area of skin while maintaining the mobility. Also, by rotating the flap only 90°, the bilobed flap minimizes the problem of inadequate blood flow to the tips of the margin that is present in other techniques, such as those that require 180° rotations.² In addition, the local transposition of skin in this flap creates a closer skin match than do alternatives like skin grafts. Other variations of the bilobed flap design have changed lobe sizes and rotation angles to accommodate varied defects and body locations.

Methods

A PubMed search from 1900 to 2015 for the words "bilobed flap" yielded 150 results. Of those, only 35 papers were relevant and included sufficient information on the bilobed flap or proposed modifications. The other 115 papers either did not fit into the scope of this paper or were not sufficiently descriptive. The 35 papers included in our research addressed cases involving anatomical sites including the nose (30), ear (13), forearm (13), hand (20), cheek (4), thorax (19), genitals (11), foot (6), eye (16), mouth (15), and leg (3).

Discussion

Nose

The nose can be difficult to repair due to the limited available sources from which to locally harvest tissue and the high potential for distortion. If planned properly and well executed, a bilobed flap can restore the natural appearance of the nose. When the flap is not

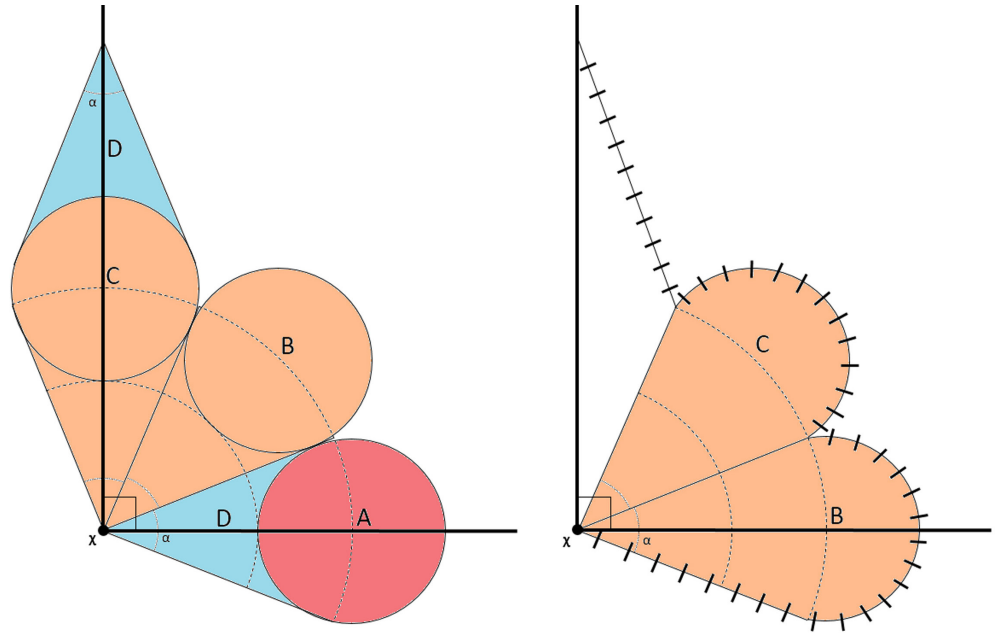


Figure 1. Zitelli's bilobed flap design.

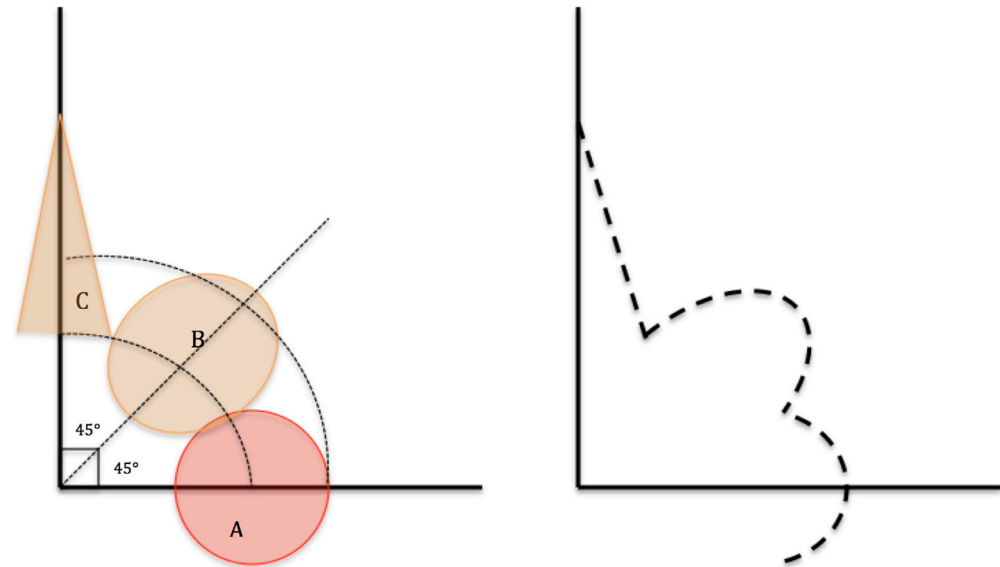
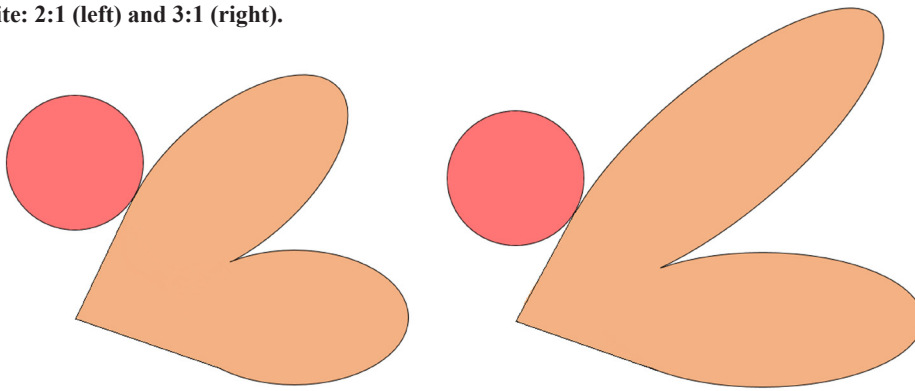


Figure 2. Left: Lobe A represents the original defect that is removed. Lobe B is 10% longer from the distal defect to the pivot point of lobe A and equal to the width of lobe A. Lobe C is 130% longer from the distal defect to the pivot point of lobe A and 67% the width of lobe A. Right: Dashed lines represent the sutured bilobed flap. The original defect is closed by transposition of lobe B to lobe A. Lobe B is then closed with the transposition of lobe C. The change from Zitelli's bilobed flap prevents nasal alar retraction.

Figure 3. Two variations in size ratios of the bilobed flap as described by White: 2:1 (left) and 3:1 (right).



precisely planned, undersizing can create contraction and distortion of the symmetry of the nose, and oversizing can cause pincushioning and depression.⁷

Zitelli was the first to modify Esser's bilobed flap.⁶ The original design indicated an angle of rotation of 90° for each lobe, for a total angle of 180°. In 1989, Zitelli proposed the most effective angle of rotation as 45° for each lobe, a modification that allowed for greater precision when reconstructing nasal defects.⁶

Zitelli's modification also makes the primary lobe the same size as the defect, but it makes the secondary lobe longer to avoid the formation of a dog ear upon primary closer of the secondary-lobe donor site. Zitelli's use of smaller, 45° angles instead of 90° angles for each lobe was validated by Miller (Figure 1).⁸ In an experiment looking at three different bilobed flaps that varied in angle of flap rotation (30°, 45°, and 60°, respectively), Miller demonstrated that a 45° rotation maximizes benefits.

Xue suggested a modification to the Zitelli flap that reduces the risk of alar retraction (Figure 2).⁹ This modification changes the proportions of the lobes while maintaining Zitelli's rotation angles. In Xue's approach, the primary lobe is 10% longer than the length of the defect but retains the same width. The secondary lobe is 130% longer than the length of the defect, and the width is two-thirds the width of the primary lobe. This alteration avoids distortion created by tension, as explained by Dzubow's principle of pivotal restraint, which says that a transposition flap will be tethered to the base of the flap, thus creating a tension vector that pulls upward on the alar rim.¹⁰

Cheek

A benefit of the bilobed flap for lateral cheek reconstruction is that donor skin can be recruited from the inferior preauricular region, which is well matched for texture and color. White describes a bilobed flap on the cheek in which the lobe distal to the wound is made smaller than the proximal lobe, between 2:1 to 4:1 in length-to-width ratio (Figure 3).¹¹

Ear

When considering reconstruction of the auricle, there are two major modifications of the bilobed flap for repair of the earlobe -- the Gavello and the D'Hooghe techniques.¹² The Gavello technique utilizes a horizontal bilobed flap inferior and posterior to the defect (Figure 3). The D'Hooghe

technique uses a lobe from each of the preauricular and postauricular areas to reconstruct the earlobe (Figure 4).¹³ The major disadvantage to the D'Hooghe technique is it can only be used for small defects.

Brent's modification is used for large defects of the lower auricle—primarily the earlobe—and utilizes a cartilage graft to counteract the contraction of tissue during wound healing.¹⁴

Gupta describes a bilobed variation similar to D'Hooghe's (Figure 4). This modification uses a lobe from the preauricular area and a lobe from the postauricular area, which is comparable to the

D'Hooghe technique; however, the base is smaller and positioned more superior to the sutured edges of the inferior margin of the lobe.¹⁵

Weerda proposed another modification for repair of the helix and earlobe that also uses cartilage grafts to reconstruct the earlobe and helix. This flap is a variation of the Gavello bilobed flap, but it harvests costal cartilage to construct the inferior portion of the helix and prevent contraction of the earlobe.¹⁶

Rodríguez suggested a method for repair of defects of moderately sized earlobes in which a bilobed flap has an anterior base, and the primary lobe is the same size as the defect. The secondary lobe is smaller and transposed on the posterior aspect of the earlobe.¹⁷ The disadvantage to this variation is scars below the earlobe.

Upper Extremities

Nikkhah describes using a bilobed flap for the excision of a sarcoma on the dorsum of the forearm.¹⁸ In this approach, the first flap is the same size as the defect, and the second lobe is twice as long as the first flap but half the width.

Zhang describes a flap for the thumb that includes skin from the second web of the hand and the dorsum of the index and middle fingers.¹⁹ The entire flap with a double neurovascular pedicle is elevated and mobilized. The skin is transferred

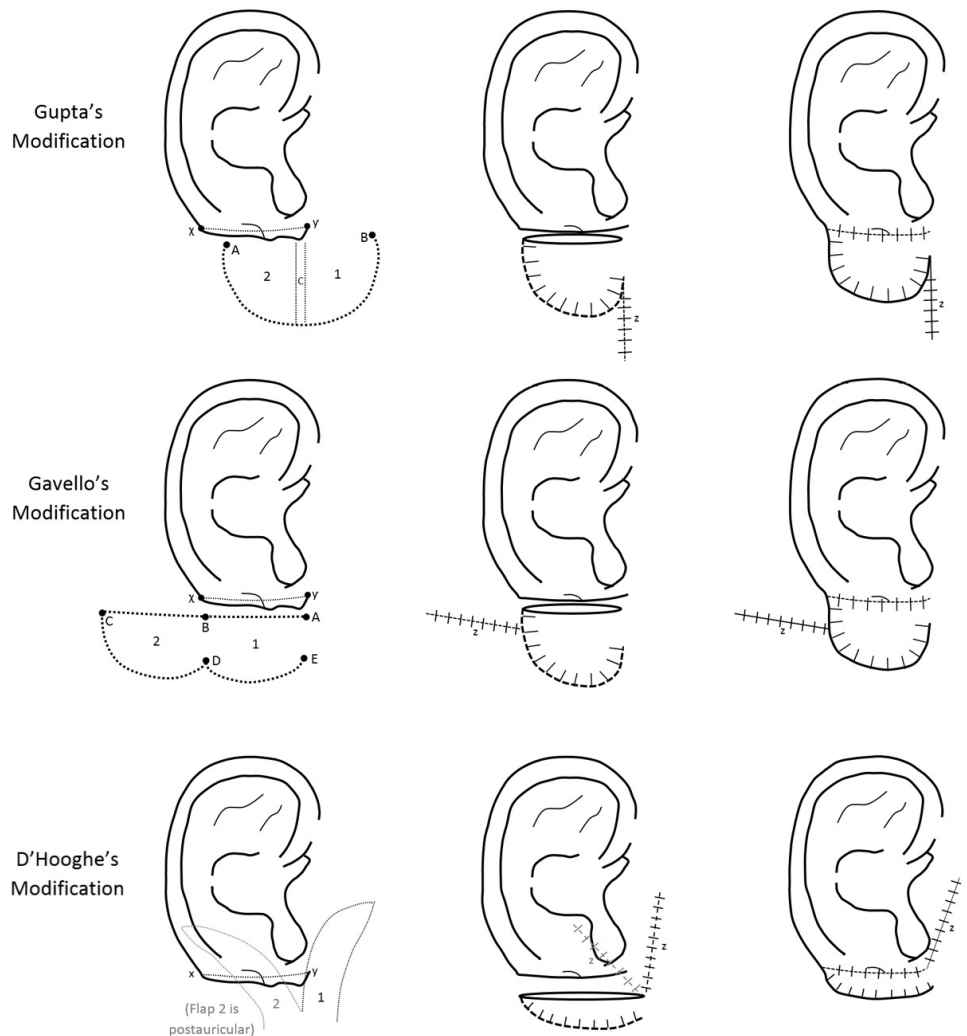
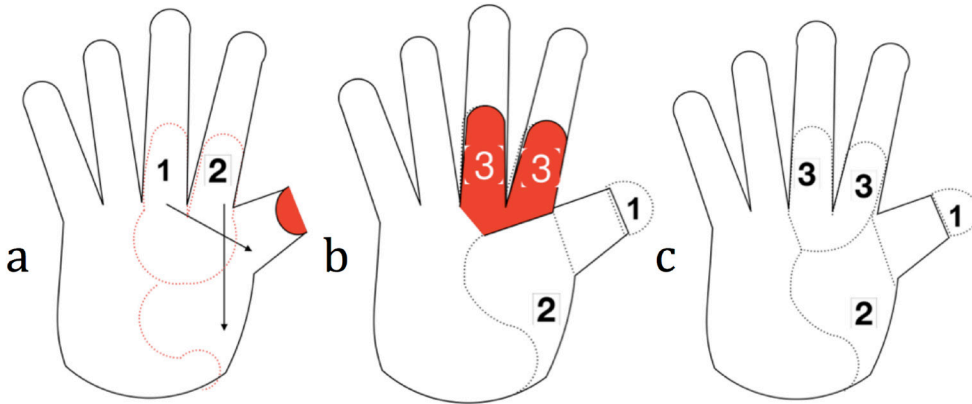


Figure 4. Modifications of the bilobed flap by Gupta, Gavello, and D'Hooghe, respectively, for earlobe repair.

Figure 5. a) The skin lobes created from the dorsum of the index and middle fingers, labeled 1 and 2, distally at the level of the proximal interphalangeal (PIP) joints and proximally at the MCP joint. An S-shaped incision is made on the dorsum of the second metacarpal. Lobe 2 is transposed to cover below the first metacarpal. Lobe 1 then covers the amputated thumb. b) Lobes 1 and 2 are sutured into place. Lobe 3 represents the hand area that will be covered by a skin graft from the thigh. c) Lobe 3 is skin grafted, and all incisions are sutured closed.



to the defect on the thumb via a subcutaneous tunnel (**Figure 5**). Dogan has mentioned similar success using bilobed flaps for dorsal thumb and web space.²⁰

Amputated fingers have been repaired using techniques described by Saba, known as a DMCA (dorsal metacarpal artery) flap.²¹ The first and second dorsal metacarpal arteries are used to resurface the phalangeal stumps. Saba uses an S-shaped incision to maintain the innervation and blood supply for the phalanges. The benefit of the modification is that it is a single stage procedure with high success rate.

Sahin uses the bilobed flap surgery to create web spaces in the syndactyly release.²² The base of the bilobed flap is designed on the dorsum of the hand, between the metacarpal heads of the involved fingers. The flap is rectangular, with a 2:1 length-to-width ratio. Markings are on the palmar side of the fingers, and the incisions are zigzag mirror-image triangular flaps. The triangular flaps are then wrapped around the newly synthesized fingers.

Vuillermin used a bilobed flap that improved hand position, soft-tissue releases, skeletal realignment, muscular rebalancing, and free skeletal transfer for radial dysplasia.²³ The bilobed flap is unique in that it avoids the forearm stiffness and ulnar injury that can result from other surgical procedures.

Trunk

Bilobed flaps are used on the torso with burns in the axillary region. Smith created a modified bilobed flap to place scars in a relatively inconspicuous location (anterior and posterior axillary lines) with no breast torsion.²⁴ The technique involved placing the flap laterally and decreasing the angle of rotation of each lobe from 90° to 45°. The point of rotation may be centered cephalic to the triangular space to include the anterior branches of the circumflex scapular artery.

Charanek describes a bilobed thoracoabdominal myocutaneous flap to cover large wounds secondary to radical mastectomies.²⁵ The technique changed the angles from 60° to 90° to allow for larger coverage. Also, the flaps were modified caudally to diminish the tension and lower the rate of dehiscence and necrosis.

Lower Extremities

The versatility of the bilobed flap is further demonstrated at sites of the lower body (**Figure 6**). Sharkirov describes a technique in which ulcers on the plantar surface of the foot were closed using bilobed flaps.²⁶ The angle between the lobes was the traditional 90° as described by Esser, but the size of the lobes was modified so the secondary lobe was smaller than the primary lobe, which is more characteristic of later modifications.

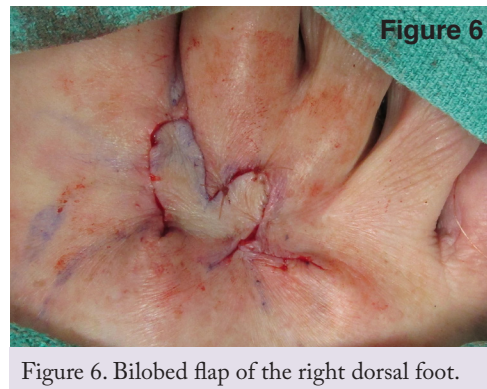


Figure 6. Bilobed flap of the right dorsal foot.

Genitalia

Grishkevich describes a medially based bilobed flap much larger than those previously discussed.²⁷ The primary lobe is 20 cm long and 10 cm wide; the secondary lobe is shorter but maintains the 10 cm width. Grishkevich continues with the Esser design of a 180° total rotation to transpose skin from the inguinal region into a defect in the anogenital area. A second stage was completed several months later to remove dog ears.

Sampaio describes a bilobed repair for a circular, 6.8 cm defect following an HPV lesion excision in the pubic region.²⁸ The flap employed the modern, 45° rotation of each lobe, for a total of 90° along the base; but while the primary lobe was the same size as the defect, the secondary lobe was longer and narrower. Lee described a similar bilobed flap technique for the treatment of sacral sores.³⁰

Kishi presented a method for surgically treating gluteal hidradenitis suppurativa with a lateral bilobed flap, repairing a 23 cm by 20 cm defect on the patient's left buttock.²⁹ This variation used the

original 180° total rotation, a primary lobe smaller than the defect and a secondary lobe smaller than the primary lobe.

Ninomya described a reconstruction of the vulva using two bilobed flaps.³¹ The technique utilized a 90° total rotation and primary lobes shorter than but equal in width to the secondary lobe. Because two bilobed flaps were utilized, the primary lobes from each flap were 50% of the defect size, together achieving 100% coverage.

Conclusion

Many authors have considered bilobed flaps ideal for aural and nasal procedures; however, the use is much broader. Overall, the utility of the bilobed flap has expanded over the past century to areas other than the nasal tip. The design allows for various components to be changed to accommodate the requirements of a particular area of the body, such as rotation angle and size of the lobes.

Further design improvements and innovative uses appear to be in the future as the bilobed flap becomes more prevalent in the reconstructive surgical arena.

References

1. Esser JF. Gestielte loakle Nasenplastik mit zweizipfligen Lappen, Deckung des sekundären Defektes vom ersten Zipfel durch den Zweiten. Deutsche Zeitschrift für Chirurgie. 1918;143:335-9.
2. Zimany A. The Bi-Lobed Flap. Plast Recon Surg. 1952 Jun;11(6):424-34.
3. Zoumalan RA, Hazan C, Levine VJ, Shah AR. Analysis of Vector Alignment With the Zitelli Bilobed Flap for Nasal Defect Repair: A Comparison of Flap Dynamics in Human Cadavers. Arch Facial Plast Surg. 2008 May;10(3):181-5.
4. Wang ZG, Chen XJ, Chen ZY. A modified bilobed flap design for nasal tip defects. Plast Aesthet Res. 2014 Jun;1(1):16-20.
5. Salgarelli AC, Bellini P, Multinu A, Magnoni C, Francomano M, Fantini F, et al. Reconstruction of Nasal Skin Cancer Defects with Local Flaps. J Skin Cancer. 2011 Apr 12;2011:1-8.
6. Zitelli JA. The Bilobed Flap for Nasal Reconstruction. Arch Dermatol. 1989 Jul;125:957-9.
7. Jellinek NJ, Cordova KB. Bilobed Flap for Reconstruction of Small Alar Rim Defects. Dermatol Surg. 2013;39:649-52.
8. Miller CJ. Design Principles for Transposition Flaps: The Rhombic (Single-Lobed), Bilobed, and Trilobed Flaps. Dermatol Surg. 2014;40:S43-S52.
9. Xue CY, Li L, Guo LL, Li JH, Xing X. The Bilobed Flap for Reconstruction of Distal Nasal Defect in Asians. Aesth Plast Surg. 2009 Mar 31;33:600-4.
10. Cho M, Kim DW. Modification of the Zitelli Bilobed Flap. Arch Facial Plast Surg. 2006 Nov;8:404-9.
11. White CP, Rosen N, Muhn CY. The usefulness of the bilobed flap for lateral cheek defects. J Plast Surg. 2012;20(1):e19-e21.
12. Cabral AR, Brinca A, Figueiredo A, Alonso N, Vieira R. Earlobe reconstruction by the Gavello technique and bilobed flap. An Bras Dermatol. 2013;88 (2), 272-5.
13. D'Hooghe PJ. Earlobe reconstruction with a bilobed, caudally-based flap. Plast Reconstr Surg. 1977:764.
14. Brent B. Earlobe Construction with an Auriculo-Mastoid Flap. Plast Recon Surg. 1976 Mar;57(3):389-91.
15. Gupta DK, Devendra S. Single-stage earlobe reconstruction: a simple method with promising results. Eur J Plast Surg. 2014;37:393-6.
16. Weerda H. Reconstructive Facial Plastic Surgery: A Problem-Solving Manual. 2nd rev. ed. Stuttgart: Thieme; 2015. 176 p.
17. Rodriguez FF, Cecilia JN, Torrejon LR. Earlobe Reconstruction with a Modified Bilobed Flap. Plast Recon Surg. 2010;126(1): 23e-24e.
18. Nikkhah D, Jones M. The bilobed flap as a lifeboat flap for a forearm soft tissue defect. J Plast Reconstr Aesthet Surg. 2015 Aug;68(8):1153-4.
19. Zhang X, Yang L, Shao X, Wen S, Zhu H, Zhang Z. The second web bilobed island flap for thumb reconstruction. J Hand Surg Am. 2011 Jun;36(6):998-1006.
20. Dogan F, Coruh A. Novel biogeometric designs of first dorsal metacarpal artery flap in hand reconstruction. J Burn Care Res. 2014 Nov;35(6): e399-e405.
21. Saba S, Lee J, Pathy V, Weber R. Salvage of a Thumb Replant Using a Bilobed Dorsal Metacarpal Artery Island Flap: Case Report and Literature Review. Hand. 2008;3(4):366-71.
22. Sahin C, Ergun O, Kulahci Y, Sever C, Karagoz H, Ulkur E. Bilobed flap for web reconstruction in adult syndactyly release: a new technique that can avoid the use of skin graft. J Plast Reconstr Aesthet Surg. 2014;67(6):815-21.
23. Vuillermin C, Wall L, Mills J, Wheeler L, Rose R, Ezaki M, et al. Soft tissue release and bilobed flap for severe radial longitudinal deficiency. J Hand Surg Am. 2015 May;40(5):894-9.
24. Smith M, Lee J. Bilobed Flap for Axillary Reconstruction. Plast Recon Surg. 2009 Jul;124(1):179e-80e.
25. Charanek A. A bilobed thoracoabdominal myocutaneous flap for large thoracic defects. Ann Plast Surg. 2014 Apr;72(4):451-6.
26. Shakirov BM. Bilobed skin flap in the surgical treatment of post-burn trophic ulcers of plantar surface of the foot. Burns. 2012;38:e35-e38.
27. Grishkevich VM. Postburn Perineal Obliteration: Elimination of Perineal, Inguinal, and Perianal Contractures With the Groin Flap. J Burn Care Res. 2010 Sep;31(5):786-90.
28. Sampaio FM, Gualberto GV, Francesconi do Valle AC, Miller MD, Galhardo MC, Cotrim de Souza PR. Use of the bilobed flap in the pubic region after tumoral lesion excision. An Bras Dermatol. 2013;88(6):224-6.
29. Kishi K, Nakajima H, Imanishi N. Reconstruction of skin defects after resection of severe gluteal hidradenitis suppurativa with fasciocutaneous flaps. J Plast Reconstr Aesthet Surg. 2009;62:800-5.
30. Lee HJ, Pyon JK, Lim SY, Mun GH, Bang SI, Oh KS. Perforator-based bilobed flaps in patients with a sacral sore: Application of a schematic design. J Plast Reconstr Aesthet Surg. 2011;64:790-5.
31. Ninomiya R, Kishi K, Imanishi N, Nakajima H, Nakajima T. Reconstruction of vulva using pudendal thigh gluteal fold bilobed flap. J Plast Reconstr Aesthet Surg 2010;63:e130-2.

Acknowledgements

Figure 6 was provided by Michael Zaycosky, DO.