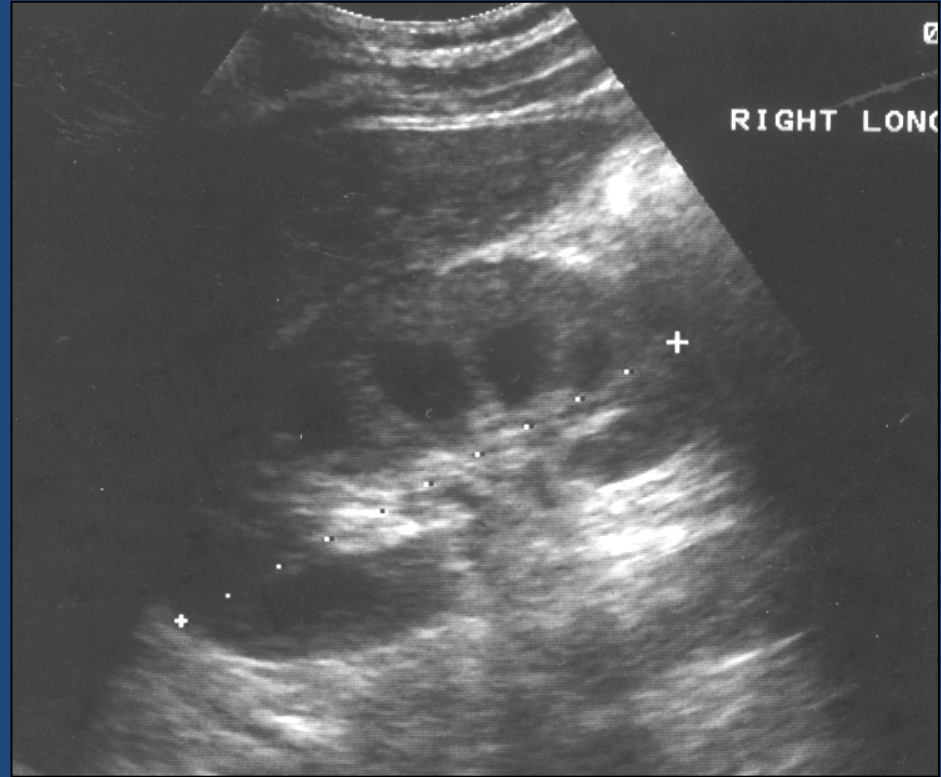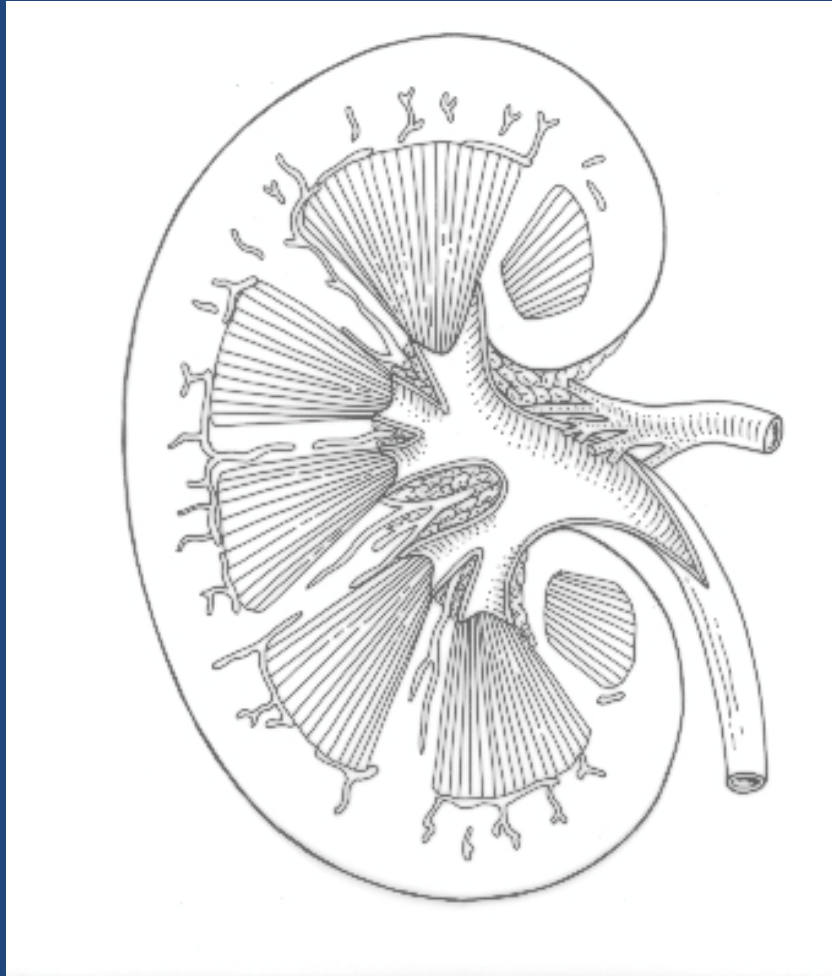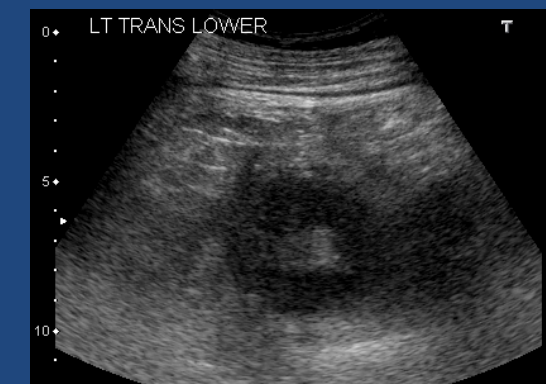
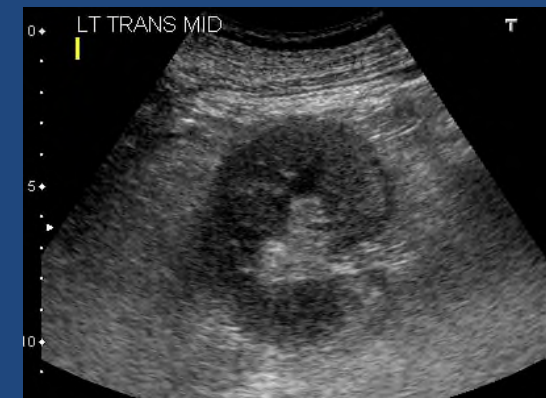
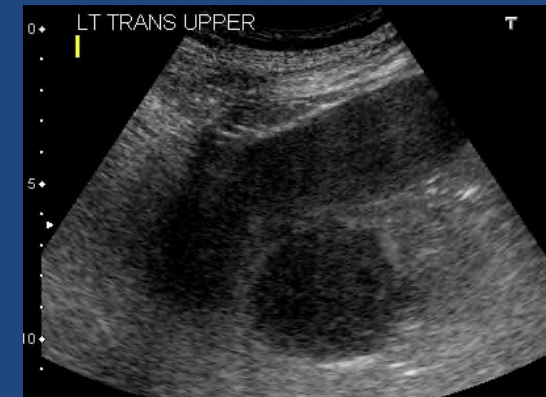
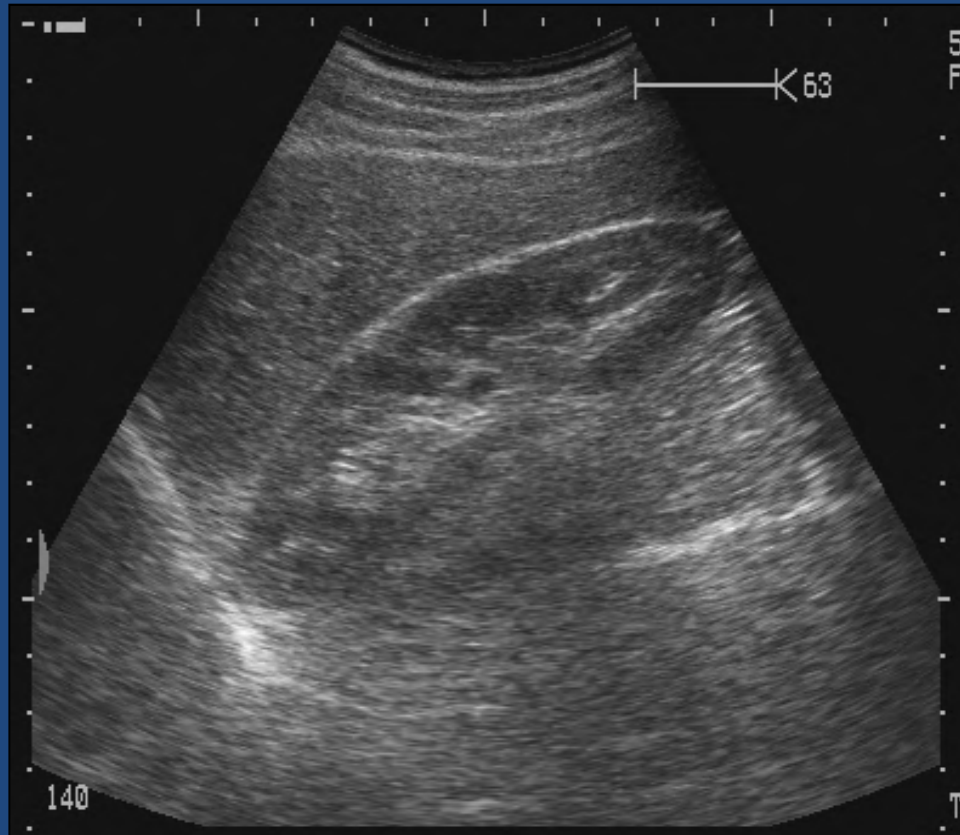


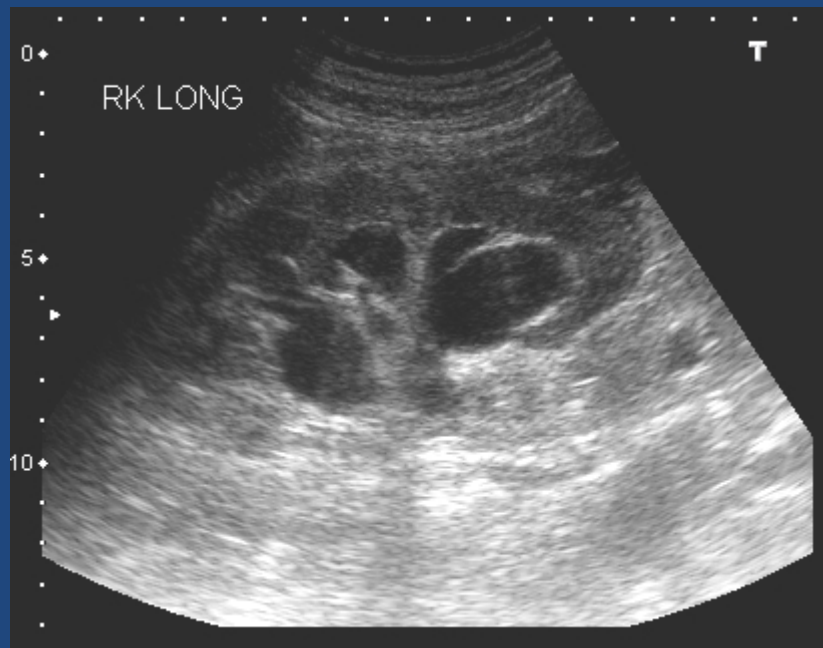Normal kidney

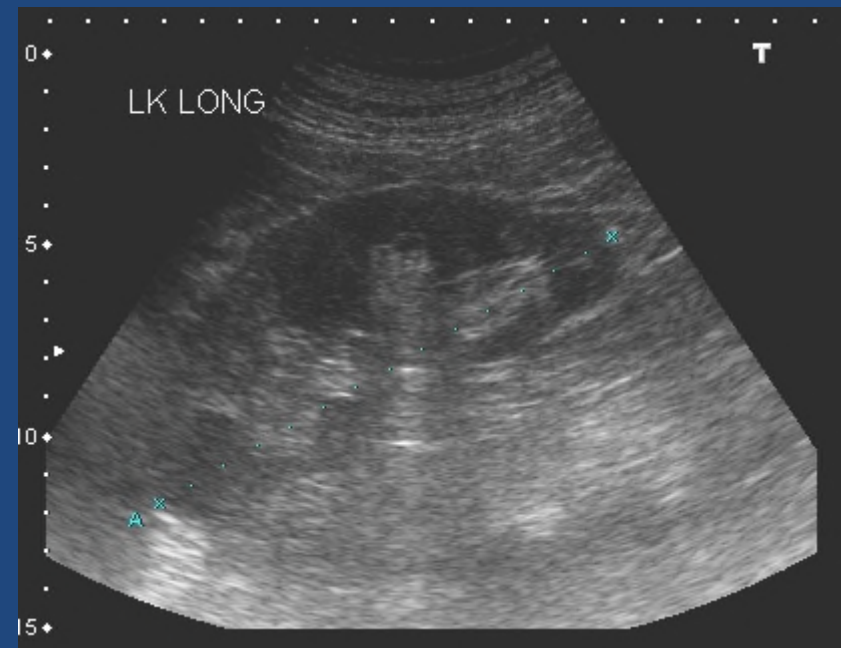


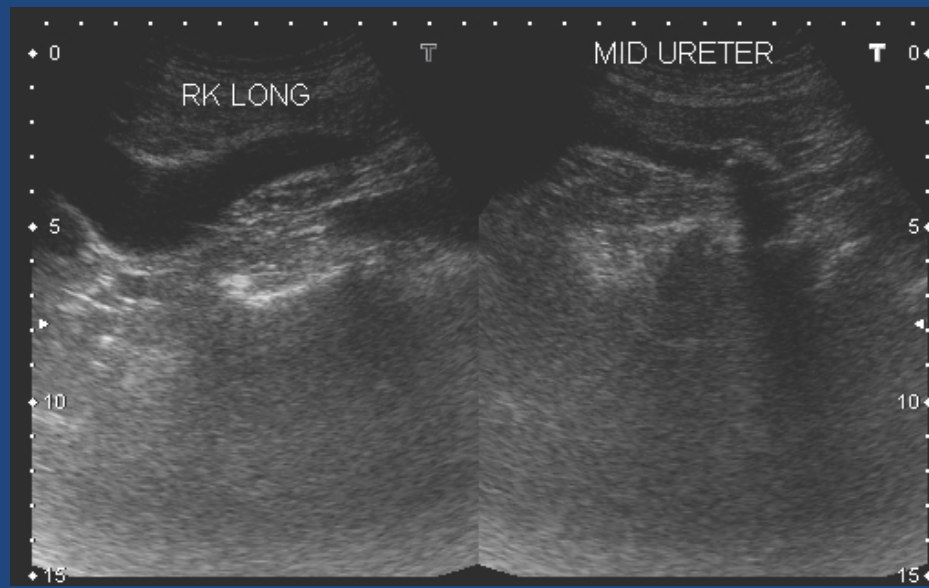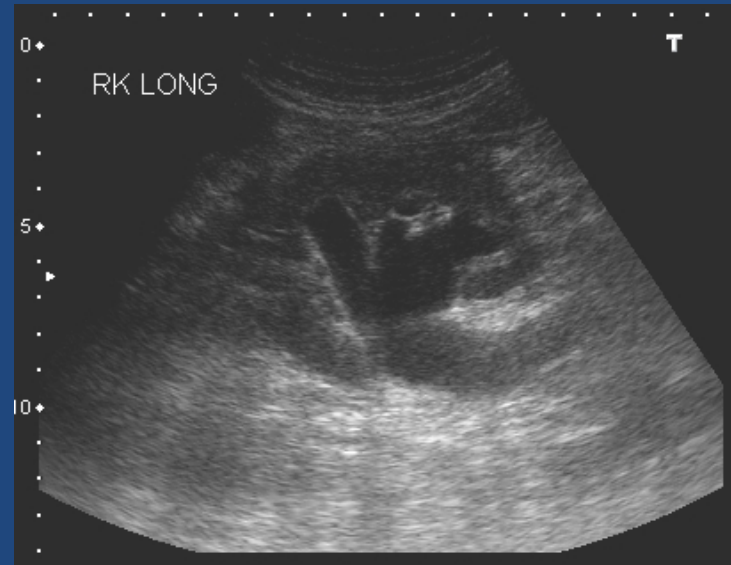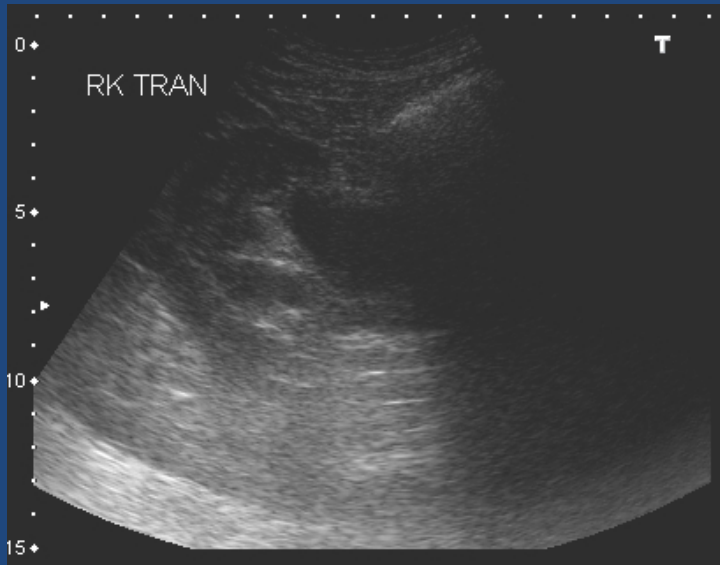
- 64 y.o male with chronic calcium nephrolithiasis; routine follow-up
- No symptoms ; urinalysis: cloudy, trace blood, negative LE
- Serum creatinine: 1.13

Right



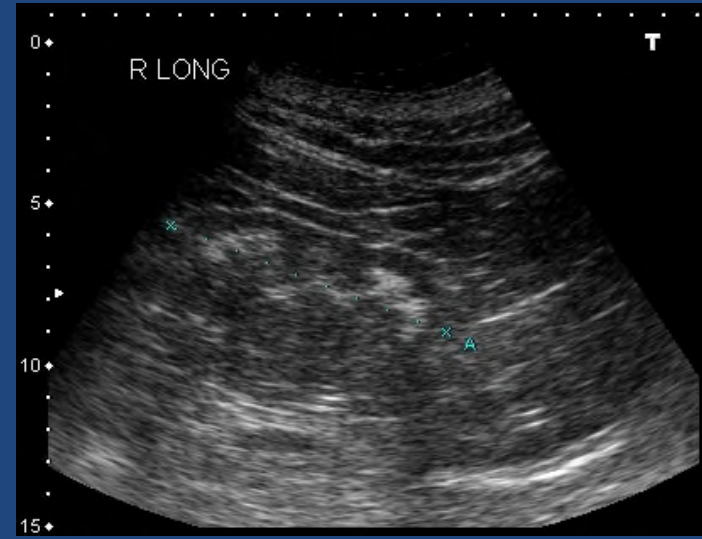
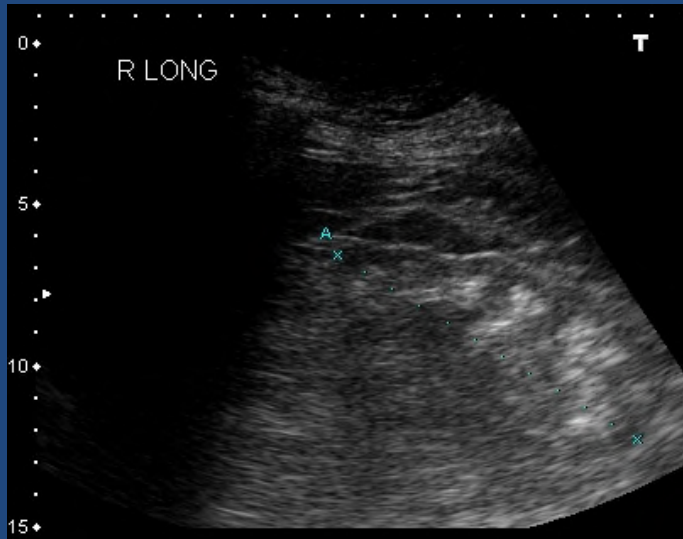
Left





- 58 y.o male with IgA nephropathy, obesity, diabetes, and severe gout
- Recent onset of hematuria without clots, pain, or fever
- Serum creatinine: 2.4

Right



Left

