PROCEEDINGS

2016 JOINT

AMERICAN ASSOCIATION OF ZOO VETERINARIANS (AAZV)

EUROPEAN ASSOCIATION OF ZOO AND WILDLIFE VETERINARIANS (EAZWV)

LEIBNIZ INSTITUTE FOR ZOO AND WILDLIFE RESEARCH (IZW)

CONFERENCE

Atlanta, Georgia
July 16-22, 2016

CHARLOTTE KIRK BAER
PROCEEDINGS EDITOR

CONTINUING EDUCATION

Continuing education sponsored by the American College of Zoological Medicine.



Continuing education credits provided by:

Wildlife Conservation Society provides the funding to the American College of Zoological Medicine to register as a certified CE provider for the state of New York. Attendees licensed in New York will receive CE credits for the AAZV 48th Annual Conference.



DISCLAIMER

The information appearing in this publication comes exclusively from the authors and contributors identified in each manuscript. The techniques and procedures presented reflect the individual knowledge, experience, and personal views of the authors and contributors. The information presented does not incorporate all known techniques and procedures and is not exclusive. Other procedures, techniques, and technology might also be available. Any questions or requests for additional information concerning any of the manuscripts should be addressed directly to the authors.

The sponsoring associations of this conference and resulting publication have not undertaken direct research or formal review to verify the information contained in this publication. Opinions expressed in this publication are those of the authors and contributors and do not necessarily reflect the views of the host associations. The associations are not responsible for errors or for opinions expressed in this publication. The host associations expressly disclaim any warranties or guarantees, expressed or implied, and shall not be liable for damages of any kind in connection with the material, information, techniques, or procedures set forth in this publication.

AMERICAN ASSOCIATION OF ZOO VETERINARIANS

"*Dedicated to wildlife health and conservation*"

581705 White Oak Road • Yulee, Florida, 32097 • 904-225-3275 • Fax 904-225-3289

Dear Friends and Colleagues,

It is with great pleasure and excitement that I welcome you to Atlanta, Georgia USA to the 48th AAZV Annual Conference and first joint conference with the European Association of Zoo and Wildlife Veterinarians (EAZWV) and the Leibniz Institute for Zoo and Wildlife Research (IZW). On behalf of AAZV I would like to extend a warm welcome to our European co-hosts and to all our international colleagues in attendance. Congratulations to the AAZV International Scholarship awardees and a very special welcome to our new members, first–time conference attendees, and students.

Our Scientific Program Committee, together with their EAZWV counterparts, has worked hard to prepare a dynamic and educational program that reflects current knowledge and methodologies across our global community. It was a bold step for EAZWV and IZW to hold their conference in the USA and I would like to acknowledge Stephanie Sanderson and Hanspeter Steinmetz from EAZWV and Alex Greenwood and Anke Schumann from IZW for facilitating this first-of-its kind conference. I would also like to acknowledge ACZM for providing continuing education credits for the conference.

Conference attendees will be treated to a double helping of southern hospitality from our hosting institutions, Zoo Atlanta and the Georgia Aquarium. Thanks to our hosts Hayley Murphy from Zoo Atlanta, Tonya Clauss from the Georgia Aquarium, and the staff and volunteers from both institutions for opening their facilities to us and making us feel welcome.

I applaud the hard work of our conference planning team, Rob Hilsenroth, Adine Nicholson, Kathy Nemaric, and Julie Fazlollah, as well as contributions from our student volunteers, who perennially insure the successful planning and implementation of our conference. The 2016 conference marks the 10th anniversary for our Executive Director Rob Hilsenroth, whose dedication, enthusiasm, and tireless advocacy has made a tremendous contribution to our organization's growth and success over the past decade.

Most importantly, I want to thank you the membership for your dedication to our profession and support of our organization. AAZV is a diverse and energetic organization because of your continued membership, contributions, and professional service. Our Wild Animal Health Fund and granting capacity continues to grow and the *Journal of Zoo and Wildlife Medicine* remains the premier source of scientific and clinical information for our field. In all that you do, AAZV members never fail to challenge and inspire me.

With respect and appreciation,

Kelly Helmick
President, American Association of Zoo Veterinarians

AMERICAN ASSOCIATION OF ZOO VETERINARIANS

"*Dedicated to wildlife health and conservation*"

581705 White Oak Road • Yulee, Florida, 32097 • 904-225-3275 • Fax 904-225-3289

Dear Colleagues and Friends,

On behalf of the Scientific Program Committee (SPC), I would like to welcome you to the 48th Annual Conference of the American Association of Zoo Veterinarians (AAZV) and the first ever joint conference of the AAZV and the European Association of Zoo and Wildlife Veterinarians (EAZWV) and the Leibniz Institute for Zoo and Wildlife Research (IZW). These organizations have worked hand in hand to build an outstanding conference for you this year. We thank our gracious hosts at Zoo Atlanta and Georgia Aquarium, including Hayley Murphy, Sam Rivera, Kate Leach and Tonya Clauss, for their tremendous help and hospitality.

Our conference program continues to evolve each year based on your feedback. Please let us know your thoughts and how we can continue to offer you the highest quality program and workshops. This year we built upon an "open call" for abstracts with particular emphasis on several topics. Our session chairs, including representatives from the AAZV, EAZWV and IZW, reviewed hundreds of abstracts to develop 15 scientific sessions that represent a diverse blend of taxa and discipline-based themes. We also have a number of advanced and special topics including contraception and infertility, emerging fungal diseases and gross lesion recognition. Based on overwhelming interest and positive feedback, we are continuing to offer a half-day leadership workshop at the end of the conference.

The main conference program will provide a maximum of 25.7 credit hours of continuing education, certified by the American College of Zoological Medicine. A maximum of 16 additional credit hours are available with two days of exciting and diverse workshops ranging from avian and turtle coelioscopy to current topics in chimpanzee medicine to behavioral conditioning and enrichment in aquatic species.

We would also like to gratefully acknowledge the expertise and tireless efforts of the office of the Executive Director, including Rob Hilsenroth, Adine Nicholson, Julie Fazlollah, and Kathy Nemaric for their support in making this year's conference a success.

Finally, welcome to Atlanta! We hope you have a wonderful time at the conference advancing your professional development and spending time with new and old friends. Remember to stay hydrated and wear sunscreen! We hope you return home energized about our meaningful profession and our contributions to animal health and conservation.

Best regards,



Deena Brenner, DVM, Dipl. ACZM
Chair, AAZV Scientific Program Committee
Senior Veterinarian, San Diego Zoo

European Association of Zoo and Wildlife Veterinarians

Dear friends and colleagues,

It is a great honor and pleasure to welcome you to the first joint Conference of the American Association of Zoo Veterinarians (AAZV), the Leibniz Institute for Zoo and Wildlife Research (IZW) and the European Association of Zoo and Wildlife Veterinarians (EAZWV) in Atlanta. The idea of this conference grew out of a long friendship among the organizations and the realization that cooperation, as in conservation, would benefit the welfare and health of wildlife. The coming days here in Atlanta are a great opportunity to exchange experiences and knowledge and build a network of old and new friendships around the globe. I am sure we will have a good time in Atlanta with hands-on workshops, great scientific presentations, colleagues from all over the world and networking opportunities during the conference and during the diverse social program. And in two years' time we will have the conference over in Europe in wonderful historic Prague, Czech Republic and we hope that you can all take the opportunity to visit your friends in Europe.

At this point I really would like to acknowledge the enthusiasm of many of our colleagues who helped to make this conference to become a reality either by dedicating their days off for reviewing articles, preparing their manuscripts and talks, or volunteering for other work in the conference organization. And they do all of this great work just for applause, a handshake or a smile. Please do not forget that all of this cannot be done without the dedication and enthusiasm for the welfare, health and conservation of wildlife. I am so proud to be a part of this community and hope we can continue to share our idealism and develop the knowledge of zoo and wildlife medicine as our teachers taught us. This conference is made for the conservation and welfare of wildlife by you, for you and for the future of our profession. Thank you and please enjoy your days in Atlanta to share your experience.

Sincerely,

Hanspeter W. Steinmetz
Vice-president EAZWV



Dear Friends and Colleagues,

On behalf of the Leibniz Institute for Zoo and Wildlife Research we welcome everyone to the first joint AAZV/IZW/EAZWV Conference in Atlanta. We are grateful to our local American hosts for having us over from across the pond. We hope everyone from all three organizations will use the opportunity to catch up with colleagues and also meet many new people and exchange ideas and useful information. We strongly feel that this joint meeting represents a unique opportunity to all involved to not only reach a wider audience for their own experiences but to expand their own horizons. We should explore the similarities in experience between Europe and the Americas but also benefit from the differences.

This year's Scientific Program Committee (SPC) reflects a mix of people from the three participating organizations who have worked tirelessly to bring you a diverse and exciting array of workshops, sessions, master classes and plenary speakers. The topics and speakers represent a wide range of specialties from all three participating organizations and beyond and we are confident everyone will draw new inspiration from what they hear and experience.

We thank Allison Tuttle, Deena Brenner, Susan Bartlett and the rest of the SPC members for their tireless efforts. We thank our counterpart organizers Stephanie Sanderson, Hanspeter Steinmetz from the EAZWV and Adine Nicholson, Kathy Numeric, and Rob Hilsenroth from the AAZV for making this joint meeting possible. From the IZW side, please extend special thanks to Anke Schumann, Gudrun Wibbelt and Steven Seet who have tirelessly organized the European meetings for years and have helped to organize the joint meeting in a similar capacity this year.

Sincerely,

Alex Greenwood
Head of the Department of Wildlife Diseases
Leibniz Institute for Zoo and Wildlife Research

American Association of Zoo Veterinarians
2016 Scientific Program Committee

SCIENTIFIC PROGRAM COMMITTEE CHAIR	Deena Brenner
SCIENTIFIC PROGRAM COMMITTEE CO-CHAIR	Susie Bartlett
AAZV PRESIDENT	Kelly Helmick
AAZV PRESIDENT-ELECT	Scott Larsen
AAZV VICE PRESIDENT	Mike Adkesson
PROGRAM CHAIR	Allison Tuttle
WORKSHOP CHAIR	Kristen Phair
WORKSHOP CO-CHAIR	Sam Rivera
EXOTIC ANIMAL MEDICINE FOR THE CLINICAL PRACTITIONER (EAMCP) CHAIR	Gwen Jankowski
2016 LOCAL HOST	*Zoo Atlanta* Hayley Murphy Sam Rivera Kate Leach *Georgia Aquarium* Tonya Clauss

CONTENTS

PROGRAM CHAIR: *Allison Tuttle*

KEYNOTE TOPIC: WILDLIFE FIELD TECHNIQUES
Clay Hilton and Martine van Zijll Langhout, Co-chairs

BEST PRACTICE GUIDELINES FOR FIELD-BASED SURGERY AND ANESTHESIA OF FREE-RANGING WILDLIFE
Sathya K. Chinnadurai, Christine V. Fiorello, Craig A. Harms, Danielle Strahl-Heldreth, and Daniel M. Mulcahy* 1

WILDLIFE FIELD TECHNIQUES
Clay Hilton and Martine van Zijll Langhout, Co-chairs

WRITING AND REVIEWING ANIMAL CARE AND USE PROTOCOLS FOR WILDLIFE RESEARCH: TIPS ON PLANNING FOR THE UNEXPECTED
Elizabeth A. Falendysz and Jennifer E. Brunner* 2

ON-THE-GO LABS: PORTABLE FIELD DIAGNOSTIC EQUIPMENT AND TECHNIQUES
Paul P. Calle, Bonnie L. Raphael, Denise McAloose, and Tracie A. Seimon* 4

HOW AND WHAT CAN WE—SHOULD WE—LEARN ABOUT WORKING WITH BIOLOGISTS?
Sonia M. Hernandez and Daniel M. Mulcahy* 6

HOW ARE WILDLIFE BIOLOGISTS TRAINED IN WILDLIFE HEALTH?
Jennifer C.G. Bloodgood and Sonia M. Hernandez* 7

ONE HEALTH
Pam Dennis and Alex Greenwood, Co-chairs

ONE HEALTH AND CONSERVATION MEDICINE ARE EVOLVING TO BUILD TRANSDISCIPLINARY COLLABORATIONS, INTEGRATIVE RESEARCH, AND LOCAL CAPACITY
A. Alonso Aguirre and Val Beasley* 8

PRACTICAL EXPERIENCES OF A NON-GOVERNMENTAL ORGANIZATION (NGO) IMPLEMENTING ONE HEALTH INITIATIVES IN THE ALBERTINE, ECOSYSTEM, HOIMA, UGANDA
Lawrence Mugisha, Travis Dominic, and Katey Pelican* 10

SEROEPIDEMIOLOGIC MONITORING IN SENTINEL ANIMALS AND HUMANS AS PART OF ARBOVIRUS SURVEILLANCE IN THE ATLANTIC FOREST OF BAHIA, BRAZIL
Lilian S. Catenacci, Sharon L. Deem, Milene S. Ferreira, Kristel M. De Vleeschouwer, Leonardo C. Oliveira, Camila R. Cassano, Gustavo Canale, Debora D. C. Fernandes, Livia C Martins, Juan S. Tello Patrcia Parker, Pedro F. Vasconcelos, and Elizabeth Salbe T. Rosa* 11

CLINICAL RELEVANCE OF NEWLY DEVELOPED *Chlamydia psittaci*-SPECIFIC ANTIBODY TESTS IN HUMANS AND ANIMALS SUSCEPTIBLE TO MULTIPLE *Chlamydia* spp.
*Denise Pesti, Christopher R. Gregory, and Branson W. Ritchie** 13

EFFECT OF ENVIRONMENTAL STRESS OF AN EL NIÑO EVENT ON ADENOVIRAL DIVERSITY IN MARINE ANIMAL ROOKERIES
Galaxia Cortes-Hinojosa, Michael J. Adkesson, Susana Cárdenas-Alayza, Mauricio Seguel, Héctor Pavés, and James F.X. Wellehan* 14

IS THERE EVIDENCE TO SUGGEST ELEPHANT-TO-ELEPHANT TRANSMISSION OF HUMAN TUBERCULOSIS?
David Abraham, T. Rajeev, and Jacob V. Cheeran* 16

REPTILES AND AMPHIBIANS
Matt Allender and Javier Lopez, Co-chairs

SUITABILITY OF THE ERYTHROCYTE MICRONUCLEUS TEST FOR ASSESSING GENOTOXICITY IN GREEN TURTLES (*Chelonia mydas*)
Cindy Braud, Leandro Abreu da Fonseca, Fabrícia M. Girardi, Fagundes Valeria, Girardi F.M., and Batistotte Cecilia* 18

ELECTROCARDIOGRAPHIC MONITORING IN SEMI-AQUATIC TURTLES USING SMARTPHONE EKG SOFTWARE (ALIVECOR®) AND COMPARISON TO CONVENTIONAL ELECTROCARDIOGRAPHY
Mariana Sosa, Adriana Ducoing, Luis Carrillo, Marco A. Benítez, Osvaldo Martínez, and Dulce María Brousset Hernández-Jauregui* 20

HEALTH EVALUATION, PATHOGEN SCREENING AND HEMATOLOGIC VALUES IN FREE-RANGING TEXAS HORNED LIZARDS (*Phrynosoma cornutum*)
Michael McEntire, Carlos R Sanchez, Ashley Pich, Martin Zordan, Diane Barber, Vicky Poole, Nathan Rains, Devin Erxleben, J. Jill Heatley, and Jim Wellehan* 22

Chlamydophila-ASSOCIATED ENCEPHALITIS IN A POPULATION OF HOUSTON TOADS (*Bufo houstonensis*): AN UPDATE ON THE OUTBREAK AND THE AMPHIBIAN NEUROLOGIC EXAM
Erin Berlin, Eric Snook, Fabiano Oliveira, Anibal G. Armien, Tyler Parker, Colin Thompson, Bernard Wolff, Paula Ciembor, Branson Ritchie, and Lauren L. Howard* 24

MINIMAL INVASIVE HEART SURGERY IN ANURANS
Norin Chai, Céline Vivien, Valérie Chetboul, and Laurent Coen* 25

ARE OPIOIDS EFFECTIVE ANALGESICS IN SNAKES? FENTANYL EFFICACY, PHARMACOKINETICS, AND MU-OPIOID RECEPTOR MRNA EXPRESSION IN BALL PYTHONS (*Python regius*)
Kurt K. Sladky, Rima Kharbush, Kate Hartzler, Rebecca Kimyon, Sherry Cox, Jyoti Watters, Andrew Abbott, and Stephen M. Johnson.* 26

ANALGESIC EFFICACY OF TRAMADOL AND MORPHINE IN WHITE'S TREE FROGS (*Litoria caerulea*)
Jennifer C. Hausmann, Ashley Krisp, Stephen Johnson, and Kurt Sladky* 27

TRANSPORT AND TRANSBOUNDARY DISEASES
Sonia Hernandez and Christian Wenker, Co-chairs

WILD AFRICAN ELEPHANT (*Loxodonta africana*) SEMEN ACROSS BORDERS: WHEN SANITARY REQUIREMENTS AND LEGAL COMPLIANCE CHALLENGE A GROUND-BREAKING PROJECT
Romain Potier, Paul Bartels, Frank Goeritz, Robert Hermes, Barbara Baker, and Thomas Hildebrandt* 29

AN OUTBREAK OF GOAT POX VIRUS IN NONDOMESTIC HOOFSTOCK AT AL WABRA WILDLIFE PRESERVATION
Wouter Pieters, Francois Le Grange, Abdi Arif, Cromwell Purchase, Elizabeth du Plessis, Almero Oosthuizen, and Essa Suleman* 31

SPECIAL TOPIC: IMPORTATION OF NONHUMAN PRIMATES
Geoff Pye, Chair

CENTERS FOR DISEASE CONTROL AND PREVENTION (CDC) REGULATIONS FOR IMPORTING NONHUMAN PRIMATES INTO THE UNITED STATES
G. Gale Galland 32

KEYNOTE TOPIC: ELEPHANT ENDOTHELIOTROPIC HERPESVIRUS
Lauren Howard and Thomas Hildebrandt, Co-chairs

ELEPHANT ENDOTHELIOTROPIC HERPESVIRUS (EEHV): A ZOO CLINICIAN'S SURVIVAL GUIDE
Lauren L. Howard 34

ELEPHANT ENDOTHELIOTROPIC HERPESVIRUS
Lauren Howard and Thomas Hildebrandt, Co-chairs

THE IMPACT OF ELEPHANT ENDOTHELIOTROPIC HERPESVIRUS ON THE CAPTIVE ASIAN ELEPHANT (*Elephas maximus*) POPULATION OF THE UNITED KINGDOM AND IRELAND (1995-2013)
Rebecca Kendall, Lauren Howard, Nic Masters, and Robyn Grant* 39

NEW QUANTITATIVE POLYMERASE CHAIN REACTION ASSAYS TO DETECT ELEPHANT ENDOTHELIOTROPIC HERPESVIRUS 1A, 1B, AND 4 IN ASIAN ELEPHANTS (*Elephas maximus*)
Taylor A. Pursell, Angela Fuery, Jie Tan, Lauren Howard, and Paul D. Ling* 41

CORRELATION BETWEEN SERUM AND URINARY CORTISOL LEVELS AND SHEDDING OF ELEPHANT ENDOTHELIOTROPIC HERPESVIRUS (EEHV) 1,3,4 AND 5 IN CALVES AND ADULT ASIAN ELEPHANTS (*Elephas maximus*) PRE- AND POST-ARRIVAL OF A NEW BULL ELEPHANT
Carlos R Sanchez, Tarren Wagener, Don Nevitt, Erin Latimer, and Janine Brown* 43

DEVELOPMENT OF FREEZE-DRIED PLATELET-DERIVED HEMOSTATIC AGENTS AS A NOVEL TREATMENT FOR ELEPHANT ENDOTHELIOTROPIC HERPESVIRUS HEMORRHAGIC DISEASE
Suzan Murray, Sabrina McGraw, Dennis Schmitt, Tim Walsh, Lauren Howard, Carlos Sanchez, and Erin Latimer* 45

SPECIAL TOPIC: CONTRACEPTION AND INFERTILITY
Sharon Deem and Robert Hermes, Co-chairs

REPRODUCTIVE MANAGEMENT: APPROACHES TO CHOOSING CONTRACEPTIVES AND DIAGNOSING INFERTILITY
Mary Agnew, Yedra Feltrer, Dalen Agnew, Bruce Christensen, Linda Penfold, and Anneke Moresco* 47

REPRODUCTION
Sharon Deem and Robert Hermes, Co-chairs

PROGRESS IN UNDERSTANDING REPRODUCTIVE DISEASE IN SOUTHERN STINGRAYS (*Dasyatis americana*)
Natalie D. Mylniczenko, Jennifer Wyffels, and Linda M. Penfold* 50

ULTRASONOGRAPHY AND ENDOSCOPY AS A METHOD OF ASSESSING EMBRYO DEVELOPMENT IN EGGS OF PORT JACKSON SHARKS (*Heterodontus portusjacksoni*)
Nuno Pereira, Hugo David, Ana Jarego, Patrícia Rocha, Ana Ferreira, and Elsa Santos* 51

CHEMICAL CASTRATION AND AGGRESSION CONTROL IN IMPALA (*Aepyceros melampus*) USING ZEUTERIN™
*Deidre K. Fontenot*and Linda M Penfold* 53

AVIAN MEDICINE
Joanne Paul-Murphy and Francis Vercammen, Co-chairs

THINK PINK: COMBINING CULINARY AND VETERINARY EXPERIENCES FOR SUCCESSFUL CHILEAN FLAMINGO (*Phoenicopterus chilensis*) HAND-REARING EFFORTS
Kathryn C. Gamble and Sunny Nelson* 54

EFFECT OF ROUTINE HANDLING AND TRANSPORTATION ON HEMATOLOGIC VALUES AND PLASMA CORTICOSTERONE IN HISPANIOLAN AMAZON PARROTS (*Amazona ventralis*)
Anna McRee Thomas N. Tully, Javier G. Nevarez, Hugues Beaufrere, Melanie Ammersbach, Stephen D. Gaunt, Rory G. Fuller, and Michael Romero* 56

STRESS INFLUENCE ON PLASMA PROTEIN ELECTROPHORESIS IN TWO ANSERIFORM SPECIES
Antoine Leclerc, Baptiste Mulot, Alice Brunet, and Yannick Roman* 57

TREATMENT OF SECONDARY BRODIFACOUM TOXICOSIS IN A CAPTIVE ANDEAN CONDOR (*Vultur gryphus*)
Kira Hydock, Camille DeClementi, and Pilar Fish* 59

DEVELOPMENT OF A qPCR FOR *Atoxoplasma* DIAGNOSIS IN PASSERINE BIRDS
Jennifer A. Landolfi, Michael Adkesson, Timothy Snyder, and Karen A. Terio* 61

RETROSPECTIVE STUDY OF PROVENTRICULAR ACUARIID SPIRURIDIASIS IN CAPTIVE PSITTACINE BIRDS WITH PROLIFERATIVE PROVENTRICULAR DISEASE
Carles Juan-Sallés, Michael M. Garner, Nuhacet Fernández, Andrés Montesinos, Jorge Rosell, Mikel Sabater, María Ardiaca, and Chris H. Gardiner* 62

OUTCOME OF TIBIOTARSAL FRACTURES IN SMALL BIRDS: 87 CASES FROM FIVE INSTITUTIONS
Louden Wright, Christoph Mans, Grayson Doss, Geoff Olsen, Brian Speer, Gerd Britsch, J. Jill Heatley, Jane Christman, and Michael Jones* 64

USE OF ORTHOTICS AND PROSTHETICS FOR DISTAL LIMB INJURIES IN WATERFOWL
Laura M. Kleinschmidt, Virginia Ellsworth, and Sharman M. Hoppes* 65

BEHAVIOR
Sathya Chinnadurai and Mads Bertelsen, Co-chairs

A SYSTEMATIC APPROACH TO BEHAVIOR CASES: THE KEY TO THE RIGHT DIAGNOSIS—CLINICAL CASES
Marion Desmarchelier, Shannon T. Ferrell, and Diane Frank* 67

SEMIOCHEMICALS AND THEIR POTENTIAL APPLICATIONS IN ZOO ANIMAL HOUSING AND WELFARE
Valarie V. Tynes 70

CASE REPORT: PHEROMONE THERAPY WITH FELINE FACIAL PHEROMONE FRACTION F3 (FFP) AS AN ALTERNATIVE THERAPEUTIC FOR PSYCHOGENIC DERMATITIS IN FIVE MARGAY (*Leopardus wiedii*) AT SOROCABA ZOO IN SÃO PAULO, BRAZIL
Hanna S. Kokubun, André L.M.Costa, Vanessa L. Ribeiro, Henrique G. Riva, and Rodrigo H.F.Teixeira* 72

LONG-TERM ADMINISTRATION OF HALOPERIDOL IN AN AFRICAN ELEPHANT (*Loxodonta africana*), SUPPPORTING THE THERAPY OF SELF-DESTRUCTIVE STEREOTYPIC BEHAVIOR
Endre Á. Papp and László Garamvölgyi* 74

AQUATIC ANIMAL MEDICINE
Tonya Clauss and Eva Martinez, Co-chairs

SERUM AMYLOID A: AN INFLAMMATORY MARKER OF *Otostrongylus* INFECTION IN JUVENILE NORTHERN ELEPHANT SEALS (*Mirounga angustirostris*) IN CENTRAL CALIFORNIA
Julie D. Sheldon, Shawn P. Johnson, Jorge Hernandez, Carolyn Cray, and Nicole I. Stacy* 76

COELOMIC FLUID ANALYSIS OF TWO SEA STAR GENERA*:* A COMPARISON OF HEALTHY SEA STARS AND THOSE AFFECTED BY SEA STAR WASTING DISEASE
Sarah J. Wahlstrom, Lesanna L. Lahner, Nicole Stacy, and Alisa L. Newton* 78

HEALTH MONITORING IN FLORIDA MANATEES (*Trichechus manatus latirostris*) VIA LIVE CAPTURE HEALTH ASSESSMENTS: LESSONS LEARNED AND ENHANCING STRATEGIES TO MONITOR POPULATION HEALTH IN THE FUTURE
Martine de Wit, Michael T. Walsh, Nicole I. Stacy, and Robert K. Bonde* 80

COMPARISON OF DIETARY AND ENVIRONMENTAL IODINE EFFECTS ON THYROID PROTEIN LEVELS IN CAPTIVE WHITE-SPOTTED BAMBOO SHARKS (*Chyloscyllium plagiosum*)
Lily Parkinson, Kurt Sladky, and Terry Campbell* 82

RESPONSE TO THE DIAGNOSIS OF TUBERCULOSIS (*Mycobacterium pinnipedii*) IN A COLONY OF CAPTIVE PINNIPEDS IN NEW ZEALAND
James Chatterton, An Pas, Sarah A. Alexander, Richard Jakob-Hoff, Cathy Harvey, and Wendi Roe* 84

DETERMINING TOTAL HEMOCYTE COUNTS AND HEMOLYMPH CLINICAL CHEMISTRY PROFILES FOR FREE-RANGING AMERICAN HORSESHOE CRABS (*Limulus polyphemus*)
Jill E. Arnold, Leigh Ann Clayton, Catherine A. Hadfield, and Carolyn Cray* 85

ESTABLISHING THE COAGULATION PROFILE OF THE FLORIDA MANATEE (*Trichechus manatus latirostris*) AND IDENTIFYING COAGULOPATHIES IN THE PATHOPHYSIOLOGY OF COLD STRESS SYNDROME
Ashley Barratclough, Bobbi Conner, Roger L. Reep, Ray L. Ball, and Ruth Francis Floyd* 87

Proteus anguinus IN CROATIA: WHAT WE HAVE LEARNED
Maja Lukac, Ivan Cizelj, Susanne Holtze, Dusan Jelic, Frank Mutschmann, Danijela Horvatek Tomic, Estella Prukner-Radovcic, Zeljko Gottstein, Ivan Rychlik, Petra Videnska, and Thomas B. Hildebrandt* 89

REMOTE IMMOBILIZATION OF ENTANGLED CALIFORNIA SEA LIONS (*Zalophus californianus*) USING AN ACOUSTIC TRANSMITTER TRACKING SYSTEM
Cara L. Field, Greg Frankfurter, Eugene DeRango, and Shawn Johnson* 90

CARNIVORES
Paul Calle and Maya Kummrow, Co-chairs

KNUT THE POLAR BEAR (*Ursus maritimus*) SUFFERED FROM AUTOIMMUNE ENCEPHALITIS: A NEW DISEASE OF WILDLIFE
*Harald Prüß, Jonas Leubner, Nina K. Wenke, Gabor Á. Czirják, Claudia A. Szentiks, and Alex D. Greenwood** 91

INVESTIGATING CARDIOVASCULAR DISEASE IN BILE-FARMED ASIATIC BLACK BEARS (*Ursus thibetanus*) IN CHINA: COMPARISONS WITH FREE-RANGING ASIATIC BLACK BEARS IN JAPAN (*Ursus thibetanus japonicas*)
Monica K. H. Bando, O. Lynne Nelson, Chris Linney, Hannah Stephenson, Koji Yamazaki, Claudia Hartley, David Donaldson, Mandala Hunter-Ishikawa, and Wendy Leadbeater* 93

SCREENING OF BANDED MONGOOSES (*Mungos mungo*) IN THE KRUGER NATIONAL PARK, SOUTH AFRICA, FOR *Mycobacterium bovis* INFECTION
Angela C. Brüns, Manfred Tanner, Mark C. Williams, Louise Botha, Amanda O'Brien, Geoffrey T. Fosgate, Paul D. Van Helden, John Clarke, and Anita L. Michel* 95

EMERGING INFECTIOUS DISEASE
Maja Rütten and Kirsten Gilardi, Co-chairs

TUBERCULOSIS IN A CLOSED POPULATION OF VERVET MONKEYS (*Chlorocebus pygerythus*): IMMUNODIAGNOSTICS AND PATHOLOGY
Martine van Zijll Langhout, Emily Lane, Steve Unwin, and Anita L. Michel* 97

TUBERCULOSIS IN UNDER-RECOGNIZED SPECIES: IS THIS AN EMERGING DISEASE THREAT?
Michele Miller, Peter Buss, Chris Foggin, Lin-Mari de Klerk-Lorist, Paul van Helden, and Sven Parsons* 99

BABESIOSIS *(Babesia odocoilei*): AN EMERGING DISEASE OF ONTARIO CERVIDS
Adriana R. Pastor, Adriana M.W. Nielsen, Doran W. Kirkbright, Amélie Mathieu, Graham Crawshaw, Simon Hollamby, and Dale A. Smith* 101

Babesia capreoli INFECTION IN CAPTIVE REINDEER (*Rangifer tarandus tarandus*) IN OUWEHAND ZOO, THE NETHERLANDS
Jan H. Bos, Fokko C. Klip, Hein Sprong, Els M. Broens, and Marja J.L. Kik* 103

EVALUATION OF A COMMERCIAL ELISA FOR DETECTION OF AVIAN INFLUENZA VIRUS SUBTYPE H5 ANTIBODIES IN 31 AVIAN SPECIES
Trine H. Jensen, Mads F. Bertelsen, Charlotte K. Hjulsager, Mariann Chriél and Jannie H. Andersen* 105

Angiostrongylus cantonensis IN A ZOOLIGICAL COLLECTION IN FLORIDA WITH AN ANTEMORTEM DIAGNOSIS AND SUCCESSFUL TREATMENT IN A WHITE-THROATED CAPUCHIN MONKEY (*Cebus capucinus*)
Justin F. Rosenberg, Heather S. Walden, Marjorie Bercier, Kathy Russell, and James F. X. Wellehan.* 107

CYTOLOGIC CHARACTERIZATION OF MYELODYSPLASIA IN RETROVIRAL-INFECTED KOALAS (*Phascolarctos cinereus*)
Nicole I. Stacy, Bruce Rideout, John W. Harvey, Geoffrey W. Pye, Amber Gillett, Christine L. Miller, and Michael M. Garner* 109

Bacillus cereus biovar *anthracis* KILLS ENDANGERED WILDLIFE IN CENTRAL AFRICAN REPUBLIC
Kim Grützmacher, Fee Zimmermann, Constanze Hoffmann, Susann Dupke, Tianna Peller, Anna Feistner, Angelique Todd, Ilka Herbinger, Roland Grunow, Sébastien Calvignac-Spencer, Silke R. Klee, and Fabian H. Leendertz* 111

ELEPHANTS AND RHINOCEROS
Gretchen Cole and Endre Sos, Co-chairs

BRONCHOALVEOLAR LAVAGE TECHNIQUE: A NEW APPROACH FOR DIAGNOSIS OF TUBERCULOSIS INFECTION IN ELEPHANTS
Thomas B. Hildebrandt, Joseph Saragusty, Irmgard Moser, Susanne Holtze, Thomas Voracek, Andreas Bernhard, Tim Bouts, Frank Göritz, and Robert Hermes* 113

TO BE OR NOT TB: DIAGNOSIS OF TUBERCULOSIS IN A GROUP OF ASIAN ELEPHANTS (*Elephas maximus*)
Hanspeter Steinmetz and Maja Rütten* 115

THROMBOELASTOGRAPHY IN THE ASIAN ELEPHANT (*Elephas maximus*)
Kathryn L. Perrin, Annemarie T. Kristensen, Anne H. Krogh, Louise Bochsen, Wendy K. Kiso, Dennis Schmitt, Lauren Howard, and Mads F. Bertelsen* 117

A COMPARISON OF OXIDATIVE STRESS MARKERS AND ANTIOXIDANT STATUS IN TWO SPECIES OF RHINOCEROS, *Diceros bicornis* AND *Ceratotherium simum*
Daniel V. Fredholm, Justin W. Shmalberg, Karen C. Scott, and Natalie D. Mylniczenko* 118

SPERM QUALITY OF WILD AFRICAN ELEPHANT BULLS: WHAT CAN BODY AND ULTRASOUND MEASUREMENTS TELL US?
Frank Goeritz, Joseph Saragusty, Robert Hermes, Romain Potier, Paul Bartels, Barbara Baker, and Thomas B. Hildebrandt* 120

TWENTY YEARS OF EXPERIENCE REHABILITATING ORPHANED ASIAN ELEPHANT (*Elephas maximus*) CALVES IN SRI LANKA
B. Vijitha Perera, Suhada Jayawardena, Neshma Kumudini, and Tharaka Prasad* 122

CARDIOPULMONARY EFFECTS OF ETORPHINE IN IMMOBILIZED WHITE RHINOCEROS (*Ceratotherium simum*) AND SUBSEQUENT INTRAVENOUS ADMINISTRATION OF BUTORPHANOL
Peter Buss, Michele Miller, Andrea Fuller, Anna Haw, Rachel Wanty, Francisco Olea-Popelka, and Leith Meyer* 123

SUCCESSFUL TREATMENT OF DIGITAL OSTEITIS AND ARTHRITIS BY INTRAVENOUS REGIONAL PERFUSION OF CEFTIOFUR IN AN AFRICAN ELEPHANT (*Loxodonta africana*)
Christopher J. Dutton, Pauline G. Delnatte, Simon R. Hollamby, and Graham J. Crawshaw* 125

MEDICAL MANAGEMENT AND INTENSIVE CARE IN A NORTHERN WHITE RHINOCEROS (*Ceratotherium simum cottoni*)
Meredith M. Clancy, Katie W. Delk, Jim Oosterhuis, Allan Pessier, and Nadine Lamberski* 126

HERBIVORES
Julie Napier and William Magnone, Co-chairs

EVALUATION OF NONINVASIVE OSCILLOMETRIC BLOOD PRESSURE MONITORING IN ANESTHETIZED BENNETT'S WALLABIES (*Macropus rufogriseus*)
Megan K. Watson, Ashley Mitek, and Sathya K. Chinnadurai* 128

ADDAX ANTELOPE (*Addax nasomaculatus*) DIGESTIVE TRACT REACTION TO A CONCENTRATE OR FORAGE FEEDING REGIME
Stamatios A. Tahas, Udo Hetzel, Olga Martin Jurado, Sven Hammer, Jean-Michel Hatt, and Marcus Clauss* 129

A WAKE-UP CALL: RADIOGRAPHIC EVIDENCE OF FRONT FOOT FRACTURES AND OSTEOARTHRITIS IN RELATIVELY YOUNG RETICULATED GIRAFFE (*Giraffa camelopardalis reticulata*)
Liza Dadone, Francisco Olea-Popelka, Eliza Stout, Eric Klaphake, Matthew S. Johnson, and Myra Barrett* 130

IMMOBILIZING MUSK OX (*Ovibos moschatus*) IN HIGH ARCTIC CONDITIONS
Carsten Grøndahl, Emilie Andersen-Ranberg, Jesper Bruun Mosbacher, Mikkel Stelvig, Lars Holst Hansen, and Niels Martin Schmidt* 131

TIPS, TRICKS, AND CASE REPORTS
Karen Kearns and Norin Chai, Co-chairs

PARASITIC INFECTIONS DETECTED BY FLOTAC IN ZOO MAMMALS: INSIGHTS FROM THE FIELD
Michele Capasso, Emilio Noviello, Dario D'Ovidio, Laura Rinaldi, and Giuseppe Cringoli* 133

Cryptococcus neoformans var. *grubii*-ASSOCIATED RENAL AMYLOIDOSIS CAUSING PROTEIN-LOSING NEPHROPATHY IN A RED KANGAROO (*Macropus rufus*)
Mary Irene Thurber, Jenessa Gjeltema, Matthew Sheley, and Ray F. Wack* 135

FAILURE OF PASSIVE TRANSFER AND LEUKOPENIA IN FIVE RETICULATED GIRAFFE CALVES (*Giraffa camelopardalis reticulata*)
S. Emmanuelle Knafo, Margaret Underwood, and Daniela Bedenice* 137

SQUAMOUS CELL CARCINOMA IN SNOW LEOPARDS (*Uncia uncia*): OUTCOME AND HISTOLOGY OF TWO CASE REPORTS OF UNUSUAL AURICULAR PRESENTATION
Benoît Quintard, Eva Greunz, Antoine Leclerc, Brice Lefaux, and Karin Lemberger* 138

CORRECTION OF SEVERE BILATERAL CARPUS VALGUS IN TWO JUVENILE CHEETAHS (*Acinonyx jubatus*) FOLLOWING STAGGERED BILATERAL ULNAR OSTECTOMY INCORPORATING OMENTAL FAT GRAFT
Conor P. Kilgallon 140

QUALITY-OF-LIFE EVALUATION AND MONITORING AS A TOOL IN THE HUMANE CARE OF A CAPTIVE RIVER OTTER (*Lontra canadensis*) WITH DILATED CARDIOMYOPATHY
Kelly E. Helmick, Allison Barr, Amy Brandt, and Deanna DeBo* 141

NOVEL COMBINED ENDOSURGICAL AND SYSTEMIC THERAPEUTIC APPROACH TO AN ALMOST COMPLETELY OBSTRUCTIVE INTRALUMINAL ZYGOMICETAL TRACHEAL MASS IN A BOTTLENOSE DOLPHIN (*Tursiops truncatus*)
Daniel García-Párraga, Enrique Cases, Teresa Álvaro, Mónica Valls, and Andreas Fahlman* 142

CASE SERIES OF CLOACITIS IN KĀKĀPŌ (*Strigops habroptila*)
Joanne Paul-Murphy, Richard Jakob-Hoff, Daryl Eason, James Chatterton, An Pas, Andrew Digby, Bethany Jackson, Cathy Harvey, and Brett Gartrell* 143

ANESTHESIA AND SURGERY IN AN ELECTRIC EEL (*Electrophorus electricus*) PRESENTING WITH A PERFORATING GASTRIC FOREIGN BODY
Sandra Wenger, Fabia Wyss, and Jean-Michel Hatt* 145

VETERINARY OUTREACH AND BIG PICTURE TOPICS
Natalie Mylizcenko and Christian Walzer, Co-chairs

AN ALGORITHM FOR RISK-BASED MANAGEMENT OF THE TRANSFER OF ANIMALS BETWEEN ZOOS AND AQUARIUMS
Geoffrey W. Pye 146

DATA SHARING, DATA MINING AND GLOBAL INFORMATION RESOURCES
J. Andrew Teare and Rachel Thompson* 148

MESHING REHABILITATION, EDUCATION, AND RESEARCH: THE JEKYLL ISLAND DIAMONDBACK TERRAPIN (*Malaclemys terrapin*) MODEL
Terry M. Norton Michelle Kaylor, Kimberly Andrews, John C. Maerz, and Brian A. Crawford* 153

WORKING WITH, INSTEAD OF AGAINST, THE U.S. DEPARTMENT OF AGRICULTURE'S ANIMAL AND PLANT HEALTH INSPECTION SERVICE: TIPS FOR DEVELOPING A SOLID WORKING RELATIONSHIP
Wm. Kirk Suedmeyer 155

BRINGING ARTISTS AND SCIENTISTS TOGETHER TO FOSTER SUSTAINED AND INFORMED SUPPORT FOR ANIMAL CONSERVATION
Lucy H. Spelman 157

PRIMATES
Kathryn Gamble and Baptiste Mulot, Co-chairs

HIGH MORTALITY DUE TO STREPTOCOCCAL TOXIC SHOCK SYNDROME IN A CAPTIVE COLONY OF LION-TAILED MACAQUES (*Macaca silenus*)
Maya S. Kummrow and Kerstin Mätz-Rensing* 159

TRANSCUTANEOUS ULTRASOUND EVALUATION OF KIDNEY AND ADRENAL GLAND SIZE IN HEALTHY CALLIMICOS (*Callimico goeldii*) AND COMPARISON WITH MEASUREMENTS USING COMPUTED TOMOGRAPHY
James G. Johnson III, Jennifer N. Langan, Sathya K. Chinnadurai, Randi Drees, Mark Warneke, and Matthew C. Allender* 161

BLOOD PRODUCT TRANSFUSIONS IN GREAT APES: RETROSPECTIVE REVIEW OF 11 CASES
A. Hahn, G. Sturgeon, and J. Rossi* 163

ADVANCED TOPIC: FUNGAL EMERGING DISEASES
Chris Cornelison, Chair

MANAGING EMERGING FUNGAL INFECTIONS IN WILDLIFE AND AGRICULTURE: DEVELOPING NOVEL TOOLS TO CONTROL NOVEL PATHOGENS
Christopher T. Cornelison, Sybill Amelon, Sarah Hooper, Kyle Gabriel, Courtney Barlament, Sid Crow, and George Pierce* 165

ADVANCED TOPIC: GROSS RECOGNITION OF LESIONS
Michael Garner, Chair

GROSS LESION RECOGNITION IN ZOO REPTILES
Michael M. Garner 167

POSTERS
Trevor Zachariah, Adrienne Atkins, Annette Liesegang, Jen Langan, Mads Bertelsen, Co-chairs

AQUATIC ANIMAL MEDICINE

HEALTH ASSESSMENT IN FREE ROAMING CETACEANS: DETERMINING BASELINE LEVELS FOR CYTOKINE EXPRESSION IN COMMON DOLPHINS
Carolina Bento, Pedro Verdelho, Catarina Eira, José Vingada, Marisa Ferreira, Luís Tavares, and Ana Duarte* 168

Pseudomonas aeruginosa DERMATITIS IN A CARIBBEAN WHIPTAIL STINGRAY (*Himantura schmardae*)
Erick O. Bernal, Sac-Nictec Y. Franco, and Josue Garduno* 170

AN INVESTIGATION INTO FACTORS AFFECTING THE AMOUNT OF LEAKAGE FROM INTRAMUSCULAR INJECTIONS IN FISH
Iain Cope and Becca Powell* 171

TRENDS OF THE FLORIDA MANATEE (*Trichechus manatus* ssp. *latirostris*) REHABILITATION EFFORTS AT TAMPA'S LOWRY PARK ZOO
Kelleen Johnson and Ray Ball* 172

CHALLENGES OF MEDICAL THERAPY IN THE TREATMENT OF CORNEAL ABSCESS IN A SUBANTARCTIC FUR SEAL (*Arctocephalus tropicalis*)
Laura C. Reisfeld Paloma C. Henrique, and Carmen M.H. Colitz* 173

EVALUATION OF FACTORS IMPACTING SERUM CORTISOL CONCENTRATIONS IN ATLANTIC BOTTLENOSE DOLPHINS (*Tursiops truncatus*) AT THE NATIONAL AQUARIUM
Estelle Rousselet, Catherine A. Hadfield, Leigh Ann Clayton, and Allison C. Ginsburg* 175

VETERINARY ASPECTS OF TRANSPORT AND REINTRODUCTION OF ANTILLEAN MANATEES (*Trichechus manatus manatus*) IN THE GRAND CUL-DE-SAC BAY IN GUADELOUPE, FRENCH LESSER ANTILLES
Natalia M. Rozniewska, Jolt Evva, Ray L. Ball, and Sébastien Rives* 177

AVIAN MEDICINE

SURGICAL MANAGEMENT OF CERVICAL AIR SAC RUPTURE IN A JACKASS PENGUIN (*Spheniscus demersus*)
Rui Bernardino, Teresa Lobo Fernandes, Arlete Sogorb, and Narciso Lapão,* 179

OVICIDAL EFFECT OF THE FUNGUS *Pochonia chlamydospora* ON THE GASTROINTESTINAL PARASITE *Contracaecum pelagicum* IN THE MAGELLANIC PENGUIN (*Spheniscus magellanicus*)
Cindy Braud, Fabio Ribeiro Braga, Filippe Elias de Freitas Soares, Tiago Senna, Thiago de Hollanda Ayupe, Leandro Abreu da Fonseca, Tracy Lacerda, Anderson Rocha Aguiar, Luis Felipe Mayorga, and Jackson Victor de Araújo* 180

SERUM CONCENTRATIONS OF IONISED CALCIUM, TOTAL CALCIUM AND PHOSPHORUS IN THE CRITICALLY ENDANGERED KĀKĀPŌ (*Strigops habroptilus*)
James Chatterton, An Pas, Sarah A. Alexander, Joanne Paul-Murphy, Richard Jakob-Hoff, Daryl Eason, and Andrew Digby* 182

PLASMID-MEDIATED ANTIMICROBIAL RESISTANCE GENES IN HOUSE SPARROWS (*Passer domesticus*): A COMPARATIVE STUDY BETWEEN LIVESTOCK AND URBAN ENVIRONMENTS
Verónica Delicado, Fernando Esperón, Matilde Carballo, José Ignacio Aguirre, and Ana de la Torre* 184

ELECTROCHEMOTHERAPY FOR THE TREATMENT OF FIBROMA IN RED-BILLED CURASSOW (*Crax blumenbachii*)
Suzana B. Hirata, Carlos H. M. Brunner, and Stéfanie V. Santos* 186

PUBLIC HEALTH IMPORTANCE OF ANTIBIOTIC-RESISTANT ENTEROBACTERICEAE IN CLOACAL ISOLATIONS FROM FOUR SPECIES OF PSITTACIDAE (*Pyrrhura picta, Primolius couloni, Pionus menstruus AND Pionus chalcopterus*) KEPT IN CAPTIVITY IN LIMA, PERU
María Fernanda Jordán Romero, Gianmarco Rojas Moreno, Siever Morales Cauti , and Lizzie Ortiz Cam* 188

EVALUATING A TRICHOMONAS RAPID TEST IN PIGEONS (*Columbia livia f. domestica*) AND BUDGERIGARS (*Melopsittacus undulatus*)
H. Kempf, F. Benaglia, and S. Oefner* 190

NEWCASTLE VACCINE IN SOUTHERN GROUND-HORNBILLS (*Bucorvus leadbeateri*): A TOOL TO REDUCE MORTALITY IN REINTRODUCTION STOCK
Katja N. Koeppel, Lucy Kemp, and Louis Maartens* 191

CHLAMYDIACEAE IN FREE-RANGING HAWKS (*Buteo* sp.) IN NORTHERN CALIFORNIA
Charlene Luján-Vega, Michelle G. Hawkins, Christine Kreuder Johnson, Christopher Briggs, Chris Vennum, Peter Bloom, Joshua M. Hull, Carolyn Cray, Denise Pesti, Bernard Wolff, Paula Ciembor, and Branson W. Ritchie* 193

SERUM BIOCHEMICAL AND HEMATOLOGIC VALUES FROM ALCIDS: A 17-YEAR RETROSPECTIVE STUDY IN THE OCEANÁRIO DE LISBOA, PORTUGAL
Nuno Pereira, Salomé Gonçalves, Bruno Baptista, Pedro Serra, Hugo David, Iara Nogueira, and Núria Baylina* 195

CARDIOLOGY IN THE IBIS: CARDIAC TROPONIN I, ECHOCARDIOLOGY, AND POST-MORTEM LESIONS
Kathryn L. Perrin, Michael M. Garner, Mark F. Stidworthy, Rebecca Langhorn, Jakob L. Willesen, Jørgen Koch, and Mads F. Bertelsen* 196

PROVENTRICULAR DISEASE IN THE LITTLE PENGUIN (*Eudyptula minor novaehollandiae*)
Gabrielle Tobias, Lydia Tong, Kimberly Vinette Herrin, Larry Vogelnest, Frances Hulst, Cheryl Sangster, and Laetitia Volait* 198

SIGNIFICANCE OF CAUSES OF ADMISSION OF NORTH AMERICAN OSPREY (*Pandion haliaetus*) TO A SOUTH CAROLINA AND A FLORIDA RESCUE CENTER
Anna Vecchione, Debbie Mauney, Renata Schneider, and Antonia Gardner* 200

PHARMACOKINETIC EVALUATION OF A LONG-ACTING FENTANYL SOLUTION AFTER TRANSDERMAL ADMINISTRATION IN HELMETED GUINEAFOWL (*Numida meleagris*)
Lynnette Waugh Heather Knych, Gretchen Cole, and Jennifer D'Agostino* 201

HIGH-DOSE COMBINED CHELATION THERAPY AND CARDIAC EVALUATION IN A BALD EAGLE (*Haliaeetus leucocephalus*) WITH ACUTE HIGH LEAD TOXICITY
Ernesto Domínguez-Villegas, Irene Galan-Lecona, Michelle Willette, Kathleen MacAulay, and Patrick Redig* 203

CARNIVORES

FEMINIZING ADRENAL TUMOR IN A MALE LION (*Panthera leo*)
Alice Andolfatto, Giuliano Ravasio, Maurizio Longo, Donatella De Zani, Vanessa Rabbogliatti, Alessia Giordano, Saverio Paltrinieri, William Magnone, Paola Roccabianca, and Davide Danilo Zani*..... 205

ULTRASONOGRAPHY IN BOBCATS (*Lynx rufus*): ASSESSMENT OF REPRODUCTIVE PERFORMANCE AND GENERAL HEALTH STATUS
Julia Bohner, Sergey V. Naidenko, Katarina Jewgenow, Johanna Painer, and Frank Göritz*..... 207

SUCCESSFUL TREATMENT AND MANAGEMENT OF SEVERE DERMATOPHYTOSIS IN A GROUP OF CAPTIVE SNOW LEOPARDS (*Uncia uncia*)
Sarah Chapman, Phillipa Dobbs, Kate Griffiths, Elizabeth M. Graham, and Mary Pinborough*..... 209

FAMILIAL OCCURRENCE OF SUSPECTED SWEAT GLAND ADENOCARCINOMA IN FOUR AFRICAN HUNTING DOGS (*Lycaon pictus*)
Baptiste Chenet, Marion Mosca, David Gomis, Karin Lemberger, and Didier Pin*..... 211

INFLAMMATORY BOWEL DISEASE IN A CLOUDED LEOPARD (*Neofelis nebulosa*)
*Yen Hsueh Lai, Olivia Hsieh, and Jun Cheng Guo**..... 213

EFFICIENT TREATMENT OF FLEA INFESTATION WITH ORAL FLURALANER IN EIGHT CAPTIVE MANED WOLVES (*Chrysocyon brachyurus*)
Hanna S. Kokubun, André L.M. Costa, Vanessa L. Ribeiro, Rode P. Gomes, Mariana H. Paschoalotti, and Rodrigo H.F. Teixeira* 214

SURGICAL APPROACH TO PARTIAL EYELID AGENESIS IN SNOW LEOPARDS (*Uncia uncia*)
Jochen Lengger, Hannes Meissel, Leif Blomqvist, and Barbara Nell* 216

CAUSES OF MORTALITY IN FELIDS AT PARQUE ZOOLOGICO HUACHIPA FROM 1998 TO 2015
Fernando Murillo, Gianmarco Rojas, Lizzie Ortiz, and Ewerton L. de Lima*..... 217

ANESTHESIA OF EUROPEAN BROWN BEARS (*Ursus arctos*)
Johanna Painer and Frank Goeritz* 218

SEROLOGIC EVIDENCE OF *Cytauxzoon felis* IN CAPTIVE LIONS OF INDIA
Sujay C. S., Muliya S. K., Gonathinayagam. S., Senthilkumar. K., Manjunatha. V., Azhahianambi. P., and Jayathangaraj. M. G.* 219

PHYLOGENETIC ANALYSIS OF THE HEMAGGLUTININ GENE OF CANINE DISTEMPER VIRUS FROM NATIVE WILDLIFE IN THE SOUTHEASTERN UNITED STATES
Kellyn M. Sweeley, Karen L. Bailey, Jerry T. Saliki, Michael J. Yabsley, and Daniel G. Mead* 220

ULTRASONOGRAPHIC CHARACTERISTICS OF INTESTINAL ASCARIASIS COINCIDENT WITH CHOLECYSTITIS AND CHOLELITHIASIS IN ASIATIC CHEETAH (*Acinonyx jubatus venaticus*)
Yasamin Vali, Iman Memarian, Mohammad Molazem, and Alireza Shahrdari* 222

GENERAL TOPICS

ZOONOTIC HELMINTHOSIS IN ZOOKEEPERS AND ZOO ANIMALS IN UNIVERSITY ZOOLOGICAL GARDEN ABEOKUTA, SOUTHWEST NIGERIA
*Oluwaseun D. Adisa, Emmanuel C. Uwalaka, Oyeduntan A. Adediran, Adeniyi O. Egbetade, Olufemi I. Olatoye, and Olufemi B. Adedeji** 224

CONSERVATION EDUCATION CENTERS AS BOUNDARY ORGANIZATIONS FOR VETERINARY OUTREACH
Jennifer C.G. Bloodgood, Gary T. Green, Nik Heynen, Katie Higgins, Terry M. Norton, Lisa A. Hoopes, and Sonia M. Hernandez* 226

TENSILE FAILURE LOAD IN TWO MONOFILAMENT ABSORBABLE SUTURES: A COMPARISON OF THREE INCUBATION TEMPERATURES OVER TIME
Sarah A. Cannizzo, Simon C. Roe, Craig A. Harms, and Michael K. Stoskopf* 228

THE ANIMAL WELFARE ACT: OVERVIEW OF REQUIREMENTS FOR VETERINARY CARE
Laurie J. Gage 229

DEVELOPMENT OF AN ONLINE TUMOR DATABASE FOR ZOOLOGICAL AND EXOTIC SPECIES
Tara M. Harrison, Cassondra Bauer, Ryan Colburn, Joanne Paul-Murphy, Michelle G. Hawkins, Catherine Pfent, and Ashley Zehnder* 232

TO BE OR NOT TO BE: CLINICAL SIGNIFICANCE INDEX (CSI) AS A PROPOSED TOOL TO CATEGORIZE THE IMPORTANCE OF INFECTIOUS PATHOGENS IN WILD ANIMALS
Ezequiel Hidalgo-Hermoso, Rodrigo Salgado, Consuelo Vega, and Rocio Lagos* 234

VETERINARIAN STAFFING TO COLLECTION-ANIMALS RATIO: HOW DOES YOUR INSTITUTION STACK UP?
Julia E. Napier and Douglas L. Armstrong* 235

INTERNATIONAL TRANSPORT OF ZOO ANIMALS AND THE IMPORTANCE OF OVERLOOKING THE BASIC MANAGEMENT TECHNIQUES TO ACCOMPLISH ANIMAL WELLBEING
Patricia M. Rios 236

THE PAST, PRESENT, AND FUTURE OF THE FROZEN ZOO®
Oliver A. Ryder PhD, Barbara S. Durrant, and Marlys L. Houck* 237

SMALL SEEDS TO MIGHTY TRUNKS: BUILDING A COLLABORATIVE PARTNERSHIP TO STRENGTHEN VETERINARY DIAGNOSTIC PATHOLOGY CAPACITY IN UGANDA
Dale A. Smith, Julius Okuni, Michael Cranfield, Linda J. Lowenstine, Sarah Corner,* and Tanja S. Zabka* 239

THE APPLICATION OF ONE HEALTH TO FACILITIES, AQUARIUMS AND ZOOS
Michael T. Walsh 241

REPTILES AND AMPHIBIANS

PHARMACOKINETICS OF VORICONAZOLE IN TUATARA (*Sphenodon punctatus*)
Sarah A. Alexander, Sharon Paterson, Nick Holford, Merran Govendir, Andrew McLachlan, Richard Jakob-Hoff, and Kristin Warren* 243

HEALTH SURVEY INCLUDING SELECTED BLOOD PARAMETERS IN THE SLENDER SNOUTED CROCODILE (*Mecistops cataphractus*) AT THE ABIDJAN ZOO IN CÔTE D'IVORIE
Carol Bradford and Matt Eschenbrenner* 245

DIAGNOSIS OF RANAVIRUS USING BONE MARROW HARVESTED FROM MORTALITY EVENTS IN EASTERN BOX TURTLES (*Terrapene carolina carolina*)
Claire E. Butkus, Matthew C. Allender, Laura A. Adamovicz, and Christopher A. Phillips* 247

HEALTH ASSESSMENT OF CAPTIVE-RAISED ALLIGATOR SNAPPING TURTLES (*Macrochelys temminckii*) IN A CONSERVATION INITIATIVE IN LOUISIANA, USA
Peter M. DiGeronimo, Nicola Di Girolamo, Hughes Beaufrère, João Brandão, Beau B. Gregory, Peter Jowett, Britton J. Grasperge, and Javier G. Nevarez* 249

MEASURING INTRAOCULAR PRESSURE IN WHITE'S TREE FROGS (*Litoria caerulea*) BY REBOUND TONOMETRY: COMPARING DEVICE, TIME OF DAY, AND MANUAL VERSUS CHEMICAL RESTRAINT
Jennifer C. Hausmann, Ashley Krisp, Kurt Sladky, Paul E. Miller, and Christoph Mans* 251

HUMORAL IMMUNE RESPONSE AND PRESENCE OF VIRAL RNA IN TISSUE OF HATCHLING AMERICAN ALLIGATORS (*Alligator mississippiensis*) AFTER VACCINATION WITH A KILLED WEST NILE VIRUS VACCINE
Christine T. Higbie, Javier G. Nevarez, Alma F. Roy, and Fabio Del Piero* 252

HARD SCIENCE FOR SOFTSHELLS: CRYOPRESERVING TURTLE SPERM
Susanne Holtze, Peter Praschag, Shannon DiRuzzo, Frank Göritz, Joseph Saragusty, and Thomas Bernd Hildebrandt* 253

COMPARING THE SUCCESS OF TWO HORMONAL BREEDING PROTOCOLS IN HOUSTON TOADS (*Anaxyrus houstonensis*)
Rachel A. Jania, Tyler Parker, Colin Thompson, Vance L. Trudeau, and Lauren L. Howard* 254

PHARMACOKINETICS OF NEBULIZED AND SUBCUTANEOUSLY IMPLANTED TERBINAFINE IN COTTONMOUTHS (*Agkistrodon piscivorus*)
Lauren P. Kane, Matthew C. Allender, Grace Archer, Katie Leister, Marta Rzadkowska, and Sherry Cox* 255

ANESTHETIC EFFICACY OF MS-222 IN WHITE'S TREE FROGS (*Litoria caerulea*)
Ashley R. Krisp, Jennifer C. Hausmann, Christoph Mans, and Kurt Sladky* 256

IDENTIFICATION OF A NOVEL HERPESVIRUS IN FREE-RANGING BLANDING'S TURTLES (*Emydoidea blandingii*) FROM ILLINOIS
Dana M. Lindemann, Matthew C. Allender, Dan Thompson, Laura Adamovicz, and Elena Dzhaman* 257

MODIFIED HIDING PLACE-SHIFTING BOX FOR SAFE VETERINARY TREATMENT OF VENOMOUS SNAKES
Maja Lukac, Ivan Cizelj and Ivo Peranić* 259

SURGICAL EXCISION OF A SALIVARY GLAND NEOPLASIA OF A PATAGONIAN GREEN RACER (*Philodryas patagoniensis*) IN CAPTIVITY IN BRAZIL
Henrique G. Riva, Vanessa L. Ribeiro, Hanna S. Kokubun, André Luiz M. da Costa, Viviane Nemer, Rodrigo A. Réssio, Natália C. Fernandes, and Marcelo P. N. de Carvalho* 260

ECTOPIC OSSIFICATION AND SOFT TISSUE MINERALIZATION IN CAPTIVE- RAISED EASTERN INDIGO SNAKES (*Drymarchon couperi*)
John F. Roberts, Paige Roberts, Sam Rivera, Elizabeth W. Howerth, Marie E. Rush, David A. Steen, and Craig Guyer* 263

DERMATITIS-ASSOCIATED MORBIDITY AND MORTALITY, AND SUCCESSFUL TREATMENT IN ENDANGERED HOUSTON TOADS (*Anaxyrus houstonensis*)
Jacobo Romano Noriega, Paul S. Crump, Tyler Parker, and Lauren L. Howard* 264

PELVIC LIMB AMPUTATION AND OUTRIGGER WHEEL PROSTHESIS IN A SULCATA TORTOISE (*Geochelone sulcata*)
Michelle C. Whitehead, J. Jill Heatley, Bill Bickley, Jennifer L. Perkins, and Sharman M. Hoppes* 265

MIXED TAXA

CASE REPORT: TOXOPLASMOSIS IN A RED KANGAROO (*Macropus rufus*) AND MARA (*Dolichotis patagonum*) IN CAPTIVITY
Nataly Díaz-Ayala, Constanza Cabello, Ezequiel Hidalgo-Hermoso, and Francisco R. Carvallo* 266

DENTAL FRACTURE IN A BENNETT'S WALLABY (*Macropus rufogriseus*): CASE PROGRESSION AND DIAGNOSTIC CHALLENGES
Paloma C. Henrique, Laura C. Reisfeld, and Damiana C. F. Pimenta* 268

A SLOTH, ANTEATER AND ARMADILLO WALK INTO THE CLINIC: VETERINARY HUSBANDRY BEHAVIORS IN XENARTHRANS
Dominique L. Keller, Sarah Graham, Tara Jimenez, and Kristina Ellis* 269

DIAGNOSIS AND MEDICAL MANAGEMENT OF THORACIC ACTINOMYCOSIS AND PULMONARY HYPERTROPHIC OSTEOPATHY IN A RED KANGAROO (*Macropus rufus*)
Patricia E. Kunze, Carlos R. Sanchez, Ashley Pich, and Stuart Aronson* 270

KOALA (*Phascolarctos cinereus adustus*) DIGIT AMPUTATION DUE TO DEEP CRYPTOCOCCOSIS
Teresa Lobo Fernandes, Rui Bernardino, and Hugo Pissarra* 271

SEROLOGIC ASSESSMENT OF DISEASE EXPOSURE AND VACCINE EFFICACY OF WILD RACCOONS (*Procyon lotor*) AND OPOSSUM (*Didelphis virginiana*) WITHIN A ZOOLOGIC INSTITUTION
Dennis Michels, Britany Rizzo, Kim Rainwater, Ric Berlinski, and Yousuf Jafarey* 272

BACK TO AFRICA: TRANSLOCATION OF EUROPEAN CAPTIVE ANIMALS TO A SEMI-FREE EXHIBIT IN DJIBOUTI
Baptiste Mulot, Romain Potier, Thierry Petit, and Bertrand Lafrance* 274

MANAGING REPRODUCTION AND SOCIAL DYNAMICS IN A NAKED MOLE RAT (*Heterocephalus glaber*) COLONY: WHICH CONTRACEPTION IS BEST?
Janis A. Raines, Elizabeth Bickenese, and Linda Penfold* 275

WHAT RISK DO PROGRAM ANIMALS POSE TO OUR COLLECTIONS?
Edward C. Ramsay and Vanessa Rabito* 277

EVALUATION OF THE IMPACT OF INVASIVE BLACK RATS (*Rattus rattus*) ON MALAGASY ENDEMIC RODENTS: HABITAT OCCUPANCY AND PARASITISM
Emilie Ribault, Fidisoa T. Rasambainarivo, Alexis Ribas and Emmanuelle Gilot-Fromont* 278

POISONING OF WILDLIFE IN ENVIRONMENTAL PARKS OF BRAZIL
Elisângela de Albuquerque Sobreia and Sheila Canevese Rahal* 280

HEPATITIS E VIRUS-RELATED VIRUSES: DO THEY ALSO OCCUR IN ZOO ANIMALS?
Carina Spahr, Reimar Johne, Tobias Knauf-Witzens, and Rainer G. Ulrich* 281

DISSEMINATED PROTOTHECOSIS IN A RUWENZORI LONG-HAIRED FRUIT BAT (*Rousettus lanosus*)
Brian G. Stockinger, Douglas L. Armstrong, and Alan R. Doster* 282

PRIMATES

INDIVIDUAL ASSESSMENT OF THE WESTERN LOWLAND GORILLA (*Gorilla g. gorilla*) DIET IN THE ZOO BASEL
Sara Abreu, Christina Simon, Stefan Hoby, Adrian Baumeyer, and Christian Wenker* 283

CHARACTERIZATION AND TREATMENT OF A NEW WASTING DISEASE OF OWL MONKEYS (*Aotus* sp.)
Alan G. Brady Gregory K. Wilkerson, Lawrence E. Williams, and George W. Tustin* 284

SEVERE PROTEIN-ENERGY MALNUTRITION: KWASHIORKOR IN A JUVENILE CHIMPANZEE (*Pan troglodytes*)
Thalita Simões Calvi 285

COMPARISON OF THREE METHODS OF PREVENTING PERI-ANESTHETIC HYPOTHERMIA IN CALLIMICO (*Callimico goeldii*)
Sathya K. Chinnadurai, James G. Johnson III, and Jennifer N. Langan* 287

ALLOMETRIC SCALING OF ECHOCARDIOGRAPHIC VARIABLES IN WILD-BORN CAPTIVE CHIMPANZEES (*Pan troglodytes*)
Aimee L. Drane, Alan M. Batterham, Pablo Rodriguez, Carlos Sanchez, Michael Stembridge, Sarah Simcox, Yedra Feltrer, Bruce Peck, Jacyn Eng, Glyn Howaston, Rebeca Atencia, and Rob Shave* 288

LONG-TERM SURVEILLANCE OF HERPES B-LIKE VIRUS IN CAPTIVE SILVERED LEAF MONKEYS (*Trachypithecus cristatus*)
Kate A. Gustavsen, Julia K. Hilliard, Bonnie L. Raphael, and Paul P. Calle* 290

DISEASE MONITORING OF REHABILITATED WESTERN CHIMPANZEES (*Pan troglodytes verus*) IN SIERRA LEONE
Sophie Moittié, Rosa Garriga, Jenny Jaffe, and Carles Juan-Sallés* 291

SUCCESSFUL SURGICAL TREATMENT OF A CECO-CUTANEOUS FISTULA IN A CROWNED SIFAKA (*Propithecus coronatus*)
Benoît Quintard, Xavier Ferreira, Mélanie Berthet, Brice Lefaux, Alexandrine Vesz, and Karin Lemberger* 293

GENE ANALYSIS AND COMPARISION OF GENES INVOLVED IN IRON METABOLISM IN THREE DIFFERENT LEMUR SPECIES
Maja Ruetten, Hanspeter Steinmetz, Vidhya Jagannathan, Markus Thiersch, Regina Hoffmann-Lehmann, Tosso Leeb, and Max Gassmann* 294

A RETROSPECTIVE REVIEW OF MORTALITY AMONG ZOO-HOUSED GREAT APES BETWEEN 2004-2014
Victoria Strong, Kerstin Baiker, Marnie Brennan, Victoria L. Clyde, Sharon Redrobe, and Kate White* 295

IMPROVING THE WAY WE DART: REVIEWING TRENDS IN DARTING WILD PRIMATES
Elena Cunningham, Steve Unwin, and Joanna M. Setchell* 296

UNGULATES

SAFETY OF AZAPERONE FOR REPEATED ANESTHESIA ON WILD BOAR (*Sus scrofa scrofa*)
Barbara Blanc, Katia Ortiz, Yann Locatelli, and Thomas Cucchi* 298

PERIODONTAL DISEASE IN TWO ZOO-BASED SOUTHERN BLACK RHINOCEROS (*Diceros bicornis minor*)
Benn Bryant and Michelle Campbell-Ward* 300

DIAGNOSIS AND TREATMENT OF TWO SUBADULT BAIRD'S TAPIR (*Tapir bairdii*) WITH BILATERAL GUTTURAL POUCH INFECTION
Genevieve Dumonceaux 301

PHARMACOKINETICS OF A SINGLE ORAL DOSE OF FLUNIXIN MEGLUMINE IN THE WHITE RHINOCEROS (*Ceratotherium simum*)
Brittni East, Lisa Tell, Scott B. Citino, Daniel V. Fredholm, Kathryn C. Gamble, and Virginia Fajt* 303

EFFECT OF A PHYTOESTROGEN-RICH DIET ON THE MARE (*Equus caballus*) ESTROUS CYCLE: A MODEL FOR EXOTIC PERISSODACTYLA
Rachel Ferris, Bruce Christensen, Ghislaine Dujovne, and Camilla Scott* 305

UPDATE ON ELEPHANT ENDOTHELIOTROPIC HERPESVIRUS (EEHV) IN ASIAN ELEPHANT (*Elephas maximus*) RANGE COUNTRIES: A REPORT FROM THE FIRST ASIAN EEHV STRATEGY MEETING
Lauren L. Howard, Khajohnpat Boonprasert, Chatchote Thitaram, Christopher Stremme, Zaw Min Oo, Arun Zachariah, and Sonja Luz* 307

DIAGNOSIS OF PREGNANCY IN WILD BOVIDAE SPECIES USING A BOVINE ASSAY FOR PREGNANCY-ASSOCIATED GLYCOPROTEINS
Benjamin Lamglait and Thomas Rambaud* 308

COMPARING FECAL EGG COUNTS TO TIME SPENT EATING IN A GROUP OF GIRAFFES (*Giraffa camelopardalis*) IN A ZOOLOGICAL PARK: A RETROSPECTIVE STUDY
Denise Lukacs and Ray Ball* 310

COAGULOPATHY ASSOCIATED WITH FACTOR VII DEFICIENCY IN AN ASIAN ELEPHANT (*Elephas maximus*)
Michael Lynch, Ken McGrath, Karthik Raj, Philippa McLaren, Karen Payne, Richard McCoy, and Urs Giger* 311

PREVALENCE OF *Cobboldia elephantis* (Cobbold, 1866) IN FREE-RANGING ASIATIC ELEPHANTS (*Elephas maximus*) OF TAMIL NADU, INDIA
Nachimutu Sadiyappan Manoharan, Kadirvelu Senthilkumar, Sankaralingam Gomathinayagam, and Madurai Ganesan Jayathangaraj* 312

EFFECT OF IMPROVAC® ON SPERM VARIABLES, TESTOSTERONE SECRETION AND ACCESSORY SEXUAL GLANDS SIZE OF PYGMY GOAT (*Capra hircus*): A MODEL FOR CONTRACEPTIVE TREATMENT OF WILD RUMINANTS
Eva Martínez-Nevado, Adolfo Toledano-Díaz, Juncal García García, Rosario Velázquez, Cristina Castaño, Milagros C. Esteso, Antonio López-Sebastián, Rodolfo Ungerfeld, and Julián Santiago-Moreno* 314

CAPTURE OF FREE-RANGING MULE DEER (*Odocoileus hemionus*) WITH A COMBINATION OF MEDETOMIDINE, AZAPERONE AND ALFAXALONE
Amélie Mathieu, Nigel Caulkett, Patrick M. Stent, and Helen M. Schwantje* 315

PROPOSED GUIDELINES FOR NATIONAL MOVEMENT OF BOVIDAE SEMEN BETWEEN ZOOLOGICAL INSTITUTIONS
Linda M Penfold Natalie Hall, and Geoff Pye* 316

PORCINE ZONA PELLUCIDA (PZP) VACCINATION IN A FREE-ROAMING FERAL HORSE POPULATION FOLLOWING INDIVIDUAL CHEMICAL IMMOBILISATION AND REMOTE BOOSTER: IS IT FEASIBLE?
Ovidiu Rosu, Alin I. Birtoiu, and Schwarzenberger Franz* 317

TREATMENT OF AN ASIAN ELEPHANT (*Elephas maximus*) WITH FLUOXETINE
Valarie V. Tynes, Steven E. Scott, and Lydia P. Young* 326

DIAGNOSIS AND SHEDDING INCIDENCE OF ELEPHANT ENDOTHELIOTROPIC HERPESVIRUS IN SWISS CAPTIVE ASIAN ELEPHANTS (*Elephas maximus*)
*Sandra Wenger,*Jean-Michel Hatt, Hanspeter Steinmetz, and Mathias Ackermann* 327

DELICATE TRANSATLANTIC ADVENTURE: OKAPI (*Okapia johnstoni*) AND LESSER KUDU (*Tragelaphus imberbis*) TRANSFER FROM THE UNITED STATES TO SWITZERLAND
Christian Wenker, Stefan Hoby, Friederike von Houwald, and Beatrice Steck*..... 328

SERUM CONCENTRATIONS OF ANTIMYCOBACTERIAL DRUGS IN ASIAN ELEPHANTS (*Elephas maximus*)
Lydia Young, Steve Scott, Max Salfinger, and Ed Ramsay* 330

BEST PRACTICE GUIDELINES FOR FIELD-BASED SURGERY AND ANESTHESIA OF FREE-RANGING WILDLIFE

Sathya K. Chinnadurai, DVM, MS, Dipl ACZM, Dipl ACVAA,[1]* Christine V. Fiorello, DVM, PhD, Dipl ACZM,[2] Craig A. Harms, DVM, PhD, Dipl ACZM,[3] Danielle Strahl-Heldreth, MS, DVM,[4] and Daniel M. Mulcahy, PhD, DVM, Dipl ACZM[5]

[1]Chicago Zoological Society, Brookfield, IL 60513 USA; [2]Wildlife Health Center, School of Veterinary Medicine, University of California at Davis, Davis, CA 95616 USA; [3]Center for Marine Sciences and Technology and Department of Clinical Sciences, College of Veterinary Medicine, North Carolina State University, Morehead City, NC 28557 USA; [4]University of Illinois, College of Veterinary Medicine, Urbana, IL 61802 USA; [5]P.O. Box 241512, Anchorage, AK 88524 USA

Abstract

A basic standard of care for field-based wildlife anesthesia and surgery should be established.[1,2] This presentation details best practice guidelines for veterinarians and wildlife professionals performing these procedures on free-ranging animals. Procedures in the field are typically done as part of research and management projects and usually involve a combination of biologists and veterinarians with the possibility of conflicts in scientific cultures. Field anesthesia is often necessary for both invasive and noninvasive procedures on wild animals. We describe basic principles of safe anesthetic delivery, monitoring, and recovery for application in procedures involving free-ranging wildlife. For invasive procedures, the potential for immediate and lasting pain must be addressed and appropriate analgesia provided. In situations where the minimum standard of safe anesthesia and effective analgesia cannot be provided, the investigator and approving bodies should rigorously evaluate the risk to the patient against the value of the data obtained. The principles of surgical asepsis apply to field surgeries with few exceptions. The minimum level for performance of surgeries in the field on free-ranging animals should be the same as for domestic animals undergoing surgery in animal hospitals. This document outlines a minimum standard of care for field anesthesia and surgery and will serve as a resource for Institutional Animal Care and Use Committees, and biologists and veterinarians planning projects that involve surgeries on free-ranging wildlife in field conditions.

Key words: Analgesia, anesthesia, guidelines, immobilization, surgery, wildlife

LITERATURE CITED

1. Chinnadurai SK, Strahl-Heldreth D, Fiorello CV, Harms CA. Best practice guidelines for field-based surgery and anesthesia of free-ranging wildlife. I. Anesthesia and analgesia. J Wildl Dis. 2016;52(2): S14-S27.

2. Fiorello CV, Harms CA, Chinnadurai SK, Strahl-Heldreth D. Best practice guidelines for field-based surgery and anesthesia on free-ranging wildlife. II. Surgery. J Wildl Dis. 2016;S28-S39.

WRITING AND REVIEWING ANIMAL CARE AND USE PROTOCOLS FOR WILDLIFE RESEARCH: TIPS ON PLANNING FOR THE UNEXPECTED

Elizabeth A. Falendysz, DVM and Jennifer E. Brunner, BS*

USGS National Wildlife Health Center, 6006 Schroeder Rd. Madison, WI 53711 USA

Abstract

Any wildlife research in the United States involving non-avian warm-blooded animals that has the potential to substantially change the animal's behavior or that involves an invasive procedure must be approved by a properly constituted Institutional Animal Care and Use Committee (IACUC), according to the Animal Welfare Act.[5,6] Depending on the institution, this review may be required for research using other species as well. Although some consider this process a hurdle in completing their research, it can function as a tool to help plan research that promotes animal welfare while producing high quality science. Zoo and wildlife veterinarians may act in several roles in this process: as an investigator and writer of animal care and use protocols, as a subject matter expert, as the provider of the legally-required veterinary consultation, as a member of an IACUC and reviewer of protocols, or a combination of these roles. Experienced wildlife veterinarians and field biologists offer a wealth of knowledge and have published several invaluable references to get researchers started in developing appropriate field research protocols.[1,2,4,7] Of course, no publication can cover every unique field situation or every species. While typical laboratory animal use protocols may follow well-established guidelines for procedures and use of drugs,[3] wildlife field research may require a more in-depth search for relevant literature, consultation of others with experience, and may require higher reliance on well-reasoned assumptions. Wildlife field research requires thoughtful consideration of many factors, some beyond the control of researchers, including weather, the presence of predators or territorial conspecifics, migration patterns, and others. Physical or chemical immobilization also requires special consideration outside of just species-appropriate drug doses, such as species-typical behavior, downstream affects on the food chain, and terrain. Of course, many of these factors are not completely predictable. The protocol review process should allow researchers to consider what *could* happen, consider appropriate alternative procedures, and protocols should include some flexibility to allow experienced field staff to make adjustments to current conditions while still staying fully compliant with their animal care and use protocol.

Key words: Animal use, animal welfare, field research, IACUC, wildlife research

LITERATURE CITED

1. American Society of Ichthyologists, The Herpetologists League, Society for the Study of Amphibians and Reptiles. Guidelines for the use of live amphibians and reptiles in field research [Internet]. Available from http://www.aaalac.org/accreditation/Guidelines_for_Use_of_Live_Amphibians_and_Reptiles.pdf/ c2006

2. Gaunt AS, Oring LW (eds.). Guidelines to the use of wild birds in research. Washington (DC): The Ornithological Council; 1997.

3. National Research Council. Guide for the care and use of laboratory animals: eighth edition. Washington, DC: The National Academies Press; 2011. p. 41-104.

4. Sikes RS, Gannon WL, The Animal Care and Use Committee of the American Society of Mammologists. Guidelines of the American Society of Mammalogists for the use of wild mammals in research. J Mammal. 2011;92(1):235-253.

5. United States Department of Agriculture. Animal Welfare Act. 7 U.S.C Sections 2131-2159; 2013. p. 1-6.

6. United States Department of Agriculture. Animal Welfare Regulations. 9 C.F.R. Parts 1-4; 2013. p. 17-33.

7. West G, Heard D, Caulkett N (eds.). Zoo animal and wildlife immobilization and anesthesia. Ames (IA): Blackwell Publishing; 2007.

ON-THE-GO LABS: PORTABLE FIELD DIAGNOSTIC EQUIPMENT AND TECHNIQUES

Paul P. Calle, VMD, Dipl ACZM,* Bonnie L. Raphael, DVM, Dipl ACZM, Denise McAloose, VMD, Dipl ACVP, and Tracie A. Seimon, PhD

Wildlife Conservation Society, Zoological Health Program, Bronx, NY 10460-1099 USA

Abstract

Advances in medical equipment and techniques have enabled a suite of portable, compact, durable equipment and supplies for field settings. Mobile laboratory technologies enhance diagnostic testing in locations with limited resources and can facilitate both the analysis and export of diagnostic samples. On-site processing provides immediate results that can inform real-time decisions such as those for appropriate animal treatment or needed biosecurity measures. Use of portable field equipment may also eliminate the need for sample export and import that, depending upon the species and country, could take months or years to arrange or be impossible due to export prohibitions.

The Wildlife Conservation Society's Zoological Health Program is active in regional and international field research projects. The portable equipment we have most frequently used in these situations are portable microscopes, centrifuges, hand-held biochemistry analyzers, liquid nitrogen dry shippers, molecular diagnostic kits for DNA/RNA isolation,[a,b] conventional and quantitative PCR,[a,c] gel electrophoresis, ultrasound, and endoscopes. Helpful techniques include use of filter papers for protein and nucleic acid preservation[d,e] that can be simply prepared and stored without refrigeration or freezing for toxicology, serology, and molecular diagnostics; Natt and Herricks solution for non-mammalian CBCs; and preservation solutions to enable later analysis such as feces in sodium acetate formalin for enteric fecal parasite screening, whole blood in neutral buffered formalin for CBC counts, and tissue or blood in RNA*later*®[b] for molecular testing. Much of the equipment can be powered by field-friendly methods that use an internal battery, 110 or 220 volt current (from either an outlet or a generator), car battery (connected either directly or through a vehicle cigarette lighter connection), or solar battery,[f] which also greatly expand the utility of these techniques for diverse and remote field settings.

[a]Biomeme, Inc., 20 N 3rd St., Philadelphia, PA 19106 USA
[b]Qiagen, 27220 Turnberry Lane, Suite 200, Valencia, CA 91355 USA
[c]Bio-Rad Laboratories, 9500 Jeronimo Road, Irvine, CA 92618 USA
[d]903 Proteinsaver Snap-Apart Card, GE Healthcare Bio-Sciences, 100 Results Way, Marlborough, MA 01752 USA
[e]FTA Elute cards, GE Healthcare Bio-Sciences, 100 Results Way, Marlborough, MA 01752 USA
[f]GoalZero, 675 West 14600 South Bluffdale, UT 84065 USA

Key words: Field equipment, mobile laboratory, molecular diagnostics, technology

ACKNOWLEDGMENTS

The authors thank the WCS veterinarians and veterinary and molecular technicians who contributed to identification and application of the equipment during our various field veterinary projects.

HOW AND WHAT CAN WE—SHOULD WE—LEARN ABOUT WORKING WITH BIOLOGISTS?

Sonia M. Hernandez, DVM, Dipl ACZM, PhD[1,2]* and Daniel M. Mulcahy, PhD, DVM, Dipl ACZM[3]

[1]Warnell School of Forestry and Natural Resources, University of Georgia, Athens, GA 30602 USA; [2]Southeastern Cooperative Wildlife Disease Study, College of Veterinary Medicine, University of Georgia, Athens, GA 30602 USA; [3]United States Geological Survey, Alaska Science Center, Anchorage, AK 99508 USA

Abstract

At times, the relationship between the biologist and the veterinarian has seemed strained at best. The two groups intersect in a variety of ways—traditionally, veterinarians have provided technical expertise with field studies, which can create inequality among participants and lead to conflict. This need not be the case, as examples of productive and synergistic work among the two abound and increasingly, it is the directive of zoos, state/federal agencies and NGO's to encourage multidisciplinary work. Ideally, true *collaborative* and *integrative* work entails intellectual investment from all parties involved, but that also requires respect and a sincere understanding of each other's training, credentials, background and ultimate goals. Additionally, while veterinarians were busy understanding their place in wild animal health, other groups (e.g., Ecological Society of America, The Wildlife Society) have been training wildlife health/disease specialists from a variety of perspectives. In fact, since the 1960s, ecologists and biologists have recognized that health and disease play a significant role in population dynamics and have contributed to our understanding of these fields exponentially. Most recently, techniques typically associated with biomedical sciences have been adopted and integrated into ecological contexts, largely bypassing DVMs all together (e.g., the rapidly growing fields of ecoimmunology, ecotoxicology and ecologic physiology). This presentation will 1) provide examples where veterinarians and biologists tend to come together, and pathways for successful collaboration; 2) highlight some highly successful non-DVM wildlife health/disease professionals and track their career paths, including their formulae for collaboration with DVMs; and 3) provide, through examples, the do's and don'ts of working in fruitful teams.

Key words: Biologists, conflict, respect, wildlife health specialist

HOW ARE WILDLIFE BIOLOGISTS TRAINED IN WILDLIFE HEALTH?

Jennifer C.G. Bloodgood, MS[1] and Sonia M. Hernandez, DVM, Dipl ACZM, PhD[1,2]*

[1]Daniel B. Warnell School of Forestry and Natural Resources, University of Georgia, Athens, GA 30602 USA; [2]Southeastern Cooperative Wildlife Disease Study, College of Veterinary Medicine, University of Georgia, Athens, GA 30602 USA

Abstract

Wildlife biologists serve in a wide range of positions, from government to non-governmental organizations, to academia. They can work in the field, behind a bench, and/or in an office. Wildlife biologists are trained in all aspects of wildlife natural history, including ecology, management, behavior, disease, genetics, habitat use, nutrition, and physiology. Undergraduates who pursue a wildlife career typically graduate with a BS in Wildlife Biology, Ecology, Biology, or Zoology. Wildlife biologists working for agencies typically go on to an MS degree, whereas most researchers and academics have earned PhDs. Wildlife biologists often belong to various professional organizations, including The Wildlife Society, Ecological Society of America, and Society for Conservation Biology, as well other more taxa-specific organizations (e.g., American Ornithologists' Union). Furthermore, The Wildlife Society, through a two-step process, provides accreditation as an Associate Wildlife Biologist after completion of educational requirements, which can evolve into Certified Wildlife Biologist status after a minimum of 5 yr of professional experience.[1]

With such a breadth of knowledge, wildlife biologists serve important roles in collaborative health investigations with veterinarians. They are an important resource when working in the field, with an in-depth knowledge of their study system and host species, legal boundaries, the permitting process, and sample collection and processing. While most biologists do not have a DVM degree, many do have advanced training in wildlife health and disease investigation and some go on to specialize in wildlife diseases. The Southeastern Cooperative Wildlife Disease Study (SCWDS) is an example of an institution dedicated to training biologists with advanced wildlife disease investigation skills. The USGS, the USDA and many universities employ individuals who are trained wildlife disease specialists but are not veterinarians. In this presentation, examples of preeminent wildlife biologists working in the field of wildlife health/disease with different careers, including state and federal agencies and academia, will be discussed. Understanding the background and career paths that have shaped various wildlife professionals is important when entering a collaborative effort.

Key words: Disease investigation, training, wildlife biologist, wildlife health

LITERATURE CITED

1. AboutTWS [Internet]. The Wildlife Society; c2015 [cited 2015 November 25]. Available from: http://wildlife.org/learn/professional-development-certification/

ONE HEALTH AND CONSERVATION MEDICINE ARE EVOLVING TO BUILD TRANSDISCIPLINARY COLLABORATIONS, INTEGRATIVE RESEARCH, AND LOCAL CAPACITY

A. Alonso Aguirre, DVM, MS, PhD[1] and Val Beasley, DVM, PhD, Dipl AVBT[2]*

[1]Department of Environmental Science and Policy, George Mason University, Fairfax, VA 22030-4400 USA; [2]Department of Veterinary and Biomedical Sciences, College of Agricultural Sciences, The Pennsylvania State University, University Park, PA 16802 USA

Abstract

Conservation Medicine evolved from the realization that dealing with the threats to declining and endangered species was highly dependent upon the health of the affected species, the integrity and resilience of their ecosystems, and the health and wellbeing of neighboring domestic animals as well as the human communities that shared or live nearby the landscapes and water bodies involved. Conservation Medicine has emphasized the need to bridge disciplines, thereby linking human health, animal health, and ecosystem health under the paradigm that "health connects all species in the planet." The strategies of Conservation Medicine include long-term monitoring, coupled with health assessments and interventions to protect at-risk humans, other species, and/or ecosystems. Therefore, Conservation Medicine requires studies of relatively straightforward to extraordinarily complex interactions. The former might include a study of a single pathogen and risks of disease in a local human community and a single group of animals. An example of the latter might include an evaluation of multiple stressors (e.g., climate extremes, pathogens, toxicants, habitat availability and quality) and multiple species of animals at risk across a large area. Building upon the time-sensitive interventionist underpinnings of conservation biology, that is, species can become extinct if needed interventions are delayed, Conservation Medicine focuses on the ecological context of health and the remediation of ecological health problems. Conservation Medicine depends upon the combined expertise of team members who have the knowledge and skills needed to examine and provide care for individuals, populations, communities, and ecosystems. Consistent with this philosophy and goals, conservation medicine strives to ensure lasting local conservation impacts with local health solutions with every project by training community leaders, volunteers and school children, in addition to professional, in-country experts.

Over the past decade, the term One Health has been rationally applied to historic and evolving roles including research and application in the fields of: comparative morphology and physiology, animal models of human diseases, translational medicine, zoonotic diseases and antimicrobial resistance. In recent years, One Health has added to those areas greater attention on understanding and prevention of infectious disease transmission at the wildlife/domestic animal/human interface. Today, One Health is increasingly focusing on the interdependence of human health, animal and plant health and the necessary backdrop of ecosystem integrity. Accordingly, for the near- and long-term future, One Health has little choice but to engage in the study, mitigation and prevention of daunting challenges. To succeed, One Health groups will need to address not only emerging and re-emerging infectious diseases, but also the broader stressors that affect overcrowded and stressed human, domestic animal and wildlife populations. They will need to help counteract

habitat fragmentation and loss, human-wildlife conflicts, overharvest of wild species of plants and animals, invasive species, toxic chemical contamination, nutrient pollution and related hypoxic and dead zones as well as harmful algal blooms, climate change and ocean acidification, species declines and extinctions, and even warfare. Like other health scientists and practitioners, One Health integrators already recognize the need for effective engagement through groups whose careers are narrowly focused by economic and political constraints. Thus, to protect multiple species through integrated research, education, and stewardship will require bringing One Health perspectives and opportunities clearly and persuasively to the greater society. As with nested human, public, and animal health practices, integrated One Health researchers and practitioners will need to map, prioritize and target populations, health indicators, and stressors from local to global levels. Efforts to get this done and to intervene to improve One Health will need to be both "bottom/local up" and "top/national/international down." Innovative means to provide education to both everyday citizens and professionals in business, industry, politics, law, policy, agriculture, forestry, wildlife biology and management, fisheries, and the broad array of ecological and health sciences will be needed to catalyze the understanding required to underpin demands for synchronous gains in the health of humans, domestic and wild animals, and domestic and wild plants.

Conservation Medicine and One Health interventions require practical, sustainable and effective solutions. As such, these disciplines require a keen understanding of local socio-economic factors as well as a solid grasp of complex regional, national and international health and environmental policies. One Health and Conservation Medicine represent time-sensitive opportunities for zoo and wildlife veterinarians to apply their biomedical and health expertise to give rise to simultaneous benefits for humans, animals, and the environment. Work in some cases will be focused on individual animals and in other instances on populations, communities, regions, continents and the world as a whole. Such nested efforts are already underway and they should be expanded and built upon with great determination and vigor.

Key words: Climate change, conservation medicine, emerging infectious diseases, One Health

PRACTICAL EXPERIENCES OF A NON-GOVERNMENTAL ORGANIZATION (NGO) IMPLEMENTING ONE HEALTH INITIATIVES IN THE ALBERTINE, ECOSYSTEM, HOIMA, UGANDA

Lawrence Mugisha,[1,2]* Travis Dominic,[2] and Katey Pelican[2]

[1]Conservation and Ecosytem Health Alliance (CEHA), P.O.Box, 34153, Kampala, Uganda; [2]Ecosystem Health Initiative, Veterinary Population Medicine, College of Veterinary Medicine, University of Minnesota, St. Paul, MN 55108 USA

Abstract

The One Health concept, recognized as a multi-disciplinary, multi-sectorial approach to addressing grand challenges in health, is increasingly being utilized in the control and management of infectious diseases at human-wildlife-livestock interface. Recently, several university networks and initiatives have emerged to partner with and assist agencies at regional and global levels, triggering a myriad of opportunities for engagement such as local and international One Health conferences, workshops and meetings; however, One Health approaches remain largely theoretical at the local/community level. In order to bridge this gap, Conservation & Ecosystem Health Alliance (CEHA), a local non-governmental organisation, is working in the Albertine Ecosystem, Hoima, Uganda to integrate these initiatives into the community. By engaging district local governments to identify priority local health challenges, the aim is to help through research, capacity building and intervention. Thus, the establishment of these "One Health demonstration field sites" in Hoima, Kibaale and Kasese Districts will provide opportunities for short and long term research on diseases and health issues affecting communities at the human-animal interface, while building local capacity through interaction with various types of students and university faculty. Preliminary observations and experience with this approach reveal that local governments and communities are yearning for partnership and willing to adopt One Health approaches in solving complex health challenges affecting their communities once understood and appreciated.

Key words: Conservation, ecosystem, One Health

SEROEPIDEMIOLOGIC MONITORING IN SENTINEL ANIMALS AND HUMANS AS PART OF ARBOVIRUS SURVEILLANCE IN THE ATLANTIC FOREST OF BAHIA, BRAZIL

Lilian S. Catenacci, DVM,[1,2,3,4,12]* Sharon L. Deem, DVM, PhD, Dipl ACZM,[4] Milene S. Ferreira,[1] Kristel M. De Vleeschouwer, PhD,[3] Leonardo C. Oliveira, PhD,[5,6] Camila R. Cassano, PhD,[7] Gustavo Canale, PhD,[8] Debora D. C. Fernandes,[1] Livia C Martins, PhD,[1] Juan S. Tello, PhD[9,10] Patrcia Parker, PhD,[11,12] Pedro F. Vasconcelos, PhD,[1] and Elizabeth Salbe T. Rosa, PhD[1]

[1]Evandro Chagas Institute, Ananindeua, PA 67030-000 Brazil; [2]Universidade Federal do Piaui, Bom Jesus, PI 64900-000 Brazil; [3]Centre for Research and Conservation, Royal Zoological Society of Antwerp, Antwerp 2018 Belgium; [4]Saint Louis Zoo Institute for Conservation Medicine, Saint Louis, MO 63110 USA; [5]Bicho do Mato Instituto de Pesquisas, Belo Horizonte, MG 30380-234 Brazil; [6]Faculdade de Formação de Professor da Universidade do Estado do Rio de Janeiro, RJ 24435-005 Brazil; [7]Universidade Estadual de Santa Cruz, Ilheus, Bahia 45662-900 Brazil; [8]Universidade Federal do Mato Grosso, Cuiaba, MT 78060-900 Brasil; [9]Center for Conservation and Sustainable Development, Missouri Botanical Garden, Saint Louis, MO 63110 USA; [10]Escuela de Ciencias Biológicas, Pontificial Universidad Católica del Ecuador, Quito, Pichincha 17012184 Ecuador; [11]University of Missouri-St Louis, Saint Louis, MO 63121 USA; [12]Saint Louis Zoo, Saint Louis, MO 63110 USA

Abstract

Diseases caused by arboviruses, including yellow fever, dengue, Zika and West Nile virus, represent serious global public health concern. Seroepidemiologic monitoring of animals, vectors, and humans was used to assess arboviral prevalence in fragmented areas of the Brazilian Southern Atlantic Forest (BSAF). Between 2006 and 2014, 196 samples were collected from free-living primates (142 *Leontopithecus chrysomelas* and 7 *Sapajus xanthosthernos*) and 47 from sloths (40 *Bradypus torquatus* and 7 *Bradypus variegatus*). In the same sites, dip nets and CDC traps were used to survey vectors. In 2014, 282 humans at the same sites were sampled. Antibodies were detected using Haemagglutination Inhibition test for 25 arboviruses in 4 genus: *Flavivirus, Alphavirus, Orthobunyavirus* and *Phlebovirus.* Period prevalence (2006-2014) was 26.8% for wildlife; *B. torquatus* (41%)*, L. chrysomelas* (25.4%)*, S. xanthosthernos* (14.3%) and *B. variegatus* (14.3%). Using a generalized linear model, prevalence among mammal species, sexes and ages was compared. Prevalence was not associated with sex or age; however, prevalence was highest in *B. torquatus*. In humans, prevalence was 70.3%. Among virus genus, *Flavivirus* had the highest prevalence at 21.1% in animals and 69.8% in humans. Seroprevalence of *Alphavirus* and *Orthobunyavirus* was 0.7% and 4.2% in wildlife and 0.3% and 0.7% in humans, respectively. Antibodies of six arboviruses were present in humans and wildlife. Anopheline and phlebotomine vectors also were identified. Results suggest viral circulation and risk of transmission across species. This study is an important initiative that integrates data on human, wildlife and environmental health in a One Health framework.

Key words: Arboviruses, Neotropical primates, One Health, public health, sloths, virus

ACKNOWLEDGMENTS

The authors thank the Coordination for the Improvement of Higher Education Personnel (CAPES), and Lion Tamarins Fund to provide scholarship and funds to PhD Candidate Lilian Catenacci. Also, we would like to thank the Seção de Arbovirologia e Febres Hemorragicas from the Evandro Chagas Institute for their help with laboratory tests, the Health Service of the Ilheus and Una municipalities, Laboratorio Central de Salvador, 6ª Diretoria Regional de Saúde and the Federal Environmental Service (ICMbIO- REBIO and REVIS UNA) for help and permission to conduct this research. We further thanks for the Centre for Research and Conservation, Royal Zoological Society of Antwerp (Project Bio Brasil), the NGO IESB and Bicho do Mato Instituto de Pesquisa, the field assistants and the local communities for their assistance.

CLINICAL RELEVANCE OF NEWLY DEVELOPED *Chlamydia psittaci*-SPECIFIC ANTIBODY TESTS IN HUMANS AND ANIMALS SUSCEPTIBLE TO MULTIPLE *Chlamydia* spp.

Denise Pesti, MS, Christopher R. Gregory, DVM, PhD, and Branson W. Ritchie, DVM, PhD, Dipl ABVP (Avian), Dipl ECZM (Avian)*

Infectious Diseases Laboratory, University of Georgia, Athens, GA 30602 USA

Abstract

Testing for *Chlamydia psittaci* antibodies in humans is primarily based on micro-immunoflouresence (MIF) test kits that were developed in the 1970s. These kits were developed and validated at a point in history prior to the recognition of *C. pneumonia*e as a common human pathogen when chlamydial infection in humans were either classified as *C. trachomatis* or *C. psittaci*. According to a package insert from a commonly available MIF test kit, "At lower dilutions the specimens [human test serum] may cross-react to all three Chlamydia species. Unfortunately, cross-reactivity in these assays continues to result in patients with respiratory disease and a history of bird exposure being diagnosed with psittacosis irrespective of risk factors for infection with *C. trachomatis* or *C. pneumoniae* and actual titer results. To resolve the ongoing issues with the human-avian bond associated with incorrect interpretation of chlamydia serologic assays, we have developed species specific elementary body agglutination (EBA) and neutralization (SN) assays for *C. psittaci* that do not cross react with antibodies generated to *C. pneumoniae*. Additionally, we have developed in situ hybridization based assay that corrects for the cross-reaction that occurs between many gram-negative bacteria (*Salmonella* spp*., E. coli* spp., etc) and chlamydia inherent with commercial anti-chlamydial antibodies used in immunohistochemistry.

Key words: *Chlamydia* spp., EBA, in situ hybridization, MIF, psittacosis, SN

EFFECT OF ENVIRONMENTAL STRESS OF AN EL NIÑO EVENT ON ADENOVIRAL DIVERSITY IN MARINE ANIMAL ROOKERIES

Galaxia Cortes-Hinojosa, MV, MSc, PhD,[1]* Michael J. Adkesson, DVM, Dipl ACZM,[2] Susana Cárdenas-Alayza, MSc,[2,3] Mauricio Seguel, MV, ACVP,[4] Héctor Pavés, PhD,[5] and James F.X. Wellehan, Jr., DVM, PhD, Dipl ACZM, Dipl ACVM[6]

[1]University of Florida, Biology Department, Gainesville, FL 32611 USA; [2]Chicago Zoological Society, Brookfield Zoo, Brookfield, IL 60513 USA; [3]Center for Environmental Sustainability, Cayetano-Heredia University, Armendariz 445, Miraflores, Lima 18, Peru; [4]University of Georgia, Department of Pathology, College of Veterinary Medicine, Athens, GA 30602 USA; [5]Universidad Austral de Chile, Laboratory of Studies on Biology and Conservation of Aquatic Mammals and Sea Birds, Valdivia, 509000, Chile; [6]College of Veterinary Medicine, University of Florida, Gainesville, FL 32610 USA

Abstract

Environmental changes have major effects on the health of marine animals, especially in critical life stages. Small changes in productivity around breeding sites can effect the body condition index in juvenile Humboldt penguins. El Niño events change the normal patterns of the Humboldt upwelling, and significantly reduce the productivity of the system at a larger scale, generating mortalities, especially on juveniles. The effects of infectious diseases on South American fur seals (SAFS, *Arctophoca australis*) and Humboldt penguins (HP, *Spheniscus humboldti*) have received limited study, and the effects of environmental conditions on viral diversity in these animals have not been previously investigated. Adenoviruses are found in diverse vertebrates, with strong host fidelity exhibited.[1] Currently, there is a poor understanding of greater adenoviral diversity and ecology, mostly related with a research bias toward human adenoviruses. From the six genera proposed for adenoviruses, mastadenoviruses have only been detected in mammalian hosts, and aviadenoviruses have only been found in birds.[1] Two breeding colonies of SAFS,[2] a Chilean and a Perúvian colony, were screened using nested pan-adenoviral PCR primers. Differences in adenoviral diversity between an El Niño and a normal year in juveniles of SAFS in the Perúvian colony were evaluated. Four mastadenoviruses, four aviadenoviruses and a siadenovirus were identified in SAFS. Concurrent investigation of adenoviruses in HP at the same Peruvian site identified three mastadenoviruses, two aviadenoviruses, and three Siadenoviruses in HP. One aviadenovirus was detected in both HP and SAFS, suggesting a host jump. All aviadenoviruses detected in SAFS happened in pups sampled during an El Niño year, this suggests that environmental conditions can expose hosts to novel viruses; or alter susceptibility of the host to them. This is the first report of aviadenoviruses in marine mammals and mastadenoviruses in birds, and suggests that further viral diversity studies in sites with high density mixed species populations are warranted.

Key words: Adenovirus, El Niño event, Humboldt penguin, South American fur seal

ACKNOWLEDGMENTS

The authors thank Dr. Gwen Jankowski, Dr. Matt Allender, Marco Cardeña, and Franco Garcia for their assistance with this project. Partial funding for sample collection was provided by the Chicago Zoological Society, the Chicago Board of Trade Endangered Species Fund, and the Saint Louis Zoo WildCare Center.

LITERATURE CITED

1. Harrach B, Benko M, Both G, Brown M, Davison A, King A, Carstens E, Adams M, and Lefkowitz E et al. Family Adenoviridae. In: King AMQ, Adams MJ, Cartstens, Lefkowitz EJ (eds.). Virus Taxonomy: Ninth Report of the International Committee on Taxonomy of Viruses. New York (NY): Elsevier; 2011. p. 125-141.

2. Wellehan J, Johnson A, Harrach B, Benko M, Pessier A, Johnson C, Garner M, Childress A, and Jacobson E. Detection and analysis of six lizard adenoviruses by consensus primer PCR provides further evidence of a reptilian origin for the atadenoviruses. J Virol. 2004;78:13366-13369.

IS THERE EVIDENCE TO SUGGEST ELEPHANT-TO-ELEPHANT TRANSMISSION OF HUMAN TUBERCULOSIS?

David Abraham, BVSc&AH, MSc,[1]* T. Rajeev, BVSc&AH,[2] and Jacob V. Cheeran, BVSc&AH, MSc[3]

[1]Veterinary Surgeon, Veterinary Dispensary Theekuni, Kozhikode 673507, Kerala, India; [2]Veterinary Surgeon, Veterinary Dispensary Velavoor, Thiruvananthapuram 695607, Kerala, India; [3]Professor and Head (Rtd.), Department of Pharmacology, Wildlife Sciences, Kerala Agricultural University, Thrissur 680651, Kerala, India

Abstract

Mycobacterium tuberculosis and *M. africanum*, the two human-adapted members of *Mycobacterium tuberculosis* complex not known to have reservoir hosts in any other mammalian species, are defined as exclusive human pathogens.[4,5] The large number of reports of tuberculosis in the many species of wild and domestic animals caused by *M. tuberculosis*, are thus considered to represent spillover infections resulting from human co-habitation.[2] Most reported cases of tuberculosis in captive and wild Asian elephants (*Elephas maximus*), in range as well as non-range countries, are caused by *M. tuberculosis*.[7-10] As part of a long term research project, tuberculosis surveillance in more than 800 captive Asian elephants in southern India was performed.[1] Using DPP® Vet TB Assay (Chembio Diagnostics, Medford, New York), now licensed by the USDA for tuberculosis screening in Asian and African elephants, the seroprevalence of tuberculosis in the captive population was estimated to be nearly 16 per cent.[6] Seven pairs of elephants, where a seropositive elephant and a seronegative elephant are in 'trunks-on contact' for at least 1 yr, were identified. 'Trunks-on contact' was defined as the physical contact of the trunk of an elephant with the trunk or mouth or anus of another elephant. Three of the seven pairs had 'trunks-on contact' for more than 5 yr. *M. tuberculosis* was isolated from trunk wash culture on Lowenstein Jensen medium, once from two of the seven seropositive elephants. Our preliminary findings seem to suggest little evidence for elephant-to-elephant transmission of human tuberculosis, under the tropical climatic conditions in southern India.

Key words: Asian elephant, DPP® Vet TB Assay, *Elephas maximus*, *Mycobacterium tuberculosis*, spillover infection, tuberculosis

LITERATURE CITED

1. Abraham,D, Cheeran JV, Sukumar R, Mikota SK, Rao S, Ganguly S, Varma S. Health Assessment of captive Asian elephants in India with special reference to tuberculosis. In: Bangalore (India): Asian Elephant Research and Conservation Centre, A Division of Asian Nature Conservation Foundation; 2008. p.1-2.

2. Abraham D, Cork SC, Mundayoor S, Alex PC, Ganguly S. Identification of mycobacteria isolated from captive elephants and mahouts, project report submitted to Sea World and Busch Gardens Conservation Fund. Department of Ecosystem and Public Health, Faculty of Veterinary Medicine, University of Calgary; 2010. p. 1-26.

3. Behr MA, Gordon SV. Why doesn't *Mycobacterium tuberculosis* spread in animals? Trends in Microbiol. 2015; 23(1):1-2.

4. Gagneux S. Host-pathogen coevolution in human tuberculosis. Phil Trans R Soc B. 2012;367(1590):850-859.

5. Gagneux S, DeRiemer K, Van T, Kato-Maeda M, de Jong BC, Narayanan S, Nicol M, Niemann S, Kremer K, Gutierrez MC, Hilty M, Hopewell PC, Small PM. Variable host-pathogen compatibility in *Mycobacterium tuberculosis*. Proc Natl Acad Sci USA. 2006;103(8):2869-2873.

6. Greenwald R, Lyashchenko O, Esfandiari J, Miller M, Mikota S, Olsen JH, Ball R, Dumonceaux G, Schmitt D, Moller T, Payeur JB, Harris B, Sofranko D, Waters WR, Lyashchenko KP. Highly accurate antibody assays for early and rapid detection of tuberculosis in African and Asian elephants. Clin Vaccine Immunol. 2009;16(5): 605-612.

7. Mikota SK, Gairhe K, Giri K, Hamilton K, Miller M, Paudel S, Lyashchenko K, Larsen RS, Payeur JB, Waters WR, Greenwald R, Dumonceaux G, Vincent B, Kaufman GE. Tuberculosis surveillance of elephants (*Elephas maximus*) in Nepal at the captive-wild interface. Eur J Wildl Res. 2015;61(2):221-229.

8. Mikota SK, Maslow JN. Tuberculosis at the human-animal interface: an emerging disease of elephants. Tuberculosis. 2011;91(3):208-211.

9. Obanda V, Poghon J, Yongo M, Mulei I, Ngotho M, Waititu K, Makumi J, Gakuya F, Omondi P, Soriguer RC, Alasad S. First reported case of fatal tuberculosis in a wild African elephant with past human-wildlife contact. Epidemiol Infect. 2013;141(7):1476-1480.

10. Perera BVP, Salgadu MA, de S. Gunawardena GSP, Smith NH, Jinadasa HRN. First confirmed case of fatal tuberculosis in a wild Sri Lankan elephant. Gajah. 2014;41:28-31.

SUITABILITY OF THE ERYTHROCYTE MICRONUCLEUS TEST FOR ASSESSING GENOTOXICITY IN GREEN TURTLES (*Chelonia mydas*)

Cindy Braud, VM,[1]* Leandro Abreu da Fonseca, DVM, MS, PhD,[2] Fabrícia M. Girardi, DVM,[3] Fagundes Valeria,[3] Girardi F.M.,[4] and Batistotte Cecilia, DVM[5]

[1] Ecole Nationale Vétérinaire de Toulouse, Toulouse, Midi-Pyrénées, 31300, France; [2]Departamento de Veterinária, Universidade Federal de Viçosa, Viçosa, MG; [3]Departamento de Biologia Animal, Universidade Federal do Espírito Santo, Vitória, ES; [4]Escola de Veterinária, Universidade Federal de Minas Gerais, Belo Horizonte, MG; [5]Projeto TAMAR ICMBio/IBAMA

Abstract

The micronucleus assay is a test that highlights the occurrence of chromosome damage by assessing the presence of fragments or whole chromosomes (micronuclei) in the erythrocytes' cytoplasma.[3,4,6] The test allows the identification of increased mutation frequency in cells that are exposed to a variety of genotoxic agents.[5] Compared to other cytogenetic tests for screening of exposure to toxic and carcinogenic substances, the micronucleus test has some advantages including low cost and speed of analysis.[1,2] The aim of this study was to determine the incidence of chromosomal defects in erythrocytes of green turtles *Chelonia mydas.* One hundred forty turtles were sampled at two different sites: (1) a protected natural environment, Fernando de Noronha archipelago, where fibropapillomatous lesions are not observed (group 1; n = 34) and (2) a polluted area, the Victoria Coast, where papillomatosis occurs (group 2: papilloma free turtles; n = 66 and group 3: turtles with papillomatous lesions; n = 40). Turtles from the protected natural environment (group 1), showed a ten times lower number of micronuclei in erythrocytes (5,000 ± 7,000/µl) than the animals from group 2, from the polluted Victoria Coast (61,000 ± 52,000/µl). Furthermore, we observed that turtles with fibropapillomas (group 3) expressed a number of erythrocytes micronuclei twice higher (164,000 ± 63,000/µl) than turtles without fibropapillomatous lesions (group 2). These results suggest suitability of the erythrocyte micronuclei test as a biomarker of environmental changes and carcinogenic alterations in green turtles (*Chelonia mydas*).[7,8]

Key words: Biomarker, *Chelonia mydas,* environmental change, erythrocyte, green turtle, micronucleus test

ACKNOWLEDGMENTS

The authors would like to thank Fundação de Amparo à Pesquisa do Espírito Santo (FAPES) and Conselho Nacional de Desenvolvimento Científico e Tecnológico (CNPq) for their support.

LITERATURE CITED

1. Anderson ET, Harms C, Stringer EM, Cluse WM. Evaluation of hematology and serum biochemistry of cold-stunned green sea turtles (*Chelonia mydas*) in North Carolina, USA. J Zoo Wildl Med. 2011;42:247-255.

2. Andreani G, Santoro M, Cottignoli S, Fabbri M, Carpene E, Isani G. Metal distribution and metallothionein in loggerhead (*Caretta caretta*) and green (*Chelonia mydas*) sea turtles. Sci Total Environ. 2008;390:287-294.

3. Bonassi S, Znaor A, Ceppi M, Lando C, Chang WP, Holland N, Kirsch Volders M, Zeiger E, Ban S, Barale R, Bigatti MP, Bologesi C, Cebulska Wasilwskq A, Fabianova E, Fucici A, Hagmar L, Joksic G, Martelli A, Migllore L, Mirkova E, Scarfi MR, Zijno A, Norppa H, Fenech M. An increased micronucleus frequency in peripheral blood lymphocytes predicts the risk of cancer in humans. Carcinogenesis Advance Access. 2007;28:625-631.

4. Çavas T, Ergene-Gozukara S. Induction of micronuclei and nuclear abnormalities in *Oreochromis niloticus* following exposure to petroleum refinery and chromium processing plant effluents. Aquat Toxicol. 2005;74:264-271.

5. Ergene S, Çavas T, Çelik A, Koleli N, Kaya F, Karahan A. Monitoring of nuclear abnormalities in peripheral erythrocytes of three fish species from the Goksu Delta (Turkey): genotóxico damage in relation to water pollution. Ecotoxicol. 2007;16:385-391.

6. Fenech, M. In vitro micronucleus technique to predict chemosensitivity. Methods Mol Med. 2005;111:3-32.

7. Monserrat JM, Martinez PE, Geracitano LA, Amado LL, Martins CM, Pinho GL, Chaves IS, Ferreira-Cravo M, Ventura-Lima J, Bianchini A. Pollution biomarkers in estuarine animals: critical review and new perspectives. Comp Biochem Physiol C. 2007;146(1):221-234.

8. Wells PG, Depledge MH, Butler JN, Manock JJ, Knap AH. Rapid toxicity assessment and biomonitoring of marine contaminants-exploiting the potential of rapid biomarker. Marine Poll Bull. 2001;42(10):799-804.

ELECTROCARDIOGRAPHIC MONITORING IN SEMI-AQUATIC TURTLES USING SMARTPHONE EKG SOFTWARE (ALIVECOR®) AND COMPARISON TO CONVENTIONAL ELECTROCARDIOGRAPHY

Mariana Sosa, MVZ,[1]* Adriana Ducoing, M en E,[1] Luis Carrillo, MV,[2] Marco A. Benítez, MVZ,[3] Osvaldo Martínez,[3] MVZ, and Dulce María Brousset Hernández-Jauregui, PhD[1]

[1]National Autonomous University of Mexico, Mexico City, 04510, Mexico; [2]Zoofari Zoo, Morelos, 62652, México; [3]Africam Safari, Puebla, 75240, Mexico

Abstract

The diagnosis and management of cardiovascular diseases can be performed using electrocardiogram equipment (ECG) and heart monitors, but technical challenges limit its use in reptile species.[3-6] This study assessed a mobile phone application (Alivecor®, Alivecor Inc., San Francisco, CA 94108 USA) and conventional veterinary electrocardiography (BMECG30AV Carewell® Health Care, Shenzhen, China) in semi-aquatic turtles: red-eared slider (*Trachemys scripta elegans*) (n = 14), Meso-American slider (*Trachemys scripta venusta*) (n = 2), and Western pond turtle (*Actinemys marmorata*) (n = 4). These individuals were maintained under parenteral anesthesia with ketamine (Anesket Pisa Agropecuaria, Hidalgo, México; 50mg/kg i.m.) and midazolam (Relacum, Pisa, Jalisco, México; 1 mg/kg i.m.).

Traces obtained with both devices were morphologically and visually similar. Heart rate (HR), R-wave amplitude and duration were calculated. The Bland and Altman method was used to establish the level of agreement between both approaches.[1-2] The limits of agreement were: R-wave amplitude (-0.043, 0.0726 mV), R-wave duration (-0.03463, 0.05573 sec) and HR (-28.996, 21.82 beats per min). These wide limits suggested no correspondence in the values obtained by each of the two devices, despite the visual and apparent morphologic similarity. Traces were difficult to read in turtles measuring less than 16 cm (n = 3). More studies are needed to establish the novel software to guide the diagnosis of cardiac disease in reptiles, or to set numerical values for accurate measurements. However, it could be used as an easy access, inexpensive, and minimally invasive tool for cardiac monitoring in this taxon, particularly for field use.

Key words: *Actinemys marmorata*, Alivecor®, electrocardiography*, Trachemys scripta elegans*, *Trachemys scripta venusta*

ACKNOWLEDGMENTS

The authors thank the personnel at Zoofari Zoo and Africam Safari for providing all turtles for this study and their assistance with this residency project; all the doctors who helped during the procedures and Kathryn Gamble DVM, MS, Dip ACZM for her assistance in the developing and writing of this study.

LITERATURE CITED

1. Altman DG. Some common problems in medical research. In: Altman DG (ed.) Statistics for medical research. Chapman and Hall/CRC; 2007. p. 396-439.

2. Bland JM, Altman DG. Statistical methods for assessing agreement between two methods of clinical measurement. Int J Nurs Stud. 2010;47:931-936.

3. Holz RM, Holz P. Electrocardiography in anaesthetised red-eared sliders (*Trachemys scripta elegans*). Res Vet Sci. 1995;58:67-69.

4 Kik MJ, Mitchel M. Reptile Cardiology: A review of anatomy and physiology, diagnostic approaches, and clinical disease. Semin Avian Exot Pet. 2005;14(1):52-60.

5 Murray MJ. Cardiology. In: Mader DR, (ed.). Reptile medicine and surgery. St. Louis (MO): Saunders; 2006. p.181-195.

6 Schilliger L, Chai N, Chetboul V, Bonwitt J. Smartphone-based ECG Monitor: feasibility and applications in herpetological medicine. Proc Assoc Rept Amphib Vet; 2014. p.129-131.

HEALTH EVALUATION, PATHOGEN SCREENING AND HEMATOLOGIC VALUES IN FREE-RANGING TEXAS HORNED LIZARDS (*Phrynosoma cornutum*)

Michael McEntire, BS,[1]* Carlos R Sanchez, DVM, MSc,[2] Ashley Pich, BS, LVT,[2] Martin Zordan, MV,[3] Diane Barber,[2] Vicky Poole,[2] Nathan Rains,[4] Devin Erxleben,[4] J. Jill Heatley, DVM, Dipl ABVP, Dipl ACZM,[1] and Jim Wellehan, DVM, MS, PhD, Dipl ACZM, Dipl ACVM, Dipl ECZM[5]

[1]College of Veterinary Medicine and Biomedical Sciences, Texas A&M University, College Station, TX 77843 USA; [2]Fort Worth Zoo, Fort Worth, TX 76109 USA; [3]Latin American Association of Zoological Parks and Aquariums, Las Condes, Santiago, 7560758 Chile; [4]Texas Parks and Wildlife Department, Austin, TX 78744 USA; [5]College of Veterinary Medicine, University of Florida, Gainesville, FL 32610 USA

Abstract

The Texas horned lizard (*Phrynosoma cornutum*) is listed as a threatened species in Texas (federal category C2) because wild populations have been declining throughout much of their range in Northern Texas and Oklahoma. The causes of this decline are multifactorial, including changes in land use and the spread of invasive fire ants.[1,3] The potential effects of an infectious disease outbreak in this species are unknown as the prevalence of diseases or even basic health parameters, such as hematology, on this species have not been well studied.

As part of an interdisciplinary, multi-institutional and interdepartmental project, 49 free-ranging Texas horned lizards were captured in 4 different Texas locations for health evaluation and sample collection for pathogen screening. Fecal samples, oral and cloacal swabs, and blood samples were collected for most of the animals. Results revealed 42.8% of wild lizards exhibited some degree of internal parasitism; 74.3% of lizards were positive for at least one enteric pathogen in fecal culture. *Entamoeba* was the most commonly identified parasite (33.3%). The most common enteric bacteria cultured were *Corynebacterium* (33.3%), *Enterobacter* (25.6%), *Staphylococcus* (25.6%), *Escherichia* (17.9%), *Salmonella* (14.2%) and *Streptococcus* (12.8%). Several different *Salmonella* serovars were isolated. No individuals were found to be actively shedding Herpesviridae or Adenoviridae. Hematologic values were established as reference data for clinically normal Texas horned lizards. The described pathogen prevalence and hematologic parameters are the first attempt to gather information that could help to manage the species both in captivity and during translocation and captive-breeding and reintroduction projects for this charismatic species.[2]

Key words: Hematology, pathogen screening, *Phrynosoma cornutum*, Texas horned lizard

ACKNOWLEDGMENTS

The authors wish to thank Megan Baumer and Robyn Doege from the ectotherm department at the Fort Worth Zoo, John McEachern and Chip Ruthven from the Texas Parks and Wildlife Department, and Dean Williams from Texas Christian University for their assistance in field work. They also wish to thank the Fort Worth Zoo, Fresno Chaffee Zoo, Texas Parks and Wildlife Department, East Texas Herpetological Society, and backers on Experiment.com for financial support.

LITERATURE CITED

1. Allen CR, Epperson DM, Garmestani AS. Red imported fire ant impacts on wildlife: a decade of research. Am Midl Nat. 2004;152:88-103.

2. Griffith B, Scott JM, Carpenter JW, Reed C. Animal translocations and potential disease transmission. J Zoo Wildl Med. 1993;24(3):231-236.

3. Hencke SE. Baseline survey of Texas horned lizards, *Phrynosoma cornutum*, in Texas. Southwestern Nat. 2003;48(2):278-282.

Chlamydophila-ASSOCIATED ENCEPHALITIS IN A POPULATION OF HOUSTON TOADS (*Bufo houstonensis*): AN UPDATE ON THE OUTBREAK AND THE AMPHIBIAN NEUROLOGIC EXAM

Erin Berlin,[1]* Eric Snook, DVM, Dipl ACVP,[2] Fabiano Oliveira, DVM, Dipl ACVP,[3] Anibal G. Armien, DVM, MSc, PhD, Dipl ACVP,[4] Tyler Parker,[5] Colin Thompson,[5] Bernard Wolff, MS,[6] Paula Ciembor, DVM, PhD,[6] Branson Ritchie, DVM, PhD, Dipl ABVP (Avian), Dipl ECZM (Avian),[6] and Lauren L. Howard, DVM, Dipl ACZM[5]

[1]Western University of Health Sciences, College of Veterinary Medicine, 309 E. Second Street, Pomona, CA 91766 USA; [2]TVMDL Texas A&M Veterinary Medical Diagnostic Laboratory, College Station Laboratory, P.O. Box 3040, College Station, TX 77841 USA; [3]Antech Diagnostics, 6166 Imperial Loop Dr., College Station, TX 77845 USA; [4]University of Minnesota College of Veterinary Medicine, Veterinary Diagnostic Laboratory, 1333 Gortner Avenue, St. Paul, MN 55108 USA; [5]Houston Zoo, Inc. 1513 Cambridge Street, Houston, TX 77030 USA; [6]Infectious Diseases Laboratory, University of Georgia, Athens, GA 30602 USA

Abstract

The Houston Zoo cares for and breeds a captive assurance colony of endangered Houston toads (*Anaxyrus houstonensis*), and the eggs are released each spring to bolster declining wild populations. In 2012, significant numbers of Houston toads began presenting with notable neurologic disease. The condition was characterized through histopathology, electron microscopy, DNA sequencing and bacterial isolation as granulomatous encephalomyelitis due to *Chlamydia pneumoniae*. Although a consistent pre-mortem test for chlamydia-associated encephalitis (CAE) is not currently available, a combination of epidemiologic data, yearly physical exams, and euthanasia of sentinel toads has been used to control the spread and limit the mortality in the population. By increasing physical exams and monitoring of the toads, it has been possible to recognize signs of CAE earlier, and through this process, refine a basic neurologic exam. This exam assesses the presence of the following clinical signs: ataxia, abnormal posture, anisocoria and a slowed righting reflex. Treatment protocols for clinical CAE include a combination of antibiotics, antifungals and supportive care.

Using medical records and data from the past 5 yr, the index cases were traced to an outdoor toad enclosure in late 2011, which could indicate that the *C. pneumoniae* may have been originally transmitted to the toads from wildlife in the area. Current and future research is focused on ensuring the health of the wild and captive Houston toad populations by obtaining a pre-mortem test for CAE, increasing the specificity of the neurologic exam and looking for incidences of *C. pneumoniae* in the wild.

Key words: *Anaxyrus houstonensis*, Chlamydia-associated encephalitis, *Chlamydia pneumoniae*, Houston toad

MINIMAL INVASIVE HEART SURGERY IN ANURANS

Norin Chai, DVM, MSc, PhD, Dipl ECZM (ZHM),[1,2]* Céline Vivien, PhD,[2] Valérie Chetboul, DVM, PhD, Dipl ECVIM (Cardiology),[3] and Laurent Coen, PhD[2]

[1]Ménagerie du Jardin des Plantes, National Museum of Natural History, Paris, 75005 France; [2]Evolution des Régulations Endocriniennes UMR CNRS 7221 - Dpt RDDM, National Museum of Natural History, Paris, 75005 France; [3]Ecole Nationale Vétérinaire d'Alfort, Unité de Cardiologie d'Alfort, Centre Hospitalier Universitaire Vétérinaire d'Alfort, 94704 Maisons-Alfort France

Abstract

To study anuran capacity for cardiac regeneration, the feasibility of heart amputation by endoscopy was evaluated in adults. Coelioscopic pericardiotomy (CP) and a CP followed by a ventricle biopsy (CVB) were performed on 15 and 24 5-yr-old adult African clawed frogs (*Xenopus laevis*), respectively. Before surgery, all 39 frogs were first anesthetized with an injection of butorphanol (1 mg/kg intracoelomic), followed by an injection of meloxicam (0.4 mg/kg intracoelomic) and then induced for 10 min in buffered MS-222 (0.5 g/L). The surgeries were performed through a single paramedian incision with CO_2 insufflation (1.5 mm Hg) not exceeding 0.5 L/min. CP was achieved with a 1.3 mm endoscopic sharp scissors, single action jaws and CVB was achieved at the apex with a 1.7-mm endoscopic biopsy forceps. For CVB, the amputated fraction was about 4% of the whole ventricle volume. The coelomic membrane and the skin were closed in one layer with one or two interrupted sutures using monofilament nylon. All 39 frogs recovered from anesthesia without complication. Two of the 24 animals in the CVB group died within the first 24 hr from conditions believed to be related to iatrogenic trauma on the ventral vein but not on the heart surgery itself. The animals were euthanazed for research purposes on heart regeneration at 1, 2, 3, 6 and 9 mo postoperatively but all remain clinically healthy up to then.

In summary, minimal invasive heart surgery in adult anurans provides a useful method/technique to study the cardiac regenerative process in adult African clawed frogs. Furthermore, this study aims to provide pragmatic advice on how to conduct safe and effective endoscopic examinations and surgery in amphibians.

Key words: Amphibians, endoscopy, heart surgery, heart regeneration, *Xenopus laevis*

ARE OPIOIDS EFFECTIVE ANALGESICS IN SNAKES? FENTANYL EFFICACY, PHARMACOKINETICS, AND MU-OPIOID RECEPTOR MRNA EXPRESSION IN BALL PYTHONS (*Python regius*)

Kurt K. Sladky, MS, DVM, Dipl ACZM, Dipl ECZM (Herpetology),[1]* Rima Kharbush, BA,[2] Kate Hartzler,[2] Rebecca Kimyon, BS,[2] Sherry Cox, PhD,[3] Jyoti Watters, PhD,[2] Andrew Abbott, BS, BA,[1] and Stephen M. Johnson, MD, PhD[2]

[1]Dept. of Surgical Sciences and [2]Dept. of Comparative Biosciences, School of Veterinary Medicine, University of Wisconsin, Madison, WI 53706 USA; [3]College of Veterinary Medicine, University of Tennessee, Department of Biomedical and Diagnostic Sciences, Knoxville, TN 37996 USA

Abstract

Considering reptile pain and analgesia, snakes seem to be an enigma with respect to our ability to understand the efficacy of opioid analgesics.[1] The antinociceptive efficacy, respiratory effects, and pharmacokinetics associated with transdermal fentanyl application in ball pythons (*Python regius*) were evaluated in an incomplete, crossover study (analgesia; n = 16), complete crossover study (respiratory; n = 10), and in a fentanyl pharmacokinetic study (n = 6). Antinociceptive efficacy was assessed by applying infrared heat stimuli to the cranioventral surface of ball pythons, and thermal withdrawal latencies were measured at 0, 3, 6, 9, 24, and 48 hr after patch application in treated snakes (3 and 12 µg/hr fentanyl patch; Duragesic, Janssen Pharmaceuticals, Inc., Titusville, NJ) and controls. Mean thermal withdrawal latencies were not significantly altered from baseline or from time controls at 3-48 hr post-patch application. Breath frequency was measured using closed-chamber plethysmography at 0, 6, and 24 hr after patch application in unrestrained treated snakes (12 µg/hr fentanyl patch) and controls. Mean breathing frequency decreased from baseline by 23% and 41% at 24 and 48 hr, respectively ($P < 0.05$). Plasma fentanyl concentrations were elevated at 6, 24, and 48 hr after patch application. Mu-opioid receptor mRNA was quantified using reverse transcription polymerase chain reaction (RT-PCR) in the cortex, midbrain, brainstem, and cervical spinal cord of ball pythons (n = 7) and compared to levels in turtles (*Trachemys elegans scripta*; n = 10), a species, which is highly sensitive to mu-opioid agonist drugs.[2] There were no differences in mu-opioid mRNA levels in snakes and turtles in all four brain regions.

Key words: Analgesia, ball pythons, fentanyl, mRNA, respiration, snakes, turtles

LITERATURE CITED

1. Sladky KK, Kinney M, Johnson, SM. Analgesic efficacy of butorphanol and morphine in bearded dragons (*Pogona vitticeps*) and corn snakes (*Elaphe guttata*). J Am Vet Med Assoc. 2008;233:267-73.

2. Sladky KK, Miletic V, Paul-Murphy J, Kinney M, Dallwig R, Johnson SM. Analgesic efficacy and respiratory effects of butorphanol and morphine in turtles (Trachemys scripta). J Am Vet Med Assoc. 2007;230:1356-1362.

ANALGESIC EFFICACY OF TRAMADOL AND MORPHINE IN WHITE'S TREE FROGS (*Litoria caerulea*)

Jennifer C. Hausmann, DVM,[1]* Ashley Krisp, BS,[1] Stephen Johnson, MS, MD, PhD,[2] and Kurt Sladky, MS, DVM, Dipl ACZM, Dipl ECZM[1]

[1]Department of Surgical Sciences and [2]Department of Comparative Biosciences, School of Veterinary Medicine, University of Wisconsin-Madison, WI 53706 USA

Abstract

Published data are limited with respect to clinically-relevant pain perception and analgesia in amphibians, despite the fact that amphibians are maintained as companion animals, displayed in zoos and aquaria, and used extensively in research. The literature on amphibian analgesia has primarily focused on nociceptive pathways in northern leopard frogs (*Rana pipiens*)[4]; however, efficacy studies evaluating clinically-relevant antinociceptive drugs and dosages for amphibians are lacking.[1] The objective of this study was to assess the analgesic efficacy and safety of tramadol p.o. and morphine s.c., in White's tree frogs (*Litoria caerulea)*. It was hypothesized that tramadol and morphine would provide dose-dependent antinociception, as measured by a significant increase in hind limb withdrawal latencies after exposure to a noxious thermal stimulus by use of a standard, Hargreaves apparatus.[2,3] Two randomized, placebo controlled, complete cross-over studies were performed, with tramadol[a] orally administered at 15, 25, and 40 mg/kg and morphine[b] given s.c. at 5 and 10 mg/kg. Hind limb withdrawal latencies were measured for 72 hr. No adverse side effects or signs of sedation were noted, even with trial doses of 75 mg/kg tramadol p.o. and 40 mg/kg s.c. morphine. No differences in withdrawal latencies were detected between control and either opioid, except for an increase at 8 hr with 5 and 10 mg/kg s.c. morphine; however, this was not statistically significant. This study evaluated tramadol and morphine in White's tree frogs and found it to be safe, even at high doses, but was only suggestive of efficacy which was not statistically significant.

[a]Tramadol Hydrochloride, 50 mg tablet dissolved in water to create a suspension, Amneal Pharmaceaticals of NY, Hauppauge, NY 11788 USA
[b]Morphine Sulfate injection preservative free, 10 mg/ml, Westward Inc. Eatontown, NJ 07724 USA

Key words: Antinociception, Hargreaves apparatus, *Litoria caerulea,* morphine, tramadol, White's tree frogs

LITERATURE CITED

1. Duncan A. Reptile and amphibian analgesia. In: Miller RE, Fowler ME (eds.). Zoo and wild animal medicine, Volume 7, Current therapy. St. Louis (MO): Elsevier; 2012. p. 247-253.

2. Sladky KK, Kinney M, Johnson SM. Analgesic efficacy of butorphanol and morphine in bearded dragons (*Pogona vitticeps*) and corn snakes (*Elaphe guttata*). J Am Vet Med Assoc. 2008;233:267-273.

3. Sladky KK, Miletic V, Paul-Murphy J, Kinney M, Dallwig R, Johnson SM. Analgesic efficacy and respiratory effects of butorphanol and morphine in turtles (*Trachemys scripta*). J Am Vet Med Assoc. 2007;230:1356-1362.

4. Stevens CW, Klopp AJ, Facello JA. Analgesic potency of Mu and Kappa opioids after systemic administration in amphibians. J Pharmacol Exp Ther. 1994;269:1086-1093.

WILD AFRICAN ELEPHANT (*Loxodonta africana*) SEMEN ACROSS BORDERS: WHEN SANITARY REQUIREMENTS AND LEGAL COMPLIANCE CHALLENGE A GROUND-BREAKING PROJECT

Romain Potier, DVM,[1]* Paul Bartels, DVM,[2] Frank Goeritz, DVM,[3] Robert Hermes, DVM,[3] Barbara Baker, DVM,[4] and Thomas Hildebrandt, DVM, Dipl ECZM[3]

[1]FauneVet, F-44200 Nantes, France; [2]Department Nature Conservation, Tshwane University of Technology, Pretoria, South Africa; [3]Institute for Zoo and Wildlife Research (IZW), D-10315 Berlin, Germany; [4]Pittsburgh Zoo and PPG Aquarium, Pittsburgh, PA 15206 USA

Abstract

In 2009, an international team of experts launched the Frozen Dumbo Project to help prevent the decline of genetic diversity in captive African elephant (*Loxodonta africana*) populations. Semen samples from wild African elephant bulls were collected and frozen in 2009 and 2010 in the Republic of South Africa (RSA).[2,3] In 2010, the two batches of samples were imported from RSA into France. Since then, two births and one pregnancy have been achieved in Europe with imported frozen thawed semen.[2] Challenges for African elephant semen to be imported were firstly that the suit of health requirements refers to domestic animal species or species that are under some form of physical control, and secondly that there are no species-specific validated laboratory tests for some of the diseases. Furthermore, sensitivity of elephants to most contagious disease is still unknown. Due to the lack of a proper health risk assessment for wild African elephant semen, the French authorities issued a custom set of health requirements based on current health certificate requirements for bovine semen. The main issues addressed were the definition of the epidemiologic unit used for the certificate of origin and the lack of follow-up testing of the donors. Importing semen from the wild is a promising concept but regulatory agencies should be approached early in the planning process. Since the involved parties cannot be part of the health risk assessment, health authorities should be oriented toward experienced and open-minded specialists to perform this task.[1,4]

Key words: African elephant, disease risk assessment, import, *Loxodonta africana*, sanitary requirement, semen

ACKNOWLEDGMENTS

The authors would like to thank CatchCo Africa for the elephants capture, and First-STLC for the shipment of the liquid nitrogen tanks.

LITERATURE CITED

1. Cooper ME, Rosser AM. International regulation of wildlife trade: relevant legislation and organisations. Rev Sci Tech Off Int Epiz. 2002;21(1):103-123.

2. Hermes R, Saragusty J, Göritz F, Bartels P, Potier R, Baker B, Streich WJ, Hildebrandt TB. Freezing African elephant semen as a new population management tool. PLoS One 2013;8(3):e57616.

3. Hildebrandt TB, Hermes R, Saragusty J, Potier R, Schwammer HM, Balfanz F, Vielgrader H, Baker B, Bartels P, Göritz F. Enriching the captive elephant population genetic pool through artificial insemination with frozen-thawed semen collected in the wild. Theriogenology 2012;78:1398-1404.

4. Leighton FA. Health risk assessment of the translocation of wild animals. Rev Sci Tech Off Int Epiz. 2002;21(1):187-195.

AN OUTBREAK OF GOAT POX VIRUS IN NONDOMESTIC HOOFSTOCK AT AL WABRA WILDLIFE PRESERVATION

Wouter Pieters, DVM,[1]* Francois Le Grange, BSc, BVSc,[2] Abdi Arif, BVSc, MVSc,[2] Cromwell Purchase, MVSc, PhD,[2] Elizabeth du Plessis, BVSc, MMedVet,[3] Almero Oosthuizen, BSc,[4] and Essa Suleman, PhD[4]

[1]Oasis Park Fuerteventura, 35627 La Lajita, Fuerteventura, Spain; [2]Al Wabra Wildlife Preservation, Doha, Qatar; [3]IDEXX Laboratories, 0110 Pretoria, Republic of South Africa; [4]National Zoological Gardens of South Africa, 0001 Pretoria, Republic of South Africa

Abstract

A severe outbreak of goat pox virus (*Capripoxvirus*) occurred at the Al Wabra Wildlife Preservation (AWWP) in Qatar. Nearly 250 animals from 16 species of exotic ruminants (caprinae, antilopinae and hippotraginae) died over a 4-mo period. Despite biosecurity measures and herd vaccination, the disease spread across the facility in an east to west direction. Clinical symptoms varied over the course of the outbreak and differed from species to species. These included lethargy, recumbency, anorexia, fever, nasal and ocular discharge, diarrhea, skin nodules, fever and death. Some species proved to be more susceptible than others with high morbidity (90%) and mortality (85%) rates. Histologic lesions included lymphadenitis, hepatitis, hemorrhagic abomasitis, nodular dermatitis and pneumonia. Goat pox virus was confirmed using Polymerase Chain Reaction (PCR) and the detected strain was 99% identical to goat pox isolates from Kazakhstan.[3] Several cases were complicated with secondary bacterial infections. It is not clear whether capripox was the sole viral pathogen involved in this outbreak and results of investigations to identify other viruses are pending. Studies suggest that there is no strong evidence of a wildlife reservoir for capripoxviruses.[1] Apart from one report in an Arabian oryx (*Oryx leucoryx*),[2] capripoxvirus infection has not been previously reported in any of the species affected during this outbreak. This report describes the first case of goat pox infection in a wide range of exotic ruminants in a preservation center.

Key words: *Capripoxvirus*, exotic ruminants, goat pox, nodular dermatitis, nodular pneumonia

LITERATURE CITED

1. Babiuk S, Bowden TR, Boyle DB, Wallace DB, Kitching RP. Capripoxviruses: an emerging worldwide threat to sheep, goats and cattle. Transbound Emerg Dis. 2008;55(7):263-272.

2. Greta A, Gourreau JM, Vassart M, Wyers M, Lefevre PC. Capripoxvirus disease in an Arabian oryx (*Oryx leucoryx*) from Saudi Arabia. J Wildl Dis. 1992;28(2):295-300.

3. Tulman ER, Afonso CL, Lu Z, Zsak L, Sur JH, Sandybaev NT, Kerembekova UZ, Zaitsev VL, Kutish GF, Rock DL. The genomes of sheeppox and goatpox viruses. J Virol. 2002;76(12):6054-6061.

CENTERS FOR DISEASE CONTROL AND PREVENTION (CDC) REGULATIONS FOR IMPORTING NONHUMAN PRIMATES INTO THE UNITED STATES

G. Gale Galland, DVM, MS, Dipl ACVPM

Importations and Animal Contact Team, Division of Global Migration and Quarantine, National Center for Emerging and Zoonotic and Infectious Diseases, Centers for Disease Control and Prevention (CDC), Atlanta, GA 30329 USA

Abstract

The importation of nonhuman primates (NHPs) into the United States has been regulated by the Centers for Disease Control and Prevention (CDC) since the 1950s. Initially, NHPs could be imported for any reason, as long as they appeared healthy. In 1975, the regulations changed and NHPs could no longer be imported as pets; they could only be imported for science, education, or exhibition. According to the new regulations, to import an NHP, a person also had to register with CDC. Registration wasn't difficult, and almost everyone who applied to import an NHP was approved (approximately 100 individuals). CDC's regulations also mandated a 31-day quarantine at a registered facility, as well as three tuberculin skin tests using mammalian old tuberculin (MOT). The tuberculin skin test using MOT is the only test that is validated and approved by the United States Department of Agriculture (USDA) for the detection of tuberculosis in NHPs and is the official tuberculosis test that CDC requires for imported NHPs.

After an outbreak of Ebola Reston in a group of imported NHPs in 1989, the regulations were strengthened and CDC began to monitor incoming shipments and systematically inspect all CDC-registered NHP importers for compliance with biosecurity and biosafety requirements. As a result, most of the previously approved importer registrations were revoked and the number of CDC-registered importers decreased to around 25.

In 2013, CDC further revised the regulations. The current regulations now allow for the transfer of NHPs to zoos in the United States from an Association of Zoos and Aquariums (AZA)-accredited (or its equivalent) facilities outside of the United States. Zoos may transfer animals that have adequate medical records documenting both regular physical exams and tuberculin skin testing and avoid undergoing all of the requirements for quarantine of imported nonhuman primates. Preferably, physical exams and tuberculosis testing would have been done on a routine schedule, yearly or biennially. At a minimum, records should include three complete physical exams, including routine laboratory testing and three tuberculin skin tests. The receiving zoos must register with CDC and quarantine the imported NHPs according to their zoo policies. This change was made to help facilitate zoos with the transfer of NHPs that are important for preservation of a species and have been long-term residents in accredited facilities. In order for a zoo to register with CDC to import NHPs using the zoo-to-zoo transfer, they must provide the following:

- A completed registration/application form;
- A completed statement of intent that describes the number and types of NHPs intended for import during the registration period;
- The intended permitted purposes for which the NHPs will be imported;

- Updated written standard operating procedures that include all elements required for a zoo-to-zoo transfer;
- A copy of all federal, state, or local registrations, licenses, and/or permits; and
- A signed self-certification stating that the importer is in compliance with the regulations and agrees to continue to comply.

If a zoo requests to import NHPs from a non-accredited facility, or to import an NHP that does not have a good medical history, the zoo must meet all requirements to become a fully registered importer. These requirements are more extensive, and the zoo must have a designated, properly designed building for quarantine. The updated regulation can be found in Title 42, Code of Federal Regulations, Part 71, Subpart F. Section 71.53.

To date, very few animals have had adequate medical records and tuberculosis testing to allow for a zoo-to-zoo transfer.

Key words: Centers for Disease Control and Prevention, importation, nonhuman primate, quarantine, zoo-to-zoo transfer

ELEPHANT ENDOTHELIOTROPIC HERPESVIRUS (EEHV): A ZOO CLINICIAN'S SURVIVAL GUIDE

Lauren L. Howard, DVM, Dipl ACZM

Houston Zoo, Inc., Houston, TX 77584 USA

Abstract

For institutions with elephants, it is not a question of *if* elephant endotheliotropic herpesvirus (EEHV) will cause illness in a herd, but *when*. EEHV causes acute, often fatal hemorrhagic disease in young Asian elephants (*Elephas maximus*). For zoo veterinarians, this disease can be one of the most challenging and daunting aspects of caring for a breeding elephant herd at their institution. The zoo clinicians' best tools for managing EEHV are preparedness, vigilance, and an early, aggressive approach to treatment. Each elephant-owning institution should develop an EEHV Plan which includes methods of monitoring, treatment and necropsy, and should specifically include feasible means of famciclovir acquisition. Institutions with at-risk elephants (Asian elephants (*Elephas maximus*) aged 1-8 yr) should evaluate their elephants regularly, preferably weekly, by testing for EEHV viremia via quantitative polymerase chain reaction (qPCR) and through evaluation of complete blood cell counts (CBC). Routine PCR testing will detect EEHV viremia before clinical signs develop, and allow for early and aggressive treatment. Treatment should include supportive care as well as antiviral therapy, and should be accomplished with standing sedation if it is not possible through training alone. Establishing open lines of communication between the veterinary and elephant teams, and institutional support from administrators and public relations personnel is critical to the successful management of EEHV at any institution.

Key words: EEHV, elephant, Herpesvirus, famciclovir, viremia

Introduction

Elephant endotheliotropic herpesvirus (EEHV) causes acute, often fatal hemorrhagic disease in young Asian elephants (*Elephas maximus*).[13] For zoo veterinarians, this disease can be one of the most challenging and daunting aspects of caring for a breeding elephant herd at their institution. Based on February 2015 calculations, EEHV was the cause of 40% of deaths in all Asian elephants between 1 and 37 yr of age that were born in North America, making it the single greatest cause of death in this cohort.[8] EEHV has caused disease in African elephants (*Loxodonta africana*) as well, and more research is needed to better understand the epidemiology in this species.

The zoo clinicians' best tools for managing EEHV are preparedness, vigilance, and an early, aggressive approach to treatment. This presentation will hit the highlights of these areas below, while many more details and sample protocols can be found at the website: www.eehvinfo.org .

Healthy Asian and African elephants have been shown to shed several of their own species of EEHV virus as part of a natural infection cycle that has evolved over millions of years.[14,16,18,22] While exposure to EEHV appears to be a natural process, Asian elephants between 1 and 8 yr of age at are a high risk of developing an aberrant hemorrhagic disease (EEHV HD) associated with

EEHV infection.[20] Older Asian elephants and African elephants are also susceptible to EEHV HD, but with less documented frequency thus far. Asian elephants under human care in Europe and in several Asian range countries have succumbed to EEHV HD,[2,15,21] and deaths have been documented in wild Asian elephants as well.[10] EEHV is a global issue that we are also fighting at a very local level.

As of February 2016, there have been 32 cases of EEHV HD confirmed in Asian elephants born in North America since 1980. Nine of these elephants survived infection and 23 succumbed (one as recently as January 2016), leading to an overall mortality rate of 72%. It is hoped that, with more research into elephant immunity and EEHV, we may learn why some elephants survive primary exposure to EEHV, often without any clinical illness at all, and some elephants develop widespread and often fatal hemorrhagic disease. Until more is known about this aspect of the virus, the recommendations listed below represent the EEHV community's best attempts at increasing young elephant survival in face of the constant threat of EEHV.

EEHV Preparedness

All institutions housing elephants should establish an EEHV plan that outlines monitoring for viremia, treatment of ill animals, and necropsy guidelines, and highlights the supplies needed for each. Drug acquisition should be thought out ahead of time; famciclovir is the antiviral drug most often used to treat EEHV, and the amount of required to treat an elephant (15 mg/kg p.o. or rectally TID)[3] is not readily available on short notice. All protocols should be developed jointly with veterinary and elephant care teams, with support of key zoo administrators. Decision making strategies and communication tactics should be discussed ahead of time so that critical time is not wasted on long meetings when an elephant is ill. Preparation for EEHV can be a costly and time consuming process and requires the full cooperation of all stakeholders. The Houston Zoo runs yearly EEHV drills, as it does drills for other catastrophic events such as opioid exposures, animal escapes, and venomous snake bites.

A potentially overlooked hallmark of EEHV preparedness is to cultivate and maintain open lines of communication between the veterinarians and the elephant care team. This is critical to allow for bilateral flow of important information, as well to streamline the process of discussions and decisions that will be part of any EEHV case.

EEHV Vigilance

Historically we have seen that elephants die of EEHV HD rapidly, often within 24 hr of showing clinical signs of illness.[12,20] By the time the virus has caused enough internal damage for illness to be perceptible in these stoic, frequently inaccessible patients, the damage is often irreversible, even with treatment. Recent research has shown that elephants ill from EEHV HD are viremic up to 2 wk prior to the onset of clinical signs.[17] Recent clinical experience has shown that elephants with EEHV HD often demonstrate changes in their hemograms early in viremia, also prior to the onset of clinical signs.[1,5,6] The changes include mild to moderate leukopenia, particularly monocytopenia, and thrombocytopenia. These subtle changes are most notable when compared to the individual elephant's own complete blood cell counts (CBC) ranges, and can be overlooked when compared to more general elephant reference values.

Regular measurement of fecal bolus temperature, body weight, non-invasive blood pressure and heart rate, respiratory rate, and oral mucosa coloration are important steps in establishing normal value ranges for each elephant, which will allow for easy identification of subtle changes that can be a first clue to a more serious illness.[7]

The recommendation of the EEHV Advisory Group is to monitor at-risk elephants (1-8 yr old Asian elephants) routinely (weekly is ideal) for EEHV viremia via whole blood quantitative polymerase chain reaction (qPCR). This is the best way to detect EEHV HD early and allow for early, aggressive treatment. Additionally, the Houston Zoo measures CBC's of at-risk elephants weekly, which helps to establish individual reference ranges for key parameters (white blood cell count, monocytes, and platelets) and helps us identify subtle decreases that may be associated with early viremia. If at-risk elephants show any signs of abnormal behavior, including decreased appetite, changes in sleep patterns, lameness, or changes in mentation or training, blood is collected immediately for EEHV qPCR and CBC, even if this requires standing sedation to accomplish.

Early, Aggressive Treatment for EEHV

All ill young elephants should be considered as possible EEHV HD cases until proven otherwise by the results of whole blood qPCR testing. Treatment should be initiated rapidly and often before confirmation of EEHV qPCR results is possible. Famciclovir (FCV) is the antiviral most often used in North America and in Europe to treat EEHV HD, and acyclovir and ganciclovir have also been used. The efficacy of FCV against EEHV has not been proven. To date, however, there is no peer reviewed data available to establish that famciclovir **does not** have effect against EEHV.[9] Until proven otherwise, it remains best practice to treat EEHV HD cases with FCV. Pharmacokinetic data of FCV in Asian elephants is available.[3] Antivirals are only one aspect of treatment, and it is becoming apparent that supportive care is just as important, if not more so, in the management of an EEHV HD case.[5,6,20] Rectal fluids can be initiated immediately and have a striking ability to improve an elephant's hydration and demeanor. At the Houston Zoo, we have administered fresh and frozen-thawed elephant plasma, along with crystalloids, via IV boluses under standing sedation, every 2-3 days as indicated by clinical condition and CBC status. Antibiotics for secondary infections, anti-inflammatories (at low doses in well hydrated animals), and opioids have also been given to elephants with EEHV HD. Full details on treatment protocols can be found at www.eehvinfo.org, or by contacting the author.

When to treat an elephant with EEHV HD is as important as how to treat one. With weekly monitoring of CBC's and EEHV qPCR in at-risk elephants, the zoo clinician can identify a case of EEHV HD early, often prior to the onset of any visible clinical signs of illness. Treatment with FCV and fluid therapy should be instituted in cases with viral loads above 5,000 vge/ml and/or with rapidly increasing EEHV viral loads, and in any animal that has EEHV viremia combined with an abnormal CBC, even if the elephant appears clinically normal. Low level EEHV viremia should be monitored closely with serial whole blood qPCR and CBCs. It is important to note that most of the data collected thus far is based on experience with EEHV1A and EEHV1B, while interpretation of viral loads for EEHV4, EEHV3 and EEHV5 are not as well established.

Even conscientious monitoring and timely treatment cannot guarantee a successful outcome. Necropsy of an EEHV HD case is an important opportunity to gain more information on this devastating disease. Full necropsy guidelines are available on www.eehvinfo.org.

Future Directions

Though our understanding of EEHV has grown astronomically in the past 5 yr, there is still very much we do not know about this virus. Current research efforts of the Houston Zoo and Baylor College of Medicine are focused on T cell assays to better characterize the immune response and develop ways to measure vaccine response, as well as fine tuning EEHV HD treatment recommendations. Some headway is being made into understanding the elephant immune response, though there is much more to learn.[4,11,19] An ultimate goal of the EEHV community is to develop an EEHV vaccine to decrease the severity of clinical illness, if not eliminate illness altogether, but there is much work to be done before that is accomplished. Additionally, a better evaluation of the epidemiology and distribution of EEHV in North America, Europe, and Asian range countries is important to better understand the impact of this disease on wild and captive elephant populations. And finally, education of zoo professionals as well as the lay-public, by sharing our success and advances with EEHV, is critical to establishing public support for elephant institutions and EEHV-related research.

LITERATURE CITED

1. Atkins L, Zong JC, Tan J, Mejia A, Heaggans SY, Nofs SA, Stanton JJ, Flanagan JP, Howard L, Latimer E, Stevens MR, Hoffman DS, Hayward GS, Ling PD. Elephant endotheliotropic herpesvirus 5, a newly recognized elephant herpesvirus associated with clinical and subclinical infections in captive Asian elephants. J Zoo Wildl Med. 2013;44:136-134.

2. Bouchard B, Xaymountry B, Thongtip N, Lertwatcharasarakul P, Wajjwalku W. First reported case of elephant endotheliotropic herpesvirus infection in Laos. J Zoo Wildl. Med. 2014;45:704-707.

3. Brock AP, Isaza R, Hunter RP, Richman LK, Montali RJ, Schmitt DL, Koch DE, and WA Lindsey. Am J Vet Res. 2012;73:1996-2000.

4. Fuery, A, Rooney CM, Makedonas G, Howard LL, Ling PD. Detecting EEHV-specific T cell responses in Asian elephants. Proc 10th International Workshop for EEHV; 2015. p. 13.

5. Fuery A, Browning GR, Tan J, Long S, Hayward GS, Cox SK, Flanagan JP, Tocidlowski ME, Howard LL, Ling PD. Clinical infection of captive Asian elephants (*Elephas maximus*) with elephant endotheliotropic herpesvirus 4. J Zoo Wildl Med. 2016; In press.

6. Fuery A, Tan J, Peng R, Flanagan JP, Tocidlowski ME, Howard LL, Ling PD. Clinical infection of two captive Asian elephants (*Elephas maximus*) with elephant endotheliotropic herpesvirus 1B. J Zoo Wildl Med. 2016, In press.

7. Howard LL, Hofman DS, Stevens MR, Flanagan JP. Herd monitoring for elephant endotheliotrophic herpesvirus in captive Asian elephants (*Elephas maximus*). Proc. International Elephant and Rhino Conservation and Research Symposium; 2011. p. 26-27.

8. Howard LL. EEHV by the numbers: EEHV case definitions and the impact of EEHV on the captive Asian elephant (*Elephas maximus*) population in North America. Proc 9th International Workshop for EEHV; 2013. p. 8-11.

9. Howard LL. Penciclovir levels in Asian elephants undergoing famciclovir treatment for clinical EEHV viremia at the Houston Zoo. Proc 10th International Workshop for EEHV; 2015. p. 33-34.

10. Howard LL, Boonprasert K, Thitaram C, Stremme C, Oo ZM, Zachariah A, Luz S. Update on EEHV in Asian elephant (*Elephas maximus*) range countries: a report from the first Asian EEHV Strategy Meeting. Proc Am Assoc Zoo Vet; 2016. In press

11. Humphreys AF, Tan J, Peng RS, Benton SM, Qin X., Worley KC, Mikulski RL, Chow DC, Palzkill TG, Ling PD. Generation and characterization of antibodies against Asian elephant (*Elephas maximus*) IgG, IgM, and IgA. 2015. PLoS ONE 10(2): e0116318.

12. Kendall, R, Howard L, Masters N, Grant R. The impact of elephant endotheliotropic herpesvirus on the captive Asian elephant (*Elephas maximus*) population of the United Kingdom and Ireland (1995-2013). J Zoo Wildl Med. 2016, In press.

13. Richman LK, Hayward GS. Elephant herpesviruses. In: Fowler ME, Miller RE (eds.). Zoo and wild animal medicine, Volume 7, Current therapy. St. Louis (MO): Elsevier; 2012. p. 496-502.

14. Richman, LK, Zong JC, Latimer EM, Lock J, Fleischer RC, Heaggans SY, Hayward GS. Elephant endotheliotropic herpesviruses of EEHV1A, EEHV1B, and EEHV2 from cases of hemorrhagic disease are highly diverged from other mammalian herpesviruses and may form a new subfamily. J Virol. 2014; 88:13523-13546.

15. Sripiboon S, Tankaew P, Lungka G, Thitaram C. The occurrence of elephant endotheliotropic herpesvirus in captive Asian elephants (*Elephas maixmus*): first case of EEHV4 in Asia. J Zoo Widl Med. 2013;44:100-104.

16. Stanton JJ, Zong JC, Latimer E, Tan J, Herron A, Hayward GS, Ling PD. Detection of pathogenic elephant endotheliotropic herpesvirus in routine trunk washes from healthy adult Asian elephants (*Elephas maximus*) by use of a real-time quantitative polymerase chain reaction assay. Am J Vet Res. 2010;71:925-933.

17. Stanton J, JC Zong, C Eng, L Howard, J Flanagan, M Stevens, D Schmitt, E Wiedner, D Graham, RE Junge, MA Weber, M Fischer, A Mejia, J Tan, E Latimer, A Herron, GS Hayward, and PD Ling. Kinetics of viral loads and genotypic analysis of elephant endotheliotropic herpesvirus-1 infection in captive Asian elephants. J Zoo Wildl Med. 2013;44:42-54.

18. Stanton JJ, Nofs SA, Zachariah A, Kalaivannan N, Ling PD. Detection of elephant endotheliotropic herpesvirus infection among healthy Asian elephants (*Elephas maximus*) in South India. J Zoo Wildl Med. 2014;50:279-287.

19. Van den Doel P, Prieto VR, van Rossum-Fikkert SE, Schaftenaar W, Latimer E, Howard L, Chapman S, Masters N, Osterhaus AD, Ling PD, Dasjerdi A, Martina B. A Novel Antigen Capture ELISA for the Specific Detection of IgG Antibodies to Elephant Endotheliotropic Herpes Virus. BMC Vet Res. 2015;11:203-212.

20. Wiedner E, Howard L, Isaza R. Treatment of elephant endotheliotrophic herpesvirus (EEHV). In: Fowler ME, Miller RE (eds.). Zoo and wild animal medicine, Volume 7, Current therapy. St. Louis (MO): Elsevier; 2012. p. 537-543.

21. Zachariah A, Zong JC, Long SY, Latimer EM, Heaggans SY, Richman LK, Hayward GS. Fatal herpesvirus hemorrhagic disease in wild and orphan Asian elephants in Southern India. J Zoo Wildl Med. 2013; 49:381-393.

22. Zong JC, Latimer EM, Long SY, Richman LK, Heaggans SY, Hayward GS. Comparative genomic analysis of four elephant endotheliotropic herpesviruses, EEHV3, EEHV4, EEHV5, and EEHV6, from cases of hemorrhagic disease or viremia. J Virol. 2014;88:13547-13569.

THE IMPACT OF ELEPHANT ENDOTHELIOTROPIC HERPESVIRUS ON THE CAPTIVE ASIAN ELEPHANT (*Elephas maximus*) POPULATION OF THE UNITED KINGDOM AND IRELAND (1995-2013)

Rebecca Kendall, MSc, BSc,[1]* Lauren Howard, DVM, Dipl ACZM,[2] Nic Masters, MA, VetMB,[3] and Robyn Grant, PhD, BSc[4]

[1]Ontario Veterinary College, Guelph, ON N1G 2W1 Canada; [2]Houston Zoo, Inc., Houston, TX 77030 USA; [3]Zoological Society of London, London NW1 4RY UK; [4]Manchester Metropolitan University, Manchester M1 5GD UK

Abstract

Elephant endotheliotropic herpesvirus (EEHV) is one of the most devastating causes of mortality in captive Asian elephant (*Elephas maximus*) populations.[1-10] The impact of EEHV on the captive population of the United Kingdom and Ireland has not been assessed previously. EEHV hemorrhagic disease (EEHV HD) was found to be responsible for 29.6% of fatalities in Asian elephants born in captivity in this population during 1995-2013. Using medical records and postmortem data from six zoological institutions that currently, or have previously, housed a captive Asian elephant group, eight confirmed fatal EEHV cases are described. Although clinical signs may be associated with specific EEHV species, the swiftness of disease progression means that most body tissues are impacted 1-6 days following the presentation of visible clinical signs. Treatment is less likely to succeed after this point. We recommend that EEHV monitoring in the United Kingdom and Ireland should consist of conducting regular PCR analysis of whole blood samples from at-risk Asian elephants aged 1-8 yr in order for subclinical viremia to be identified early and treatment to be started before the appearance of visible clinical signs.

Key words: Asian elephant, case studies, elephant endotheliotropic herpesvirus, *Elephas maximus*, health monitoring, hemorrhagic disease

ACKNOWLEDGMENTS

The authors thank the numerous zoo professionals within the United Kingdom who gave their support, advice, and encouragement for this project. We are grateful to Mark Pilgrim for his guidance and support of the BIAZA Elephant Welfare Group. We would also like to thank Jonathan Cracknell, Lisa Bottell, Javier Lopez, Sarah Chapman, Jane Hopper, Zak Showell, and Akbar Dastjerdi for their time, advice, cooperation, and assistance in data collection.

LITERATURE CITED

1. Atkins L, Zong JC, Mejia A, Heaggans SY, Nofs SA, Stanton JJ, Flanagan JP, Howard L, Latimer E, Stevens MR, Hoffman DS, Hayward GS, Ling PD. Elephant endotheliotropic herpesvirus 5, a newly recognized elephant herpesvirus associated with clinical and subclinical infections in captive Asian elephants (*Elephas maximus*). J Zoo Wildl Med. 2013;44:136-143.

2. Fickel J, Richman LK, Montali R, Schaftenaar W, Göritz F, Hildebrandt TB, Pitra C. A variant of the endotheliotropic herpesvirus in Asian elephants (*Elephas maximus*) in European zoos. Vet Microbiol. 2001;82:103-109.

3. Garner MM, Helmick K, Ochsenreiter J, Richman LK, Latimer E, Wise AG, Maes RK, Kiupel M, Nordhausen RW, Zong JC, Hayward GS. Clinico-pathologic features of fatal disease attributed to new variants of endotheliotropic herpesviruses in two Asian elephants (*Elephas maximus*). Vet Pathol. 2009;46:97-104.

4. Latimer E, Zong J, Heaggans SY, Richman LK, Hayward GS. Detection and evaluation of novel herpesviruses in routine and pathological samples from Asian and African elephants: Identification of two new probosciviruses (EEHV5 and EEHV6) and two new gammaherpesviruses (EGHV3B and EGHV5). Vet Mircobiol. 2011;147:28-41.

5. Ossent P, Guscetti F, Metzler AE, Lang EM, Rubel A, Hauser B. Acute and fatal herpesvirus infection in a young Asian elephant (*Elephas maximus*). Vet Pathol. 1990;27:131-133.

6. Reid CE, Hildebrandt TB, Marx N, Hunt M, Thy N, Reynes JM, Schaftenaar W, Fickel J. Endotheliotropic elephant herpes virus (EEHV) infection: The first PCR-confirmed fatal case in Asia. Vet Q. 2006;28(2):61-64.

7. Richman LK, Montali RJ, Garber RL, Kennedy MA, Lehnhardt J, Hildebrandt T, Schmitt D, Hardy D, Alcendor DJ, Hayward GS. Novel endotheliotropic herpesviruses fatal for Asian and African elephants. Science. 1999;283(5405):1171-1176.

8. Richman LK, Montali RJ, Cambre RC, Schmitt D, Hardy D, Hildebrandt T, Bengis RG, Hamzeh FM, Shahkolahi A, Hayward GS. Clinical and pathological findings of a newly recognized disease of elephants caused by endotheliotropic herpesviruses. J Wildl Dis. 2000;36:1-12.

9. Sripiboon S, Tankaew P, Lungka G, Thitaram C. The occurrence of elephant endotheliotropic herpesvirus in captive Asian elephants (*Elephas maximus*): First case of EEHV4 in Asia. J Zoo Wildl Med. 2013;44:100-104.

10. Zachariah A, Zong J, Long SY, Latimer EM, Heaggans SY, Richman LK, Hayward G. Fatal herpesvirus hemorrhagic disease in wild and orphan Asian elephants in Southern India. J Wildl Dis. 2013;49:381-393.

NEW QUANTITATIVE POLYMERASE CHAIN REACTION ASSAYS TO DETECT ELEPHANT ENDOTHELIOTROPIC HERPESVIRUS 1A, 1B, AND 4 IN ASIAN ELEPHANTS (*Elephas maximus*)

Taylor A. Pursell, BS,[1]* Angela Fuery, PhD,[2] Jie Tan, BS,[2] Lauren Howard, DVM, Dipl ACZM,[3] and Paul D. Ling, PhD[2]

[1]Texas A&M College of Veterinary Medicine, College Station, TX 77845 USA; [2]Department of Molecular Virology and Microbiology, Baylor College of Medicine, Houston, TX 77030 USA; [3]Houston Zoo Inc., Houston, TX 77030 USA

Abstract

Elephant endotheliotropic herpesviruses (EEHVs) can cause a fatal hemorrhagic disease in Asian and African elephants (*Elephas maximus* and *Loxodonta africana*).[1,2] There are quantitative polymerase chain reaction (qPCR) tests that can detect all seven known EEHVs (1A, 1B, 3, 4, 5, and 6) in mucosal secretions, tissue isolates, and blood samples[3]; however, current tests were unable to distinguish between EEHV 3 and 4 or 1A and 1B. To address these inadequacies, new qPCR assays to specifically detect EEHV 1A, 1B, and 4 were generated and validated. Each assay was specific for its EEHV target when tested against known banked samples from past EEHV cases. Unlike conventional PCR, qPCR assays give veterinarians an estimate of viral loads providing another method to monitor disease progression and effectiveness of treatments. In addition, these tests used in conjunction with previously published qPCR assays provide a same day method of characterizing even subclinical EEHV events in elephants.

The new EEHV1A and 1B assays were then used to characterize an 8-wk, low-level EEHV1 viremic event in a young Asian elephant. This particular viremia was EEHV1A in origin and occurred 1 yr before the same elephant experienced a clinical EEHV1B infection. These new qPCR assays allowed us to provide additional evidence that EEHV1A and 1B do not provide cross protective immunity. It also suggests that the ability to determine the etiology of a juvenile elephant's viremias, even if they are subclinical, will provide veterinary and keeper staff with valuable information which may affect treatment decisions.

Key words: Asian elephant, elephant endotheliotropic herpesvirus 1A, elephant endotheliotropic herpesvirus 1B, elephant endotheliotropic herpesvirus 4, *Elephas maximus*, qPCR

ACKNOWLEDGMENTS

The authors would like to thank the zoological institutions for providing control and archived samples for this study. Support for this study was provided by the Houston Zoo. Taylor Pursell was supported by the AVMA/AVMF second opportunity summer research scholarship.

LITERATURE CITED

1. Richman LK, Montali RJ, Garber RL, Kennedy MA, Lehnhardt J, Hildebrandt T, Schmitt D, Hardy D, Alcendor DJ, Hayward GS. Novel endotheliotropic herpesviruses fatal for Asian and African elephants. Science. 1999; 283:1171-1176.

2. Richman LK, Hayward GS. Elephant Herpesviruses. In: Miller RE, Fowler ME (eds.). Zoo and wild animal medicine, Volume 7, Current Therapy. St. Louis (MO): Elsevier; 2012. p. 496-502.

3. Stanton JJ, Nofs S, Peng R, Hayward GS, Ling PD. Development and validation of quantitative real-time polymerase chain reaction assays to detect elephant endotheliotropic herpesviruses-2, 3, 4, 5, and 6. Journal of Virological Methods [Internet]. 2012. [cited 2015 November 28].

CORRELATION BETWEEN SERUM AND URINARY CORTISOL LEVELS AND SHEDDING OF ELEPHANT ENDOTHELIOTROPIC HERPESVIRUS (EEHV) 1,3,4 AND 5 IN CALVES AND ADULT ASIAN ELEPHANTS (*Elephas maximus*) PRE- AND POST-ARRIVAL OF A NEW BULL ELEPHANT

Carlos R Sanchez, DVM, MSc,[1]* Tarren Wagener, MS,[1] Don Nevitt,[1] Erin Latimer,[2] and Janine Brown, PhD[3]

[1]Fort Worth Zoo, Fort Worth, TX 76110 USA; [2]Center for Animal Care Sciences, Smithsonian Conservation Biology Institute, National Zoological Park, Washington, DC 20008 USA; [3]Smithsonian Conservation Biology Institute, National Zoological Park, Front Royal, VA 22630 USA

Abstract

Elephant endotheliotropic herpesvirus (EEHV)-hemorrhagic disease, with an 85% mortality rate, is considered a serious disease threat to elephants both in the wild and in captivity.[3] Recently, researchers have looked into the relationship between husbandry and other individual factors and EEHV occurrence and EEHV1 shedding.[1,2] The effect of the stress hormone cortisol and EEHV shedding when a new adult male elephant was added to an established elephant herd was evaluated. Weekly serum and urine samples were collected from two calves (<2-yr-old male and female) and three adult (>15-yr-old females) elephants, and urine samples from a resident adult bull for 3 wk before and 4 wk after the new elephant's arrival. Trunk washes were collected at the same time from the calves and female elephants. Urinary and serum cortisol levels were measured by validated immunoassays. Trunk washes were evaluated for EEHV1, 3/4 and 5 levels using qPCR. Results indicate that the male calf was shedding EEHV5 throughout the 7-wk study, with a peak shortly after arrival of the new bull. In contrast, the female calf was shedding EEHV1 for the entire 7 wk, but exhibited the highest vge/rxn values before the arrival of the bull. The other elephants showed very low levels of EEHV1 in some of their samples but no EEHV 3 or 4. Preliminary evaluation of serum and urinary cortisol did not show a direct correlation with EEHV shedding. Although two adult elephants showed "spikes" on their urinary cortisol, the elevations were observed on both pre and post new elephant arrival samples.

Key words: Asian elephant, EEHV shedding, elephant endotheliotropic herpesvirus, *Elephas maximus,* serum cortisol*,* urinary cortisol

ACKNOWLEDGMENTS

The authors would like to thank the elephant keepers and supervisors, and veterinary hospital staff at the Fort Worth Zoo for their assistance in this project. The project was funded by the Fort Worth Zoo.

LITERATURE CITED

1. Bennett L, Dunham S, Yon L, Chapman S, Kenaghan M, Purdie L, Tarlinton R. Longitudinal study of Asian elephants *Elephas maximus*, indicates intermittent shedding of elephant endotheliotropoic herpesvirus 1 during pregnancy. Vet Rec Open. 2015;2:e000088.

2. Howard LL, Deem SL, Isaza R. Disease risk management in Asian elephants (*Elephas maximus*) in North America: establishing the basics of the epidemiology of EEHV-1. Proc Am Assoc Zoo Vet; 2013. p. 136.

3. Wiedner E. Proboscidea. In: Miller RE, Fowler ME (eds.). Zoo and wild animal medicine, Volume 8. St Louis (MO): Elsevier Saunders; 2015. p. 517-532.

DEVELOPMENT OF FREEZE-DRIED PLATELET-DERIVED HEMOSTATIC AGENTS AS A NOVEL TREATMENT FOR ELEPHANT ENDOTHELIOTROPIC HERPESVIRUS HEMORRHAGIC DISEASE

Suzan Murray, DVM, Dipl ACZM,[1] Sabrina McGraw, DVM, PhD, Dipl ACVP,[1]* Dennis Schmitt, DVM, PhD,[2] Tim Walsh, DVM, Dipl ACVP,[3] Lauren Howard, DVM, Dipl ACZM,[4] Carlos Sanchez, DVM, MSc,[5] and Erin Latimer, MSc[6]

[1]Smithsonian Global Health Program, Smithsonian National Zoological Park and Conservation Biology Institute, Washington, DC 20008 USA; [2]International Elephant Foundation, Azle, TX 76098 USA; [3]Department of Pathology, Smithsonian National Zoological Park and Conservation Biology Institute, Washington, DC 20008 USA; [4]Houston Zoo, Houston, TX 77030 USA; [5]Fort Worth Zoo, Fort Worth TX 76110 USA; [6]National Elephant Herpesvirus Laboratory, Smithsonian National Zoological Park and Conservation Biology Institute, Washington, DC 20008 USA

Abstract

Elephant endotheliotropic herpes virus (EEHV) is the leading cause of death of young captive Asian elephants (1-15 yr old).[6] Clinical disease involves severe fulminant hemorrhagic disease (EEHV HD) and often rapid mortality.[1] In the 20 yr since the index case reported at the Smithsonian Institution's National Zoological Park, much has been learned about the disease, but effective treatment remains elusive.[1, 4] Antiviral therapies have demonstrated limited efficacy but are often cost prohibitive.[4] To date, treatment primarily consists of supportive care. Use of whole blood and concentrated blood-derived products have been applied as method to control the extensive hemorrhage associated with viral hemorrhagic fevers.[3] In particular, platelets have been shown to play a critical role in the survival of gravely ill patients.[3] Acute thrombocytopenia is a poor prognostic indicator in many hemorrhagic diseases, including EEHV HD.[5] Therapeutic replacement of circulating platelets may provide a means to withstand thrombocytopenic crisis. Platelet products for use in severe hemorrhage have a short shelf life (5 days), and are therefore not feasible for elephant care facilities. However, novel technologies are available to produce freeze-dried platelet-derived hemostatic agents (FDPDHAs), which are platelet products that can be stored at ambient temperature for 24-36 mo and be reconstituted within minutes.[2] Through a collaboration with Cellphire Inc., FDPDHAs will be produced from Asian elephant blood and eventually made available for potential use in critically ill elephants through a collaborative network of elephant care facilities.

Key words: Elephant endotheliotropic herpesvirus, *Elephas maximus*, FDPDHA, hemorrhagic disease, herpesvirus, platelet

ACKNOWLEDGMENTS

The authors would like to thank the member zoos and Ringling Bros. Center for Elephant Conservation for their collaboration on this project.

LITERATURE CITED

1. Hayward, GS. Conservation: Clarifying the risk from herpesvirus to captive Asian elephants. Vet Rec. 2012; 170(8):202-203.

2. Ho D, Orser CS, Rudolph AS, Moskowitz K, and Dee J. Methods for preparing freeze-dried platelets, compositions comprising freeze-dried platelets, and methods of use. 2013. U.S. Patent No. 8,486,617. Washington, DC: U.S. Patent and Trademark Office.

3. Kabra, S. K., Jain, Y., Tripathi, P., Singhal, T., Broor, S., Dar, L., & Seth, V. (1998). Role of platelet transfusion in dengue hemorrhagic fever. Indian pediatrics, 35, 452-454.

4. Richman LK, Montali RJ, Garber RL, Kennedy MA, Lehnhardt J, Hildebrandt T, Schmitt D, Hardy D, Alcendor DJ, Hayward GS. Novel endotheliotropic herpesviruses fatal for Asian and African elephants. Science. 1999; 283(5405), 1171-1176.

5. Vanderschueren, S, De Weerdt, A, Malbrain, M, Vankersschaever, D, Frans, E, Wilmer, A, & Bobbaers, H. Thrombocytopenia and prognosis in intensive care. Critical care medicine. 2000; 28(6), 1871-1876.

6. Zachariah A, Zong JC, Long SY, Latimer EM, Heaggans SY, Richman LK, Hayward GS. Fatal herpesvirus hemorrhagic disease in wild and orphan Asian elephants in southern India. J Wildl Dis. 2013 Apr;49(2):381-93. doi: 10.7589/2012-07-193.

REPRODUCTIVE MANAGEMENT: APPROACHES TO CHOOSING CONTRACEPTIVES AND DIAGNOSING INFERTILITY

Mary Agnew, PhD,[1]* Yedra Feltrer, MSc, MRCVS,[2] Dalen Agnew, DVM, PhD, Dipl ACVP,[3,7] Bruce Christensen, DVM, MS, Dipl ACT,[4] Linda Penfold, PhD,[5] and Anneke Moresco, DVM, PhD[6,7]

[1]AZA Reproductive Management Center, Saint Louis Zoo, Saint Louis, MO 63110 USA; [2]EGZAC and Zoological Society of London, Regent's Park, London NW1 4 RY, UK; [3]College of Veterinary Medicine, Michigan State University, East Lansing, MI 48824 USA; [4]University of California, Davis School of Veterinary Medicine, Davis, CA 95616 USA; [5]South-East Zoo Alliance for Reproduction and Conservation, Yulee, FL 32097 USA; [6]Denver Zoo, Denver, CO 80205 USA; [7]Reproductive Health Surveillance Program, Michigan State University/Denver Zoo

Abstract

Animal population sustainability is recognized as a major challenge facing zoos around the world. Reproductive rates in many managed programs result in negative growth rates and fail to meet targets for gene diversity. Sound reproductive management is key to animal programs reaching both demographic and genetic goals. In recognition of the importance of more focused reproductive research and management in addressing population sustainability, the Association of Zoos and Aquariums (AZA) has expanded the scope of the Wildlife Contraception Center. The new AZA Reproductive Management Center will continue to conduct research and produce recommendations for contraceptive use, but in its expanded role will also coordinate research and implementation of methods to improve reproductive rates. Included in that approach will be a focus on prevention, diagnosis and treatment of infertility.

Reproductive management strategies vary by region, influenced by traditional and cultural values regarding animals. In the U.S., and increasingly in other regions of the world, complex pedigree analysis is used to generate breeding recommendations. For animals not recommended to breed, options include primarily separation of sexes and reversible contraception. Permanent sterilization is generally reserved for older animals that have already made a genetic contribution to the population.

In response to growing interest in contraception as an alternate management option in Europe, the European (now EAZA) Group for Zoo Animal Contraception (EGZAC) was formed in 2008. Coordination with the AZA program, beginning with a similarly structured database of contraceptive use, allows the groups to share information and expertise, mutually strengthening their analyses and programs. The major difference between the regions is the availability of certain contraceptive products.

Retrospective studies by Munson and her colleagues in the 1990s and 2000s revealed serious pathology associated with the use of progestin-based contraceptive products in felids and canids.[5,7,9-11] Equally important, some of these studies documented that the occurrence of some lesions may not be related to contraceptives.[2,5,6] The tissue and life history information analyzed

in those studies was submitted to the Reproductive Health Surveillance Program (RHSP) by collaborating zoo veterinarians around the U.S. and Canada, highlighting the value of these archived samples. The RHSP archive now includes more than 2,800 cases and continues to be used to extend the studies to other taxa[4] treated with progestins and with other contraceptive products.

Ante-mortem histologic analysis is also a critical component of our ongoing survey of prevalence of endometrial hyperplasia (EH), which uses transcervical biopsy (TCB) as a diagnostic tool. This technique is valuable because it does not require surgery, yet permits diagnosis of early stages of endometrial hyperplasia, which cannot be diagnosed with ultrasound.[3] Results from our own analysis of canid populations, combined with reports from other taxa, point to EH and other endometrial abnormalities as potential causes of infertility in many females.[1,12] A common risk factor for these abnormalities across taxa is not reproducing regularly, something we call "Use It or Lose It."[12] When considering that delayed first reproduction carries even more risk of infertility in some species, a more fitting admonition might be "Breed Early and Often." With TCB, early detection at minimum could explain why a pair was failing to reproduce, so alternative plans could be formulated for those individuals, or at best treatment to restore fertility might be possible.

In contrast to the current standard approach of just reassigning new partners for pairs that fail to reproduce, identifying the cause would allow a more proactive approach to addressing the actual problem. A more holistic approach to diagnosing the point(s) of failure, which examines all the phases and factors in the reproductive process, is needed. Such an approach is most successful when a team approach, involving keepers, curators, and nutritionists, as well as veterinarians, is used, bringing together all relevant information on the case.[8] Inclusion of a reproductive specialist in the team, together with techniques such as long-term hormone monitoring, ultrasound examination and semen collection and assessment can help confirm or eliminate potential causes of infertility. The Infertility Workshop in 2014 produced two diagnostic reference tools: a Checklist for Clinical History and a Decision Tree for assessing infertility, available on our webpage (www.stlzoo.org/contraception).

The need to reproduce frequently to establish and maintain fertility introduces other concerns regarding effects on gene diversity, demography and production of surplus individuals. Culling would be the simple answer in some regions, but cultural sensitivities require a different approach in the U.S. and some other countries. The response has been to propose Lifetime Reproductive Planning for each female, mapping out at birth when and how often she should reproduce to make her genetic contribution to the population while maintaining fertility as long as needed. Collaborator, population geneticist Kathy Traylor-Holzer, is developing a model to test the effects of various reproductive scenarios on gene diversity and population size.

The hope is that the AZA and EAZA zoo veterinary community will contribute to the Sustainability Initiative by incorporating fertility diagnosis in their practice at their respective institutions.

Key words: Contraception, infertility, reproduction, reproductive pathology

LITERATURE CITED

1. Asa CS, Bauman KL, Devery S, Zordan M, Camilo GR, Boutelle S, Moresco, A. Factors associated with uterine endometrial hyperplasia and pyometra in wild canids: Implications for fertility. Zoo Biol. 2014;33:8-19.

2. Chassy LM, Gardner IA, Plotka ED, Munson L. Genital tract smooth muscle tumors are common in zoo felids but are not associated with melengestrol acetate contraceptive treatment. Vet Pathol. 2002;39:379-385.

3. Christensen BW, Schlafer DH, Agnew DW, Kozlowski C, Asa CS. Diagnostic value of transcervical endometrial biopsies in domestic dogs compared with full-thickness uterine sections. Reprod Domest Anim. 2012;47:342-46.

4. French SJ, Moresco A., Agnew DW 2013. The effects of contraceptives on the reproductive tract of female otters (*Lutrinae*). Proc Am Assoc Zoo Vet; 2013. p. 120.

5. Harrenstien LA, Munson L, Seal US, American Zoo And Aquarium Association Mammary Cancer Study Group. Mammary cancer in captive wild felids and risk factors for its development: A retrospective study of the clinical behavior of 31 cases. J Zoo Wildl Med. 1996;27:468-476.

6. Kazensky CA, Munson L, Seal US. The effects of melengestrol acetate on the ovaries of captive wild felids. J Zoo Wildl Med. 1998;29:1-5.

7. Moresco A, Munson L, Gardner IA. Naturally occurring and melengestrol acetate associated reproductive tract lesions in zoo canids. Vet Pathol. 2009;46:1117-1128.

8. Moresco A., Penfold LM. Failure ro reproduce, who's invited? Proc Am Assoc Zoo Vet; 2014. p. 57.

9. Munson L, Gardner IA, Mason RJ, Chassy LM, and Seal, US. 2002. Endometrial hyperplasia and mineralization in zoo felids treated with melengestrol acetate contraceptives. Vet Pathol. 2002;39:419-427.

10. Munson L, Moresco A, Calle PP. Adverse effects of contraceptives. In: Asa CS, Porton IJ (eds.). Wildlife Contraception: Issues, Methods, and Application. Baltimore (MD): Johns Hopkins University Press; 2005. p. 66-82.

11. Munson L., Stokes JE, Harrenstien LA. Uterine cancer in zoo felids on progestin contraceptives. Vet Pathol. 1995;32:578.

12. Penfold LM, Powell D, Traylor-Holzer K, Asa CS. "Use it or lose it": characterization, implications, and mitigation of female infertility in captive wildlife. Zoo Biol 2014;33:20-28.

PROGRESS IN UNDERSTANDING REPRODUCTIVE DISEASE IN SOUTHERN STINGRAYS (*Dasyatis americana*)

Natalie D. Mylniczenko, DVM, MS, Dipl ACZM,[1]* Jennifer Wyffels, PhD,[2] and Linda M. Penfold, PhD[2]

[1]Disney's Animals, Science and Environment, Bay Lake, FL 32830 USA; [2]South-East Zoo & Aquariums for Reproduction & Conservation, Yulee, FL 32097 USA

Abstract

Elasmobranchs are susceptible to human disturbances because of their late age to maturity and slow reproductive output. In the last two decades they have experienced enormous population declines. Stingrays are a popular species with many aquariums still acquiring them from the wild. A large cystic ovary and fluid engorged uterus are signs of what is now defined as a reproductive disease in rays that causes anorexia, lethargy and in many cases leads to death. Previous research has demonstrated that the problem is widespread, with 72% of females diagnosed as having moderate to severe abnormal ovarian and uterine pathology. The initial hypothesis was that elevated estrogens (>10,000 pg/ml) were linked to reproductive disease. A comprehensive and systematic review of steroid hormones and reproductive disease in 52 captive and 33 free ranging rays has since shown that circulating estradiol or progesterone (specific metabolites were not evaluated) is not correlated with reproductive disease ($P > 0.05$) and that similar concentrations are found in females with normal reproductive anatomy. Continued research into causal agents of reproductive disease is now focusing on thyroid hormones (T3 and T4) and iodine. Preliminary data shows captive rays have higher circulating T3, but not T4, than free ranging rays. Iodine is similarly elevated in captive but not free ranging rays. Improved understanding of stingray reproductive biology will allow the development of better treatments. In the case of many non-domestic and endangered species where basic reproductive knowledge is still lacking, the systematic collection and objective review of data allows the veterinarian to pursue evidence based treatments. In the interim, maintaining stingrays as a breeding group is recommended, as single gender housed animals appear to be more at risk for development of disease. The ability of aquariums to manage reproductive disease and maintain ray health will increase their longevity and allow reproduction, ultimately contributing to the conservation of the species by reducing offtake pressure on wild populations.

Key words: *Dasyatis americana*, reproductive disease, southern stingray

ULTRASONOGRAPHY AND ENDOSCOPY AS A METHOD OF ASSESSING EMBRYO DEVELOPMENT IN EGGS OF PORT JACKSON SHARKS (*Heterodontus portusjacksoni*)

Nuno Pereira, DVM,[1]* Hugo David, DVM,[2] Ana Jarego, BSc,[1] Patrícia Rocha, BMarSc, MSc,[1] Ana Ferreira, BMarSc, MSc,[1] and Elsa Santos, BSc, MSc[1]

[1]Oceanário de Lisboa, Lisboa 1990-005, Portugal, [2]Vetset-Hospital Veterinário, Palmela 2950-298, Portugal

Abstract

Port Jackson shark (*Heterodontus portusjacksoni*), an annual breeding oviparous shark is found in southern Australia.[2,3] In captivity, *Heterodontus* spp. assisted-hatching must be performed due to the absence of pre-hatching egg capsule erosion that is observed in the wild.[1] Since 2011, seven eggs have been assessed weekly using ultrasonography and endoscopy to evaluate embryo vitality and development and also to determine time of hatch. Standard ovoscopy with light is not feasible due to the egg capsule opacity; therefore, ultrasonography and endoscopy procedures were performed in eggs immersed in water and recorded as still images and videos. Embryos were visible at 31 days post oviposition. Yolk sac height measurements were the best indicator for assisted-hatching scheduling. Height of the yolk decreased from around the 8th to the 11th mo. At hatching time, yolk height was an average of 1.67 mm. Egg hatching time ranged from 307 to 432 days (10-14 mo). Late stage embryos were also observed by endoscopy using the two respiratory slits on the extremities of the eggs. Endoscopy provided embryo vitality assessment and was important to confirm the final size of the yolk sac. All seven sharks that hatched were able to swim and breathe without any problem. They have all thrived well: the oldest is 32 mo old as of February 2016. Ultrasonography and endoscopy can be used as safe methods to assess embryo development in Port Jackson sharks and provide an efficient method to follow the yolk sac dimensions and determine the correct timing for assisted hatching.

Key words: Captive breeding, egg, endoscopy, *Heterodontus portusjacksoni,* Port Jackson shark*,* ultrasonography

ACKNOWLEDGMENTS

The authors thank Warren Spencer (Artis Zoo, Amsterdam, Netherlands) for advice on *Heterodontus* spp. assisted-hatching procedures, Siemens Portugal for offering the ultrasound equipment, Jardim Zoológico de Lisboa, Portugal and Stortz for providing the endoscopy equipment and the staff at Oceanário de Lisboa for the work and dedication which made this study possible.

LITERATURE CITED

1. Dral AJ, Du Bois A, Schuurman M, Platvoet D, Bruins E. Captive breeding of *Heterodontus francisci* and its problems. Bull Inst Océanogr Monaco. 2004;77(1445):65-71.

2. Huveneers C, Simpfendorfer C. *Heterodontus portusjacksoni*. The IUCN Red List of Threatened Species [Internet] 2015: e.T39334A68625721. Downloaded on 29 November 2015. Available from http://www.iucnredlist.org/

3. Rodda KR, Seymour RS. Functional morphology of embryonic development in the Port Jackson shark *Heterodontus portusjacksoni* (Meyer). J Fish Biol. 2008;72:961-984.

CHEMICAL CASTRATION AND AGGRESSION CONTROL IN IMPALA (*Aepyceros melampus*) USING ZEUTERIN™

Deidre K. Fontenot, DVM[1]*and Linda M Penfold, PhD[2]

[1]Disney's Animals, Science and Environment, Bay Lake, FL 32830 USA; [2]South-East Zoo & Aquariums for Reproduction & Conservation, Yulee, FL 32097 USA

Abstract

Breeding groups of antelope under managed care are usually comprised of one breeding male and multiple females. However, surplus males are often managed as bachelor groups, which can be problematic due to intra/interspecific aggression. Options for contraception and aggression control in male hoofstock species are limited. GnRH does not down regulate LH/ testosterone; while progestin has variable effects on aggression control with questionable down- regulation of semen production for contraception. Castration and vasectomy require surgery which can prove difficult for larger herds. In contrast, Zeuterin™ (zinc gluconate neutralized by arginine, Irvington, NY, 10533 USA), an intra-testicular injectate, causes irreversible fibrosis, disrupting spermatogenesis without completely eliminating testosterone, thus preserving some secondary sexual characteristics. This study investigated impala (*Aepycerus melampus*) at 6-8 mo of age following intra-testicular injection of 0.15 +/- 0.1 ml/cm^3 testicular volume Zeuterin™ (Group 1, n = 3) using canid dosing and 0.31 +/- 0.24 ml/cm^3 testicular volume (Group 2, n = 3) using twice the canid dosing. Body weight, testicular measurements and semen and sperm assessments, and horn and neck morphometrics were collected pre-treatment and 6 mo post-treatment. Body weights increased in all individuals. Testicular measurements changed in both groups from small evenly-sized to larger asymmetric testes in 2/3 males in both groups. Mean testicular volume increased from 11.3 ± 1.6 cm^3 to 26.3 ± 4.8 cm^3. No spermic ejaculates were obtained for any of the prepubertal males. Six months later, low numbers of morphologically abnormal spermatozoa (3 and 4×10^6 sperm/ml, 49% and 16% abnormal morphology) were detected in 2/3 males in Group 1, but azoospermic ejaculates were obtained in group 2. Behavioral observations noted reduced aggression and mounting behavior in both groups and reduced inter-species aggression in the mixed exhibits. Results demonstrate a useful non-surgical tool to contracept and reduce aggression in impala males and may be appropriate for other antelope species.

Key words: *Aepyceros melampus*, castration, impala

THINK PINK: COMBINING CULINARY AND VETERINARY EXPERIENCES FOR SUCCESSFUL CHILEAN FLAMINGO (*Phoenicopterus chilensis*) HAND-REARING EFFORTS

Kathryn C. Gamble, DVM, MS, Dipl ACZM, Dipl ECZM (ZHM)[1]* and Sunny Nelson, BS[2]

[1]Veterinary and [2]Animal Care Departments, Lincoln Park Zoo, Chicago IL 60614 USA

Abstract

With 2015 presenting US poultry production several avian influenza outbreaks, a commercial impact of increased fresh egg prices and reduced inventory for processing to shelf-stable formulations was observed. In this same year, Lincoln Park Zoo had planned its inaugural Chilean flamingo (*Phoenicopterus chilensis*) breeding and hand-rearing program. The primary captive formulae available for this species are heavily egg-based.[1-3] In prior veterinary and curatorial experiences, use of non-powdered egg blends was expected with marked complications for this novice feeding team, and for the chicks. Primarily, this concern would be attributed to inconsistent blending of whole eggs as a smooth, but not homogenous, formula which contributes to feeding tube clogging, and potential aspiration sequelae with leaking tubes.

In advance of the chicks' hatching, culinary collaboration was utilized to identify novel equipment to the restaurant and molecular gastronomy experience. The selected instrument (Paco-Jet , Advanced Gourmet, Greensboro, NC 27419 USA) processes food within a stainless steel cylinder that is frozen to -8ºF (-22ºC); the outcome is a "snow" of fine particles that essentially melt to an entirely liquefied product. This process was trialed with a published formula of whole cooked eggs and cooked egg yolks immersed in generic corn oil, water, and tocopherol (Emcelle, Mazuri Animal Nutrition, St. Louis, MO 63166 USA) prior to freezing. The result was considered extremely easy to pass through feeding tubes; caused essentially no obstructions; and produced such a homogenous product that increased weight gains caused reduced formulae volumes on several days for the five chicks hand-reared.

The Paco-Jet is an easily operated and maintained piece of equipment within a zoo kitchen. Although the initial expense for purchase is an impact, no consumables are part of the processing, and all can be sanitized between uses. It can produce similar texture as described for this effort for any hand-rearing or supplemental feeding formulae, whether protein- or plant based.

Key words: Chilean flamingo, formulae, hand-rearing, Paco-Jet, *Phoenicopterus chilensis*

ACKNOWLEDGMENTS: The entire Chilean flamingo hand-rearing team within both Bird and Veterinary departments are commended for their efforts in this successful effort.

LITERATURE CITED

1. Brown C, King C (eds.). Flamingo husbandry guidelines: a joint effort of the AZA and EAZA in cooperation with WWT. [Internet]. 2015 [cited 2015 August]; Available from http://aviansag.org/Husbandry/Unlocked/Care_Manuals/Flamingo%20Husbandry%20Guidelines.pdf

2. Dierenfeld ES, Macek M, Snyder T, Vince M, Sheppard C. A simple and effective egg-based hand-rearing diet for flamingos. In: Clauss M, Fidgett A, Janssens G, Hatt J-M, Huisman T, Hummel J, Nijboer J, Plowman A (eds.). Zoo animal nutrition, vol 4. Germany: Filander Verlag; 2009. p. 37-46. Available from http://szb.org.br/blog/conteudos/bibliografias/08-nutricao/a-simple-and-effective-egg-based-hand-rearing-diet-for-flamingos.pdf

3. Shannon P. Flamingos. In: Gage L, Duerr R (eds.). Hand-rearing birds. Ames (IA): Blackwell Publishing; 2007. p. 97-103.

EFFECT OF ROUTINE HANDLING AND TRANSPORTATION ON HEMATOLOGIC VALUES AND PLASMA CORTICOSTERONE IN HISPANIOLAN AMAZON PARROTS (*Amazona ventralis*)

Anna McRee, DVM,[1]* Thomas N. Tully, DVM, MS, Dipl ABVP (Avian), Dipl ECZM (Avian),[2] Javier G. Nevarez, DVM, PhD, Dipl ACZM, Dipl ECZM (Herpetology),[2] Hugues Beaufrere, DMV, PhD, Dipl ACZM, Dipl ABVP (Avian), Dipl ECZM (Avian),[3] Melanie Ammersbach, DVM,[3] Stephen D. Gaunt, DVM, MS, PhD, Dipl ACVP,[2] Rory G. Fuller, BS,[4] and Michael Romero, MS, PhD[4]

[1]Nashville Zoo at Grassmere, Nashville, TN 37211 USA; [2]Department of Veterinary Clinical Sciences, Louisiana State University School of Veterinary Medicine, Baton Rouge, LA 70803 USA; [3]Ontario Veterinary College, University of Guelph, Guelph, ON N1G2W1 Canada; [4]Department of Biology, Tufts University, Medford, MA 02155 USA

Abstract

Increased glucocorticoids cause a characteristic "stress leukogram" in mammalian taxa.[1] It is assumed that avians exhibit a similar response, but to date there have been no controlled studies to correlate serial endogenous corticosterone levels to hematologic values. An established flock of 18 Hispaniolan Amazon parrots (*Amazona ventralis*) was used as a model in a cross-over study. The treatment group was subjected to the stress of transport, restraint, and common clinical procedures with serial blood samples collected at 20-min intervals (80 total) for hematology and corticosterone levels; the control group was sampled at the same intervals. Longitudinal data analysis was performed with linear mixed modeling. For all hematologic analytes, the baseline value had a significant positive effect on subsequent values (all $P < 0.001$). The WBC, heterophil counts, eosinophil counts, and H:L ratio increased over time in the treatment group whereas it remained stable in the control group ($P = 0.016$, $P < 0.001$, $P < 0.001$, $P = 0.02$ respectively for the time × treatment effect). Lymphocyte absolute counts decreased over time, although not significantly; the decrease was significant for the relative lymphocyte count in the treatment group. Monocytes and basophils were not significantly altered. The treatment group had a higher mean corticosterone level overall than the control group by approximately 60% ($P = 0.008$). The mean corticosterone level also increased over time in both groups by 3-4 fold ($P < 0.001$) by 20 min then plateaued. These results demonstrate that some significant hematologic changes may arise with routine handling and transportation of birds and should be accounted for in hematologic interpretation of cell counts.

Key words: *Amazona ventralis,* avian hematology, corticosterone, Hispaniolan Amazon parrot, stress leukogram

LITERATURE CITED

1. Davis AK, Maney DL, Maerz JC. The use of leukocyte profiles to measure stress in vertebrates: a review for ecologists. Funct Ecol. 2008;22:760-772.

STRESS INFLUENCE ON PLASMA PROTEIN ELECTROPHORESIS IN TWO ANSERIFORM SPECIES

Antoine Leclerc, DVM,[1]* Baptiste Mulot, DVM,[1] Alice Brunet, DVM,[1] and Yannick Roman, DVM, PhD[2]

[1]ZooParc de Beauval, 41110 Saint-Aignan, France; [2]Le Parc de Clères, 76690 Clères, France

Abstract

The objective of this study was to evaluate the effects of stress, as measured by total heterophil + eosinophil counts (THECs) and plasma corticosterone (PC),[1,3-7] on plasma protein electrophoresis (PPE), a valuable diagnostic tool,[2,8] in two Anseriform species.

Ten red-breasted geese (*Branta ruficollis*), and eight Hawaiian geese (*Branta sandvicensis*) were admitted into quarantine at Beauval Zoo (To). Two days later, all were examined as part of routine quarantine procedures and blood was collected. THECs were performed using a Malassez hemocytometer after a 1/200 dilution with an eosinophil dilution liquid containing B phloxin. PPE, as well as total protein and PC dosages, were performed on heparin-lithium plasma.

At To+20 days, all animals were similarly restrained, examined, and sampled. Pododermatitis lesions were identified on 4 red-breasted geese, and only birds without lesions were included for statistical analysis.

For each individual, THECs and PC values were sorted by value (lower or higher) independently from the day of sampling. Wilcoxon's signed rank tests showed no significant differences between lower and higher values of THECs for any of the PPE fractions. Higher values of corticosterone were associated with higher values of prealbumin, but none of the other fractions were significantly different. Spearman's rank correlation coefficient showed that THECs and PC were not correlated, suggesting possible differences in kinetics between these stress markers.

Results did not show significant alterations of electrophoresis patterns associated with stress as measured with THECs and PC. They also highlight the complexity of precisely assessing acute and chronic stress in Anseriformes.[1,4-7]

Key words: Anseriformes, corticosterone, electrophoresis, hematology, stress

ACKNOWLEDGMENTS

The authors would like to thank Caroline Berder and Gladys Beaudoin from LDH Vet Lab, ONIRIS, 44307 Nantes, for performing the corticosterone and total protein assays, as well as the vet technicians of Beauval for their help during the procedures.

LITERATURE CITED

1. Bedanova I, Voslárová E, Večerek V, Pišteková V, Chloupek P. Haemotological profile of broiler chickens under acute stress due to shackling. Acta Vet Brno. 2007;76:129-135.

2. Cray C, Tatum L. Application of protein electrophoresis in avian diagnostic testing. J Avian Med Surg. 1998;12:4-10.

3. Grieninger G, Hertzberg KM, Pindyck J. Fibrinogen synthesis in serum-free hepatocyte cultures: stimulation by glucocorticoids. Proc Natl Acad Sci. 1978;75(11):5506-5510.

4. Gross WB, Siegel PB. Long-term exposure of chickens to three levels of social stress. Avian Dis. 1980;25(2):312-325.

5. Gross WB, Siegel HS. Evaluation of the Heterophil/Lymphocyte ratio as a measure of stress in chickens. Avian Dis. 1983;27(4):972-979.

6. Minozzi G, Guéméné D, Couty M, Gourichon D, Minvielle F, Pinard-van der Laan MH. Circulating corticosterone reaction to restraint and adrenocorticotropin hormone administration in White Leghorns selected for immune response traits. Poult Sci. 2008;87:2225-2230.

7. Vleck CM, Vertalino N, Vleck D, Bucher TL. Stress, corticosterone, and heterophil to lymphocyte ratios in free-living Adélie penguins. The Condor. 2000;102:392-400.

8. Werner LL, Reavill DR. The diagnostic utility of serum protein electrophoresis. Vet Clin North Am Exot Anim Pract. 1999;2(3):651-662.

TREATMENT OF SECONDARY BRODIFACOUM TOXICOSIS IN A CAPTIVE ANDEAN CONDOR (*Vultur gryphus*)

Kira Hydock, BS,[1]* Camille DeClementi, VMD, Dipl ABT, Dipl ABVT,[2] and Pilar Fish, DVM[3]

[1]University of Pennsylvania School of Veterinary Medicine, Philadelphia, PA 19104 USA; [2]ASPCA Animal Poison Control Center, Urbana, IL 61802 USA; [3]The National Aviary, Pittsburgh, PA 15212 USA

Abstract

Brodifacoum is a common second generation anticoagulant rodenticide employed worldwide; however, there is a risk of secondary brodifacoum intoxication to carnivores in the area.[1] A 28-yr-old female Andean condor (*Vultur gryphus*) presented with weakness and vomiting 1 day after her mate died from suspected brodifacoum poisoning. Given the history, a prophylactic treatment of 0.2 mg/kg vitamin K_1 BID, single-dose 0.2 ml vitamin B complex, 10 mg/kg enrofloxacin s.i.d., and single-dose 0.012 mg/kg selenium/vitamin E, all i.m., was prescribed.[a-d] After three days of no response to treatment and declining packed cell volume and total protein levels, the decision was made to perform a transfusion utilizing donor blood from bald eagles (*Haliaeetus leucocephalus*) and Steller's sea eagles (*Haliaeetus pelagicus*) housed at The National Aviary. Pre-procedure medications included topical lidocaine at the catheter site, and 10 mg/kg i.m. vitamin K_1, 2 mg/kg i.m. diphenhydramine, and 4 mg/kg i.m. dexamethasone.[a,e-g] Anesthesia was forgone due to inherent risks and the bird's already-weakened state. Donor blood was transfused via a 25-gauge catheter into the medial metatarsal vein at a rate of 2 ml/min. Hyporexia and vomiting following transfusion prompted the addition of 1 mg/kg famotidine i.m. to the post-transfusion treatment plan of 5 mg/kg vitamin K_1 b.i.d., single-dose 0.2 ml vitamin B complex, 15 mg/kg enrofloxacin s.i.d., single-dose 0.06 mg/kg selenium/vitamin E, all i.m., and 180 ml subcutaneous fluids.[a-d,h,i] Treatment continued for 4 mo with tapering doses of vitamin K_1.

[a]Veda-K1® Injection, VEDCO, Inc., St Joseph, MO 64507 USA
[b]©Neogen Corporation, Lansing, MI 48912 USA
[c]Baytril®, ©Bayer HealthCare, Indianola, PA 15051 USA
[d]Bo-Se, Intervet/Merck Animal Health, Madison, NJ 07940 USA
[e]Lidocaine Hydrochloride Jelly, USP 2%, Akorn, Inc., Lake Forest, IL 60045 USA
[f]Benadryl®, West-Ward Pharmaceuticals, Eatontown, NJ 07724 USA
[g]Dexaject SP, Butler Schein Animal Health of Henry Schein, Dublin, OH 43017 USA
[h]Famotidine Injection, USP 200 mg/20 ml (10 mg/ml), Westward, Eatontown, NJ 07724 USA
[i]2.5% Dextrose with 0.45% NaCl, Abbot Laboratory, Abbott Park, IL 60064 USA

Key words: Andean condor, brodifacoum, second generation anticoagulant rodenticide, *Vultur gryphus*

ACKNOWLEDGMENTS

The authors would like to extend their appreciation to The National Aviary for their sponsorship of this presentation.

LITERATURE CITED

1. Eason CT, Spurr EB. Review of the toxicity and impacts of brodifacoum on non-target wildlife in New Zealand. NZ J Zool. 1995;22:371-379.

DEVELOPMENT OF A qPCR FOR *Atoxoplasma* DIAGNOSIS IN PASSERINE BIRDS

Jennifer A. Landolfi, DVM, PhD, Dipl ACVP,[1]* Michael Adkesson DVM, Dipl ACZM,[2] Timothy Snyder,[2] and Karen A. Terio, DVM, PhD, Dipl ACVP[1]

[1]Zoological Pathology Program, University of Illinois, Maywood, IL 60153 USA; [2]Chicago Zoological Society's Brookfield Zoo, Brookfield, IL 60513 USA

Abstract

The protozoal infection, atoxoplasmosis, is a significant cause of death in nestling and fledgling passerine birds impacting captive breeding and reintroduction programs. Antemortem diagnostics lack sensitivity leading to empirical anti-protozoal therapy despite questionable efficacy. The study goal was to develop a real-time quantitative PCR assay to screen blood, feces and tissue for *Atoxoplasma* sp. DNA. Real-time PCR (qPCR) primers and fluorescent-tagged MGB probe targeting the large subunit (28s) ribosomal RNA gene were designed with an assay efficiency of 94% and sensitivity of less than one dsDNA copy. To determine test sensitivity and specificity, primers and probe were then used to screen postmortem fresh and formalin-fixed paraffin embedded tissue samples from passerine birds with confirmed atoxoplasmosis (n = 14), as well as other tissues infected with phylogenetically similar protozoa. Assessment of clinical utility was achieved via examination of whole blood and fecal samples (n = 44) from live passerines. All positive results were confirmed by sequence analysis. The qPCR identified *Atoxoplasma* sp. DNA in postmortem tissues from 23/26 birds including 14/14 birds with histologically confirmed infection (100% sensitivity) as well as 9/12 birds that lacked observable intramononuclear cell organisms. The assay was also shown to amplify *Eimeria* sp. DNA; however, sequence analysis confirmed no passerine cases were positive for *Eimeria* sp. For tested clinical samples, blood and/or feces were positive in 17/44 birds; in 2/38 birds, both feces and blood contained detectable *Atoxoplasma* sp. DNA. Because fecal shedding and blood mononuclear phases of infection are intermittent, sampling strategies to enhance diagnosis are being evaluated.

Key words: *Atoxoplasma* sp., blood, feces, passerine, qPCR, tissue

ACKNOWLEDGMENTS

The authors wish to thank Nadia Ahmed for technical assistance, the animal care staff at the Chicago Zoological Society's Brookfield Zoo for collection of blood and fecal samples and pathologists with the University of Illinois Zoological Pathology Program and Veterinary Diagnostic Laboratory for collection of post-mortem samples used in this study. This study was funded, in part, by a grant from the Chicago Board of Trade Endangered Species Fund.

RETROSPECTIVE STUDY OF PROVENTRICULAR ACUARIID SPIRURIDIASIS IN CAPTIVE PSITTACINE BIRDS WITH PROLIFERATIVE PROVENTRICULAR DISEASE

Carles Juan-Sallés, LV, Dipl ACVP,[1]* Michael M. Garner, DVM, Dipl ACVP,[2] Nuhacet Fernández, LV,[3] Andrés Montesinos, LV,[4] Jorge Rosell, LV,[1] Mikel Sabater, LV,[3] María Ardiaca, LV,[4] and Chris H. Gardiner, DVM, PhD, Dipl ACVP[5]

[1]Noah's Path, Elche (Alicante), 03203 Spain; [2]Northwest ZooPath, Monroe, WA 98272 USA; [3]Loro Parque Fundación, Puerto de la Cruz (Santa Cruz de Tenerife), 38400 Spain; [4]Centro Veterinario Los Sauces, Madrid, 28010 Spain; and [5]Joint Pathology Service, Dept. of Veterinary Pathology, Silver Spring, MD 20910 USA

Abstract

Proventricular spiruridiasis usually caused by *Dispharynx* has been occasionally reported in psittacine birds.[1-3] This retrospective study of the pathology records of Northwest ZooPath (1994 to 2015) and Noah's Path (2008 to 2015) revealed 45 cases of proliferative proventriculitis with intralesional acuariid nematodes in psittacine birds, of which 32 were included in this abstract. These involved almost exclusively Australian species (particularly lorikeets/lories) and only one American species (one blue and gold macaw [*Ara ararauna*]). Age range for affected animals was 1-16 yr. Clinical evidence of gastric disease included regurgitation, proventricular or gastrointestinal dilatation, and hematochezia, but most birds were found dead with no premonitory signs. Grossly, the most frequent lesions consisted of proventricular dilatation and thickening with excessive mucus and one to multiple polypoid masses in the mucosa, gastrointestinal haemorrhage, and pale organs; nematodes were noted in the mucus or attached into the polyps in a few parrots. Microscopically, severe diffuse proliferative to adenomatous proventriculitis (adenomatous polyps) with intralesional nematodes consistent with acuariid spirurids was noted in all birds based on the egg morphology and the cuticular cordons. In a few cases, the parasites were identified as *Dispharynx*. In a bluebonnet (*Psephotus haematogaster*), a proventricular hemangiopericytoma was found underlying the proventriculitis. According to these findings and previous reports in other species, acuariid spirurid nematodes appear to be primary pathogens in psittacine birds and are often associated with severe proliferative proventriculitis and proventricular adenomatous polyps with gastric bleeding. The occurrence of proventricular hemangiopericytoma, previously unreported in proventricular spiruridiasis, is interesting because the spirurid *Spirocerca lupi* is known to cause sarcomas in the oesophagus of dogs. The occurrence of disease almost exclusively in Australian psittacine species in this case series suggests the possibility of geographic/evolutionary factors in host-parasite interaction and disease resistance.

Key words: Acuariid spirurid, lorikeet, proliferative proventriculitis, proventricular dilatation, psittacine bird, *Trichoglossus*

ACKNOWLEDGMENTS

The authors would like to thank the following Institutions for contribution of cases and providing details on their animal records and clinical histories: The Audubon Nature Institute, Columbus Zoo, Gladys Porter Zoo, Henry Doorly Zoo, Indiannapolis Zoo, Nashville Zoo, Oregon Zoo, San Antonio Zoo, Santa Barbara Zoo, Sedgwick

County Zoo, The Palm Beach Zoo at Dreher Park, and Zoo Miami. Liz Post/Cathy Minogue and Christie Buie (Northwest ZooPath) are acknowledged for data retrieval and Institutional contact information, respectively.

LITERATURE CITED

1. Churria CD, Spinsanti E, Origlia J, Marcantoni H, Piscopo M, Loyola MH, Petruccelli M. *Dispharynx nasuta* (Nematoda:Acuariidae) infection causing proventricular lesions and death in three captive rosellas (Psittaciformes:Psittacidae). J Zoo Wildl Med. 2011;42:164-165.

2. González-Hein G, Fredes F, Kinsella M, Larenas J, González-Acuña D. New reports of helminthes in captive exotic psittacine birds in Chile. Arch Med Vet. 2012;44:87-91.

3. Raymond JT, Miller CL, Garner MM. Adenomatous proliferative proventriculitis (APP) in captive birds. Proc Am Assoc Zoo Vet; 2002. p. 94-95.

OUTCOME OF TIBIOTARSAL FRACTURES IN SMALL BIRDS: 87 CASES FROM FIVE INSTITUTIONS

Louden Wright, DVM,[1]* Christoph Mans, Dr med vet, Dipl ACZM,[1] Grayson Doss, DVM,[1] Geoff Olsen, DVM, Dipl ABVP (Avian),[2] Brian Speer, DVM, Dipl ABVP (Avian), Dipl ECZM,[2] Gerd Britsch, Dr. med. Vet.,[3] J. Jill Heatley, DVM, Dipl ACZM, Dipl ABVP (Avian),[4] Jane Christman, DVM,[4] and Michael Jones, DVM, Dipl ABVP (Avian)[5]

[1]University of Wisconsin Veterinary Teaching Hospital, Madison, WI 53706 USA; [2]The Medical Center for Birds, Oakley, CA 94561 USA; [3]Vogel und Reptilienpraxis Dr Britsch, 76139 Karlsruhe, Germany; [4]Texas A&M College of Veterinary Medicine and Biomedical Sciences, College Station, TX 77845 USA; University of Tennessee College of Veterinary Medicine, Knoxville, TN 37996 USA

Abstract

Tibiotarsal fractures are a common presentation in small bird species and anecdotally have been reported to carry a good prognosis with proper repair, such as external coaptation.[1-3] For this retrospective study, the medical records of five institutions were reviewed for tibiotarsal fractures diagnosed in birds weighing < 200 g. Eighty-seven cases met the inclusion criteria. Cockatiels (*Nymphicus hollandicus*) (24/87) and budgerigars (*Melopsittacus undulates*) (20/87) were the most common species. The median body weight of the birds included was 64 g (range: 10-182 g). The majority of fractures were mid-diaphyseal (46/87) and closed (72/87). A tape splint, alone or along with an intramedullary pin (7/87), were applied in all cases. The median time to fracture stabilization based on palpation was 18 days (range: 7-49). In the majority of cases (61/87), the initially applied splint was maintained until fracture healing was complete or the patient was euthanatized. Cases resolution was classified as acceptable, including normal function and moderate lameness, or unacceptable, including severe lameness or necrosis of the distal limb, resulting in amputation, euthanasia, or death. In 87% (76/87) of the cases an acceptable recovery was achieved. The most common complication was chronic lameness (13/87). Other complications included necrosis of the limb (7/87), bandage sores, nerve damage, and death. Lack of deep pain was noted on 7/87 birds on initial presentation, but returned in 4/7. The data from this study suggests that application of a tape splint is an appropriate means of repairing tibiotarsal fractures in birds less than 200 g.

Key words: Avian, fracture, psittacine, tape splint, tibiotarsus

LITERATURE CITED

1. Altman RB. Fractures of the extremities in birds. In: Kirk RW (ed). Current veterinary therapy VI. Philadelphia (PA): WB Saunders; 1977.

2. Bennett RA. Orthopedic surgery. In: Altman RB, Clubb SL, Dorrestein GM, Quesenberry K (eds.). Avian medicine and surgery. Philadelphia (PA): Saunders; 1997. p. 733-66.

3. Helmer P, Redig PT. Surgical resolution of orthopedic disorders. In: Harrison GJ, Lightfoot TL (eds.). Clinical avian medicine. Palm Beach (FL): Spix Pub; 2006. p. 761-74.

USE OF ORTHOTICS AND PROSTHETICS FOR DISTAL LIMB INJURIES IN WATERFOWL

Laura M. Kleinschmidt, DVM,[1,3]* Virginia Ellsworth, DVM,[2] and Sharman M. Hoppes, DVM, Dipl ABVP(Avian)[3]

[1]Saint Louis Zoo, Saint Louis, MO 63110 USA; [2]East Dallas Veterinary Clinic, PLLC, Dallas, TX 75228 USA; [3]Texas A&M University, Department of Small Animal Veterinary Clinical Sciences, College Station, TX 77845 USA

Abstract

Use of prosthetics and orthotics in veterinary medicine has been reported in dogs, cattle, horses, tortoises, and pigs.[1-2,5,7,10] Prosthetics in avian medicine have largely been limited to beak prostheses, though limb prostheses have been sporadically reported.[3-4,6,8-9,11] A 1-yr-old client-owned female mallard duck (*Anas platyrhynchos*) presented after being attacked by a dog. A severe degloving wound extended from the right hip distally with fractures of digits two and three. Treatments included surgical debridement, antibiotics and analgesics, wet-to-dry bandaging, hydrotherapy and amputation of affected toes. Neurologic sensation was lost in the remaining phalanges and severe tarsal and stifle contracture resulted in inability to ambulate. An orthosis was created to allow weight-bearing and with physical therapy the bird was able to utilize the orthosis to walk. A second case, a 1-mo-old male domestic goose (*Anser anser domesticus*) presented with an injured left leg. The foot was missing with necrotic tissue present. A prosthesis was created to dissipate pressure from the distal aspect of the limb and allow for ambulation. The patient ambulates using the prosthesis with only a slight change in gait. These cases demonstrate the successful use of orthoses and prostheses in two waterfowl, preventing morbidity and mortality typically associated with severe distal limb injuries. Both devices were made from a cast mold of the limb with polypropylene plastic,[a] lined with thermofoam padding[b] and medical grade silicone,[c] affixed with non-skid soles, and held in place using velcro strapping. Both birds continue to use the devices daily.

[a]Polypropylene Natural Plate .063 x 48 x 96 inches Smooth, Quadrant Engineering Plastic Products, International, www.quadrantplastics.com
[b]Volara®, Sekisui Voltek, Lawrence, MA 01843 USA
[c]Quick-sil, UCO International, Wheeling, IL 60090 USA

Key words: *Anas platyrhynchos*, *Anser anser domesticus*, distal limb injury, domestic goose, mallard duck, orthotics, prosthetics

ACKNOWLEDGMENTS

The authors would like to recognize Bill Bickley at Pet Artificial Limbs and Supports (PALS) for his diligent work on these cases.

LITERATURE CITED

1. Adamson C, Kaufmann M, Levine D, Millis DL, Marcellin-Little DJ. Assistive devices, orthotics, and prosthetics. Vet Clin North Am Small Anim Pract. 2005;35(6):1441-1451.

2. Clabaugh K, Haag KM, Hanley CS, Latimer KS, Hernandez-Divers SJ. Undifferentiated sarcoma resolve by forelimb amputation and prosthesis in a radiated tortoise (*Geochelone radiata*). J Zoo Wildl Med. 2005;36(1):117-120.

3. Crosta L. Alloplastic and heteroplasic bill prostheses in 2 ramphastidae birds. J Avian Med Surg. 2001;16(3):218-222.

4. David T. Knee-joint prosthesis in a buzzard (*Buteo buteo*). Tierarztl Prax. 1976;4(3):387-389.

5. Koger LM, McIlhattan J, Schladetzky R. Prosthesis for partially amputated foreleg in a horse. J Am Vet Med Assoc. 1970;156(11):1600-1604.

6. Morris PJ, Weigel JP. Methacrylate beak prosthesis in a Marabou stork (*Leptoptilos crumeniferus*). J Assoc Avian Vet. 1990;4.2:103-106: 4(2).

7. Prakash KK, Prakash S. Artificial limb for a heifer. Vet Rec. 1990;127(25-26):623.

8. Richter NA, Bacon RD, Richter KJ, Grubbs RW, MacCoy DM. Use of a leg prosthesis in a bald eagle (*Haliaeëtus leucocephalus). J Assoc Avian Vet. 1990:109-112.*

9. Rush EM, Turner TM, Montgomery R, Ogburn AL, Urban RM, Sidebothum C, LaVasser A. Implantation of a titanium partial limb prosthesis in a white-naped crane (*Grus vipio*). J Avian Med Surg. 2012;26(3):167-175.

10. Saunders MM, Brecht JS, Verstraete MC, Kay DB. Njus GO. Lower limb direct skeletal attachment: a Yucatan micropig pilot study. J Invest Surg. 2012;25(6):387-397.

11. Sleamaker TF. Prosthetic beak for a salmon-crested cockatoo. J Am Vet Med Assoc. 1983:183(11):1300-1301.

A SYSTEMATIC APPROACH TO BEHAVIOR CASES: THE KEY TO THE RIGHT DIAGNOSIS—CLINICAL CASES

Marion Desmarchelier, DVM, IPSAV, DES, MSC, Dipl ACZM,[1,2,3]* Shannon T. Ferrell, DVM, Dipl ABVP (Avian), Dipl ACZM,[2] and Diane Frank, DVM, Dipl ACVB[3]

[1]Zoological Medicine Service - Faculté de médecine vétérinaire - Université de Montréal, Saint-Hyacinthe QC J2S 7C6 Canada; [2]Zoo de Granby, Granby QC J2G 5P3 Canada; [3]Behavioral Medicine Service - Faculté de médecine vétérinaire - Université de Montréal, Saint-Hyacinthe QC J2S 7C6 Canada

Abstract

The so-called "behavior cases" are often challenging for zoo veterinarians. The inappropriate behaviors displayed by zoo animals, such as pacing, aggression, or compulsive disorders, should be interpreted as clinical signs. In order to treat patients with behavioral problems, it is important to first acquire an accurate diagnosis. A systematic approach can be used to build a thorough differential diagnosis list. The first step is to obtain detailed history on the animal, including behavioral development, medical history, feeding, grooming, exploratory and play behaviors, breeding history and sexual/maternal behavior, and then the relevant social and physical environments. The second point is to obtain a precise description of the problem behavior, including details about frequency, duration, and context of the behavior. Observation of the behavior by the veterinarian is of critical importance, directly or on a video format. Filming the animal over a 24-hr period has proven insightful in several cases. Behavioral analysis can be performed at that point, identifying the antecedents and the consequences of the problem behavior, as well as the general context. Then, a full physical examination of the animal should be performed. Depending on the case, diagnostics can include blood analyses, radiographs or more advanced imaging, gastroduodenal endoscopy with biopsies, and skin biopsies.[1,4,6] When all the information has been gathered and analyzed, a differential diagnosis list can be made. All potential medical or surgical causes should first be excluded and/or treated. Potential environmental causes should be addressed as much as possible. If the problem remains or if the improvement is incomplete, anxiety disorders or other behavioral diagnoses could be considered. Several clinical cases were successfully diagnosed and treated with this systematic approach.

An 8-yr-old female Amur tiger (*Panthera tigris altaica*) presented for aggression towards keepers and unfamiliar people. Signs were first observed a few months before presentation, but increased over time. This female tiger was also aggressive towards her 2.5-yr-old daughter with whom she was housed. Minor injuries between the two animals were reported. Physical examination of this adult tiger was unremarkable. Tiger cubs generally leave their mother at 2-3 yr of age in the wild. Keeping the mother isolated from her daughter obviously resolved intraspecific aggressive behavior, but also resulted in a return to her usual nonaggressive behavior towards the keepers within only a few days.

An 18-mo-old male Canadian lynx (*Lynx canadensis*) was presented for increased pacing over a few months since the departure of his family (mother and two sisters). Medical history revealed short bouts of dysorexia during the same period. Video analysis demonstrated that the pacing also

occurred at night, and that the behavior was not stereotypic. Physical examination including gastroduodenoscopy and bronchoscopy revealed several medical conditions, such as *Helicobacter* gastritis, bacterial pneumonia and congenital cardiac malformations. Treatment with antibiotics and omeprazole resulted in a significant decrease of the pacing behavior. Environmental and social adjustments were also made in this case as part of the therapeutic plan.

A 24-yr-old Asiatic black bear (*Ursus thibetanus*) was presented for stereotypic pacing behavior. Few changes had occurred in the bear's environment in the previous years. More efforts had already been placed to enrich the environment and stimulate natural behaviors, but were unsuccessful in decreasing the daily duration of the pacing. Physical examination and radiographs detected multiple dental root infections. Treatment was associated with a complete resolution of the pacing behavior. A few years later, the bear started pacing again. Another dental infection was rapidly diagnosed and treated, and the pacing behavior disappeared.

An 11-yr-old female Amur leopard (*Panthera pardus orientalis*) was observed pacing in circles with her 6-wk-old cub in her mouth. The behavior increased over time despite numerous environmental adjustments and alpha-casozepine therapy (Zylkene, Vetoquinol Canada, Saint-Hyacinthe QC, Canada). A visual examination revealed signs consistent with a localized mastitis. Pacing with the cub ceased 24 h after initiation of the antibiotic therapy.

A 2-yr-old male jaguar (*Panthera onca*) presented with self-inflicted tail wounds. This jaguar had been licking his tail since he was a cub. Behavioral observations showed that he spent 7% of his daytime hours licking his tail. Changes in the environment increased the behavior. Physical examination, including skin biopsies and gastroduodenoscopy, revealed a severe infection of the tip of the tail and possibly a mild eosinophilic gastritis. Radiographs were unremarkable. Local wound care and antibiotic therapy significantly decreased the licking behavior, but did not lead to a complete resolution. Successive treatments with omeprazole and gabapentin did not show any improvement. Though some medical causes could not be excluded at that time (food allergy, neuropathic pain), a compulsive disorder was suspected and treated with fluoxetine.[2,3,7] Further behavior analyses were conducted while the jaguar was treated with the SSRI and a new pattern was observed: the tail-licking/chewing behavior mainly occurred after meals or food enrichments. Therefore, treatment with omeprazole at a higher dose, based on the new feline literature recommendations was initiated and, in combination with the fluoxetine, led to almost complete resolution of the behavior.[5]

Many behavior cases can be managed and/or treated when a diagnosis is found, with the help of a systematic approach. When environmental adjustments have been made and medical conditions excluded, consulting with a board-certified behaviorist could be recommended to choose the most appropriate treatment for the animal and to monitor the recovery.

Key words: Aggression, behavior, pacing, self-mutilation, tail licking

LITERATURE CITED

1. Becuwe-Bonnet V, Belanger MC, Frank D, Parent J, Helie P. Gastrointestinal disorders in dogs with excessive licking of surfaces. J Vet Behav: Clin App Res. 2012;7:194-204.

2. Ciribassi J. Understanding behavior: feline hyperesthesia syndrome. Compend Contin Educ Vet. 2009;31:E10.

3. Denerolle P, White SD, Taylor TS, Vandenabeele SI. Organic diseases mimicking acral lick dermatitis in six dogs. J Am Anim Hosp Assoc. 2007;43:215-220.

4. Frank D. Repetitive behaviors in cats and dogs: are they really a sign of obsessive-compulsive disorders (OCD)? Can Vet J. 2013;54:129-131.

5. Sutalo S, Ruetten M, Hartnack S, Reusch CE, Kook PH. The effect of orally administered ranitidine and once-daily or twice-daily orally administered omeprazole on intragastric pH in cats. J Vet Int Med. 2015;29:840-846.

6. Waisglass JE, Landsberg GM, Yager JA, Hall JA. Underlying medical conditions in cats with presumptive psychogenic alopecia. J Am Med Assoc. 2006;228:1705-1709.

7. Zulch HE, Mills DS, Lambert R, Kirberger RM. The use of tramadol in a Labrador retriever presenting with self-mutilation of the tail. J Vet Behav. 2012;7:252-258.

SEMIOCHEMICALS AND THEIR POTENTIAL APPLICATIONS IN ZOO ANIMAL HOUSING AND WELFARE

Valarie V. Tynes, DVM, Dipl ACVB

Veterinary Services, Ceva Animal Health, Lenexa, KS 66215 USA

Abstract

Chemical communication is the oldest and most widely used form of communication among animals. The term semiochemical refers to any chemical involved in a chemical interaction between animals. Pheromones are a subclass of semiochemicals and are defined as "substances secreted outside of the body by one individual and received by a second individual of the same species, in which they release a specific reaction."[7] The response to pheromones is innate and in many instances behavior or endocrine changes occur in the receiver as a result of exposure.

Man has exploited this knowledge of chemical communication in animals for years and recent research into the use of pheromones has found them to be useful in parasite control in a variety of species,[2,3] to decrease aggression in group housed swine,[5] to reduce stress in commercially housed broiler chickens[4] and to decrease aggression between cats in the multi cat household.[1]

Research into the use of pheromones in captive wild animals remains limited but shows similar promise. Pheromones have been used in different species to aid in introductions and to aid in reducing stress associated with travel. The author is aware of a great deal of other anecdotal use that continues to be unreported and undocumented.

Appeasing pheromones (also referred to as appeasines) show particular promise. The appeasines are semiochemicals produced by nursing females from sebaceous glands located in the intramammary sulcus.[6] They have a calming or soothing effect on the young, and animals have been shown to be capable of responding the same way to this pheromone into adulthood. The first appeasine was identified in sows and they have since been identified in bitches, mares, cows, queens, ewes and does.

Appeasing pheromones have the potential to aid in reducing stress in captive wild animals. They may prove useful in aiding introductions of unrelated animals, decreasing stress during movement between zoological parks or between enclosures. They may be useful in managing events that have been shown to be stressful for certain animals such as busier or nosier times of year in zoological parks. The presence of pheromones in enclosures may even serve as a form of environmental enrichment for some individuals.

Further study is needed in all of these areas to demonstrate if this particular form of therapy is as effective as it is safe. Pheromone therapy is currently an underutilized form of therapy, most likely due to the fact that the majority of veterinarians have been taught very little about chemical communication or behavior problems and behavior therapy in animals. This form of therapy is deserving of further investigation. It could potentially avoid the need for anxiolytics in many situations and yet due to the fact that it acts uniquely from pharmaceuticals it can also safely be

used as an adjunct with any medication. In companion animal behavior therapy it is often used as a component of multi modal therapy. Pheromones take effect more rapidly than drugs, are not taken up into the bloodstream, so require no metabolism or elimination from the body. Thus they are safe to use in any animal regardless of their age or state of health.

In order to collect useful information about their effects, it will be important that good behavioral data, using consistent, published ethograms (when possible) be collected prior to and after the use of the pheromones. Sharing this data amongst the zoological community can then aid in better use of this potentially valuable tool.

Key words: Anxiety, behavior, pheromones, semiochemicals, stress

LITERATURE CITED

1. DePorter T, Lopez A, Ollivier E. Evaluation of the efficacy of a new pheromone product versus placebo in the management of feline aggression in multi-cat households. Proc Am Coll Vet Behav, Am Vet Soc Anim Behav, Vet Behav Symp; 2014.

2. Hastie LC, Wallace C, Birkett MA, et al. Prevalence and infection intensity of sea lice (*Lepeophtheirus salmonis*) on Atlantic salmon (*Salmo salar*) is reduced by the non-host compound 2-aminoacetophenone. Aquaculture 2013;410-411:179-183

3. Kelly PJ, Lucas HM, Randolph CM, et al. Efficacy of slow- release tags impregnated with aggregation-attachment pheromone and deltamethrin for control of *Amblyomma variegatum* on St. Kitts, West Indies. Parasites Vectors 2014; 7:182-190.

4. Madec I, Gabarrou JF, Saffray D, et al. Broilers (*Gallus gallus*) are less stressed if they can smell a mother odorant. S Afr J Anim Sci. 2008;38(3):201-206.

5. McGlone JJ, Anderson DL. Synthetic maternal pheromone stimulates feeding behavior and weight gain in weaned pigs. J Anim Sci. 2002;80:3179-3183.

6. Pageat P, Gaultier E. Current research in canine and feline pheromones. Vet Clin Sm Anim Pract. 2003;33:187-211.

7. Wyatt TD. Pheromones and animal behavior. 2nd ed. Cambridge (UK): Cambridge University Press; 2014.

CASE REPORT: PHEROMONE THERAPY WITH FELINE FACIAL PHEROMONE FRACTION F3 (FFP) AS AN ALTERNATIVE THERAPEUTIC FOR PSYCHOGENIC DERMATITIS IN FIVE MARGAY (*Leopardus wiedii*) AT SOROCABA ZOO IN SÃO PAULO, BRAZIL

Hanna S. Kokubun, DVM,[1]* André L.M.Costa, DVM,[1] Vanessa L. Ribeiro, DVM,[1] Henrique G. Riva, DVM,[2] and Rodrigo H.F.Teixeira, DVM, MSc[1]

[1]Sorocaba Zoo, Sorocaba, São Paulo, 18020-268, Brazil; [2]Fundación Botánica y Zoológica de Barranquilla, Barranquilla, Colombia

Abstract

Pheromone therapy using pheromone fraction F3 of feline facial pheromone (FFP)[a,8,9,13,14] is widely used in animal shelters to minimize stress that can generate morbidity (i.e., psychogenic dermatitis [PD])[11,16,18] and misbehavior.[1-3,5,7,10,17,19] Studies of FFP use in captive wild felids are needed.[4] In the wild, cats are typically solitary, whereas in captivity may be located near other individuals or share the same enclosure.[6,12,15] The objective of this study was to report the use of FFP in five margays (*Leopardus wiedii*)[6,12,15] diagnosed with PD due to excessive licking behavior at Sorocaba Zoo despite the use of environmental enrichment. They were declared previously healthy and free of parasitism and fungal infection by physical exam and routine blood work. They were classified as: Class I: 1-10% of fur loss (n = 2); Class II: 10-30% of fur loss (n = 2) and Class III: over 30% of fur loss (n = 1). The cats' behaviors were observed before and after pheromone therapy, administered twice a day for 60 days sprayed in the enclosure. Behaviorial data were recorded during normal working hours. In this period, all animals demonstrated normal appetite and indifference to the act of spraying the product, except for one animal, that showed aversion to the spraying and soughtshelter. 80% of treated animals demonstrated full fur regrowth, due to a decrease in PD. Only one animal (Class I) showed aversion and did not change his classification. Based on the results, FFP could be a useful environmental therapy to minimize stress in wild cats in captivity, but further studies are necessary.

[a] Feliway® , Ceva Saúde Animal, Paulínia, SP, Brazil

Key words: Captive distress, *Leopardus wiedii*, licking dermatitis, margay, pheromone fraction therapy, wild cat disease

ACKNOWLEDGMENTS

We would like to thank those who somehow helped with this project, especially the Sorocaba Zoo Team.

LITERATURE CITED

1. Amat M, Camps T, Manteca X. Stress in owned cats: behavioral changes and welfare implications. J Feline Med Surg. 2015; pii: 1098612X15590867. Epub ahead of print].

2. American Association of Feline Practitioners. Feline behavior guidelines. Topeka (KS): Hill´s Pet Nutrition; 2004. p. 25-35.

3. Bowen J, Heath S. Feline compulsive disorders. In: Bowen J, Heath S (eds.). Behaviour problems in small animals. Philadelphia (PA): Elsevier; 2005. p. 181-182.

4. Dehnhard M. Mammal semiochemicals: understanding pheromones and signature mixtures for better zoo-animal husbandry and conservation. Int Zoo Yearb**.** 2011;45:55-79.

5. Eiler H. Glândulas Endócrinas. In: Reece WO Dukes Fisiologia dos Animais Domésticos. (Brazil) 12. ed. Rio de Janeiro: Guanabara Koogan; 2012. p. 578.

6. Eisenberg JF. The Northern Neotropics. In: Mammals of the Neotropics. v. 1, London (UK): University of Chicago Press, 1989. p.283.

7. Ellis SLH. Environmental enrichment: practical strategies for improving feline welfare. J Feline Med Surg. 2009;11(11):901-912.

8. Frank D, Beauchamp G, Palestrini C. Systematic review of the use of pheromones for treatment of undesirable behavior in cats and dogs. J Am Vet Med Assoc. 2010;236;1308-1316.

9. Griffith CA, Steigerwald ES, Buffington C. Effects of a synthetic facial pheromone on behavior of cats. J Am Vet Med Assoc. 2000;217:1154-1156.

10. Gunn-Moore DA, Cameron ME. A Pilot Study Using Synthetic Feline Facial Pheromone For The Management Of Feline Idiopathic Cystitis. J Feline Med Surg. 2004;6:133-138.

11. Mege, C. Skin conditions associated with behavioural disorders. In: Guaguere E, Prelaud P (eds.). A practical guide to feline dermatology**.** New York (NY): Merial; 1999. p. 17.1-17.11.

12. Oliveira TG, Cassaro K. Guia de Identificação dos Felinos Brasileiros. São Paulo: Publicação Sociedade de Zoológicos do Brasil & Fund. Parque Zoológico de São Paulo, Brazil; 1997. p. 21.

13. Pageat P, Gaultier E. Current research in canine and feline pheromones. Vet Clin North Am Sm Anim Pract**.** 2003;33:187-211.

14. Ramos D. Comportamento Felino, Feromônios Naturais E Feromonioterapia Na Clínica Comportamental Felina, São Paulo: Ceva; 2014. p. 14-35.

15. Redford KH, Eisenberg JF. The southern cone. In: Mammals of the Neotropics v. 2, London (UK): University of Chicago Press; 1989. p.169.

16. Roosje P, Henfrey J. An approach to the alopecia in the cat. In: Foster AP, Foil C. BSAVA manual of small animal dermatology. 2nd ed. London (UK): Br Sm Anim Vet Assoc; 2003. p. 74.

17. Schmidt-Nielsen K. Informação E Sentidos. In: ___. Fisiologia Animal - Adaptação E Meio Ambiente**.** 5. Ed. São Paulo: Santos Editora (Brazil); 2002. p. 537.

18. Scott DW, Miller WH, Griffin CE. Doenças psicogênicas da pele. In: Muller & Kirk´s dermatologia de pequenos animais, 5. ed. Rio de Janeiro: Interlivros Edições (Brazil), 1996. p. 799-800.

19. Simpson BS, Papich MG. Pharmacologic management in veterinary behavioral medicine. Vet Clin Sm Anim Pract. 2003;33:365-404.

LONG-TERM ADMINISTRATION OF HALOPERIDOL IN AN AFRICAN ELEPHANT (*Loxodonta africana*), SUPPPORTING THE THERAPY OF SELF-DESTRUCTIVE STEREOTYPIC BEHAVIOR

Endre Á. Papp, DVM* and László Garamvölgyi, DVM

Nyíregyházi Állatpark Nonprofit Kft. (SostoZoo), Nyíregyháza, 4431 Hungary

Abstract

Haloperidol has been used for behavior modification in several species.[2,3,5] In the African elephant (*Loxodonta africana*), single administration dosages are described,[1,4] but an extended oral regimen has not been published. A 29-yr-old female African elephant, kept for 23 yr alone, showed steretoypic behavior, following a translocation into a newly established group of conspecifics. The lack of socialization, abnormal eruption of the tusks, inflammation of the tusk sheaths, and anxiety appeared in the medical history of the animal. The behaviorial anomalies worsened in over the next 2 yr in the winter period, when the confinement in the closed barn increased. Knocking of the head, chip fractures of the tusk, traumatic lesions and persistent inflammation of the facial area fulminated. In the second year a complex treatment begun, including pain management, several episodes of wound debridement in standing sedation, X-ray assisted shaping of the tusks, modification of the handling techniques, behavioral enrichment, and the oral administration of 120 mg haloperidol (Haloperidol-Richter 1.5 mg Tablet, Richter Gedeon Nyrt., Budapest, 1103 Hungary) daily for 20 wk. The prescribed dosage produced anxiolysis without profound sedation and adverse effects. The self-destructive behavior stopped, the elephant became more receptive for the stimuli of the environment and the conspecifics, developing appropiate responses. Further deterioration of the tusks and possible exposure of the pulp cavity was avoided and complete recovery of the soft tissues could be achieved. The neuroleptic therapy efficiently supported the complex management of this behavior problem.

Key words: African elephant, haloperidol, *Loxodonta africana,* neuroleptic therapy*,* stereotype behavior, tusk

ACKNOWLEDGMENTS

The authors acknowledge the Nyíregyházi Állatpark Nonprofit Kft. (Sosto Zoo) staff for all their husbandry efforts, Dr. Debbie Young, Dr. Ellen Wiedner, Dr. Gerhard Steenkamp, and the Észak-magyarországi Lógyógyászati Kft. for their contribution to this work.

LITERATURE CITED

1. du Toit JG. Veterinary care of African elephants. Pretoria, Republic of South Africa: Novartis; 2001. p. 1-59.

2. Heeran JV, Chandrasekharan K, Radhakrishnan K. A case of ochlophobia in a tusker. In: Silas EG, Nair MK, NirmalanG. (eds.). The Asian elephant: Ecology, biology, diseases, conservation and management. Trichur, India: Kerala Agricultural University; 1992. p. 176.

3. Hofmeyr JM. The use of haloperidol as a long-acting neuroleptic in game capture operations. J. S. Afr. Vet. Assoc.1981;52(4):273-282.

4. Raath JP. Chemical capture of the African elephant. In: McKenzie AA (ed.). The capture and care manual: capture, care, accommodation and transportation of wild African animals. Pretoria, Republic of South Africa: Wildlife decision support services; 1993. p. 484-511.

5. Redrobe SP. Neuroleptics in great apes with specific reference to modification of aggressive behavior in a male gorilla. In: Fowler ME, Miller RE (eds.). Zoo and wild animal medicine, Volume 6, Current therapy. St. Louis (MO): Elsevier; 2008. p. 243-250.

SERUM AMYLOID A: AN INFLAMMATORY MARKER OF *Otostrongylus* INFECTION IN JUVENILE NORTHERN ELEPHANT SEALS (*Mirounga angustirostris*) IN CENTRAL CALIFORNIA

Julie D. Sheldon, DVM,[1]* Shawn P. Johnson, DVM, MPVM,[2] Jorge Hernandez, DVM, MPVM, PhD,[3,4] Carolyn Cray, PhD,[5] and Nicole I. Stacy, DVM, Dr. Med Vet, Dipl ACVP[3]

[1]University of California Davis School of Veterinary Medicine, Davis, CA 95616 USA; [2]The Marine Mammal Center, Sausalito, CA 94965 USA; [3]Department of Large Animal Clinical Sciences, University of Florida College of Veterinary Medicine, Gainesville, FL 32608 USA; [4]Department of Small Animal Clinical Sciences, University of Florida College of Veterinary Medicine, Gainesville, FL 32608 USA; [5]Department of Pathology & Laboratory Medicine, University of Miami Miller School of Medicine, Miami, FL 33136 USA

Abstract

The lungworm, *Otostrongylus circumlitis* (OC), is a significant cause of mortality among stranded juvenile Northern elephant seals (NES; *Mirounga angustirostris*) along the central coast of California. Because mortality in NES occurs during the OC pre-patent period, fecal identification is not sensitive and patients are diagnosed upon necropsy.[1] Antemortem diagnostic techniques are needed to diagnose and treat this disease earlier. Acute phase protein concentrations reportedly serve as early inflammatory markers in many species including elephant seals with OC infections.[2-6] An experimental serum amyloid A assay (Eiken © Chemical SAA1 reagent) was validated and performed on banked serum collected from NES admitted to The Marine Mammal Center between 2012-2014. Samples were selected and organized into three groups: healthy individuals within three days upon release back into the wild (n = 23), malnourished individuals within 4 days upon admission to the center without clinical evidence of OC infection and were eventually released (n = 23), and individuals diagnosed with OC on necropsy that exhibited clinical signs of OC infection at time of sampling within 0-17 days before death or euthanasia (n = 23). The null hypothesis that median SAA concentrations are not different between groups was tested using the non-parametric Kruskal-Wallis test. Median SAA concentrations were significantly higher in OC infected elephant seals (327.9 mg/L) ($P < 0.05$) compared to healthy (11.2 mg/L) and malnourished (33.8 mg/L) groups. These results indicate that SAA has potential to serve as a diagnostic tool to help direct treatment for suspected OC infections in rehabilitating juvenile elephant seals.

Key words: Acute phase proteins, lungworms, *Mirounga angustirostris*, Northern elephant seal, *Otostrongylus circumlitis*, serum amyloid A

ACKNOWLEDGMENTS

The authors would like to thank the volunteers, research staff, and veterinarians at the Marine Mammal Center for animal care, sample collection, necropsies, and help sending samples to the University of Miami Avian and Wildlife Laboratory. We would also like to thank all laboratory technicians at the University of Miami for their technical support and Eiken Chemical for their gift of the SAA reagents.

LITERATURE CITED

1. Gulland FM, Beckmen K, Burek K, Lowenstein LJ, Werner L, Spraker T, Dailey M, Harris E. Nematode (*Otostrongylus circumlitus*) infestation of northern elephant seals (*Mirounga angustirostris*) stranded along the central California coast. Mar Mamm Sci. 1997;13(3):446-459.

2. Harr K, Harvey J, Bonde R, Murphy D, Lowe M, Menchaca M, Haubold E, Francis-Floyd R. Comparison of methods used to diagnose generalized inflammatory disease in manatees (*Trichechus manatus latirostris*). J Zoo Wildl Med. 2006;37(2):131-159.

3. Kjelgaard-Hansen M, Jensen AL, Kristensen AT. Evaluation of a commercially available human C-reactive protein (CRP) turbidometric immunoassay for determination of canine serum CRP concentration. Vet Clin Pathol. 2003;32(2):81-87.

4. Rosenfeld H, Lassen S, Prange A. Charactarization of haptoglobin in the blood plasma of harbor seals (*Phoca vitulina*). J Prot Res. 2009;8:2923-2932.

5. Sheldon JD, Johnson SP, Cray C, Stacy NI. Acute-phase protein concentrations during health, malnutrition, and *Otostrongylus* infection in juvenile Northern elephant seals (*Mirounga angustirostris*) in Central California. In: Proc Inter Assoc Aq Anim Med; 2015.

6. Stanton J, Cray C, Rodriguez M, Arheart KL, Ling PD, Herron A. Acute phase protein expression during elephant endotheliotropic herpesvirus-1 viremia in Asian elephants (*Elephas maximus*). J Zoo Wildl Med. 2013;44(3):605-612.

COELOMIC FLUID ANALYSIS OF TWO SEA STAR GENERA: A COMPARISON OF HEALTHY SEA STARS AND THOSE AFFECTED BY SEA STAR WASTING DISEASE

Sarah J. Wahlstrom, BA,[1,2]* Lesanna L. Lahner, DVM, MPH,[1] Nicole Stacy, DVM, DrMedVet, Dipl ACVP,[3] and Alisa L. Newton, VMD, Dipl ACVP[4]

[1]Seattle Aquarium, Seattle, WA 98101 USA; [2]The Ohio State University College of Veterinary Medicine, Columbus, OH 43210 USA; [3]Department of Large Animal Clinical Sciences, University of Florida, College of Veterinary Medicine, Gainesville, FL 32608 USA; [4]Wildlife Conservation Society, Bronx, NY 10460 USA

Abstract

Sea star wasting disease (SSWD) is one of the largest marine wildlife die-offs ever recorded and has killed millions of sea stars from 20 Asteroid species between Alaska to Mexico since the summer of 2013. A sea star-associated densovirus has been associated with SSWD but the exact disease etiology remains unknown.[4] Coelomic fluid surrounds the sea star's organs, playing a role in nutrient transportation[3] and innate immune function. Coelomocytes, similar to vertebrate leukocytes, provide cell-mediated immunity. Coelomic fluid macromolecules including lectins, agglutinins, perforins, complement and several cytokines provide a humoral response.[1,2,5] To investigate the pathophysiology of SSWD, coelomic fluid (n = 107) from two commonly affected species, the mottled sea star (*Evasterias troschelii*) and the ochre sea star (*Pisaster ochraceus*), was sampled for electrolytes, total protein, and coelomocyte counts with establishment of baseline intervals for *Pisaster ochraceus* for magnesium (93.7-109.1 mg/dL), sodium (376-441 mEq/L), potassium (4.2-14.5 mEq/L), chloride (428-454 mEq/L), calcium (31.0-36.5 mg/dL), and total protein (1.2-2.2 g/dL). Although diseased sea stars (n = 63) demonstrated a wider range of all values, only chloride was significantly higher. Free and phagocytized bacteria were noted in 51.6% coelomic fluid samples from deceased sea stars and in no samples from healthy sea stars. The wider range of electrolytes, presence of bacteria within coelomic fluid and coelomocytes, and increased coelomocyte counts in sick animals suggest inflammation, bacterial infection, and impaired osmoregulation due to SSWD.

Key words: Coelomic fluid, *Evasterias troschelii,* mottled sea star, ochre sea star, *Pisaster ochraceus,* sea star wasting disease

ACKNOWLEDGMENTS

The authors would like to thank the staff at the Seattle Aquarium for their support of this project and Dr. Carolyn Cray from the University of Miami for performing the electrolyte analysis.

LITERATURE CITED

1. Beck G, Habicht GS. Isolation and characterization of a primitive interlekin-1-like protein from an invertebrate, *Asterias forbesi.* Immunol. 1986;83:7429-7433.

2. Burke RD, Watkins RF. Stimulation of starfish coelomocytes by interleukin-1. Biochem Biophys Res Comm. 1991;180(2):579-584.

3. Ferguson JC. Nutrient transport in starfish. I. Properties of the coelomic fluid. Biol Bull. 1963;126:33-53.

4. Hewson I, Button JB, Gudenkauf BM, Miner B, Newton AL, Gaydos JK, Wynne J, Groves CL, Hendler G, Murray M, Fradkin S, Breitbart M, Fahsbender E, Lafferty KD, Kilpatrick AM, Miner CM, Raimondi P, Lahner L, Friedman CS, Daniels S, Haulena M, Marliave J, Burge CA, Eisenlord ME, Harvell CD. Densovirus associated with sea-star wasting disease and mass mortality. Proc Natl Acad Sci. 2014;111(48):17278-17283.

5. Ramírez-Gómez F, García-Arrarás JE. Echinoderm immunity. Invert Survival J. 2010;7: 211-220.

HEALTH MONITORING IN FLORIDA MANATEES (*Trichechus manatus latirostris*) VIA LIVE CAPTURE HEALTH ASSESSMENTS: LESSONS LEARNED AND ENHANCING STRATEGIES TO MONITOR POPULATION HEALTH IN THE FUTURE

Martine de Wit, DVM, Dipl AVBP,[1]* Michael T. Walsh, DVM,[2] Nicole I. Stacy, DVM, DrMedVet, Dipl ACVP,[2] and Robert K. Bonde, PhD[3]

[1]Fish and Wildlife Research Institute, Florida Fish and Wildlife Conservation Commission, Saint Petersburg, FL 33701 USA; [2]Department of Large Animal Clinical Sciences, Aquatic Animal Health Program, College of Veterinary Medicine, University of Florida, Gainesville, FL 32608 USA; [3]Sirenia Project, Wetland and Aquatic Research Center, U.S. Geological Survey, Gainesville, FL 32653 USA

Abstract

Florida manatees (*Trichechus manatus latirostris*) are threatened by numerous anthropogenic effects and natural disease factors. Watercraft collisions and loss of warm-water habitat have been identified as the greatest population threats statewide.[3] Since 1996, ten unusual or recurring mass mortality events have added additional impact to subpopulations in southwest and central-east Florida. To establish baseline data on manatee health and better understand existing and emergent pressures on the health of the population, conservation partners have captured free-ranging manatees to perform physical exams and collect blood, urine, feces, and skin samples for a broad suite of analyses, including novel molecular studies. In the previous decade, samples from health assessments were instrumental in establishing reference intervals for hematology and chemistry analytes,[1,2] which are now useful in monitoring and following trends in the population. Between December 2008 and September 2015, 238 health assessments were performed on manatees in three different habitats: winter habitat of artesian spring complex, winter habitat of industrial warm-water and secondary warm-water sites, and summer habitat. Spatial and temporal differences were observed in body and skin conditions, feces, and in blood parameters, including subtle electrolyte abnormalities. These findings identified possible environmental effects on manatee health, and support that long-term monitoring through health assessments can help identify stressors, and other threats. How can today's data and archive translate into a framework for future conservation efforts? Further development of a collaborative program for information exchange and archival which integrates key health research objectives is imperative to timely detect health concerns in the future.

Key words: Health assessment, manatee, population health

ACKNOWLEDGMENTS

Manatee captures are a tremendous team effort and the authors are very appreciative of the invaluable assistance of our colleagues and volunteers from FWRI, USGS, UF and USFWS, and other stranding partners. Manatee health assessments were conducted under USFWS research permit issued to USGS #MA-791721.

LITERATURE CITED

1. Harvey JW, Harr KE, Murphy D, Walsh MT, Chittick EC, Bonde RK, Pate MG, Deutsch CJ, Edwards HH, Haubold EM. Clinical biochemistry in healthy manatees (*Trichechus manatus latirostris*). J Zoo Wildl Med. 2007;38:269-279.

2. Harvey JW, Harr KE, Murphy D, Walsh MT, Nolan EC, Bonde RK, Pate MG, Deutsch CJ, Edwards HH, Clapp WL. Hematology of health Florida manatees (*Trichechus manatus*). Vet Clin Pathol. 2009;38:183-193.

3. Runge MC, Langtimm CA, Martin J, Fonnesbeck CJ. Status and threats analysis for the Florida manatee (*Trichechus manatus latirostris*), 2012. U.S. Geological Survey Open-File Report 2015-1083; 2015. 23 p. Available from http://dx.doi.org/10.3133/ofr20151083

COMPARISON OF DIETARY AND ENVIRONMENTAL IODINE EFFECTS ON THYROID PROTEIN LEVELS IN CAPTIVE WHITE-SPOTTED BAMBOO SHARKS (*Chyloscyllium plagiosum*)

Lily Parkinson, DVM,[1]* Kurt Sladky, MS, DVM, Dipl ACZM, Dipl ECZM (Herpetology),[1] and Terry Campbell, DVM, PhD[2]

[1]School of Veterinary Medicine, University of Wisconsin, Madison, WI 53706 USA; [2]College of Veterinary Medicine and Biomedical Sciences, Colorado State University, Fort Collins, CO 80523 USA

Abstract

Goiter remains a recognized and still treated disease in captive elasmobranchs.[1-4] Goiter, an enlargement of the thyroid gland, can cause a number of problems including goiter rupture, anorexia, and death.[4] It was long believed that goiter was simply the result of insufficient iodine in the diet or tank water, but recent studies have indicated that other factors, such as nitrates, and other unknown variables are at play.[5] Some researchers believe that the wide variety of thyroid dysfunctions observed in elasmobranchs (including, but not limited to diffuse hyperplastic goiter, diffuse colloid goiter, and multinodular goiter) cannot be attributed to iodine level disturbances alone.[2] Before the additional variables that affect the thyroid of captive elasmobranchs can be thoroughly studied and clarified, the role that iodine plays in this complex process should be thoroughly researched. Iodine undoubtedly plays a large role in the healthy function of an elasmobranch thyroid, but iodine's exact role and importance is far from being understood. Previous studies have shown that moving a shark with goiter from a high nitrate and low iodine enclosure to one with water containing high iodine and low nitrates can reverse the development of a goiter.[3] More recent studies have also indicated that with the increasing use of ozone treatment in aquaria for water quality, iodide levels in commercial and home aquaria are dropping.[6] This may not be immediately apparent to a home aquarist, however. This is because, although iodide, the bioavailable form of iodine, decreases when a tank is ozonated, total iodine remains the same.[6] Should an aquarist only measure total iodine, then, the problem might not be detected until the shark presented with goiter. Many aquariums circumvent the question of iodine levels in tank water by supplementing the sharks orally with iodine, with the Mazuri Vita-Zu Shark/Ray Tablet seemingly the most popular form of oral supplementation. Very little is understood about the benefits and drawbacks of oral versus environmental iodine supplementation, however. This study provided 8 wk of supplementation to experimental groups of 7 sharks while a control group received no iodine supplementation. The first experimental group received oral iodine supplementation at the recommended dosage of Mazuri Shark/Ray tablets, the second group received environmental supplementation in the form of iodine in the water brought to the level of natural seawater (0.06 ppm), and the final experimental group received both forms of supplementation. Levels of iodine in the water were measured with spectrophotometry and ion chromatography daily. T_4, T_3, RT_3, and T_2 species were measured at weeks 0, 1, 2, 4, 6, and 8 by LC-MS/MS. Results revealed that spectrophotometry did not accurately reflect iodine levels in the tank water. Additionally, only T_3 levels were found to differ significantly in the orally supplemented sharks. No other significant differences were discovered. This study indicates that further research is required and that more lengthy research studies are likely required to fully

elucidate the role of iodine and thyroid hormones in elasmobranchs.

Key words: *Chyloscyllium plagiosum*, iodine, liquid chromatography, mass spectrometry, supplementation, thyroid

LITERATURE CITED

1. Crow GL, Atkinson MJ, Ron B, Atkinson S, Skillman AD, Wong GT. Relationship of water chemistry to serum thyroid hormones in captive sharks with goitres. Aquat Geochem. 1998;4(3-4):469-480.

2. Crow GL, Luer WH, Harshbarger JC. Histological assessment of goiters in elasmobranch fishes. J Aquat Anim Health. 2001;13:1-7.

3. Crow GL. Goiter in elasmobranchs. In: Smith M, Warmolts D, Thoney D, Hueter R (eds.). Elasmobranch husbandry manual: captive care of sharks, rays, and their relatives; 2004. p. 441-448) [Pagemaker File]. Available from https://docs.google.com/viewer?a=v&pid=sites&srcid=ZGVmYXVsdGRvbWFpbnxlb GFzbW9icmFuY2hodXNiYW5kcnl8Z3g6MTFlNjUxYjY3ZGE3Y2ExYw

4. Janse M, Firchau B, Mohan PJ. Elasmobranch nutrition, food handling, and feeding techniques. In: Smith M, Warmolts D, Thoney D, Hueter R (eds.). Elasmobranch husbandry manual: Captive care of sharks, rays, and their relatives; 2004. p. 183-200 [Pagemaker File]. Available from https://docs.google.com/viewer?a=v&pid=sites&srcid=ZGVmYXVsdGRvbWFpbnxlb GFzbW9icmFuY2hodXNiYW5kcnl8Z3g6MTFlNjUxYjY3ZGE3Y2ExYw

5. Morris AL. The relationship between water chemistry and goiter development in two species of bamboo shark, *Chyloscyllium* spp. 2010. (Doctoral dissertation, University of Florida, Gainesville, FL).

6. Sherrill J, Whitaker BR, Wong GT. Effects of ozonation on the speciation of dissolved iodine in artificial seawater. J Zoo and Wildl Med. 2004;35(3):347-355.

RESPONSE TO THE DIAGNOSIS OF TUBERCULOSIS (*Mycobacterium pinnipedii*) IN A COLONY OF CAPTIVE PINNIPEDS IN NEW ZEALAND

James Chatterton, BVMS, MSc, CertZooMed, MRCVS,[1]* An Pas, DVM, MVS (ConsMed),[1] Sarah A. Alexander, BSc, BVMS, PGCert,[1] Richard Jakob-Hoff, BVMS, MANZCVS,[1] Cathy Harvey, BVSc, Dipl ACVP,[2] and Wendi Roe, BVSc, Dipl ACVP, PhD[3]

[1]New Zealand Centre for Conservation Medicine, Auckland Zoo, Auckland, NZ 1245; [2]IDEXX New Zealand Veterinary Pathology, Auckland 1022, NZ; [3]Institute of Veterinary Animal and Biomedical Sciences, Palmerston North, NZ 4442

Abstract

In June 2014, a 3-yr-old captive (wild-born) New Zealand Fur Seal (*Arctocephalus forsteri*) presented with abdominal pain and haematuria, which was refractory to initial treatment. A serologic test (Chembio DPP Vet-TB) reaction gave suspicion of TB and this was confirmed by routine testing of tracheo-bronchial lavage samples: spoligotyping confirmed *Mycobacteria pinnipedii* and advanced molecular methods confirmed a strain not previously recognised in New Zealand. Subsequently, the remaining five pinnipeds underwent repeated TB surveillance: one individual was persistently reactive on serologic testing, but this was later confirmed due to sinusitis associated with *Mycobacterium marinum*, rather than TB. The remaining four individuals in the group were initially negative on serologic testing, became reactive, and to date three have become negative again, without treatment. These animals have remained negative for TB on all other diagnostic tests performed on tracheo-bronchial and oesophageal lavage samples and on computed tomography (CT) scans. In response to this diagnosis, a risk-assessment and testing regime was devised for staff and volunteers. We also divided the zoo animals into relative risk groups, based on their geographic proximity to the seal colony and the keepers' working routine. This has led to 62 general anaesthetics involving an additional 411 tests and, to date, no further case of active TB has been found. This presentation highlights some of the complexities in interpreting test results in relation to TB in pinnipeds and highlights a potential biosecurity and zoonotic risk associated with accepting wild-born pinnipeds into zoo collections.

Key words: *Arctocephalus forsteri*, *Mycobacterium pinnipedii,* pinniped*,* tuberculosis

ACKNOWLEDGMENTS

The authors would like to thank the following people for their support throughout this study: the staff at Auckland Zoo, Middlemore Hospital, New Zealand Veterinary Pathology/IDEXX and LabPLUS.

DETERMINING TOTAL HEMOCYTE COUNTS AND HEMOLYMPH CLINICAL CHEMISTRY PROFILES FOR FREE-RANGING AMERICAN HORSESHOE CRABS (*Limulus polyphemus*)

Jill E. Arnold, MS, MT(ASCP),[1] Leigh Ann Clayton, DVM, Dipl ABVP (Avian and Reptile/Amphibian),[1]* Catherine A. Hadfield, MA, VetMB, Dipl ACZM, Dipl ECZM, MRCVS,[1] and Carolyn Cray, PhD[2]

[1]National Aquarium, Baltimore, MD 21202 USA; [2]University of Miami, Department of Pathology & Laboratory Medicine, Division of Comparative Pathology, University of Miami, Miami, FL 32510 USA

Abstract

The American horseshoe crab (*Limulus polyphemus*) is a popular display animal in interactive aquatic exhibits and an important indicator of ecosystem health. There are also commercial biomedical and fishing industries. While hematology and biochemistry analyses are fundamental tools for animal health assessments, there are no hemocyte counts and limited biochemistry values reported. This prospective study was conducted to develop reference intervals for hemocyte count and select biochemistry analytes in free-ranging animals collected during annual breeding aggregation in the Delaware Bay. The work was supported by the National Aquarium Research and Animal Welfare Committees. Near-shore animals were manually restrained and hemolymph was immediately collected from the cardiac sinus through the arthrodial membrane. Hemocyte count samples were collected into chilled syringes prefilled with a modified-EDTA anti-coagulant developed for invertebrates (hemolymph dilution factor 4) and then immediately preserved in 10% formalin (dilution factor 5). For other analytes, hemolymph was immediately placed in heparin tubes and processed following standard protocols. On day 1, fifty (25.25.0) animals were sampled for hemocyte count and, on day 2, fifty (25.25.0) animals were sampled for biochemistry analytes, copper levels, and analysis by protein electrophoresis. The median and range for select values are reported in Table 1 (males and females combined). While the total hemocyte count varied widely, the majority of values were 15,000-35,000/µL. Hemolymph osmolality and electrolyte concentrations were high. On electrophoresis, the majority of protein was in the albumin migrating peak; this may represent hemocyanin. These results contribute to developing health assessment parameters for this species.

Key words: Biochemistry, hemocyte count, hemolymph, horseshoe crab, invertebrate, *Limulus polyphemus*

ACKNOWLEDGMENTS

The authors would like to thank the AAZV Wild Animal Health Fund for funding this study and staff at the Delaware Department of Natural Resources and National Aquarium for supporting this work.

Table 1. Median and range for total hemocyte count and select biochemistry analytes from free-ranging American horseshoe crabs (*Limulus polyphemus*) collected during breeding aggregation in the Delaware Bay; water temperature during sampling 70-73 ºF (21-23 ºC) and salinity 14-20 g/L.

Analyte	Median (range)	Units	n
Total hemocyte count[a]	23,045 (1,815-61,490)	/µl	43
Alanine aminotransferase[a]	45 (0-84)	U/L	50
Aspartate aminotransferase[a]	33 (0-108)	U/L	50
Alkaline phosphatase[a]	0 (0-38)	U/L	50
Gamma-glutamyl transpeptidase [a]	0 (0)	U/L	50
Cratine kinase[a]	4 (0-33)	U/L	50
Glucose[a]	41 (0-61)	mg/dl	50
Calcium[a]	24.7 (5.8-34.2)	mg/dl	50
Phosphorus[a]	0.5 (0.0-1.3)	mg/dl	50
Sodium[a]	327 (303-363)	mEq/L	50
Potassium[a]	8.1 (6.9-11.1)	mEq/L	50
Chlroide[a]	321 (294-360)	mEq/L	50
Magnesium[a]	8.7 (7.3-10.3)	mg/dl	50
Osmolality[a]	657 (613-734)	mOsmol/kg	50
Uric acid[a]	1.1 (0.0-2.2)	mg/dl	50
Creatinine[a]	0.4 (0.0-0.8)	mg/dl	50
Amylase[a]	19 (2-135)	U/L	50
Lipase[a]	13 (0-103)	U/L	50
Cholesterol [a]	0 (0)	mg/dl	50
Triglycerides [a]	2 (0-29)	mg/dl	50
Albumin[a]	1.7 (0.3-2.2)	g/dl	50
Total solids[a]	5.5 (0-8.1)	g/dl	50
Albumin-migrating fraction[b]	4.6 (0.1-8.1)	g/dl	50
Total protein[b]	6.4 (0.4-10.4)	g/dl	50

[a]Results from National Aquarium Clinical Pathology Laboratory.
[b]Results from University of Miami Department of Pathology & Laboratory Medicine; albumin migrating fraction by protein electrophoresis and total protein by refractometer.

ESTABLISHING THE COAGULATION PROFILE OF THE FLORIDA MANATEE (*Trichechus manatus latirostris*) AND IDENTIFYING COAGULOPATHIES IN THE PATHOPHYSIOLOGY OF COLD STRESS SYNDROME

Ashley Barratclough, BVetMed, MScWAH, MRCVS,[1,2]* Bobbi Conner, DVM, Dipl ACVECC,[3] Roger L. Reep, PhD,[2] Ray L. Ball, DVM,[1] and Ruth Francis Floyd, DVM, MS, Dipl ACZM[2]

[1]Veterinary Sciences, Tampa's Lowry Park Zoo, Tampa, FL 33604 USA; [2]University of Florida, Department of Large Animal Clinical Sciences, Aquatic Animal Health Division, College of Veterinary Medicine, Gainesville, FL 32610 USA; [3]University of Florida, Department of Small Animal Clinical Sciences, College of Veterinary Medicine, Gainesville, FL 32610 USA

Abstract

The exact pathophysiology of cold stress syndrome (CSS) in the Florida manatee (*Trichechus manatus latirostris)* was previously unknown. The condition was hypothesized as a nutritional, immunologic and metabolic disturbance caused by prolonged exposure to water temperatures < 20°C.[1] Following extensive research into the coagulation system, it was confirmed that CSS involves a severe hemostatic disorder. The following mean results were established for normal coagulation parameters in 40 wild manatees: prothrombin time (PT) 10.8 sec, partial thromboplastin time (PTT) 9.2 sec, fibrinogen 132 mg/dl, and D-dimer 82 ng/ml. In comparison, CSS cases had statistically prolonged PT, PTT, increased D-dimer and fibrinogen and a reduced platelet count, consistent with disseminated intravascular coagulation (DIC).

Furthermore, the normal clotting process was characterized, performing coagulation factor assays in 40 wild manatees and thromboelastography (TEG) in 29 wild manatees. Wild manatees were relatively hypercoagulable compared to other species. The following mean (SD) normal TEG parameters were determined: reaction time R = 2.1 (0.77) min, clotting time K = 0.8 (0.0) min, α angle 83.1° (2.0), maximum amplitude MA = 75 mm (7.6) and clotting lysis LY30 = 0.41% (0.68).[2] In comparison CSS cases showed increased coagulability supporting the hypothesis of thromboembolic disease playing a role in the pathophysiology of CSS. It was established that increased PTT, PT, D-dimer, and fibrinogen levels and thrombocytopenia have a negative prognostic value in assessment of CSS cases. It is proposed that prolonged hypothermia results in a coagulopathy which is a component of the syndrome and may ultimately contribute or lead to the clinical signs associated with CSS including epidermal bleaching, enterocolitis and anorexia.

Key words: Coagulopathy, cold stress syndrome, manatee, rehabilitation, thromboelastography

ACKNOWLEDGMENTS

We would like to gratefully acknowledge Florida Fish and Wildlife Conservation Commission for all the manatees successfully rescued. Thank you to USGS for facilitating sampling during the annual health assessments. The authors would additionally like to thank Dr. Trevor Gerlach, Mrs. Virginia Edwards and her manatee rehabilitation team as well as Lowry Park Zoo clinic staff.

LITERATURE CITED

1. Bossart GD, Meisner RA, Rommel S, Ghim S, Jenson AB. Pathological features of the Florida manatee cold stress syndrome. Aquat Mamm. 2002;29: 9-17.

2. Donahue SM, Otto CM. Thromboelastography: a tool for measuring hypercoagulability, hypocoagulability, and fibrinolysis. J Vet Emerg Crit Care. 2005;15:9-16.

Proteus anguinus IN CROATIA: WHAT WE HAVE LEARNED

Maja Lukac, DVM, PhD,[1]* Ivan Cizelj, dipl ing agr,[2] Susanne Holtze, DVM, PhD,[3] Dusan Jelic, mag edu biol, PhD,[4] Frank Mutschmann, DVM, Dipl ECZM,[5] Danijela Horvatek Tomic, DVM, PhD,[1] Estella Prukner-Radovcic, DVM, PhD, Dipl ECPVS,[1] Zeljko Gottstein, DVM, PhD,[1] Ivan Rychlik, RNDr, PhD,[6] Petra Videnska, Mgr, PhD,[6] and Thomas B. Hildebrandt, DVM, PhD, Dipl ECZM[3]

[1]Faculty of Veterinary Medicine, University of Zagreb, Zagreb 10000, Croatia; [2]Zagreb Zoo, Zagreb 10000, Croatia; [3]Leibniz Institute for Zoo and Wildlife Research, Berlin10315, Germany; [4]Croatian Institute for Biodiversity, Croatian Herpetological Society, Zagreb 10000, Croatia; [5]Exomed, Berlin 10319, Germany; [6]Veterinary Research Institute, Brno 62100, Czech Republic

Abstract

This research project is aimed at collecting information about *Proteus anguinus* (the olms), to help protect this very unique and endangered amphibian living in underground carst. Using novel ecological research methods discovered the largest single population to date in the Markarova cave, with approximately one individual/m^2. Keeping the animals in captivity, in a specially designed "cold room" which meets all their needs regarding the temperature, water conductivity, aeration and food, showed that they accepted all the offered food, primarily the *Lumbricus* sp., with the preference of live food over frozen. Microbiologic results of skin, cloacal and oral cavity swabs revealed the presence of soil and water microorganisms such as *Aeromonas hydrophila* and *Aspergillus flavus*, previously described as pathogens in immunocompromised amphibians. Maldi-ToF method allowed identification of the *Janthinobacterium lividum*, a bacterium with known anti-fungal properties. Next generation sequencing revealed the incorporation of *Methylotenera* sp. and *Methyloversatilis* sp. in the skin and oral cavity. Feces and intestinal scrapings were free of parasites. Real-Time PCR gave negative results for *Batrachochytrium dendrobatidis, Batrachochytrium salamandrivorans* and Ranavirus in skin swabs and for *Chlamydia* spp. in oral cavity and cloacal swabs. Scanning of animals with a precise ultrasound machine was helpful in the sex determination, general health assessment and early diagnosis and treatment of otherwise fatal *Saprolegnia* infections in captive animals. To the author's knowledge this is the first information of that kind about the biology of *Proteus anguinus*.

Key words: Field research, health assessment, microbiology, olm, *Proteus anguinus*, ultrasound

REMOTE IMMOBILIZATION OF ENTANGLED CALIFORNIA SEA LIONS (*Zalophus californianus*) USING AN ACOUSTIC TRANSMITTER TRACKING SYSTEM

Cara L. Field, DVM, PhD,* Greg Frankfurter, DVM, Eugene DeRango, and Shawn Johnson, DVM, MPVM

The Marine Mammal Center, Sausalito, CA 94965 USA

Abstract

Marine mammals with marine debris entanglements suffer high rates of morbidity and mortality. Constant proximity of free-ranging California sea lions to water greatly impedes manual capture with nets and traps. Remote immobilization using the combination of midazolam (0.2 mg/kg), butorphanol (0.2mg/kg) and medetomidine (0.03 mg/kg) can provide deep sedation and subsequent retrieval of these mammals both in and out of water, without substantially hindering their ability to surface and breathe. Incorporation of an acoustic transmitter into the dart housing allows tracking of animals underwater, particularly throughout areas with extensive marine obstacles such as boats and piers. California sea lions with active entanglements were darted from boat or land using a barbed non-reusable pneumatic dart modified to carry a small acoustic transmitter. Sea lions that entered the water after darting were tracked using a hydrophone until sedation was adequate for capture with nets. A total of 20 entangled sea lions were darted, with 12 (60%) of these successfully captured, disentangled and released. Three of the 20 animals (15%) died during rescue attempts, and 4 of the 20 (20%) were either not sedated or not retrieved. One animal (5%) was euthanatized due to injury from dart-related trauma. The successful capture, disentanglement, treatment and release of the majority of these animals supports the value of this technique.

Key words: California sea lion, entanglement, remote immobilization, *Zalophus californianus*

ACKNOWLEDGMENTS

The authors are very grateful to TechShop San Francisco, Autodesk, Inc and Matt Hoard for technical advice and dart development, and to the volunteers and veterinary science staff from The Marine Mammal Center who were integral to the rescue, disentanglement and care of the animals.

KNUT THE POLAR BEAR (*Ursus maritimus*) SUFFERED FROM AUTOIMMUNE ENCEPHALITIS: A NEW DISEASE OF WILDLIFE

Harald Prüß, MD, PhD,[1] Jonas Leubner,[1,2] Nina K. Wenke,[1] Gabor Á. Czirják, DVM, PhD, [3] Claudia A. Szentiks, DVM,[3] and Alex D. Greenwood, PhD[3]*

[1]German Center for Neurodegenerative Diseases (DZNE) Berlin, Germany; [2]Department of Neurology, Charité- Universitätsmedizin Berlin, Berlin, Germany; [3]Department of Wildlife Diseases, Leibniz Institute for Zoo and Wildlife Research, Berlin, Germany

Abstract

Knut, the world famous polar bear from Berlin, Germany, lived a very-well-documented life and death. In March 2011, in front of the public, Knut displayed seizures which resulted in his drowning in the enclosure pool. Encephalitis was diagnosed and despite the application of a comprehensive pathogen diagnostic pipeline, established particularly for this case, no etiologic agent could be identified.[4] While encephalitis is not an uncommon diagnosis in both domestic and wildlife species, many of those cases cannot be associated with a pathogenic cause.[1] The inability to identify pathogens mirrors the situation in human medicine where roughly 20% of encephalitis cases were considered of unknown etiology despite intensive searches for a pathogen cause.[2] Since 2007, many of these cases have been associated with the aberrant development of autoantibodies targeting several glutamate receptors present in neurons, the most prevalent being the N-methyl-D-aspartate receptor or NMDAR.[2] Due to the lack of conclusive evidence for involvement of an infectious agent in Knut's symptoms, despite a pathogen screen of similar intensity to what had been performed on human patients, a screen of autoimmune receptor involvement was undertaken in an attempt to understand the basis of Knut's encephalitis. Two polar bears which had died of causes unrelated to encephalitis served as negative controls whereas human patient anti-NMDAR encephalitis cerebrospinal fluid (CSF) was used as a positive control. Immunoglobulins in CSF from the bears and human patient material were both protein A/FITC labelled and Alexa-594 dye labelled and tested against cell lines expressing different candidate glutamate receptors, rodent brain tissue where the receptors are expressed and polar bear brain tissue.[3] The two negative control polar bear CSF samples failed to react in any experiment whereas the positive control human and Knut's CSF reacted strongly and specifically to cell lines and tissues expressing NMDAR. The titre of anti-NMDAR antibodies in Knut's CSF was exceptionally high indicating the disease had progressed quite far at the time of death. The results indicate that Knut suffered from anti-NMDAR encephalitis and represent the first diagnosis of this disease in an animal. In a OneHealth context, the case of Knut brings attention to a disease that can go undiagnosed in humans due to nonspecific and variable clinical symptoms, while it adds a new differential diagnosis to veterinary neurologic cases both incaptive and free living animals. In human medicine, the condition is treated with both steroidal and non-steroidal therapies, which may offer promising treatment options for veterinary medicine as well. Currently, additional cases of encephalitis of known and unknown etiology are being screened to learn more about the biology, frequency and epidemiology of this condition in domestic animals and wildlife.

Key words: Autoimmune encephalitis, NMDAR, polar bear, *Ursus maritimus*

ACKNOWLEDGMENTS

Funding was provided by The German Research Foundation (DFG, PR 1274/2-1) to H.P.

LITERATURE CITED

1. Lowrie M, Smith PM, Garosi L. Meningoencephalitis of unknown origin: investigation of prognostic factors and outcome using a standard treatment protocol. Vet Rec. 2013;172(20):527.

2. Prüss H, Dalmau J, Harms L, Höltje M, Ahnert-Hilger G, Borowski K, Stoecker W, Wandinger KP. Retrospective analysis of NMDA receptor antibodies in encephalitis of unknown origin. Neurology. 2010;75(19):1735-1739.

3. Prüss H, Leubner J, Wenke NK, Czirják GÁ, Szentiks CA, Greenwood AD. Anti-NMDA Receptor encephalitis in the polar bear (*Ursus maritimus*) Knut. Sci Rep. 2015;5:12805.

4. Szentiks CA, Tsangaras K, Abendroth B, Scheuch M, Stenglein MD, Wohlsein P, Heeger F, Höveler R, Chen W, Sun W, Damiani A, Nikolin V, Gruber AD, Grobbel M, Kalthoff D, Höper D, Czirják GÁ, Derisi J, Mazzoni CJ, Schüle A, Aue A, East ML, Hofer H, Beer M, Osterrieder N, Greenwood AD. Polar bear encephalitis: establishment of a comprehensive next-generation pathogen analysis pipeline for captive and free-living wildlife. J Comp Pathol. 2014;150(4):474-488.

INVESTIGATING CARDIOVASCULAR DISEASE IN BILE-FARMED ASIATIC BLACK BEARS (*Ursus thibetanus*) IN CHINA: COMPARISONS WITH FREE-RANGING ASIATIC BLACK BEARS IN JAPAN (*Ursus thibetanus japonicas*)

Monica K. H. Bando, BS, MS, BVSc, MRCVS,[1]* O. Lynne Nelson, DVM, MS, Dipl ACVIM,[1] Chris Linney, BVSc, CertAVP(VC),[2] Hannah Stephenson, BVMS, CertSAM, Dipl ECVIM-CA(Cardiology),[3] Koji Yamazaki, PhD,[4] Claudia Hartley, BVSc CertVOphthal Dipl ECVO,[5] David Donaldson, BVSc (Hons), Dipl ECVO,[6] Mandala Hunter-Ishikawa, BS, MS, DVM,[7] and Wendy Leadbeater, RVN, MSc[8]

[1]College of Veterinary Medicine, Washington State University, Pullman, WA 99163 USA; [2]Department of Cardiology, Small Animal Teaching Hospital, School of Veterinary Science, University of Liverpool, Leahurst, Neston, CH64 7TE, UK; [3]Hannah Stephenson Specialist Veterinary Cardiology, Barnfield Farm, Tunstall, Carnforth, Lancashire LA6 2RU, UK; [4]Department of Forest Science, Tokyo University of Agriculture, Tokyo, Japan; [5]Animal Health Trust, Lanwades Park, Kentford, Newmarket, CB8 7UU, UK; [6]SASH Veterinary Clinic, North Ryde, NSW, Australia;[7]Animals Asia, Vietnam Bear Rescue Centre, Tam Dao, Vietnam; [8]Animals Asia Foundation, China Bear Rescue Centre, Longqiao, Chengdu, Sichuan Province, 610515, People's Republic of China

Abstract

Asiatic black bears (*Ursus thibetanus*) are endangered[3] yet the predominant species farmed for bile throughout Asia; an animal welfare and conservation issue. Animal welfare charity Animals Asia (www.animalsasia.org) has rescued 578 bears from the bile industry. Bile-farmed bears experience numerous health issues[5-8] with cardiovascular disease the third leading cause of death.[1,2] In 2013 we presented the first report of aortic aneurysms in bile-farmed bears.[2] The aim of this study is to investigate the potential etiology of cardiovascular disease by comparing bile-farmed bears with free-ranging Japanese Asiatic black bears (*Ursus thibetanus japonicas*). Echocardiography confirmed aortic dilation (mild to severe) in 16 (59%) of 27 bile-farmed bears but not in free-ranging bears (n = 8). Bile-farmed bears exhibited significantly greater left ventricular (LV) free wall thickness in diastole (18.6 ± 4.2 mm vs 11.8 ± 1.2 mm), LV mass (489 ± 141 g vs 201 ± 53 g), aortic sinus (37.4 ± 7.7 mm vs 25.9 ± 3.7 mm), and aortic root (36.3 ± 9.9 mm vs 21.8 ± 3.5 mm) measurements compared to free-ranging bears. These findings of LV hypertrophy and aortic dilation in bile-farmed bears are consistent with systemic hypertension, a known risk factor in aortic aneurysm development. Suspect hypertensive retinopathies were identified in 12 (75%) of 16 bile-farmed aneurysm bears. Retinal exams were not possible in free-ranging bears. Urine protein to creatinine ratios measured in seven of 16 aneurysm bears were elevated in four (57%) (range 0.85-26.4) consistent with glomerulonephritis and were normal (<0.2[4,9]) in free-ranging bears. These findings support associations between renal damage and cardiovascular pathology, which is suspected to be due to systemic hypertension initiated by glomerulonephritis from chronic biliary extraction site infections.

Key words: Aortic aneurysm, Asiatic black bear, bear bile farming, cardiovascular disease, systemic hypertension, *Ursus thibetanus*

ACKNOWLEDGMENTS

The authors would like to thank Animals Asia and the Norbury Trust for field work financial support.

LITERATURE CITED

1. Bando M, Hunter-Ishikawa M. Common health problems of previously bile-farmed Asiatic black bears (*Ursus thibetanus*) in China. One Health Asia Pacific Conf 7th Asian Mtg Zoo Wildl Med Conserv; 2014. p. 33-34.

2. Bando MKH, Webster N, Nelson OL, Hartley C, Donaldson D, O'Dwyer J, Reynard J, Bacon HJ. Aortic aneurysms in Asiatic black bears (*Ursus thibetanus*) rescued from bile farms in China. Proc Am Assoc Zoo Vet; 2013. p. 64.

3. Convention on International Trade in Endangered Species of Wild Fauna and Flora [Internet]. Asiatic black bear [cited 2014 Nov 27]. Available from https://cites.org/eng/gallery/species/mammal/Asiatic_black_bear.html/

4. International Renal Interest Society [Internet]. IRIS Staging of CKD [cited 2015 Nov 4]. Available from http://iris-kidney.com/guidelines/staging.aspx/

5. Li, P. China's bear farming and long-term solutions. J Appl Anim Welf Sci. 2004;7(1):71-80.

6. Li, P. Rehabilitating rescued Chinese farm bears (*Ursus thibetanus*): results, limitations, and implications. J Wildl Rehab. 2004;27(1):4-15.

7. Loeffler, IK, Robinson, J and Cochrane, G. Compromised health and welfare of bears farmed for bile in China. Anim Welf. 2009;18:225-235.

8. Maas, B. 2000. The veterinary, behavioural and welfare implications of bear farming in Asia: World Society for the Protection of Animals (WSPA). Report. London, United Kingdom.

9. Stockam, SL and Scott, MA. Fundamentals of veterinary clinical pathology. 2nd ed. Ames (IA): Blackwell Publishing; 2008. p. 329-330.

SCREENING OF BANDED MONGOOSES (*Mungos mungo*) IN THE KRUGER NATIONAL PARK, SOUTH AFRICA, FOR *Mycobacterium bovis* INFECTION

Angela C. Brüns, DVM, MMedVet,[1,2]* Manfred Tanner, DVM,[3] Mark C. Williams, BVSc, MMedVet,[4] Louise Botha,[5] Amanda O'Brien, PhD,[6] Geoffrey T. Fosgate, DVM, PhD, Dipl ACVPM,[7] Paul D. Van Helden, PhD,[5] John Clarke, MSc,[6] and Anita L. Michel, DVM, PhD[2]

[1]National Zoological Gardens of South Africa, Pretoria, GP 0001 South Africa; [2]Department of Veterinary Tropical Diseases, Faculty of Veterinary Science, University of Pretoria, Pretoria, GP 0110 South Africa; [3]Friedrich Loeffler Institute (FLI), Federal Research Institute for Animal Health, Greifswald Isle Riems 17493 Germany; [4]Section of Pathology, Department of Paraclinical Sciences, Faculty of Veterinary Science, University of Pretoria, Onderstepoort 0110 South Africa; [5]SA MRC Centre for TB Research, DST/NRF Centre of Excellence for TB Research, Division of Molecular Biology and Human Genetics, Faculty of Medical and Health Sciences, Stellenbosch University, Cape Town 7505 South Africa; [6]Enfer Scientific, Unit Newhall, Naas, Co. Kildare, Ireland; [7] Department of Production Animal Studies, Faculty of Veterinary Science, University of Pretoria, Onderstepoort 0110 South Africa

Abstract

Bovine tuberculosis (bTB) in the Kruger National Park (KNP) has been well studied in the mainly affected buffalo (*Syncerus caffer*) and lion (*Panthera leo*) since first diagnosed in the park in 1990.[3,5] However, little is known about the small predators´ role in the tuberculosis epidemiology. A banded mongoose (*Mungos mungo*) population within the bTB high prevalence zone of the KNP was selected as indicator small predator and screened for *Mycobacterium bovis*.

A total of 76 live captured banded mongooses were screened serologically using ElephantTB STAT-PAK® Assay[a] on whole blood in the field and Enferplex™ Bovine TB Assay[b] on stored serum.[4,6] The STAT-PAK assay reacted positive for 12 animals (12/75), the Enferplex assay for five (5/74) of which two animals were positive on both assays (2/74). Ante mortem fecal swabs, tracheal swabs and tracheal lavages were submitted for *Mycobacterium* culture. *M. bovis* was isolated from tracheal lavages of two animals (2/65), one of which also cultured positive on the tracheal swab (1/72). Both these banded mongooses were the only ones to react positive on both STAT-PAK and Enferplex assay. A necropsy was performed on 12 banded mongooses selected for signs of clinical disease, advanced age or positive STAT-PAK assay: 8 animals were STAT-PAK positive and 4 were STAT-PAK negative reactors. Lesions from lung, lymph nodes and liver were examined histopathologically as well as cultured for *Mycobacterium*. Tuberculous lesions (i.e., calcified or caseous granulomas) were identified in two banded mongooses (2/12) and *M. bovis* was cultured from lung, lymph node and liver of both animals. The same two banded mongooses had positive culture results from tracheal lavage and positive serologic assays as described above.

In conclusion, this study demonstrated bTB infection in banded mongooses in the KNP and for the first time revealed their ability to shed *M. bovis* via the respiratory route. It further indicated a possible ante mortem diagnostic algorithm. Additionally this finding has sparked the discussion

around possible sources of infection and its significance at the human/-wildlife interface within the study area, similar to *Mycobacterium mungi* identified in disease outbreaks in the Chobe District, Botswana, between 2002 and 2010.[1,2]

[a]ElephantTB STAT-PAK® Assay, Chembio diagnostic systems, Meford, New York, USA
[b]Enferplex™ Bovine TB Assay, Enfer Scientific, Newhall, Naas, Co. Kildare, Ireland

Key words: Banded mongoose, Enferplex, Kruger National Park, *Mungos mungo*, *Mycobacterium bovis*, STAT-PAK

ACKNOWLEDGMENTS

The authors would like to thank SANParks for supporting this project. The project was funded by the German Research Foundation

LITERATURE CITED

1. Alexander KA, Laver PN, Michel AL, Williams M, Van Helden PD, Warren RM, Gey Van Pittius NC. Novel *Mycobacterium tuberculosis* complex pathogen, *M. mungi*. Emerg Infect Dis 2010;16(8):1296-1299.

2. Alexander KA, Pleydell E, Williams MC, Lane EP, Nyange JFC, Michel AL. *Mycobacterium tuberculosis*: An emerging disease of free-ranging wildlife. Emerg Infect Dis 2002;8(6):598-601.

3. Bengis RB, Kriek NPJ, Keet DF, Raath JP, De Vos V, Huchzermeyer HFAK. An outbreak of bovine tuberculosis in a free-living African buffalo (*Syncerus caffer* - Sparrman) population in the Kruger National Park: a preliminary report. Onderstepoort J Vet. 1996;63:15-18.

4. Chembio Diagnostic Systems. *Mycobacterium bovis - Mycobacterium tuberculosis,* Antibody Test Kit, ElephantTB STAT-PAK® Assay, A rapid immunochromatographic test for the detection of antibodies to *Mycobacterium tuberculosis* and *Mycobacterium bovis* in elephant serum, plasma or whole blood*,* brochure, CDS, Medford, New York, USA. 2007. http://www.invitech.co.uk/downloads/instructions/ElephantTB50Kit.pdf

5. Keet DF, Michel AL, Bengis RG, Becker P, Van Dyk DS, Van Vuuren M, Rutten VPMG, Penzhorn BL. Intradermal tuberculin testing of wild African lions (*Panthera leo*) naturally exposed to infection with *Mycobacterium bovis.* Vet Microbiol. 2010;144:384-391.

6. Whelan C, Shuralev E, O'Keeffe G, Hyland P, Kwok HF, Snoddy P, O'Brien A, Connolly M, Quinn P, Groll M, Watterson T, Call S, Kenny K, Duignan A, Hamilton MJ, Buddle BM, Johnston JA, Davis WC, Olwill SA, Clarke J. Multiplex immunoassay for serological diagnosis of *Mycobacterium bovis* infection in cattle. Clin Vaccine Immunol. 2008;15(12):1834-1838.

TUBERCULOSIS IN A CLOSED POPULATION OF VERVET MONKEYS (*Chlorocebus pygerythus*): IMMUNODIAGNOSTICS AND PATHOLOGY

Martine van Zijll Langhout, DVM, MSc,[1]* Emily Lane, BVSc, MPhil, Dipl ACVP,[3] Steve Unwin, BSc, BVSc, MRCVS,[4] and Anita L. Michel, BVSc, DVM, PhD[2,5]

[1]Artis Royal Zoo, Amsterdam, 1018 CZ, The Netherlands; [2]Bacteriology Division, ARC-Onderstepoort Veterinary Institute, Onderstepoort 0110, South Africa; [3]National Zoological Gardens of South Africa, Pretoria, South Africa; [4]Pan African Sanctuary Alliance Veterinary Co-ordinator, Conservation Medicine Division, North of England, Zoological Society (Chester Zoo), United Kingdom; [5]Department of Veterinary Tropical Diseases, Faculty of Veterinary Science, University of Pretoria, South Africa

Abstract

Tuberculosis is an emerging disease in both humans and nonhuman primates.[2] *M. tuberculosis* was isolated by culture and identified by PCR[3] from organ samples of three vervet monkeys (*Chlorocebus pygerythus*) that died in October 2008 in a large vervet monkey rescue centre in South Africa. As part of standing operational procedures of the Department of Agriculture of the Limpopo Provincial Government, the remaining monkeys at the rescue centre were tested for tuberculosis with the comparative tuberculin skin test (TST) and the PrimaTB STAT-PAK,[a] a lateral-flow kit for rapid detection of antibodies against *Mycobacterium tuberculosis* and *Mycobacterium bovis* in nonhuman primates.[1] A total of 405 monkeys were tested with both the TST and PrimaTB STAT-PAK. Fifteen animals were tested with the PrimaTB STAT-PAK only and 130 with the TST only. Fourteen monkeys tested positive with both diagnostic methods. Thirty-one monkeys tested positive with the PrimaTB STAT-PAK only and 100 monkeys tested positive with the TST only. Ninety monkeys reacted to just the Avian Tuberculin PPD and nine monkeys to just the Bovine Tuberculin PPD (grade 4). One monkey showed a reaction to both the Avian and Bovine Tuberculin PPD. A total of 98 necropsies of test positive animals were performed, including histopathology on tissues from 28 monkeys. In positive animals milliary granulomas with yellowish necrotic centres were found in lungs, spleen, intestines, bone and lymph nodes.

[a]Chembio Diagnostic Systems, Inc., Medford, New York

Key words: *Chlorocebus pygerythus,* pathology, PrimaTB STAT-PAK, tuberculin skin test, tuberculosis, vervet monkey

LITERATURE CITED

1. Lyashchenko KP, Greenwald R, Esfandiari J, Greenwald D, Nacy CA, Gibson S, Didier PJ, Washington M, Szczerba P, Motzel S, Handt L, Pollock JM, McNair J, Andersen P, Langermans JA, Verreck F, Ervin S, Ervin F, McCombs C. PrimaTB STAT-PAK assay, a novel, rapid lateral-flow test for tuberculosis in nonhuman primates. Clin Vaccine Immunol. 2007;14:1158-1164.

2. Michel AL, Hlokwe TM, Espie IW, Van Zijll Langhout M, Koeppel K, Lane E. *Mycobacterium Tuberculosis* at the Human/Wildlife Interface in a high TB Burden Country. Transbound Emerg Dis. 2013;60:46-52.

3. Warren RM, Van Pittius NC, Barnard M, Hesseling A, Engelke E, De Kock M, Guitierrez, MC, Chege GK, Victor TC, Hoal EG, and Van Helden PD. Differentiation of *Mycobacterium tuberculosis* complex by PCR amplicifation of genomic regions of difference. Int J Tuberc Lung Dis. 2006;10:818-22.

TUBERCULOSIS IN UNDER-RECOGNIZED SPECIES: IS THIS AN EMERGING DISEASE THREAT?

Michele Miller, DVM, PhD,[1]* Peter Buss, BVSC, MMedVet,[2] Chris Foggin, BVSC, PhD,[3] Lin-Mari de Klerk-Lorist, BVSC, MSc,[4] Paul van Helden, PhD,[1] and Sven Parsons, BVSC, PhD[1]

[1]Department of Science and Technology/National Research Foundation Centre of Excellence for Biomedical TB Research, Medical Research Council Centre for Tuberculosis Research, Division of Molecular Biology and Human Genetics, Faculty of Medicine and Health Sciences, Stellenbosch University, Cape Town, South Africa; [2]Veterinary Wildlife Services, South African National Parks, Kruger National Park, Skukuza, South Africa; [3]The Vic Falls Wildlife Trust, Victoria Falls, Zimbabwe; [4]Office of the State Veterinarian, Kruger National Park, Skukuza, Department of Agriculture, Forestry and Fisheries, South Africa

Abstract

Tuberculosis (TB) is a global infectious disease threat to captive and free-ranging wildlife.[2,6] Although TB is recognized as a health concern for elephants, rhinoceros, nonhuman primates, camelids, cervids, and wild bovids, the risk of this disease in small mammals, carnivores, and suids is poorly understood.[5,6] Conservation programs increasingly require translocation, importation of free-ranging animals, and movement between captive facilities to maintain genetic diversity; however, this creates the potential for introduction of infectious diseases into animal collections as well as through interfaces between and within species in new locations. Common and novel mycobacterial organisms belonging to the *Mycobacterium tuberculosis* complex may present underestimated risks due to lack of tools for detection. For example, *Mycobacterium mungi* has been observed to cause severe disease and morbidity in banded mongoose in Zimbabwe (C. Foggin, pers. comm.), and meerkats may also succumb to tuberculosis caused by M. *mungi*.[8] *Mycobacterium pinnipedii* is an emerging disease concern among collections housing sea lions and seals, and is creating a potential for zoonotic transmission (A. Lecu pers. comm.).[3] *Mycobacterium bovis* infection (bovine tuberculosis, BTB) has resulted in disease in large felids and canids (L.M. de Klerk-Lorist pers. comm.).[6] Recent studies have shown that asymptomatic BTB is commonly found in free-ranging warthogs in BTB-endemic areas (R. Bengis pers. comm.).[7] Even among ungulates, species previously considered "low risk", such as giraffe, have been documented with disease (L.M. deKlerk-Lorist pers. comm.).[4] These examples demonstrate the importance of developing accurate diagnostic tests for early detection of TB in under-recognized species to identify infected individuals, and prevent introduction and transmission of disease among cohorts and across species, including zoonotic infections in humans.[1] Zoological facilities and wildlife organizations should include strategic testing to mitigate risks of inadvertent movement of disease.

Key words: *Mycobacterium bovis, Mycobacterium mungi, Mycobacterium pinnipedii, Mycobacterium surcattiae*, tuberculosis

ACKNOWLEDGMENTS

The authors would like to thank the Veterinary Wildlife Services and State Veterinary staff of Kruger National Park for their support. We also acknowledge the financial support of the South African Research Chair Initiative (National Research Foundation) for Prof. Miller.

LITERATURE CITED

1. Etter E, Donado P, Jori F, Caron A, Goutard F, Roger F. Risk analysis and bovine tuberculosis, a re-emerging zoonosis. Ann New York Acad Sci. 2006;1081:61-73.

2. Fitzgerald SD, Kaneene JB. Wildlife reservoirs of bovine tuberculosis worldwide: hosts, pathology, surveillance, and control. Vet Pathol. 2012;50(3):488-499.

3. Kiers A, Klarenbeek A, Mendelts B, Van Soolingen D, Koeter G. Transmission of *Mycobacterium pinnipedii* to humans in a zoo with marine mammals. Int J Tuberc Lung Dis. 2008;12(12):1469-1473.

4. Lewerin SS, Olsson SL, Eld K, Roken B, Ghebremichael S, Koivula T, Kallenius G, Bolske G. Outbreak of *Mycobacterium tuberculosis* infection among captive Asian elephants in a Swedish zoo. Vet Rec. 2005;156(6):171-175.

5. Mikota SK. Tuberculosis in elephants. In: Fowler ME, Miller RE (eds.). Zoo and wild animal medicine, Volume 6, Current therapy. St. Louis (MO): Elsevier; 2008. p. 355-364.

6. Miller MA, Lyashchenko KP. Mycobacterial infections in other zoo animals. In: Mukundan H, Chambers M, Waters WR, Larsen M (eds.). Tuberculosis, leprosy and mycobacterial diseases of man and animals: the many hosts of mycobacteriosis. Boston (MA): CAB International; 2015. p. 277-295.

7. Miller M, Buss P, deKlerk-Lorist LM, Hofmeyr J, Hausler G, Lyashchenko K, Lane EP, Botha L, Parsons S, van Helden P. Application of rapid serologic tests for detection of *Mycobacterium bovis* in free-ranging warthogs (*Phacochoerus africanus*) - implications for antemortem disease screening. J Wildl Dis. 2015;doi:10.7589/2015-07-186.

8. Parsons SDC, Drewe JA, Gey van Pittius NC, Warren RM, van Helden PD. Novel cause of tuberculosis in meerkats, South Africa. Emerg Infect Dis. 2013;19(12):2004-2007.

BABESIOSIS *(Babesia odocoilei)*: AN EMERGING DISEASE OF ONTARIO CERVIDS

Adriana R. Pastor, BSc, DVM,[1,2]* Adriana M.W. Nielsen, DVM,[3] Doran W. Kirkbright, DVM,[2] Amélie Mathieu, DMV,[4] Graham Crawshaw, BVetMed, MS, Dipl ACZM,[1] Simon Hollamby, BVSc, MS, Dipl ACZM,[1] and Dale A. Smith, DVM, DVSc[2]

[1]Toronto Zoo, Scarborough, ON M1B 5K7 Canada; [2]Ontario Veterinary College, University of Guelph, Guelph, ON N1G 2W1 Canada; [3]Dubai Falcon Hospital, Dubai, United Arab Emirates; [4]College of Veterinary Medicine, The Ohio State University, Columbus, OH 43210 USA

Abstract

Babesia odocoilei is the causative agent of babesiosis in North American cervids, with white-tailed deer (*Odocoileus virginianus*) presumed to be the natural host species. Reported susceptible species include: elk (*Cervus elaphus canadensis*), caribou (*Rangifer tarandus caribou*), reindeer (*Rangifer tarandus tarandus*), desert bighorn sheep (*Ovis canadensis nelsoni*), markhor (*Capra falconeri*), muntjac (*Muntiacus reevesi*), muskox (*Ovibos moschatus*) and yak (*Bos grunniens*).[1,3-5] From 2012 to 2015, eight adult cervids (five American elk and three European reindeer) at the Toronto Zoo died acutely of a hemolytic crisis. All deaths occurred in the late fall, and animals were housed at different sites on zoo grounds. Ante-mortem clinical signs included: weakness, reduced appetite, respiratory distress, jaundice and hematuria. Three individuals died acutely with no detectable prodromal signs. Hemolysis, extensive hemorrhage and hemoglobinuria were consistent post-mortem findings. Retrospective analysis of cervid post-mortem samples from 2010 to 2015 was performed using PCR for *B. odocoilei* on frozen spleen. All elk and reindeer showing evidence of hemolysis on post-mortem examination tested positive on PCR. One elk and three reindeer that had died or were euthanatized for other reasons, and did not show evidence of hemolysis at post-mortem examination, were also positive for the parasite. One additional live, non-clinical, female reindeer was positive on PCR of whole blood. *B. odocoilei* has not been previously reported in Ontario, Canada; however, its presence has been identified in neighboring states (New York, Michigan, Minnesota, Pennsylvania).[1,2,5] Current studies are underway to determine whether the disease is present in wild cervids in Ontario.

Key words: American elk, *Babesia odocoilei*, babesiosis, *Cervus elaphus canadensis*, European reindeer, *Rangifer tarandus tarandus*

LITERATURE CITED

1. Bartlett SL, Abou-Madi N, Messick JB, Birkenheuer A, Kollias GV. Diagnosis and treatment of *Babesia odocoilei* in captive reindeer (*Rangifer tarandus tarandus*) and recognition of three novel host species. J Zoo Wildl Med. 2009;40:152-159.

2. Hamer SA, Roy PL, Hickling GJ, Walker ED, Foster ES, Barber CC, Tsao JI. Zoonotic pathogens in *Ixodes scapularis*, Michigan. Emerg Infect Dis. 2007;13:1131-1133.

3. Holman PJ, Bendele KG, Schoelkopf L, Jones-Witthuhn RL, Jones SO. Ribosomal RNA analysis of *Babesia odocoilei* isolates from farmed reindeer (*Rangifer tarandus tarandus*) and elk (*Cervus elaphus canadensis*) in Wisconsin. Parasitol Res. 2003;91:378-383.

4. Holman PJ, Madeley J, Craig TM, Allsopp BA, Allsopp MTEP, Petrini KR, Waghela SD, Wagner GG. Antigenic, phenotypic and molecular characterization confirms *Babesia odocoilei* isolated from three cervids. J Wildl Dis. 2000;36:518-530.

5. Schoelkopf L, Hutchinson CE, Bendele KG, Goff WL, Willette M, Rasmussen JM, Holman PJ. New ruminant hosts and wider geographic range identified for *Babesia odocoilei* (Emerson and Wright 1970). J Wildl Dis 2005;41:683-690.

Babesia capreoli INFECTION IN CAPTIVE REINDEER (*Rangifer tarandus tarandus*) IN OUWEHAND ZOO, THE NETHERLANDS

Jan H. Bos, DVM,[1]* Fokko C. Klip, DVM,[1] Hein Sprong, PhD,[2] Els M. Broens, DVM, PhD,[3] and Marja J.L. Kik, DVM, PhD[4]

[1]***Ouwehand Zoo, Rhenen, Utrecht, 3911 AV, the Netherlands;*** [2]***Laboratory for Zoonoses and Environmental Microbiology, National Institute for Public Health and Environment (RIVM), Bilthoven, Utrecht, 3721 MA, the Netherlands;*** [3]***Department of Infectious Diseases and Immunology, Faculty of Veterinary Medicine, Utrecht University, Utrecht, Utrecht, 3584 CL, the Netherlands;*** [4]***Department Pathobiology, Faculty of Veterinary Medicine, Utrecht University, Utrecht, Utrecht, 3584 CL, the Netherlands***

Abstract

A herd of captive reindeer (*Rangifer tarandus tarandus*) consisting of two males and seven females with five calves was diagnosed with a *Babesia capreoli* infection in June 2015. A 1-mo-old calf was found dead without any earlier clinical signs. Necropsy showed jaundice of the sclera of the eye, pleurae, serosa of the intestines, pelvis and large vessels and hemoglubinuria. Cytology showed protozoal inclusions in erythrocytes and PCR on whole blood tested *Babesia*-positive.[1] Two other calves became lethargic and a treatment schedule with imidocarb was started.[1] All animals were also treated with Ivermectin. Five females and their calves were bled for CBC, chemistry and PCR for *Babesia*; one adult female and her calf, which was exhibiting lethargy, tested positive. This calf had to be euthanatized due to respiratory distress; necropsy confirmed a *Babesia* infection. One month after the first diagnosis of *Babesia*, a 1-yr-old male reindeer, had to be euthanatized after a sudden episode of respiratory distress; this animal also tested *Babesia*-positive. All other animals and a tick (*Ixodes ricinus*) found on the clothing of the veterinarian were *Babesia*-negative. Molecular characterization of the 18S rDNA of the parasite showed complete identity with known *B. capreoli* sequences. *Ixodes ricinus* has been demonstrated to be a competent vector for *B. capreoli* from infected roe deer (*Capreolus capreolus*), the natural host of *B. capreoli*.[2-4] The *Babesia capreoli* infection in these reindeer could have been transmitted by *Babesia*-infected ticks (*Ixodes ricinus*) from the willow branches and leaves that are harvested along meadows in the lowlands around the zoo, where roe deer are very common.

Key words: *Babesia*, *Rangifer tarandus tarandus*, reindeer, roe deer

1. Bartlett SL, Abou-Madi N, Messick JB, Birkenheuer A, Kollias G V. Diagnosis and treatment of *Babesia odocoilei* in captive reindeer (*Rangifer tarandus tarandus*) and recognition of three novel host species. J Zoo Wildl Med. 2009;40(1):152-159. doi:10.1638/2008-0011.1.

2. Bastian S, Jouglin M, Brisseau N, et al. Antibody prevalence and molecular identification of *Babesia* spp. In roe deer in France. J Wildl Dis. 2012;48(2):416-424. doi:10.7589/0090-3558-48.2.416.

3. Hoby S, Mathis A, Doherr MG, Robert N, Ryser-Degiorgis M-P. *Babesia capreoli* infections in alpine chamois (*Rupicapra r. Rupicapra*), roe deer (*Capreolus c. Capreolus*) and red deer (*Cervus elaphus*) from Switzerland. J Wildl Dis. 2009;45(3):748-753. doi:10.7589/0090-3558-45.3.748.

4. Malandrin L, Jouglin M, Sun Y, Brisseau N, Chauvin A. Redescription of *Babesia capreoli* (Enigk and Friedhoff, 1962) from roe deer (*Capreolus capreolus*): Isolation, cultivation, host specificity, molecular characterisation and differentiation from Babesia divergens. Int J Parasitol. 2010;40(3):277-284. doi:10.1016/j.ijpara.2009.08.008.

EVALUATION OF A COMMERCIAL ELISA FOR DETECTION OF AVIAN INFLUENZA VIRUS SUBTYPE H5 ANTIBODIES IN 31 AVIAN SPECIES

Trine H. Jensen, DVM, PhD,[1,2]* Mads F. Bertelsen, DVM, DVSc, Dipl ACZM, Dipl ECZM (ZHM),[3] Charlotte K. Hjulsager, MSc, PhD,[4] Mariann Chriél, DVM, PhD,[4] and Jannie H. Andersen, MSc[1]

[1]Department of Chemistry and Bioscience, Aalborg University, Aalborg East, DK-9220, Denmark; [2]Aalborg Zoo, Aalborg, DK-9000, Denmark; [3]Copenhagen Zoo, Centre for Zoo and Wild Animal Health, Frederiksberg, DK-2000, Denmark; [4]National Veterinary Institute, Technical University of Denmark, Frederiksberg, DK-1870, Denmark

Abstract

Vaccination and surveillance programs for avian influenza virus (AIV) in exotic birds relying on the hemagglutination inhibition (HI) test have been established by a number of zoological institutions.[1-6] HI testing is the golden standard assay in domestic and exotic birds, although it has limitations regarding labor intensiveness and dependence on specific antigens and erythrocytes.[7] The present study compared the performance of the HI test with a commercial enzyme-linked immunosorbent assay (ELISA)[a] in detection of antibody titers against AIV subtype H5 in Danish zoos birds. The birds (n = 286) were vaccinated with a commercially available vaccine[b] and antibodies detected pre- and post vaccination using both HI and ELISA (n = 572 tests).

Using HI as the gold standard, the specificity of the ELISA was 94.2 (95% confidence interval (CI): 0.92-0.97) and the sensitivity 93.9 (95% CI: 0.91-0.97). The cut-off value for the ELISA was 35 (calculated as the ratio of the sample optic density to the negative control according to the manufacturer). There was no significant difference between the results of the two tests when statistically compared by McNemar's chi- square test (P = 0.86) and assessment of Kappa (κ=0.87). Differences in the seroconversion rates among and within different orders of birds were observed, similar to earlier findings.[1-6] Based on sensitivity, specificity and correlation between the two tests, this ELISA can be recommended as an alternative to HI test for screening of zoo bird sera for antibodies to AIV subtype H5.

[a]ID Screen® Influenza H5 Antibody Competition, IDvet
[b]France; Gallimune Flu H5N9, Merial, Milanofiori, Italy

Key words: *Avian influenza*, ELISA, H5, hemagglutination inhibition test

ACKNOWLEDGMENTS

The EU projects AVIFLU, FLUTEST and Aalborg Zoo Conservation Foundation are acknowledged for financial support.

LITERATURE CITED

1. Bertelsen MF, Klausen J, Holm E, Grøndahl C, Jørgensen PH. Serological response to vaccination against avian influenza in zoo-birds using an inactivated H5N9 vaccine. Vaccine. 2007;25:4345-4349.

2. Furger M, Hoop R, Steinmetz H, Eulenberger U, Hatt JM. Humoral immune response to avian influenza vaccination over a six-month period in different species of captive wild birds. Avian Dis. 2008;52:222-228.

3. Lécu A, Langhe CD, Petit T, Bernard F, Swam H. Serologic response and safety to vaccination against avian influenza using inactivated H5N2 vaccine in zoo bird. J Zoo Wildl Med. 2009;40(4):731-743.

4. Oh S, Martelli P, Hock OS, Luz S, Furley C, Chiek EJ, Wee LC, Keun NM. Field study on the use of inactivated H5N2 vaccine in avian species. Vet Rec. 2005;157:299-300.

5. Philippa J, Baas C, Beyer W, Bestebroer T, Fouchier R, Smith D, Schaftenaar W, Osterhaus A. Vaccination against highly pathogenic avian influenza H5N1 virus in zoos using an adjuvanted inactivated H5N2 vaccine. Vaccine. 2007;25:3800-3808.

6. Vergara-Alert J, Fernández-Bellon H, Busquets N, Alcántara G, Delclaux M, Pizarro B, Sánchez C, Sánchez A, Majó N, Darji A. Comprehensive serological analysis of two successive heterologous vaccines against H5N1 avian influenza virus in exotic birds in zoos. Clin Vaccine Immunol. 2011;697-706.

7. World Organization for Animal Health (OIE). Manual of diagnostic tests and vaccines for terrestrial animals. O.I.D. Épizooties. 2015 Available from: http://www.oie.int/fileadmin/Home/fr/Health_standards/tahm/2.03.04_AI.pdf

Angiostrongylus cantonensis IN A ZOOLIGICAL COLLECTION IN FLORIDA WITH AN ANTEMORTEM DIAGNOSIS AND SUCCESSFUL TREATMENT IN A WHITE-THROATED CAPUCHIN MONKEY (*Cebus capucinus*)

Justin F. Rosenberg, DVM,[1]* Heather S. Walden, MS, PhD,[2] Marjorie Bercier, DMV,[1] Kathy Russell, BS,[3] and James F. X. Wellehan, Jr., DVM, MS, PhD, Dipl ACZM, Dipl ACVM (Virology, Bacteriology/Mycology), Dipl ECZM (Herpetology)[1]

[1]Department of Small Animal Clinical Sciences, College of Veterinary Medicine, University of Florida, Gainesville, FL 32608 USA; [2]Infectious Diseases and Pathology, College of Veterinary Medicine, University of Florida, Gainesville, FL 32608 USA; [3]Santa Fe College Teaching Zoo, Gainesville, FL 32606 USA

Abstract

The rat lungworm, *Angiostrongylus cantonensis*, is considered the most common infectious cause of eosinophilic meningoencephalitis in the world.[3] It has been documented in a wide variety of animal species which serve as incidental hosts including humans, nonhuman primates, canids, equids, and birds.[2] Many of these species are commonly held within zoological collections. *A. cantonensis* was recently introduced in the southeastern United States, and to date, all reported confirmed nonhuman primate diagnoses in the US have been fatal.[5] The lifecycle involves the rat as definitive host and snails or slugs as intermediate hosts.[1] Incidental hosts become infected via ingestion of intermediate or paratenic hosts (undercooked or raw frogs, crustaceans, fish).[2] At a zoological collection in central Florida, preliminary data from 439 snails (*Bradybaena similaris*), 21 rats (*Rattus rattus*), and environmental rat fecal samples revealed positive results by PCR[4] as well as the presence of nematode larvae and adults. In addition to the environmental sampling, a single white-throated capuchin monkey (*Cebus capucinus*) from this collection presented with an acute onset of hind limb paraparesis. Cytology performed on a CSF sample revealed moderate eosinophilic pleocytosis and was positive for *A. cantonensis* by real time PCR. The monkey responded to fenbendazole therapy and is currently clinically normal. The known presence of *A. cantonensis* in the environment of this collection allowed the clinicians to obtain a rapid diagnosis, initiate treatment, and monitor clinical signs. *A. cantonensis* should be a differential diagnosis for neurologic animals as it continues to emerge as an infectious disease of concern.

Key words: *Angiostrongylus cantonensis*, emerging infectious disease, eosinophilic meningitis, nonhuman primate, rat lungworm, snails.

ACKNOWLEDGMENTS

The authors thank Sarah Purcell, Hollie Chiles, and Cindy Coalter for their assistance with the clinical case management. The authors also thank the keepers and care takers at Santa Fe College Teaching Zoo.

LITERATURE CITED

1. Cowie RH. Biology, systematics, life cycle, and distribution of *Angiostrongylus cantonensis*, the cause of rat lungworm disease. Hawaii J Med Public Health. 2013;72(6 Suppl 2):6-9.

2. Emerson JA, Walden HS, Peters RK, Farina LL, Fredholm DV, Qvarnstrom Y, Xayavong M, Bishop H, Slapcinsky J, McIntosh A, Wellehan JFX. Eosinophilic meningoencephalomyelitis in an orangutan (*Pongo pygmaeus*) caused by *Angiostrongylus cantonensis*. Vet Q. 2013;33(4):191-194.

3. Lindo JF, Waugh C, Hall J, Cunningham-Myrie C, Ashley D, Eberhard ML, Sullivan JJ, Bishop HS, Robinson DG, Holtz T, Robinson RD. Enzootic *Angiostrongylus cantonensis* in rats and snails after an outbreak of human eosinophilic meningitis, Jamaica. Emerg Infect Dis. 2002;8:324-326.

4. Qvarnstrom Y, da Silva AC, Teem JL, Hollingsworth R, Bishop H, Graeff-Teixeira C, da Silva AJ. Improved molecular detection of *Angiostrongylus cantonensis* in mollusks and other environmental samples with a species-specific internal transcribed spacer 1-based TaqMan assay. Appl Environ Microbiol. 2010;76:5287-5289.

5. Stockdale-Walden HD, Slapcinsky J, Qvarnstrom Y, McIntosh A, Bishop HS, Rosseland B. *Angiostrongylus cantonensis* in introduced gastropods in southern Florida. J Parasitol. 2015;101(2):156-159.

CYTOLOGIC CHARACTERIZATION OF MYELODYSPLASIA IN RETROVIRAL-INFECTED KOALAS (*Phascolarctos cinereus*)

Nicole I. Stacy, DVM, DrMedVet, Dipl ACVP,[1,4]* Bruce Rideout, DVM, PhD, Dipl ACVP,[2] John W. Harvey, DVM, PhD, Dipl ACVP,[3] Geoffrey W. Pye, BVSc, MSc, Dipl ACZM,[4] Amber Gillett, BVSc,[5] Christine L. Miller, DVM,[6] and Michael M. Garner, DVM, Dipl ACVP[7]

[1]Department of Large Animal Clinical Sciences, University of Florida, College of Veterinary Medicine, Gainesville, FL 32608 USA; [2]Wildlife Disease Laboratories, Institute for Conservation Research, San Diego Zoo Global, San Diego, CA 92112 USA; [3]Department of Physiological Sciences, University of Florida, College of Veterinary Medicine, Gainesville, FL 32608 USA; [4]Disney's Animals, Science and Environment, Disney's Animal Kingdom, Bay Lake, FL 32830 USA; [5]Australia Zoo Wildlife Hospital, Beerwah, 4519, Queensland Australia; [6]Former affiliation: Zoo Miami, Miami, FL 33177 USA; [7]Northwest ZooPath, 654 West Main, Monroe, WA 98272 USA

Abstract

The koala retroviruses (KoRVs) have been isolated from koalas in the wild as well as from koalas in zoological institutions worldwide.[2,3] KoRVs are closely related to retroviruses of gibbons, mice, cats, and humans,[1] in which these immunosuppressive viruses are linked to myelodysplasia, lymphoproliferative disease, and secondary infections.[4] With the high prevalence of lymphoid neoplasia in koalas, a causative relationship of KoRV is suspected, but not proven to date.[5] This study presents a detailed description of the hematologic manifestation of myelodysplastic changes observed in captive KoRV-infected koalas. Seven adult koalas with progressive weight loss presented with peripheral cytopenias, including moderate to severe nonregenerative anemia, neutropenia, and/or thrombocytopenia. Blood film evaluation revealed inappropriate rubricytosis with dysplastic nuclear changes, and hypersegmentation of neutrophils. Bone marrow examination showed variable cellularity with dysplasia in erythroid, myeloid, and megakaryocytic precursors, and ineffective hematopoiesis. Dyshematopoiesis was characterized by abnormal nuclear shapes, megaloblastic cells, micronuclei, binucleation, and maturational arrest in the erythroid cell line, hypersegmented neutrophils, and dwarf megakaryocytes. These morphologic findings are similar to those in myelodysplastic syndromes (MDS) of other species, in which MDS presumably indicates a preleukemic state.[4] It is concluded that myelodysplasia in KoRV-infected koalas can result in ineffective hematopoiesis with peripheral cytopenias, especially nonregenerative anemia and inappropriate rubricytosis. Myelodysplasia may be a direct or indirect effect from retroviral infection.

Key words: Blood, bone marrow, dysplasia, koala, retrovirus, rubricytosis

ACKNOWLEDGMENTS

The authors would like to thank Liz Post and Cathy Minogue of Northwest ZooPath for data retrieval, and the pathology staff and Laura Keener from San Diego Zoo Global for assistance with the cases and data retrieval. We also thank the Zoo Miami staff for assistance with medical care and clinical evaluations of one of the koala patients named "Budaru."

LITERATURE CITED

1. Denner J, Young PR. Koala retroviruses: characterization and impact on the life of koalas. Retrovirology 2013;10:108.

2. Eiden MV. A novel exogenous retrovirus isolated from koalas (*Phascolarctos cinereus*) with malignant neoplasias in a United States zoo. In: Pye GW, Johnson RN, Greenwood AD (eds.). The koala and its retroviruses: implications for sustainability and survival. Sydney (Australia): Australian Museum; 2014. p. 3-4.

3. Gillett AK. An examination of disease in captive Australian koalas (*Phascolarctos cinereus*) and potential links to koala retrovirus (KoRV). In: Pye GW, Johnson RN, Greenwood AD (eds.). The koala and its retroviruses: implications for sustainability and survival. Sydney (Australia): Australian Museum; 2014. p. 39-45.

4. Harvey JW. Veterinary Hematology: A Diagnostic Guide and Color Atlas. St. Louis (MO): Elsevier Saunders; 2012. p. 307-309.

5. Pye GW, Johnson RN, Greenwood AD. Koala retrovirus conclusion. The future of KoRV research - foundational and applied. In: Pye GW, Johnson RN, Greenwood AD (eds.). The koala and its retroviruses: implications for sustainability and survival. Sydney (Australia): Australian Museum; 2014. p. 103-105.

Bacillus cereus biovar *anthracis* KILLS ENDANGERED WILDLIFE IN CENTRAL AFRICAN REPUBLIC

Kim Grützmacher, DVM,[1]* Fee Zimmermann, DVM,[1] Constanze Hoffmann, DVM,[1] Susann Dupke, Dr rer nat,[3] Tianna Peller, BSc, MSc,[4] Anna Feistner, BSc, MSc, MBA, PhD,[4] Angelique Todd, BSc, MSc,[4] Ilka Herbinger, Dr rer nat,[2] Roland Grunow, Dr med,[3] Sébastien Calvignac-Spencer, PhD,[1] Silke R. Klee, Dr rer nat,[3] and Fabian H. Leendertz, DVM, Dr med vet, Dipl ECZM[1]

[1]Project group Epidemiology of Highly Pathogenic Microorganisms, Robert Koch-Institute, 13353 Berlin, Germany; [2]World Wildlife Foundation Germany, 10117 Berlin, Germany; [3]Center for Biological Threats and Special Pathogens, Robert Koch-Institute, 13353 Berlin, Germany; [4]World Wildlife Foundation CAR, Bangui, Central African Republic

Abstract

Bacillus cereus biovar anthracis (Bcbva) was first isolated from eight deceased western chimpanzees (*Pan troglodytes verus*) in Ivory Coast that died of anthrax-like disease in 2001.[3] This recently discovered pathogen combines the chromosomal background of *Bacillus cereus* with the virulence plasmids pXO1 and pXO2 of *Bacillus anthracis*. In 2004 and 2005 three more chimpanzees and one Western lowland gorilla (*Gorilla gorilla gorilla*) were killed by Bcbva in Cameroon.[4] Here we report further cases in a new species and wider geographic distribution. In 2012 a forest elephant (*Loxodonta cyclotis*) carcass and the remains of a central chimpanzee (*Pan troglodytes troglodytes*) were found in the same area in Central African Republic; samples were obtained from both animals. A few months later a western lowland gorilla died and nose swabs were taken. All samples tested positive using real-time PCR assays, targeting the pagA gene for pXO1, the capB gene for pXO2, and a marker specific for genomic island IV of Bcbva.[1,2] Isolates could be cultured from the elephant and gorilla samples. For further characterization full genome analyses were performed, revealing that these isolates, together with the ones from Ivory Coast and Cameroon, form a distinct clade within the *Bacillus cereus* complex. The finding of these isolates in the Congo Basin, and in a forest elephant, points towards a greater distribution and host range of Bcbva. Understanding the impact of these pathogenic bacteria on threatened wildlife species and scavenging humans is important for conservation and public health.

Key words: Anthrax, *Bacillus cereus*, *Bacillus anthracis*, great apes, forest elephant, *Loxodonta cyclotis*

ACKNOWLEDGMENTS

The authors would like to thank the government of the Central African Republic for long term support, especially the Ministère d'Eaux et Fôret, Chasse et Peche and the Ministère de l'Education Nationale, de l'Alphabetisation, de l'Enseignement Superieur, et de la Recherche. In particular we thank Jean-Baptiste Mamang-Kanga, Guian Zokoe and Christian Ndadet. We thank the staff of DSPA and especially of the Primate Habituation Programme, for logistical support in the field, and WWF for their support at DSPA and in Bangui. We would also like to thank the Hans-Böckler-Stiftung, EAZA Ape Conservation Fund, Leipzig Zoo and Gudrun Wibbelt for their support.

LITERATURE CITED

1. Ellerbrok H, Nattermann H, Ozel M, Beutin L, Appel B, Pauli G. Rapid and sensitive identification of pathogenic and apathogenic *Bacillus anthracis* by real-time PCR. FEMS Microbiol Lett. 2002;214:51-59.

2. Klee SR, Brzuszkiewicz EB, Nattermann H, Bruggemann H, Dupke S, Wollherr A, Franz T, Pauli G, Appel B, Liebl W, Couacy-Hymann E, Boesch C, Meyer FD, Leendertz FH, Ellerbrok H, Gottschalk G, Grunow R, Liesegang H. The genome of a *Bacillus* isolate causing anthrax in chimpanzees combines chromosomal properties of *B. cereus* with *B. anthracis* virulence plasmids. PLoS ONE 2010;5:e10986.

3. Leendertz FH, Ellerbrok H, Boesch C, Couacy-Hymann E, Mätz-Rensing K, Hakenbeck R, Bergmann C, Abaza P, Junglen S, Moebius Y, Vigilant L, Formenty P, Pauli G. Anthrax kills wild chimpanzees in a tropical rainforest. Nature 2004;430 (6998):451-452.

4. Leendertz FH, Lankester F, Guislain P, Néel C, Drori O, Dupain J, Speede S, Reed P, Wolfe ND, Loul S, Mpoudi-Ngole E, Peeters M, Boesch C, Pauli G, Ellerbrok H, Leroy EM. Anthrax in Western and Central African great apes. Am J Primatol. 2006;68 (9):928-933.

BRONCHOALVEOLAR LAVAGE TECHNIQUE: A NEW APPROACH FOR DIAGNOSIS OF TUBERCULOSIS INFECTION IN ELEPHANTS

Thomas B. Hildebrandt, DrMedVet, HonFRCVS, Dipl ECZM,[1]* Joseph Saragusty, DVM, PhD,[1] Irmgard Moser, DrMedVet, PhD,[2] Susanne Holtze, DrMedVet,[1] Thomas Voracek, DrMedVet,[3] Andreas Bernhard, DrMedVet,[4] Tim Bouts, DVM,[5] Frank Göritz, DrMedVet,[1] and Robert Hermes, DrMedVet, PhD[1]

[1]Department of Reproduction Management, Leibniz Institute for Zoo and Wildlife Research, D-10315 Berlin, Germany; [2]National Reference Laboratory for Tuberculosis, Institute for Molecular Pathogenesis, Friedrich-Loeffler-Institut, D-17493 Greifswald - Insel Riems, Germany; [3]Tieraerztliche Ordination Tiergarten Schoenbrunn, A-1130 Vienna, Austria; [4]Zoo Leipzig GmbH, D-04105 Leipzig, Germany; [5]Park Pairi Daiza, Domaine de Cambron in B-7940 Brugelette, Belgium

Abstract

Tuberculosis in pachyderms was put into the spotlight two decades ago when circus elephants in North America were diagnosed with *Mycobacterium tuberculosis* complex. Because of the close association between elephants and humans, zoonotic risk, and high susceptibility to *Mycobacterium tuberculosis*, periodic testing was enacted in many zoological institutions around the world.[1,2] Presently the gold standard is bacterial culture of trunk wash. Trunk wash, however, puts the operator at risk, it is insensitive, and is prone to contamination. We describe here a new technique that increases the safety and sensitivity while reducing the risk of cross-contamination. It was applied in one male and five female African and one male and three female Asian elephants. The technique relies on performing standing sedation with butorphanol 0.1 mg/kg combined with detomedine hydrochloride 0.02 mg/kg i.m. and additional nerve blocks in four locations to the trunk base 10 ml per location lidocaine hydrochloride 2%. A customized 3.5-m long videochip endoscope is inserted through the trunk and up to the larynx or the trachea. A sterile newly developed 6-hole-TBH-catheter named after inventor Thomas Bernd Hildebrandt with a length of 6 m is then placed through the 4 mm working channel of the endoscope further into the respiratory system. The lavage is performed using up to 100 ml sterile saline solution. Collection of the sample is done in closed system. The technique is safe for the operator, and has higher probability of harvesting the bacteria when such are shed while keeping environmental and trunk-related contamination to a minimum.

Key words: Bronchoalveolar lavage, elephants, *Elephas maximus*, endoscopy, *Loxodonta africana*, *Mycobacterium tuberculosis* complex, standing sedation, truncal nerve block

ACKNOWLEDGMENTS

The authors would like to thank the elephant staff from Leipzig Zoo, Tiergarten Schoenbrunn, Park Pairi Daiza, Usti Zoo, Zoo Le Pal, Knowsley Safari.

LITERATURE CITED

1. Mikota SK, Larsen RS, Montali RJ. Tuberculosis in elephants in North America. Zoo Biol. 2000;19:393-403.

2. Mikota SK, Maslow JN. Tuberculosis at the human-animal interface: An emerging disease of elephants. Tuberculosis. 2011;91:208-211.

TO BE OR NOT TB: DIAGNOSIS OF TUBERCULOSIS IN A GROUP OF ASIAN ELEPHANTS (*Elephas maximus*)

Hanspeter Steinmetz, Dr med vet, Dipl ACZM, Dipl ECZM (Zoo Health Management)[1]* and Maja Rütten, Dr med vet, Dipl ECVP[2]

[1]Walter Zoo, 9200 Gossau, Switzerland; [2]University of Zurich, Vetsuisse Faculty, Institute for Veterinary Pathology, 8057 Zurich, Switzerland

Abstract

Animal and human health is inextricably interwoven; a good example is tuberculosis (TB). Although recognized as a disease of elephants for over 20 centuries, investigations into TB's prevalence in the captive Asian elephant (*Elephas maximus*) population only go back 20 yr.[3,4] The increasing problem of human TB combined with the susceptibility of elephants and the close contact between human and elephant, makes surveillance based on reliable early diagnosis essential.[3] Although the availability of diagnostics for clinical applications has improved in recent years, there is still a wide discrepancy between their sensitivities and specificities.[1,2]

In a group of 10 Asian elephants, tuberculosis was suspected from clinical observations and various clinical tests. Nevertheless, despite over 200 trunk washes being taken for analysis over a period of 14 mo, culture and RT-PCR tests for *M. tuberculosis* were negative. Three animals were euthanatized due to severe geriatric health problems. Pathologic examination revealed typical *M. tuberculosis* lesions in lung and lymph nodes. Culture and RT-PCR performed from the lesions, of postmortem collected tracheal secretions and of stomach wall tissues confirmed *M. tuberculosis* infection.

Based on these results, utilization of a combination of clinical signs (e.g., chronic weight loss), standard tests (e.g., comparative intradermal tuberculin test, trunk wash culture or PCR) and newer serologic tests (e.g., sero-diagnostic tests - Dual Path Platform [DPP] VetTB and multiantigen print immunoassay [MAPIA]), and repeated testing to increase antemortem validity are recommended. Gastric and bronchial lavage should also be investigated to improve accuracy of antemortem diagnostics.

Key words: Asian elephant, *Elephas maximus,* serologic testing, tuberculosis

ACKNOWLEDGMENTS

The authors would like to thank all keepers for the care of the animals.

LITERATURE CITED

1. Greenwald R, Lyashchenko O, Esfandiari J, et al. Highly accurate antibody assays for early and rapid detection of tuberculosis in African and Asian elephants. Clin Vaccine Immunol. 2009;16:605-612.

2. Lyashchenko KP, Greenwald R, Esfandiari J, et al. Tuberculosis in elephants: antibody responses to defined antigens of *Mycobacterium tuberculosis*, potential for early diagnosis, and monitoring of treatment. Clin Vaccine Immunol. 2006;13:722-732.

3. Maslow JN, Mikota SK. Tuberculosis in Elephants—A reemergent disease: diagnostic dilemmas, the natural history of infection, and new immunological tools. Vet Pathol. 2015;52:437-440.

4. World Health Organization (WHO). Global tuberculosis report 2014. Geneva (Switzerland): WHO Press; 2014.

THROMBOELASTOGRAPHY IN THE ASIAN ELEPHANT (*Elephas maximus*)

Kathryn L. Perrin, BVetMed,[1]* Annemarie T. Kristensen, DVM, PhD, Dipl ACIM-CA, Dipl ECVIM-CA,[2] Anne H. Krogh, DVM,[2] Louise Bochsen, MSc,[2] Wendy K. Kiso, PhD,[3] Dennis Schmitt, DVM, PhD, Dipl ACT,[3] Lauren Howard, DVM, Dipl ACZM,[4] and Mads F. Bertelsen, DVM, DVSc, Dipl ACZM, Dipl ECZM (Zoo Health Management)[1]

[1]Center for Zoo and Wild Animal Health, Copenhagen Zoo, Frederiksberg, 2000, Denmark; [2]Department of Small Animal Clinical Sciences, Faculty of life Sciences, University of Copenhagen, Frederiksberg, DK-1870, Denmark; [3]Ringling Bros. Center for Elephant Conservation, Polk City, FL 33868 USA; [4]Houston Zoo, Houston, TX 77030 USA

Abstract

Reproductive disease and elephant endotheliotropic herpesvirus-hemorrhagic disease (EEHV-HD) are the most common causes of bleeding disorders in Asian elephants (*Elephas maximus*). A recent report of the management of a case of EEHV-HD described the use of thromboelastography (TEG) to presumptively diagnose and direct treatment.[1] In this fatal case, extreme hypocoagulability was evident, however for successful case outcome, earlier diagnosis of more subtle hemostatic changes are required. Therefore the objective for this study was to establish reference ranges for TEG values in Asian elephants.

Citrated whole blood samples were obtained using behavioural restraint from 44 (11.33) Asian elephants from four captive collections. Kaolin activated whole blood thromboelastography was performed at 60 min post-sampling and again at 24 hr post-sampling in order to replicate the effects of chilled transport to a laboratory. Significant differences were seen between the two analysis periods, with those analyzed at 24 hr having a shorter reaction time (R; median 1.9 mins, range 1.2-3.0 min) and decreased clot strength (MA; median 77.8 mm, range 71.1-82.8 mm) when compared to those analyzed at 60 min (R; median 4.9 min, range 2.2-7.3 min, MA; median 81.3 mm, range 74.3-85.3 mm). Apparent pregnancy-related hypercoagulability characterised by shorter R times and an increased alpha angle was observed in three females.

Storage conditions and duration should be taken into consideration. Appropriate reference intervals should be used when interpreting TEG results.

Key words: Asian elephant, coagulation, *Elephas maximus,* TEG, thromboelastography

ACKNOWLEDGMENTS

The authors would like to thank Nathalie Wissink and the staff at Woburn Safari Park and Fieke Molenaar, Jo Dodds and the staff at ZSL Whipsnade Zoo for their help in contributing blood samples for this project as well as Peter Fischer for the loan of the TEG machines and technical assistance.

LITERATURE CITED

1. Perrin KL, Kristensen AT, Krogh AKH, Grøndahl C, Bertelsen MF. Thromboelastography-guided diagnosis and therapy in case of elephant endotheliotropic herpesvirus hemorrhagic disease. Proc Am Assoc Zoo Vet; 2015. p. 84-85.

A COMPARISON OF OXIDATIVE STRESS MARKERS AND ANTIOXIDANT STATUS IN TWO SPECIES OF RHINOCEROS, *Diceros bicornis* AND *Ceratotherium simum*

Daniel V. Fredholm, MS, DVM, Dipl ACZM,[1,2]* Justin W. Shmalberg, DVM, Dipl ACVN, Dipl ACVSMR,[1] Karen C. Scott, PhD,[1] and Natalie D. Mylniczenko, MS, DVM, Dipl ACZM[2]

[1]Department of Small Animal Clinical Sciences, College of Veterinary Medicine, University of Florida, Gainesville, FL 32608 USA; [2]Disney's Animal Programs and Environmental Initiatives, Lake Buena Vista, FL 32830 USA

Abstract

Captive black rhinoceroses (*Diceros bicornis*) are prone to developing iron overload disorder (IOD), a chronic, progressive accumulation of iron, usually in the form of hemosiderosis. An epidemiologic relationship between IOD and a variety of disease syndromes in captive black rhinoceroses has been suggested.[1,3-8] Neither IOD, nor any of the aforementioned syndromes have been reported in white rhinoceroses (*Ceratotherium simum*). A logical, albeit unproven, pathogenic link between IOD and these diseases in black rhinoceroses is oxidative stress secondary to iron toxicity. The measurement of thiobarbituric acid-reactive substances (TBARS), which are products of lipid peroxidation, can be used to objectively measure oxidative stress.[2] This study compared TBARS, oxidized low-density lipoprotein (oxLDL), and other markers of oxidative stress, along with measures of antioxidant status in healthy, captive black rhinoceroses and white rhinoceroses. The mean value ± SD for TBARS in black rhinoceroses was 1.63 ± 0.26 nmol/ml, and for white rhinoceroses was 1.63 ± 0.31 nmol/ml (P = 0.96). No significant difference was observed between species for any of the oxidative stress markers measured, or when comparing age, sex, and location (i.e., sampling institution) of animal. Significant differences between species were found for mean values of ascorbic acid and retinol, but not for any other antioxidant markers. Within the sample population, these data show no significant differences between markers of oxidative stress in these two species of clinically normal rhinoceroses. This may suggest that captive black rhinoceroses do not experience significantly more oxidative stress than captive white rhinoceroses, although further studies are needed.

Key words: Black rhinoceros, *Ceratotherum simum*, *Diceros bicornis*, oxidative stress, TBARS, white rhinoceros

ACKNOWLEDGMENTS

The authors would like to thank the veterinary and husbandry staffs of Busch Gardens Tampa Bay, Disney's Animal Kingdom, Zoo Miami, and White Oak Conservation for their participation in the study.

LITERATURE CITED

1. Chaplin H, Malacek AC, Miller RE, Bell CE, Gray LS, Hunter, VL. Acute intravascular hemolytic anemia in the black rhinoceros: hematologic and immunohematologic observations. Am J Vet Res. 1986;47:1313-1320.

2. Dawn-Linsley M, Ekinci FJ, Ortiz D, Rogers E, Shea TB. Monitoring thiobarbituric acid-reactive substances (TBARs) as an assay for oxidative damage in neuronal cultures and central nervous system. J Neurosci Meth. 2005;141:219-222.

3. Dennis PM, Funk JA, Rajala-Schultz PJ, Blumer ES, Miller RE, Wittum TE, Saville WJA. "A review of some of the health issues of captive black rhinoceroses (*Diceros bicornis*)." J Zoo Wildl Med. 2007;38:509-517.

4. Miller RE, Boever WJ. Fatal hemolytic anemia in the black rhinoceros: case report and a survey. J Am Vet Med Assoc. 1982;181:1228-1231.

5. Munson L, Koehler JW, Wilkinson JE, Miller RE. Vesicular and ulcerative dermatopathy resembling superficial necrolytic dermatitis in captive black rhinoceroses (*Diceros bicornis*). Vet Pathol. 1998;35:31-42.

6. Murray S, Lung NP, Alvarado TP, Gamble KC, Miller MA, Paglia DE, Montali RJ. Idiopathic hemorrhagic vasculopathy syndrome in seven black rhinoceros. J Am Vet Med Assoc. 2000;216:230-233.

7. Paglia DE, Dennis P. Role of chronic iron overload in multiple disorders of captive black rhinoceroses (*Diceros bicornis*). Proc Am Assoc Zoo Vet; 1999. p 163-170.

8. Paglia DE, Kenny DE, Dierenfeld ES, Tsu IH. Role of excessive maternal iron in the pathogenesis of congenital leukoencephalomalacia in captive black rhinoceroses (*Diceros bicornis*). Am J Vet Res. 2001;62:343-349.

SPERM QUALITY OF WILD AFRICAN ELEPHANT BULLS: WHAT CAN BODY AND ULTRASOUND MEASUREMENTS TELL US?

Frank Goeritz, Dr med vet,[1]* Joseph Saragusty, DVM,[1] Robert Hermes, Dr med vet, PhD,[1] Romain Potier, DVM,[2] Paul Bartels, DVM,[3] Barbara Baker, DVM,[4] and Thomas B. Hildebrandt, Dr med vet, Dipl ECZM[1]

[1]Leibniz Institute for Zoo and Wildlife Research (IZW), D-10315 Berlin, Germany; [2]FauneVet, 44200 Nantes, France; [3]Department Nature Conservation, Tshwane University of Technology, Pretoria, South Africa; [4]Pittsburgh Zoo and PPG Aquarium, Pittsburgh, PA 15206 USA

Abstract

Quality of elephant sperm at collection is highly unpredictable, turning many collection attempts into expensive and futile procedures. In an attempt to tackle this problem, we searched for external features that might predict the expected quality of the sperm sample to be collected.[1] During 31 procedures in 14 wild African elephant bulls external body measurements and ultrasonographic measurements of the reproductive tract organs were collected and correlated with sperm characteristics for the same bulls.[1] Comparison between seasons (wet and dry) was also done. Results indicate that the external body measurements were highly correlated to each other and to the bulls' age, facilitating the generation of a synthetic *body.size* index. No association was found between this index and the internal ultrasonographic measurements with the exception of the ampullary gland area (rho = 0.63, P = 0.015, n = 14) and the volume of the prostate (rho = 0.75, P = 0.0022, n = 14). The *body.size* index was also not associated with any of the sperm characteristics and the only ultrasonographic measurement associated with the sperm was the ampullary gland area. Sperm characteristics were also not associated with the status of the temporal gland (acting as a proxy for status in musth). We also found no difference between seasons in any of the ultrasonographic measurements or sperm characteristics. Our results suggest that external body measurements cannot predict sperm quality. Bulls will need to go through ultrasonographic evaluation and semen collection to determine their suitability to act as sperm donors.[2]

Key words: African elephants, anatomy, *Loxodonta africana*, morphology, reproduction, sperm, ultrasonography

ACKNOWLEDGMENTS

The authors would like to thank CatchCo Africa for the elephants capture and Christine Reusch, Alexandre Courtiol and Stephanie Kramer-Schadt from IZW for statistical analysis

LITERATURE CITED

1. Devkota B, Koseki T, Matsui M, Sasaki M, Kaneko E, Miyamoto A, Amaya Montoya C & Miyake Y-I. Relationships among age, body weight, scrotal circumference, semen quality and peripheral testosterone and estradiol concentrations in pubertal and postpubertal Holstein bulls. J Vet Med Sci. 2008;70:119-121. Available from doi: 10.1292/jvms.70.119

2. Hildebrandt TB, Hermes R, Saragusty J, Potier R, Schwammer HM, Balfanz F, Vielgrader H, Baker B, Bartels P, Göritz F. Enriching the captive elephant population genetic pool through artificial insemination with frozen-thawed semen collected in the wild. Theriogenology. 2012;78:1398-1404.

TWENTY YEARS OF EXPERIENCE REHABILITATING ORPHANED ASIAN ELEPHANT (*Elephas maximus*) CALVES IN SRI LANKA

B. Vijitha Perera, BVSc, MSc, MSc, Cert. Endangered Species Management,* Suhada Jayawardena, BVSc, MSc, Neshma Kumudini, BVSc, Mphil, and Tharaka Prasad, BVSc, MSc

Department of Wildlife Conservation, Elephant Transit Home, Udawalawe 70190, Sri Lanka

Abstract

Approximately 6000 wild elephants are present on the island nation of Sri Lanka. During the past 2 decades, about 200 elephants have died and 15 elephant calves have been orphaned annually in human elephant conflicts. The Elephant Transit Home (ETH) in Sri Lanka was established in 1995 for the rescue and rehabilitation of orphaned elephant calves. Since then, ETH has received 301 orphaned elephant calves from all over the country, 181 males and 120 females. Ages were less than 1 wk: 14 (5%), 1 wk-3 mo: 103 (34%), 3 mo-1 yr: 98 (33%), 1-2 yr: 46 (15%), over 2 yr: 40 (13%). Usually orphaned elephant calves are found in the areas where human elephant conflict is intense. When detecting the orphaned calves they are in critical condition due to dehydration, starvation, poor body condition, heavy parasitic burden, infected wounds and congenital abnormalities. Of the elephants received, 137 (46%) died and 112 (86%) of the mortalities occurred within 2 mo of arrival and five of them while transporting to the ETH. ETH developed a process for rehabilitation and release of orphaned elephants by empirical methods, and has released 99 animals (males 51/female 48) back into the wild, where they have been tracked and monitored. Only 7 (5 male/2 female) deaths have been recorded among the released elephants and 14 of the released females have born claves. ETH also has transferred 21 (16 male/5 female) elephant calves to other elephant facilities. As of November 2015, 43 elephant calves were undergoing rehabilitation in ETH. Conflicts over space and resources between elephants and people appear to be the principal source of orphaned elephants in Sri Lanka, although some weak calves may become orphans as a result of rejection by their mothers. The high mortality of elephant calves has occurred mostly soon after arrival at the ETH. The successful integration of released elephants with their wild counterparts and the reproduction observed in released females are the major indicators of success of this rehabilitation program.

Key words: Asian elephant, *Elephas maximus*, orphan rehabilitation, Sri Lanka

CARDIOPULMONARY EFFECTS OF ETORPHINE IN IMMOBILIZED WHITE RHINOCEROS (*Ceratotherium simum*) AND SUBSEQUENT INTRAVENOUS ADMINISTRATION OF BUTORPHANOL

Peter Buss, BVSc, MMedVet,[1,3,5]* Michele Miller, DVM, PhD,[2] Andrea Fuller, BSc (Hons), PhD,[3,5] Anna Haw, BVSc,[3] Rachel Wanty, BSc,[4] Francisco Olea-Popelka, DVM, PhD,[4] and Leith Meyer, BVSc, PhD [3,5]

[1]Veterinary Wildlife Services, South African National Parks, Kruger National Park, Private Bag X402, Skukuza 1350, South Africa; [2]Department of Science and Technology/National Research Foundation Centre of Excellence for Biomedical Tuberculosis Research, Medical Research Council Centre for TB Research, Division of Molecular Biology and Human Genetics, Stellenbosch University, Cape Town, South Africa; [3]Brain Function Research Group, School of Physiology, Faculty of Health Sciences, University of the Witwatersrand, South Africa; [4]Colorado State University, College of Veterinary Medicine and Biomedical Science, Department of Clinical Sciences, Fort Collins, CO 80523 USA; [5]Department of Paraclinical Sciences, Faculty of Veterinary Science, University of Pretoria, Onderstepoort 0002, South Africa

Abstract

Chemical capture is an essential tool in the management of free-ranging white rhinoceros. Etorphine results in rapid central nervous system depression following intramuscular administration in rhinoceros.[2] Etorphine is combined with azaperone to reduce induction times, and this combination is associated with hypoxemia and hypercapnia in white rhinoceros.[4] Butorphanol, a mixed opioid agonist - antagonist, is frequently administered intravenously in immobilized rhinoceros to mitigate these adverse effects; however, variable and inconsistent improvements in oxygen and carbon dioxide arterial tensions have been reported.[1,3-5] The objectives of our study were to determine the cardiopulmonary effects of etorphine in immobilized white rhinoceros and changes associated with intravenous administration of butorphanol.

Etorphine (1000-1250 kg, 2.5 mg; 1250-1500 kg, 3.0 mg) immobilized rhinoceros developed hypoxemia (PaO_2 = 25mmHg) and hypercapnia ($PaCO_2$ = 76 mmHg). Preliminary data analysis suggests that these blood gas values were not due to hypoventilation, but rather a marked increase in both alveolar-to-arterial oxygen gradient ($P(A\text{-}a)O_2$) and oxygen consumption due to an increase in metabolic rate. Intravenous administration of butorphanol (10 times the etorphine dose, mg) resulted in improved arterial oxygen (PaO_2 = 25-48 mmHg) and carbon dioxide ($PaCO_2$ = 76-62 mmHg) tensions. Minute ventilation, $P(A\text{-}a)O_2$, physiologic dead space and alveolar ventilation fractions did not change significantly; however, there was a decrease in oxygen consumption associated with reduced skeletal muscle activity (tremors). Contrary to previous observations, these results suggest that improved blood gas values in etorphine immobilized white rhinoceros following butorphanol administration were not due to improvements in respiratory function, but rather as a result of changes in metabolic oxygen requirements.

Key words: Blood gases, butorphanol, cardiopulmonary, *Ceratotherium simum*, etorphine, metabolism, white rhinoceros

ACKNOWLEDGMENTS

The authors thank Markus Hofmeyr, Marius Kruger, Milandie Kruger, Leana Rossouw, Guy Hausler and boma staff of Veterinary Wildlife Services, Kruger National Park. The assistance of members of the Brain Function Research Group, University of Witwatersrand Medical School, and staff and students of the Faculty of Veterinary Science, University of Pretoria, is also acknowledged. Financial and in-kind support was provided by South African National Parks. The project was supported by funding grants from the South African Veterinary Foundation and University of Witwatersrand.

LITERATURE CITED

1. Boardman WSJ, Caraguel CGB, Raath JP, Van Zijll Langhout M. Intravenous butorphanol improves cardiopulmonary parameters in game-ranched white rhinoceroses (*Ceratotherium simum*) immobilized with etorphine and azaperone. J Wildl Dis. 2014;50:849-857.

2. Burroughs R, Hofmeyr M, Morkel P, Kock MD, Kock R, Meltzer D. Chemical immobilization - individual species requirements. In: Kock MD, Burroughs R (eds.). Chemical and physical restraint of wild animals. A training and field manual for African species, 2nd ed. Greyton (South Africa): International Wildlife Veterinary Services; 2012. p. 143-264.

3. Buss PB, Olea-Popelka F, Meyer L, Hofmeyr J, Mathebula N, Kruger M, Brüns A, Martin L, Miller M. Evaluation of cardiorespiratory, blood gas, and lactate values during extended immobilization of white rhinoceros. J Zoo Wildl Med. 2015;46(2):224-233.

4. Haw A, Hofmeyr M, Fuller A, Buss P, Miller M, Fleming G, Meyer L. Butorphanol with oxygen insufflation corrects etorphine-induced hypoxaemia in chemically immobilized white rhinoceros (*Ceratotherium simum*). BMC Vet Res. 2014;10(253):1-9.

5. Miller DVM, Buss P, Joubert J, Mathebula N, Kruger M, Martin L, Hofmeyr M, Olea-Popelka F. Use of butorphanol during immobilization of free-ranging white rhinoceros (*Ceratotherium simum*). J Zoo Wildl Med. 2013;44(1):55-61.

SUCCESSFUL TREATMENT OF DIGITAL OSTEITIS AND ARTHRITIS BY INTRAVENOUS REGIONAL PERFUSION OF CEFTIOFUR IN AN AFRICAN ELEPHANT (*Loxodonta africana*)

Christopher J. Dutton, BVSc, MSc, Dipl ECZM, Dipl ACZM,* Pauline G. Delnatte, DMV, DVSc, Dipl ACZM, Simon R. Hollamby, BVSc, MS, Dipl ACZM, and Graham J. Crawshaw, BVetMed, Dipl ACZM

Toronto Zoo, 361A Old Finch Avenue, Scarborough, Ontario M1B 5K7 Canada

Abstract

A 41-yr-old African elephant (*Loxodonta africana*) presented with a swollen third digit of the left forelimb and a 2-cm hole in the pad. Corrective trimming, topical treatments, and an oral antibiotic resulted in apparent resolution, however, it reoccurred after 4 mo. Radiographs suggested chronic infective arthritis of the distal interphalangeal joint and septic osteitis of the third phalanx. Flushing with metronidazole solution (metronidazole 5 mg/ml injection, Baxter Corporation, Mississauga, Ontario L5N 0C2 Canada) and intravenous regional perfusion (IVRP) of the foot were commenced. For IVRP, the elephant was trained in a protected contact situation to present the foot outside the enclosure and rest it on a horizontal bar. A tourniquet was applied just above the carpus. An interdigital vein was identified by ultrasound, and into this vein 2 g (20 ml) of ceftiofur sodium solution (Excenel Sterile Powder, Zoetis Canada, Kirkland, Quebec H9J 2M5 Canada) followed by 60 ml of heparinized saline were administered over 90 sec. The foot was kept raised for 25 min and then the tourniquet removed. IVRP was repeated every other day for 70 treatments over 6 mo. Healing occurred, and this was confirmed radiographically. IVRP offers an excellent treatment modality in a well-trained elephant.

Key words: African elephant, ceftiofur, digital arthritis, digital osteitis, intravenous regional perfusion, *Loxodonta africana*

MEDICAL MANAGEMENT AND INTENSIVE CARE IN A NORTHERN WHITE RHINOCEROS (*Ceratotherium simum cottoni*)

Meredith M. Clancy, DVM, MPH,[1]* Katie W. Delk, DVM,[1] Jim Oosterhuis, DVM,[1] Allan Pessier, DVM, Dipl ACVP,[2] and Nadine Lamberski, DVM, Dipl ACZM[1]

[1]San Diego Zoo Safari Park, San Diego Zoo Global, Escondido, CA 92027 USA; [2]Wildlife Disease Laboratory, San Diego Zoo Global, San Diego, CA 92112 USA

Abstract

Medical management of megavertebrates can be challenging as their large size can limit the scope of diagnostics possible, increase the risk of restraint, and reduce therapeutic options available. Additionally, megavertebrates are charismatic and high profile animals, and end of life decisions typically involve lengthy deliberation and multiple invested parties. Delivery of intensive care is possible with appropriate teamwork and planning, as recently demonstrated by a case at the San Diego Zoo Safari Park. The guiding tenets of case management were identification of stakeholders for communication, step-wise and serial diagnostics, systematic review of therapeutic options, including use of consultants as needed, contingency planning for emergency situations, and finally health assessment and evaluation of quality of life.

A 41-yr-old northern white rhino (*Ceratotherium simum cottoni*) presented acutely in May 2015 with a subcutaneous abscess growing beta-hemolytic *Streptococcus* sp. While significant evacuation of purulent material was performed, complete resolution of the abscess could not be achieved due to the position of the abscess and difficulty in locating a ventral drainage site. Antimicrobials were prescribed (trimethoprim and sulfadiazine oral antibiotic powder, Uniprim®, 20 mg/kg p.o., s.i.d.) in May and after recurrence of abscess and drainage in August, but compliance was intermittent. Over the following months, more aggressive medical and eventually surgical management was employed in an attempt to resolve this acute medical issue, while other more chronic medical issues, such as ileus and urinary tract infection, were investigated and managed.

Using a combination of behavioral, chemical, and mechanical (chute) restraint, multiple investigative procedures were performed to better elucidate the disease process. Chute restraint and/or sedation (butorphanol, 20µg/kg i.m. ± medetomidine, 7.5 µg/kg i.m., or diazepam, 200-250 µg/kg) allowed for protected contact and more invasive diagnostics, including serial rectal and transcutaneous ultrasounds, without which antemortem diagnosis of the rhino's retroperitoneal abscess would not have been possible. Surgical drainage of one abscess was achieved under a combination of chute restraint and standing sedation. Serial blood sampling allowed for tracking of the case and identification of disease progression and health decline, seen as persistent elevation in fibrinogen and globulins, and hypoglycemia that became more profound prior to death.

Medical management included oral antibiotics and when compliance became poor, both rectal (doxycycline, 20 mg/kg p.o., b.i.d.) and parenteral antibiotics (tulathromycin Draxxin®, 2.5 mg/kg i.m., q7d), based on antimicrobial resistance patterns of repeat cultures. Rectal fluids, including those with added dextrose, were used to manage dehydration and hypoglycemia when other

alternatives, such as intravenous catheterization, was not feasible due to the animal's size and location. Other means of glucose support such as oral dextrose and a nasogastric tube were attempted but unsuccessful.

This case highlights the importance of regular health assessments and shows that intensive care can be achieved even in megavertebrate patients. This case also details the difference between palliative geriatric care for chronic issues and pursuit of diagnosis and curative medicine for more acute problems. Without losing sight of the larger picture in a case like this, step-wise medical management helped distinguish acute and chronic problems and identify treatment modalities possible. Also, through the establishment of quality of life parameters prior to identification of severe disease processes, an emotional and difficult decision can garner objective support among multiple important stakeholders.

Key words: Animal welfare, *Ceratotherium simum cottoni*, intensive care, medical management, northern white rhino, quality of life

EVALUATION OF NONINVASIVE OSCILLOMETRIC BLOOD PRESSURE MONITORING IN ANESTHETIZED BENNETT'S WALLABIES (*Macropus rufogriseus*)

Megan K. Watson, DVM, MS,[1]* Ashley Mitek, DVM,[2] and Sathya K. Chinnadurai, DVM, MS, Dipl ACZM, Dipl ACVAA[3]

[1]Illinois Zoological and Aquatic Animal Residency Program, 1008 W. Hazelwood Drive, Urbana, IL 61802 USA; [2]Department of Veterinary Clinical Medicine, University of Illinois, College of Veterinary Medicine, Urbana, IL 61802 USA; [3]Chicago Zoological Society, Brookfield Zoo, 3300 Golf Road, Brookfield, IL 60513 USA

Abstract

The objective of this study was to determine the precision and accuracy of a noninvasive oscillometric monitor in relation to invasively measured blood pressure in anesthetized Bennett's wallabies (*Macropus rufogriseus*). Six animals were anesthetized, intubated, and maintained on isoflurane throughout the procedure. Each animal was instrumented with an arterial catheter in the right medial metatarsal artery connected to a pressure transducer to obtain invasive measurements of systolic (SAP), diastolic (DAP), and mean (MAP) arterial blood pressure, as well as a pressure waveform. A cuff connected to an oscillometric device was placed on the base of the tail for noninvasive measurements. Paired data from noninvasive and invasive blood pressure measurements (SAP, DAP, and MAP) were obtained every 5 min for 60 min. Bland-Altman plots were used to compare invasive and non-invasive measurements and calculate bias and 95% limits of agreement (LOA) for SAP, DAP, and MAP. Bias for SAP is negligible (0.7882), but the LOA are wide (-44.98-46.56). For DAP and MAP, the bias is significant (DAP = 11.39; MAP = 5.187) and the LOA are again wide (DAP = -15.55-38.33; MAP = -16.97-27.34) In conclusion, when using an oscillometric blood pressure monitor on anesthetized Bennett's wallabies, veterinarians can potentially monitor changes and detect trends in blood pressure, although the displayed readings may not represent the true blood pressure measurement. Indirect measurements of blood pressure made with the oscillometric device cannot substitute for direct measurements.

Key words: Bennett's wallaby**,** blood pressure, macropod, *Macropus rufogriseus,* noninvasive, oscillometric

ADDAX ANTELOPE (*Addax nasomaculatus*) DIGESTIVE TRACT REACTION TO A CONCENTRATE OR FORAGE FEEDING REGIME

Stamatios A. Tahas, DVM, MSc, PGCert, MRCVS,[1]* Udo Hetzel, Dr rer nat, Dr med vet, MRCVS,[2] Olga Martin Jurado, Dr med vet,[1] Sven Hammer, Dr med vet,[3] Jean-Michel Hatt, Prof Dr med vet, MSc, Dipl ACZM, Dipl ECZM (avian),[1] and Marcus Clauss, Prof Dr med vet, MSc, Dipl ECVCN[1]

[1]Clinic for Zoo Animals, Exotic Pets and Wildlife, Vetsuisse Faculty, University of Zurich, Zurich, 8057, Switzerland; [2]Institute of Veterinary Pathology, Vetsuisse Faculty, University of Zurich, Zurich, 8057, Switzerland; [3]Zoo Görlitz, Görlitz, 02826, Germany

Abstract

Subacute ruminal acidosis remains a problem for captive ruminants but has rarely been investigated systematically.[1-3] As a pilot study, twelve surplus addax antelope (*Addax nasomaculatus*) were divided into two groups 3 mo prior to culling and fed either their usual diet, consisting of a concentrate feed with a limited amount of hay, or a diet of unlimited hay only. After culling, physiologic, macroscopic and microscopic measurements were compared between groups. While both groups had mesenteric, pericardial and perirenal adipose tissue, these depots were subjectively more pronounced in concentrate-fed animals. Hay-fed animals had significantly heavier individual filled gut compartments, with corresponding significantly longer linear measurements of the filled foregut structures. Masseter muscles, cranial ruminal pillars and primary omasal leaves were significantly more prominent in hay-fed animals. Pronounced group differences were noted on rumen histology. Hay-fed animals displayed a significantly thicker ruminal stratum corneum and marked cell ballooning whereas concentrate-fed animals displayed significantly higher levels of parakeratosis. Ruminal pH, often measured by zoo animal clinicians, did not differ between groups, but was more variable in concentrate-fed animals. In agreement with other studies, this indicates that ruminal histology is possibly more sensitive than a single post-mortem pH measurement in diagnosing subacute ruminal acidosis.[3] Therefore, histologic screening may be required for assessing the nutritional adequacy in ruminant collections. These results additionally indicate the adaptability of ruminant digestive tract anatomy in adult animals even after a short period of time.

Key words: Addax antelope, *Addax nasomaculatus*, anatomic adaptability, rumen histology, ruminal pH, subacute ruminal acidosis

LITERATURE CITED

1. Gattiker C, Espie I, Kotze A, Lane EP, Cordon D, Clauss M. Diet and diet-related disorders in captive ruminants at the National Zoological Gardens of South Africa. Zoo Biol. 2014;33:426-432

2. McCusker S, Shipley LA, Tollefson TN, Griffin M, Koutsos EA. Effects of starch and fibre in pelleted diets on nutritional status of mule deer (*Odocoileus hemionus*) fawns. J Anim Physiol Anim Nutr. 2011;95:489-498.

3. Schilcher B, Baumgartner K, Geyer H, Liesengang A. Investigations on rumen health of different wild ruminants in relation to feeding management. J Zoo Aquar Res. 2013;1:28-30.

A WAKE-UP CALL: RADIOGRAPHIC EVIDENCE OF FRONT FOOT FRACTURES AND OSTEOARTHRITIS IN RELATIVELY YOUNG RETICULATED GIRAFFE (*Giraffa camelopardalis reticulata*)

Liza Dadone, VMD,[1]* Francisco Olea-Popelka, DVM, PhD,[2] Eliza Stout, BS,[2] Eric Klaphake, DVM, Dipl ACZM, Dipl ABVP (Avian), Dipl ABVP (Reptile/Amphibian),[1] Matthew S. Johnson, VMD, Dipl ABVP (Avian),[2] and Myra Barrett, DVM, Dipl ACVP[2]

[1]Department of Animal Health, Cheyenne Mountain Zoo, 4250 Cheyenne Mtn. Zoo Rd, Colorado Springs, CO 80906 USA; [2]College of Veterinary Medicine, Colorado State University, 300 W. Drake Rd., Fort Collins, CO 80523 USA

Abstract

Chronic limb lameness is a common health concern for giraffe at multiple zoos and may result in humane euthanasia if patients do not respond to medical management. Front foot radiographs from 22 giraffe at a single institution were analyzed to identify pedal fractures and coffin joint osteoarthritis (OA). For pedal osteitis, severity was rated from 0-3, with 3 as the most severe. Eight of 22 (36%) giraffe had pedal fractures at the site of the deep digital flexor attachment, with the youngest being 10 yr. There was a significant ($P = 0.044$) difference in the median age of giraffe with fractures (median = 13.5 yr) compared to those without fractures (median = 6.5 yr). There was no significant difference associated with giraffe weight and the presence/absence of fractures. The presence of osteitis significantly ($P < 0.001$) increased the risk of fracture. Giraffe phalanges with osteitis level 0 or 1 had no fractures, (3/16; 18.75%) of phalanges with osteitis level 2 had a fracture, and the majority (13/17; 76.47%) of phalanges with osteitis level 3 had a fracture. Sixteen of 22 (73%) giraffe had coffin joint OA in at least one front foot. All of the giraffes with radiographic evidence of coffin joint OA were at least 5 yr of age. Giraffe can develop radiographic evidence of front foot pedal fractures and OA at a relatively young age, so routine radiographs may allow identification of early disease and present opportunity for early intervention/prevention.

Key words: Foot fractures, *Giraffa camelopardalis reticulate,* giraffe, radiograph

ACKNOWLEDGMENTS

Thanks to the Animal and Veterinary Staff at the Cheyenne Mountain Zoo for training and taking radiographs of the giraffe herd.

IMMOBILIZING MUSK OX (*Ovibos moschatus*) IN HIGH ARCTIC CONDITIONS

Carsten Grøndahl, DVM, PhD,[1]* Emilie Andersen-Ranberg, DVM,[1,3] Jesper Bruun Mosbacher, MSc,[2] Mikkel Stelvig, MSc,[1] Lars Holst Hansen, MSc,[2] and Niels Martin Schmidt, MSc, PhD[2]

[1]Copenhagen Zoo, Centre for Zoo and Wild Animal Health, Roskildevej 38, Frederiksberg, DK-2000, Denmark; [2]Arctic Research Centre, Department of Bioscience, Aarhus University, Frederiksborgvej 399, DK-4000 Roskilde, Denmark; [3]Tierärztliche Hochschule Hannover, Institut für Terrestrische und Aquatische Wildtierforschung, Werftstr. 6, 25761 Büsum, Germany

Abstract

Immobilizing animals in the high Arctic (74˚N lat.) holds several challenges. As part of an on-going environmental project concerning ungulate movement ecology in the Wollaston Forland region, in Northeast Greenland, we immobilized a total of 14 and 15 female musk oxen (*Ovibos moschatus*) in October 2013 and October 2015, respectively. Several samples and measurements were obtained from the immobilized animals, and the musk oxen were also fitted with GPS satellite collars (Tellus Large by FollowIt). Immobilization regimen and doses were 2 mg etorphine + 30 mg xylazine + 0.3 mg medetomidine + 40 mg ketamine. Similar doses were used by Clausen et al. (1984),[2] while significantly higher doses were used by Blix et al. (2011)[1] (8-10 mg etorphine), and Jingfors and Gunn (1989)[3] (7-8 mg etorphine).

In 2015, various respiratory and cardiovascular parameters were measured which included respiratory rate, end tidal CO_2 via a nasal cannula connected to a capnometer (Emma Mainstream Capnometer by Masimo), blood pressure, rectal temperature, pulse oximetry (petMAP+ by Ramsey Medical Inc.), venous pO_2, pCO_2, pH, bicarbonate, lactate and electrolytes (I-STAT by Abbott Point of Care). Systolic blood pressure mean and standard deviation (SD) for 15 animals immobilized in 2015 was 184.6 ± 33.3 mmHg. Respiratory rate and heart rate were 25.3 ± 4.6 rpm and 50.2 ± 25.2 bpm respectively. The supplemented oxygen resulted in acceptable pulse oximetry arterial saturations. Body temperature remained stable throughout.

In conclusion, we found it possible to immobilize adult musk oxen in Northeast Greenland, generating minimal pathophysiology, in ambient temperatures of -8 to -20˚C.

Key words: Blood pressure, etorphine, high Arctic, immobilization, musk ox*, Ovibos moschatus*, pulsoximetry

LITERATURE CITED

1. Blix AS, Lian H, Ness J. Immobilization of muskoxen (*Ovibos moschatus*) with etorphine and xylazine. Acta Vet Scand. 2011;53:42.

2. Clausen B, Hjort P, Strandgaard H, Sørensen PL. "Immobilization and tagging of muskoxen (*Ovibos moschatus*) in Jameson Land, northeastern Greenland." J Wildl Dis. 1984; 141-145.

3. Jingfors K, Gunn A. The use of snowmobiles in the drug immobilization of muskoxen. Can J Zool. 1989;1120-1121.

PARASITIC INFECTIONS DETECTED BY FLOTAC IN ZOO MAMMALS: INSIGHTS FROM THE FIELD

Michele Capasso, DVM, SPACS,* Emilio Noviello, DVM, Dario D'Ovidio, DVM, PhD, Dipl ECZM, Laura Rinaldi, BSC, PhD, Ass. EVPC and Giuseppe Cringoli, DMV, EVPC

Department of Veterinary Medicine and Animal Productions, University of Naples Federico II, Unit of Parasitology and Parasitic Disease, via della Veterinaria 1, 80137 Naples, Italy

Abstract

Introduction

Parasitologic diagnosis is still neglected in zoo animals; furthermore, it is not regularly performed before establishing any program of anthelmintic treatments. FLOTAC techniques are new multivalent, sensitive, accurate and precise methods for qualitative and quantitative copromicroscopic analysis.[1] The FLOTAC techniques are based on the centrifugal flotation of a fecal sample suspension and subsequent translation of the apical portion of the floating suspension. They have already been validated in veterinary and human parasitology for the detection of helminths and protozoa. The aim of this study was to use FLOTAC in order to perform field surveys to investigate the prevalence of gastrointestinal parasites in mammals housed in zoological gardens in Italy.

Material and Methods

From 2010 to 2014, a total of 268 pools of fecal samples were collected from various carnivorous (e.g., felines, mustelids, canids), hoofed mammals (e.g., ruminants, monogastric herbivores), marsupials, primates, rodents and chiropterans. All fecal samples were analyzed using the FLOTAC techniques, having a sensitivity of 2 eggs/larvae/oocysts per gram of feces (EPG/OPG/LPG).

Results

Parasitic elements were detected by FLOTAC in 53% of the pools examined and most of them showed multiple infections and different EPG/OPG values (min/max). Carnivorous resulted infected by *Toxascaris leonina* (8/968 EPG), *Trichuris* spp. (6/48 EPG), strongyles (8/968 EPG), *Capillaria* spp. (2/40 EPG) and pinworms (2/20 EPG). Hoofed mammals resulted positive to gastrointestinal strongyles (10/1059 EPG), *Nematodirus* (2/20 EPG), *Trichuris* spp. (2/348 EPG), *Capillaria* (2/80 EPG), ascarids (6/208 EPG) and coccidia (2/220 OPG). Intestinal strongyles were prevalent in marsupials (2/10 EPG). Primates were infected by *Trichuris* spp. (4/360 EPG), *Strongyloides* (2/20 EPG) and ascarids (2/24 EPG). Rodents and chiropterans were found negative at the testing.

Discussion

Monitoring the presence of parasites in zoo animals by sensitive and multivalent techniques as FLOTAC is fundamental to diagnose, control and prevent the spread of parasitic diseases among animals kept at zoo gardens to safeguard welfare and health of animals and humans.[2] It is desirable that the "FLOTAC strategy" is used to improve the quality of parasitologic diagnosis in zoo animals.

Key words: Fecal sample, FLOTAC, flotation, mammals, parasite, zoological garden

LITERATURE CITED

1. Cringoli G, Rinaldi L, Maurelli MP, Utzinger J. FLOTAC: new multivalent techniques for qualitative and quantitative copromicroscopic diagnosis of parasites in animals and humans. Nat Protoc. 2010;5:503-515.

2. Maesano G, Capasso M, Ianniello D, Cringoli G, Rinaldi L. Parasitic infections detected by FLOTAC in zoo mammals from Warsaw, Poland. Acta Parasitol. 2014;59:343-353.

Cryptococcus neoformans var. *grubii*-ASSOCIATED RENAL AMYLOIDOSIS CAUSING PROTEIN-LOSING NEPHROPATHY IN A RED KANGAROO (*Macropus rufus*)

Mary Irene Thurber, DVM,[1]* Jenessa Gjeltema, DVM,[2] Matthew Sheley, DVM,[3] and Ray F. Wack, DVM, Dipl ACZM[2]

[1]School of Veterinary Medicine, University of California Davis, Davis, CA 95616 USA; [2]Wildlife Health Center, University of California Davis School of Veterinary Medicine, Davis, CA 95616 USA; [3]Department of Pathology, Microbiology, and Immunology, University of California Davis School of Veterinary Medicine, Davis, CA 95616 USA

Abstract

A 10-yr-old male castrated red kangaroo (*Macropus rufus*) presented for a 24-hr history of mandibular swelling. Immobilization revealed pitting edema of the mandible and ventral neck, with no dental disease evident on physical exam or radiographs. Complete blood count, serum chemistry panel, and urinalysis results revealed a mild non-regenerative anemia, moderate azotemia, and a severely elevated urine protein to creatinine ratio (UPC: 9.9). Radiographs revealed a previously noted interstitial pattern of the caudal right lung lobe; abdominal ultrasound revealed scant effusion but no other abnormalities. Further diagnostic testing was considered, but symptomatic and empirical therapy was elected. Antibiotics, anti-inflammatory drugs, and an ACE inhibitor did not resolve clinical signs, although moderately improved the UPC (3.1). Due to poor prognosis and declining quality of life, euthanasia was elected. Necropsy revealed moderate multifocal chronic granulomatous pneumonia of the right caudal lung lobe with necrosis and intralesional *Cryptococcus* organisms, identified as *C. neoformans* var. *grubii* by DNA sequencing. Severe bilateral glomerular and tubulointerstitial as well as splenic amyloidosis was considered secondary to chronic cryptococcosis. The severe amyloidosis induced protein-losing nephropathy, leading to tri-cavitary effusion, subcutaneous edema, and cachexia. *C. neoformans* var. *grubii*, the underlying cause of 95% of human cryptococcosis cases worldwide,[1] is associated with eucalyptus trees,[2] which grow near this animal's enclosure. In one study in California, 33% of *Cryptococcus* cases in cats and dogs were caused by *C. neoformans* var. *grubii*.[3] To our knowledge, this is the first reported case of *Cryptococcus*-associated reactive systemic amyloidosis causing protein-losing nephropathy in a macropod.

Key words: *Cryptococcus neoformans* var. *grubii*, protein-losing nephropathy, red kangaroo (*Macropus rufus*), renal amyloidosis

ACKNOWLEDGMENTS

The authors would like to thank the animal care staff at the Sacramento Zoo for their dedication to the care of their animals.

LITERATURE CITED

1. Chayakulkeeree M, Perfect JR. Cryptococcosis. Infect Dis Clin North Am. 2006;20:507-544.

2. Gugnani H, Mitchell T, Litvintseva A, Lengeler K, Heitman J, Kumar A, Basu S, Paliwal-Joshi A. Isolation of *Cryptococcus gattii* and *Cryptococcus neoformans* var. *grubii* from the flowers and bark of Eucalyptus trees in India. Med Mycol J. 2005;43:565-569.

3. Singer LM, Meyer W, Firacative C, Thompson GR, Samitz E, Sykes JE. Antifungal drug susceptibility and phylogenetic diversity among *Cryptococcus* isolates from dogs and cats in North America. J Clin Microbiol. 2014;52:2061-2070.

FAILURE OF PASSIVE TRANSFER AND LEUKOPENIA IN FIVE RETICULATED GIRAFFE CALVES (*Giraffa camelopardalis reticulata*)

S. Emmanuelle Knafo, DVM,* Margaret Underwood, BS, and Daniela Bedenice, DVM, Dipl ACVIM, Dipl ACVECC

Cummings School of Veterinary Medicine at Tufts University, Department of Clinical Sciences, North Grafton, MA 01536 USA

Abstract

From 2009-2015, five reticulated giraffe calves (*Giraffa camelopardalis reticulata*) from the same institution presented to a veterinary teaching hospital with failure of passive transfer (FPT) and maternal rejection. Three male and two female calves were represented. Maternal investment of captive giraffes has been demonstrated to be unbiased between male and female calves.[1] Therefore, gender bias was not believed to be a factor in maternal rejection. Age at presentation ranged from 12 hr to 5 days old. All calves presented with total protein levels (TP) below 6.0g/dL, a cut off for FPT in giraffes, and received oral bovine colostrum, which successfully produced increases in TP and GGT.[2,3] Severe, persistent leukopenia, neutropenia, and hyperfibrinogenemia were documented in each calf. Supportive care regimens including specialized nursing techniques, intravenous fluids, bovine milk replacer, antimicrobials, vitamin E and selenium supplementation, and leukocyte growth factor (filgrastim, Neupogen®)[a] produced successful outcomes in all cases. The lineage of this herd was investigated, and giraffe neonatal care guidelines are described.

[a] Neupogen® 300mcg/ml, Amgen, Thousand Oaks, CA 91320 USA

Key words: Failure of passive transfer, *Giraffa camelopardalis reticulata,* leukopenia, neonatal care, neutropenia, reticulated giraffe

ACKNOWLEDGMENTS

The authors would like to thank the students and technical support staff of the Cummings School of Veterinary Medicine, as well as Dr. Peter Brewer and the keeper staff at Southwick's Zoo for their dedication to and care of these calves while in their charge.

LITERATURE CITED

1. Bercovitch FB, Bashaw MJ, Penny CG, Reiches RG. Maternal investment in captive giraffes. J Mammal. 2004;85:428-431.

2. Howard LL, Turner, LM, Stalis IH, Morris PJ. Serum gamma-glutamyltransferase as a prognostic indicator of neonatal viability in nondomestic ruminants. J Zoo Wildl Med. 2005;36:239-244.

3. Miller M, Coville B, Abou-Madi N, Olsen J. Comparison of in vitro tests for evaluation of passive transfer of immunoglobulins in giraffe (*Giraffe camelopardis*). J Zoo Wildl Med. 1999;30:85-93.

SQUAMOUS CELL CARCINOMA IN SNOW LEOPARDS (*Uncia uncia*): OUTCOME AND HISTOLOGY OF TWO CASE REPORTS OF UNUSUAL AURICULAR PRESENTATION

Benoît Quintard, DVM,[1]* Eva Greunz, DVM,[2] Antoine Leclerc, DVM,[3] Brice Lefaux, DVM,[1] and Karin Lemberger, DVM, Dipl ACVP[4]

[1]Parc Zoologique et botanique de Mulhouse, 68100 Mulhouse, France; [2]Parc de Thoiry, 78770 Thoiry, France; [3]Zooparc de Beauval, 41110 St Aignan sur Cher, France; [4]Vet Diagnostics, 69008 Lyon, France

Abstract

Squamous cell carcinoma (SCC) is well documented in snow leopards (*Uncia uncia*) and a study in the North American Species Survival Plan revealed in 2000 that 9% of the deaths were associated with SCC.[1,4] Cases in Europe have not been specifically described and so far there are only two cases reported in Russia.[4] The most common locations affected by SCC in snow leopards are oral, facial or podal.[1,4] Here two cases, both from France, illustrate an unusual auricular presentation, which is more often reported in white domestic cats.[2,3]

The first case involves a 20-yr-old male at the Mulhouse zoo who presented for unilateral ear scratching. Endoscopic observation of the ear showed a purulent otitis. A swab of the canal was sent for bacteriology and *Pasteurella multocida* was cultured. A topical treatment was performed with miconazole, polymixin B and prednisolone. Eight days later, the animal was found comatose with severe auricular hemorrhage. The blood loss, the comatose state of the animal and a known chronic renal insufficiency led to the decision of euthanasia.

The second case involves a 21-yr-old female at the Thoiry zoo who presented for head shaking and ear scratching. Anesthesia revealed purulent otitis and masses obliterating part of the auricular canal of both ears. Swabs of the canals were sent for bacteriology and *Bacillus* sp. was cultured. A systemic treatment was administered using amoxicillin-clavulanic acid for 10 days. Symptoms of the otitis ceased within 6 days but relapses occurred 1, 4 and 5 mo later. Seven months later the animal was euthanatized because of severe apathy, diarrhea and very poor general condition, probably related to a previously diagnosed systemic hypertension and the chronic otitis.

In both cases, histology of the ear canal was consistent with SCC and showed numerous vascular emboli, with lymph node metastasis in one case. In the first case, the tumor was adherent to an underlying large blood vessel and its rupture explains the hemorrhage. No immunohistochemistry for papillomavirus could be performed.

These two cases illustrate that ear SCC can be associated with otitis and should thus be part of the differential diagnosis in snow leopards which are prone to this lesion. Ear SCC may be underdiagnosed as the ear canal is infrequently sampled for histopathology. As this tumor is prone to metastasis, when no original tumor is observed at necropsy, one should consider this auricular localization.

Key words: Ear, hemorrhage, snow leopard, squamous cell carcinoma, tumor, *Uncia uncia*

LITERATURE CITED

1. Joslin JO, Garner M, Collins D, Kamaka E, Sinabaldi K, Meleo K, Montali R, Sundberg J, Jenson AB, Ghim SJ, Davidow B, Hargis AM, West K, Clark T, Haines D. Viral papilloma and squamous cell carcinomas in snow leopards (*Uncia uncia*). Proc Am Assoc Zoo Vet, Intl Assoc Aquat Anim Med; 2000. p. 155-158.

2. Meuten DJ. Tumors in domestic animals. 4th ed. Ames (IA): Blackwell Publishing; 2002. p.51-52.

3. Miller MA, Nelson SL, Turk JR, et al. Cutaneous neoplasia in 340 cats. Vet Pathol. 1991;28:389-395.

4. Mitsouras K, Faulhaber EA, Hui G, Joslin JO, Eng C, Barr MC, Irizarry KJ. Development of a PCR assay to detect papillomavirus infection in the snow leopard. BMC Vet Res. 2011;7:1-11.

CORRECTION OF SEVERE BILATERAL CARPUS VALGUS IN TWO JUVENILE CHEETAHS (*Acinonyx jubatus*) FOLLOWING STAGGERED BILATERAL ULNAR OSTECTOMY INCORPORATING OMENTAL FAT GRAFT

Conor P. Kilgallon, MVB, MSc, MRCVS, Dipl ACZM

Dubai Falcon Hospital and Wadi Al Safa Wildlife Center, Dubai, UAE

Abstract

Angular limb deformity has been previously reported in captive juvenile cheetahs and tends to be multifactorial in etiology.[2] Treatment modalities have tended to focus on nutritional correction, exercise restriction, and confinement. Whereas such measures might effect resolution of early or mild cases, extreme deformities may best be addressed surgically.[1] Reports outlining effective surgical solutions are, however, scarce in the literature. A 6-mo-old litter of cheetahs (2.1) born at a breeding center in the United Arab Emirates presented with bilateral carpus valgus. Magnitude of deviation was considerably greater in the two males (>25º) than in the female (<15º). Radiographic changes included cranial bowing of the radius, flaring of distal ulnar physes, and presence of asymmetric metaphyseal radiolucent cores. In addition, elbow incongruency was present in the male cubs. Excessive early growth rates and inadvertent oversupplementation of calcium and vitamin D were associated with the cases. Whereas nutritional adjustment and exercise restriction resulted in correction of deformities in the female, distal ulnar ostectomies incorporating omental fat grafts at the site of ostectomy were considered necessary and were carried out bilaterally in the two males. Procedures were staggered by approximately 1 wk. Notable improvement in conformation and locomotion were achieved by 8 wk post-surgery in all animals. Valgus was minimal at 18 wk in the female, by which time deviations in the males were shown to be minimal and elbow incongruency had resolved.

Key words: *Acinonyx jubatus*, cheetah, distal ulnar ostectomy, omental fat graft, valgus

LITERATURE CITED

1. Allan G, Portas T, Bryant B, Howlett R, Blythe D. Ulnar metaphyseal osteochondrosis in seven captive bred cheetahs (*Acinonyx jubatus*). Vet Radiol Ultrasound 2008;49:551-556.

2. Bell KM, Van Zyl M, Ugarte CE, Hartman A. Bilateral carpal valgus deformity in hand reared cheetah cubs (*Acinonyx jubatus*). Zoo Biol. 2011;30:199-204.

QUALITY-OF-LIFE EVALUATION AND MONITORING AS A TOOL IN THE HUMANE CARE OF A CAPTIVE RIVER OTTER (*Lontra canadensis*) WITH DILATED CARDIOMYOPATHY

Kelly E. Helmick, DVM, Dipl ACZM,* Allison Barr, BS, Amy Brandt, BS, and Deanna DeBo, BS

Woodland Park Zoo, Seattle, WA 98103 USA

Abstract

An 8.2-kg, 18-yr-old female river otter (*Lontra canadensis*) exhibiting decreased activity, increased respirations, and coughing was diagnosed with dilated cardiomyopathy. Treatment with furosemide[a] (10 mg p.o., s.i.d. to b.i.d.) and pimobendan[b] (2.5 mg p.o., b.i.d.) was initiated. Treatment resulted in improved clinical symptoms but prognosis was guarded. Woodland Park Zoo utilizes a questionnaire for assessment and planning of long-term patient care. The questions help summarize behaviors and health indicators, prognosis, treatment options, potential outcomes or adverse effects, and potential changes to the social group. Patient-specific monitoring parameters are created with defined acceptable limits for quality of life. A scoring system is created for non-qualitative monitoring parameters. Data is regularly reviewed by staff.

For this patient, qualitative (weight, percent diet consumed, medication administration, active and resting respiration) and non-qualitative (attitude, activity, body score, mobility) monitoring was performed daily. Monthly veterinary visual assessment with team-based discussion was performed for 13 mo. Humane euthanasia was elected for declining quality of life based on monitoring parameters, particularly appetite, weight, and activity. The team assessed the quality-of-life decision and communication process as effective and compassionate. End-of-life decisions can be a difficult or emotional process. Acceptable quality of life can drift when care is long term or disease progression is slow or subtle. Establishing quality-of-life parameters and defining acceptable limits as a team, improves patient care by creating opportunities for regular communication and allows the veterinarian to be a resource when staff has questions or concerns regarding patient welfare and comfort.

[a]Generic, 20 mg tablets, Qualitest Pharmaceuticals, Huntsville, AL 35811 USA
[b]Vetmedin®, 5 mg tablets, Boehringer Ingelhein Vetmedica Inc., St. Joseph, MO 64506 USA

Key words: *Lontra canadensis*, quality of life, river otter, welfare

ACKNOWLEDGMENTS

The authors wish to thank Dr. Jerry Woodfield, DVM, Dipl ABVC for cardiac ultrasound diagnosis and treatment strategies, and the staff of the Woodland Park Zoo for their support and compassionate care.

NOVEL COMBINED ENDOSURGICAL AND SYSTEMIC THERAPEUTIC APPROACH TO AN ALMOST COMPLETELY OBSTRUCTIVE INTRALUMINAL ZYGOMICETAL TRACHEAL MASS IN A BOTTLENOSE DOLPHIN (*Tursiops truncatus*)

Daniel García-Párraga, DVM, Dipl ECZM,[1]* Enrique Cases, MD,[2] Teresa Álvaro, DVM,[1] Mónica Valls, DVM,[1] and Andreas Fahlman, PhD[3]

[1]Veterinary and Laboratory Services, Oceanografic, Ciudad de las Artes y las Ciencias, Valencia, 46013, Spain; [2]Neumology Services, Hospital Universitario La Fe de Valencia, Valencia, 46026, Spain; [3]Research Department, Oceanografic, Ciudad de las Artes y las Ciencias, Valencia, 46013, Spain

Abstract

A female bottlenose dolphin with previous history of chronic fungal respiratory pathology, presented with progressive dyspnea, reduced exercise capacity, and an inflammatory blood profile. Auscultation, radiographs and bronchoscopy revealed an intratracheal mucus-fibrinous sessile mass that extended from the distal tracheal region into the left bronchus, occluding most of the lumen around the carina. The mass was partially removed under sedation and local anesthesia during three different surgical interventions using an endoscopic N_2 cryosurgery probe and cauterizing with an argon plasma unit. A zygomycete (*Rhizopus* sp.) was confirmed as the causative of infection. Oral posaconazole (5 mg/kg p.o., b.i.d.) was then prescribed following in vitro sensitivity testing. A multirresistent *Pseudomona aeruginosa* also was isolated from biopsy samples so systemic and nebulized antibiotics were also prescribed. Intraluminal lesions were almost resolved 6 wk after last surgery. Fecal transplantation from another clinically healthy dolphin was successfully used to reestablish normal intestinal flora immediately after antimicrobial treatment suspension. A novel dolphin adapted spirometry technique was used to monitor pulmonary function, evidencing obstruction resolution and progressive recovery. Eight months after uninterrupted posaconazole therapy, a relapse of fungal growth in the tracheal lumen was detected, treating it under the same surgical approach. Based on new sensitivity testing, medical treatment was changed to nebulized liposomal amphotericin B (25 mg/kg b.i.d.) and oral terbinafine (2 mg/kg p.o., o.i.d.). Lesions completely resolved within 2.5 mo although antifungal treatment was prolonged for 4 mo. Blowhole cultures, cytologies, blood analysis, lung auscultation, scheduled bronchoscopies and spirometries are being routinely conducted in order to detect any subsequent relapse.

Key words: Bottlenose dolphin, bronchoscopic surgery, fungal granuloma, tracheal obstruction, *Tursiops truncatus*, zygomycosis

CASE SERIES OF CLOACITIS IN KĀKĀPŌ (*Strigops habroptila*)

Joanne Paul-Murphy, DVM, Dipl ACZM, Dipl ACAW,[1]* Richard Jakob-Hoff, BVMS, MANZCVS,[2] Daryl Eason, PGDipSci,[3] James Chatterton, BVMS, MSc, CertZooMed, MRCVS[4], An Pas, DVM, MVS (ConsMed),[4] Andrew Digby, PhD,[3] Bethany Jackson, BVSc MVS, PhD,[2] Cathy Harvey, BVSc, Dipl ACVP,[5] and Brett Gartrell, BVSc, PhD, MANZCVS (Avian Health)[6]

[1]Department of Veterinary Medicine and Epidemiology, University of California-Davis, Davis, CA 95616 USA; [2]New Zealand Centre for Conservation Medicine, Auckland Zoo, Auckland, NZ 1245; [3]Kākāpō Recovery Team, Department of Conservation, Invercargill, NZ 9840; [4]Auckland Zoo, Auckland, NZ 1245; [5]IDEXX New Zealand Veterinary Pathology, Auckland, NZ 1022; [6]Institute of Veterinary, Animal & Biomedical Sciences, Massey University, NZ 4442

Abstract

The kākāpō is a critically endangered parrot endemic to New Zealand, intensively managed by New Zealand Department of Conservation as an entirely free-living wildlife population, increasing from 51-125 birds between 1995-2015.[1,2] Behavioral ecology, including being nocturnal, with lek breeding, and remaining solitary outside breeding season, makes kākāpō unsuitable for captive breeding.

A mucocutaneous disease, characterized by inflammation of the cloaca and vent, has been identified in 13 kākāpō (eight males/five females) between 2002-2015 and cloacal polyps have occurred in four additional males. Acute cloacal inflammation may resolve quickly (2-4 wk). Chronic cases are characterized by cloacal exudate, ulcers, fissures and severe vent dermatitis. Five kākāpō have been hospitalized and treated symptomatically with long recovery periods (3-8 mo). Recrudescence has occurred within months to years (n = 5). Initial cloacitis cases have elevated fibrinogen concentrations compared to reference intervals ($P < 0.001$). Biopsies' histopathology (n = 5) had mild to moderate, chronic-active, lymphoplasmacytic hyperplastic cloacitis, with areas of fibrosis and haemosiderosis in chronic cases.

Absence of these clinical findings prior to 2002 suggests this is a newly emerging disease, possibly unique to kākāpō.[3] All cases have initially occurred when kākāpō have been on one island, Whenua Hou. No other significant epidemiologic factors have emerged including sex, age, kinship, heterozygosity, diet, and seasonality. Infectious etiologies continue to be explored despite lack of pattern between affected and unaffected birds. To date there is no causal link to parasites, and minimal distinction between microbiologic flora of healthy and affected cloacas and feces examined by culture as well as metagenomics.[4,5]

Key words: Cloacitis, exudative, kākāpō, *Strigops habroptila*, vent dermatitis

ACKNOWLEDGMENTS

The authors would like to thank the following people for their support and guidance given throughout this study: Ron Moorehouse, Dan Tompkins, Richard Hall, Mike Taylor, Deidre Vercoe, Kate McInnes, Craig Pritchard,

Bonnie McMeekin, Mikaylie Wilson, Mel Trickett, Lauren Best, John Potter, Stephanie Shaw, Berend Westera, Catherine Williamson, Clarinda Stirling, Dan White, David Waite and to Kaytee Foundation for their 2013 grant support.

LITERATURE CITED

1. Eason DK, Elliott GP, Merton DV, Jansen PW, Harper GA, Moorhouse RJ. Breeding biology of kakapo (*Strigops habroptilus*) on offshore island sanctuaries, 1990-2002. Notornis. 2006;53:27.

2. Elliott GP, Merton DV, Jansen PW. Intensive management of a critically endangered species: the kakapo. Biol Conserv. 2001;99:121-133.

3. Jakob-Hoff R, Gartrell B. Veterinary care of kakapo. In: Miller RE, Fowler ME (eds.). Zoo and wild animal medicine, Volume 7, Current therapy. St. Louis (MO): Elsevier; 2012. p. 304-311.

4. Waite DW, Deines P, Taylor MW. Gut microbiome of the critically endangered New Zealand parrot, the kakapo (*Strigops habroptilus*). PLoS One. 2012;7:e35803-e35803.

5. White DJ, Hall RJ, Jakob-Hoff R, Wang, J, Jackson B, Tompkins DM. Exudative cloacitis in the kakapo (*Strigops habroptilus*) potentially linked to *Escherichia coli* infection. NZ Vet J. 2015:63:167-170.

ANESTHESIA AND SURGERY IN AN ELECTRIC EEL (*Electrophorus electricus*) PRESENTING WITH A PERFORATING GASTRIC FOREIGN BODY

Sandra Wenger, Dr med vet, Dipl ECVAA, Dipl ACZM,* Fabia Wyss, Dr med vet, and Jean-Michel Hatt, Prof Dr med vet, Dipl ECZM (avian), Dipl ACZM

University of Zurich, Vetsuisse Faculty, Clinic for Zoo Animals, Exotic Pets and Wildlife, 8057 Zurich, Switzerland

Abstract

Electric eels (*Electrophorus electricus*) present unique veterinary challenges as they have specialized organs capable of discharging electrical surges exceeding 600 volts.[1,2] An adult electric eel, weighing 18 kg and measuring 2 m in length, presented with a large screw protruding through its ventrolateral body wall approximately 30 cm caudal to the mouth. Anesthesia was performed with immersion in 300 mg/L tricaine methanesulphonate (MS222) buffered with sodium bicarbonate. Once sedated, the fish was fully examined. After removal of the screw, gastrointestinal content poured out through the hole in the body wall. A stomach perforation was suspected and an exploratory celiotomy was performed. Anesthesia was supplemented with 0.11 mg/kg medetomidine and 2.2 mg/kg ketamine i.m. and aerated water containing MS222 was applied over the gills every 2-5 min. After incision of the body wall, the stomach was isolated and two stay sutures were placed. The edges of the perforation site in the stomach wall were refreshed and closed in two continuous layers using poliglecaprone 25 (Monocryl 3-0). The coelom was flushed with 1L sterile Ringers solution. The body wall was closed in two layers with polydioxanone using a continuous suture for the peritoneum (PDS®II 3-0) and horizontal mattress suture for the skin (PDS®II 4-0). At the end of surgery, anesthesia was reversed with 0.28 mg/kg atipamezole i.m. Postoperatively, 20 mg/kg ceftazidime and 0.1 mg/kg meloxicam were administered i.m. every 48 hr for three doses. Salt was added to the tank water at 1g/L for 1 wk. The electric eel recovered uneventfully and started eating on its own 11 days after surgery.

Key words: Anesthesia, celiotomy, electric eel, foreign body, surgery

ACKNOWLEDGMENTS

The authors would like to thank the curator and keepers of the Aquatic section of the Zurich Zoo, Zurich, Switzerland for their assistance in the care of this fish.

LITERATURE CITED

1. Bennett MVL. Electric organs. In: Hoar WS, Randall DJ (eds.). Fish physiology. Vol 5. New York (NY): Academic Press; 1971. p. 380-391.

2. Poll CP, Naples LM, Van Bonn WG. Techniques for handling, anesthesia, surgery and treatment of the electric eel (*Electrophorus electricus*). Proc 45th Int Assoc Aquat Anim Med; 2014. p. 20.

AN ALGORITHM FOR RISK-BASED MANAGEMENT OF THE TRANSFER OF ANIMALS BETWEEN ZOOS AND AQUARIUMS

Geoffrey W. Pye, BVSc, MSc, Dipl ACZM

Disney's Animals, Science and Environment Team, Disney's Animal Kingdom, Bay Lake, FL 32830 USA

Abstract

An algorithm for the risk-based management of the transfer of animals between zoological institutions was developed using the fundamentals of risk analysis: hazard identification, risk assessment, and risk mitigation (Figure 1). The receiving institution identifies and assesses the risk of pathogen hazards for their collection. If no pathogen hazards are identified, then no risk mitigation is required and the preshipment requests are limited to the animal is "healthy for travel" and "suitable for the function required at the receiving institution", and to collecting baseline preventive medicine data. The absence of pathogen hazards eliminates the risk mitigation need for a post-arrival isolation period, exam, and testing. Collection of preventive medicine data at the preshipment exam enables the animal to enter seamlessly into the receiving institution's preventive medicine program. If pathogen hazards are identified, the status of the sending collection and individual animal are considered. For collections or individual animals that are known negative for all of the identified hazards, the same preshipment requests (and waiving of post-arrival isolation and testing) are used as for "no hazards identified." If hazard status is unknown, additional preshipment diagnostics are requested. In circumstances where preshipment diagnostics are limited or not available, standard quarantine isolation and testing are performed. The potential for pathogen contamination during travel is considered and adjustments made to post-arrival isolation and testing. Use of this algorithm shifts responsibility to the sending institution and requires trust from the receiving institution, but can improve animal welfare by reducing immobilizations and periods of isolation.

Key words: Aquarium, quarantine, risk, shipment, zoo

ACKNOWLEDGMENTS

I would like to thank the staff and cast at San Diego Zoo and Disney's Animal Kingdom respectively for being great thought partners and challenging the concepts of risk analysis and the algorithm.

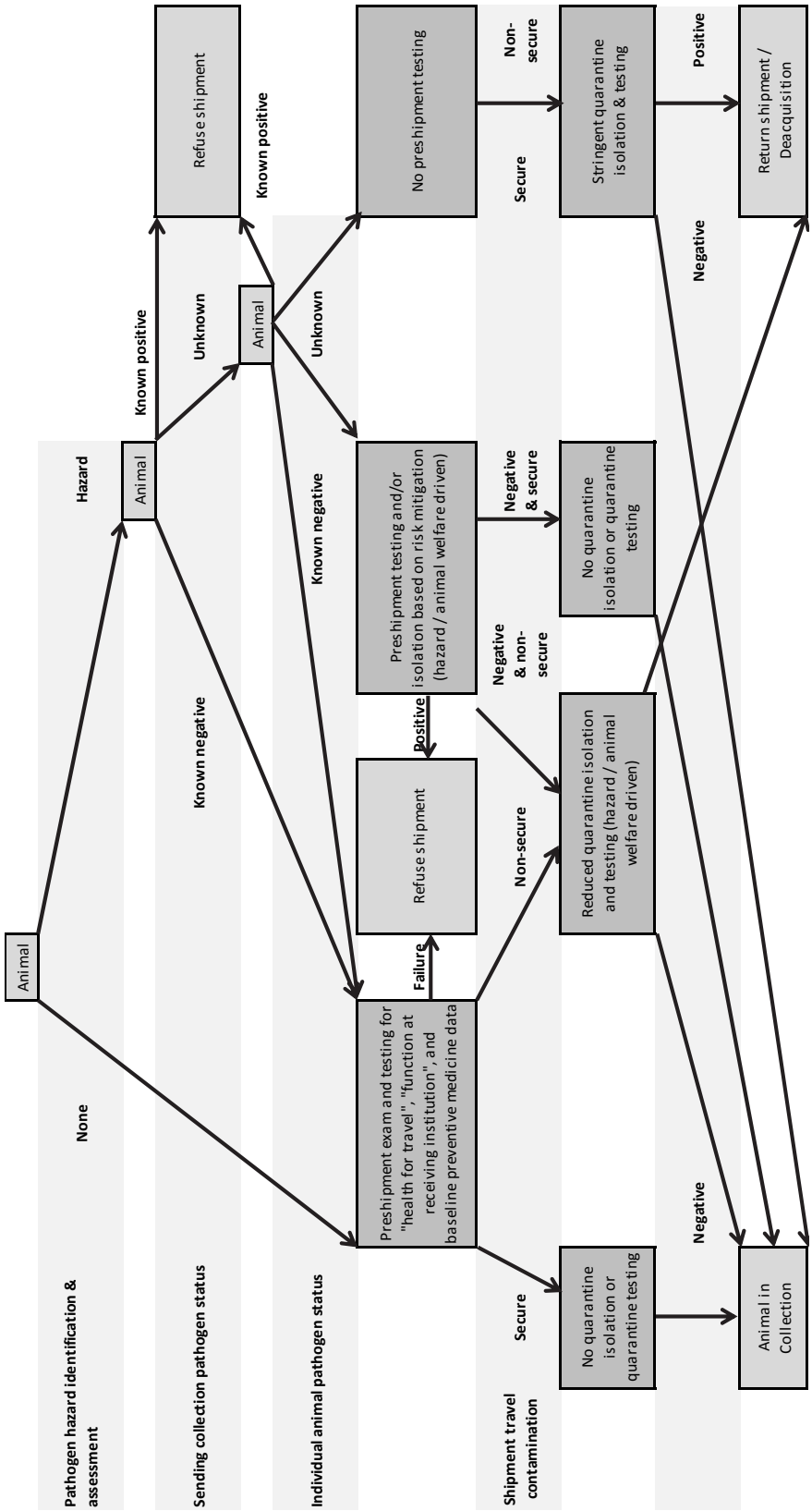

Figure 1. An algorithm for the risk-based management of the transfer of animals between zoos and aquariums.

DATA SHARING, DATA MINING AND GLOBAL INFORMATION RESOURCES

J. Andrew Teare, MS, DVM and Rachel Thompson, DVM*

International Species Information System, Bloomington, MN 55425 USA

Abstract

Medical, physiologic and biochemical information about a multitude of species is a prerequisite for the practice of zoological medicine, but such information is not always readily available. Indeed, perhaps the most effective method to fragment both the information and the experience regarding a species is to take a small global captive population and divide into even smaller groups held at multiple, widely-spaced institutions. Conferences, journal articles, text books and personal communication are the traditional means to transfer knowledge between clinicians, but these methods are often both slow and relatively inefficient. Increasing both the speed and volume of medical information and experience that circulates back into the zoological medicine community is a challenge that needs solving. Electronic medical records for zoological collections offer new opportunities for both real-time sharing of medical information between institutions and data mining of existing records to build new global information resources. Continually updated and expanded as new records and new information becomes available, these resources will change zoological medicine.

The Past

Multiple sites for maintaining captive breeding populations is a well-recognized principle for protection against a catastrophic event any single location. However, the unintended consequence of dispersing a captive population to multiple sites is the fragmentation the clinical experience and the associated medical knowledge gained through that experience. For an endangered species with a well-funded recovery program and a small number of breeding facilities, providing resources for regular meetings and increased communication between clinicians will mitigate this dispersal of medical experience. Within the zoo and aquarium community, however, most captive populations do exist as "small numbers of individuals held at multiple sites," while resources to re-integrate scattered information tend to be limited. Clinicians typically face the twin problems of experience obtained with just a few individual animals and limited time to network with the community about species under their care. Integrating medical knowledge from multiple sources is a part of the daily experience for zoo clinicians, but it is a task that must become easier if we are to deliver on the promise of improved health care for all species.

Recognition that this reintegration of medical experience and knowledge is critically important for the health of some captive populations, helped drive the establishment of Species Survival Plan (SSP) and European Endangered Species Program (EEP) medical advisors for selected species. Tasked with summarizing the available information about a species, these advisors establish health care guidelines for a managed species and become a source of knowledge for all clinicians. Often, they also study historical clinical and pathology records to identify diseases and medical conditions that are rare enough to be a case report at the institutional level, but common enough to have an impact at the population level. Species medical advisors play an important role in the management

of a captive population and they provide a unique resource for other clinicians, but as any species medical advisor can attest, reviewing medical records, whether electronic or paper, to produce useful summaries, is a slow and time-consuming process. As such, it is also a model that cannot expand to cover all the species held and displayed by zoos and aquariums around the world; there are simply not enough resources in our community. So, while data consolidation between institutions is part of the solution to this problem of distributed information and experience, it not the complete solution. If we are to increase the integration of experience and knowledge that exists within the zoological community, and improve the flow of information within the community then we need a different system.

One of the main motivations for the founding of International Species Information System (ISIS) in 1974 was to accumulate hematology and blood chemistry values from multiple institutions to use to establish reference intervals for captive wildlife. Those first publications of reference intervals for captive wildlife represent some of the earliest successes with data sharing and data amalgamation between institutions. While this early experiment was successful, it was also labor-intensive, time-consuming and involved multiple steps that could introduce errors. Clinicians with test results transcribed them onto a standardized form, send that form to ISIS, and ISIS entered the information into a computerized database. Once a year, reference intervals would be calculated, printed and sent back to the contributing clinicians. Not very surprising then that this global project averaged less than 2000 data submissions per year for the almost 25 yr that it existed in this paper in-paper out format.

Electronic medical record systems hold the promise to change information sharing between zoological institutions and to some extent electronic health records have fulfilled that promise. Exchanging computerized information and integrating the information with another electronic records system to create seamless medical histories is relatively easy. When compared to paper records, electronic information sharing, consolidation and searching is a much easier process. The Medical Animal Record Keeping System (MedARKS) software package for the personal computer was one of the first attempts to tap into this potential. The widespread adoption of MedARKS software eased the sharing of information between institutions, but it did not solve the fundamental problem of distributed information, because each institution still held their information in a local MedARKS database. Consolidating that information into a single global set of records was a process that remained a barrier to the flow of information between institutions and limited the ability to build useful resources based on that information. The extension of the ISIS physiologic reference intervals project into an electronic format was one of the few successes produced from consolidated MedARKS data and the growth of the global database to contain over 6 million test results by 2013 showed the potential inherent in an electronic record format.

The Present

The launch of the Zoological Information Management System (ZIMS) in 2012 was the next step in the evolution of zoological records. This global database has real-time data entry and the migration of existing MedARKS records into the ZIMS database guaranteed that almost 30 yr of accumulated electronic medical record keeping effort transitioned to the new system. This single global database removed one of the final barriers to the increased flow of information and experience between institutions.

In late 2014, the Institute of Museum and Library Services awarded a grant to start the process of using this global database to create some global level medical resources that would provide direct benefits back to the users. The initial proof-of-concept was a data mining utility to extract and share pharmaceutical drug experience, through the Global Drug Usage Extracts resource within the ZIMS package. The drug information is grouped by genus or species, active ingredient(s), administration route and frequency of treatment and users can search this unique resource by species, active ingredient or drug category (Figure 1). Analysis within a genus or species for each combination of drug, route and frequency produces summary dosage, treatment duration, and adverse effects information (Figure 2). Additional information for the clinician includes the number of prescriptions and the number of individual animals in the data set.

The initial publication (June 2015) summarized 1.3 million prescription records and provided objective information on 311 different drugs. However, this is not a static resource and weekly updates show a steady growth in all aspects of the Global Drug Usage Extracts resource. By December 2015, the global database had 1.44 million prescriptions and contained summary information on 386 different drugs. Currently more than 320 institutions are contributing prescriptions to the database, assuring continued growth of the Global Drug Usage Extracts and providing an ever-expanding source of useful pharmaceutical information to zoo clinicians around the world.

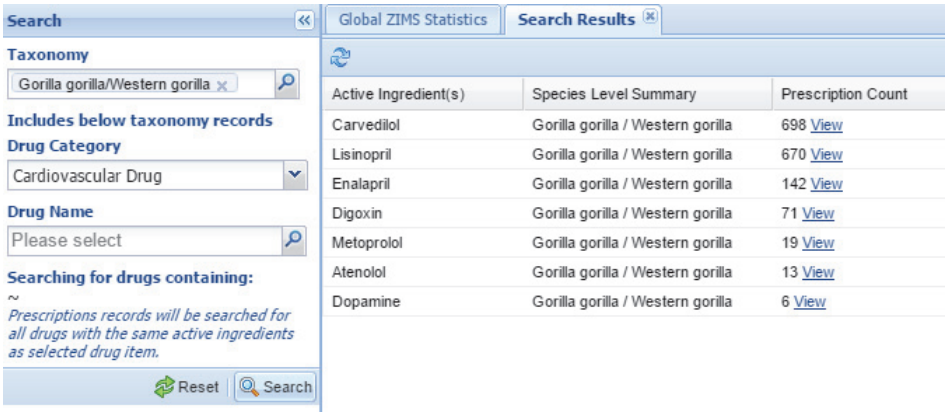

Figure 1. Results of searching the global resource for cardiovascular agents used in *Gorilla gorilla*.

Gorilla gorilla / Western gorilla

Route: Oral (p.o.)

Frequency	Dosage (mg/kg)			Duration (days)	
	Mean	Median	Range	Median	Range
once a day (sid)	0.30	0.31	0.06 - 0.47	30.0	3.0 - 2,806.0
twice a day (bid)	0.22	0.24	0.16 - 0.26	30.0	14.0 - 2,861.0

Figure 2. Details available for lisinopril usage in *Gorilla gorilla* include route, dosing frequency, dosage and duration. Additional columns (not shown) provide adverse reaction information, total prescriptions and number of animals in the analysis and a count of the prescriptions terminated early.

The Future

The coming year will see two new global resources added into ZIMS. The first resource will provide clinicians with drug protocol and dosage information for anesthesia events and the second will provide information on the most commonly reported medical problems in captive species. In the longer term, ISIS aims to both update and expand the Physiological Reference Intervals resource and improve the integration of this resource with the ZIMS test & results module, providing clinicians with additional assistance when interpreting test results. Another feature in the early discussion phase is giving institutions the ability to share their medical records directly with the SSP and EEP medical advisors and pathologists, and supporting these species advisors with tools that allow effective searches of those shared medical records. Providing basic epidemiologic reports across institutions will also be important to improve the ability of advisors to detect significant medical issues and help support the medical management of captive populations by regional associations.

Discussion

Better networking and increased connectivity are the new mantras of the digital age. On-line medical resources will increase in sophistication and usefulness for the clinician and zoological medicine cannot be immune to these changes. Electronic records have already changed the flow of information both within and between zoological institutions. We are on the cusp of major changes in zoological medicine and while it might feel that we have balanced on this cusp for a very long time, significant changes are happening now. New tools will take advantage of this information to build and deploy new global medical resources. Over time, enhanced algorithms will permit more sophisticated and nuanced analysis. How quickly this new information age arrives and how much effect it will have on the zoological community depends to a large degree on three factors: how effectively the necessary medical information is captured in a standardized manner, the quality of the information that is captured by the system and how effectively we can mine those records for clinically useful information. The zoological medicine community will help drive all parts of this process, from helping develop data standards to suggestions for analysis techniques. However, perhaps the most important task falls to those clinicians actively practicing zoological medicine - it is the quality and consistency of the medical data that you add to the global database that will ultimately drive both the quantity and quality of useful information coming out of that system.

Conclusion: Thoughts on Whether the Computer Works for You or Whether You Work for the Computer

- Will electronic records and analysis tools eliminate the need for species level medical advisors?

  That would seem to be a highly unlikely outcome. Machine “intelligence” is only as good as the rules defined for the machine. Data mining works because a human intelligence has examined the raw data, decided on the appropriate rules for data extraction, created an analysis strategy and used that process to build a global resource or summary of the information contained within the records. That process of building a global resource is what a medical advisor currently does when examining historical medical records and extracting information

to produce a useful summary; that need for a human intelligence does not disappear until we can build an artificial intelligence that is as good as a human intelligence. The difference with electronic records is that once those data extraction and analysis rules are developed and encapsulated within an algorithm, that tool that can perform the same data mining and analysis for any species with no additional effort.

- Will a global electronic records system solve all our information problems and needs?

  That also would seem to be an unlikely outcome. The information coming out of an electronic records system is dependent on the quality of information going into the system and mistakes will always happen. Again, an experienced and trained human intelligence can often just look at a medical record and recognize the presence of a data entry error or some other problem that makes the record erroneous; no machine can make that decision.

- Finally, for zoo clinicians that might feel that our current electronic health record systems are "wack," check out the following video - humorous, poignant and yet educational.

  https://www.youtube.com/watch?v=xB_tSFJsjsw&feature=youtu.be

Key words: Data mining, electronic health records, global database, One Health

ACKNOWLEDGMENTS

This project was made possible in part by the Institute of Museum and Library Services grant MG-30-14-0039-14.

MESHING REHABILITATION, EDUCATION, AND RESEARCH: THE JEKYLL ISLAND DIAMONDBACK TERRAPIN (*Malaclemys terrapin*) MODEL

Terry M. Norton, DVM, Dipl ACZM,[1]* Michelle Kaylor,[1] Kimberly Andrews, PhD,[1,2] John C. Maerz, PhD,[3] and Brian A. Crawford, MS[3]

[1]Georgia Sea Turtle Center, Jekyll Island Authority, 214 Stable Island Road, Jekyll Island, GA 31527 USA; [2]Savannah River Ecology Laboratory, University of Georgia, Aiken, SC 29802 USA; [3]D.B. Warnell School of Forestry and Natural Resources, University of Georgia, 180 E. Green Street, Athens, GA 30602 USA

Abstract

The Georgia Sea Turtle Center (GSTC) is a conservation organization that focuses its efforts on native chelonians and integrates rehabilitation, education and research. Thousands of reproductively mature female diamondback terrapins are injured and killed by motor vehicles on causeways going to developed barrier islands throughout their range during the nesting season. On the Jekyll Island Causeway (JIC) alone an average of 163 and a range of 91 to 223 terrapins have been hit annually and a total of 980 have been hit over a 6-yr period. A "Diamondback Terrapin Conservation Initiative" started in 2006 with the GSTC staff rescuing them off the road after being hit, rehabilitating them, recovering their eggs for incubation and eventual release of any that were successfully rehabilitated or hatched. In 2009, a partnership was established with the University of Georgia. This program has evolved into a multifaceted conservation program and is serving as a model for other similar initiatives. Research has focused on investigating the extent of the problem on the JIC and demonstrating that per capita terrapin mortality from vehicle strikes and nest predation rates are both sufficient to cause population declines along the JIC.[1] Hot and warm spots for terrapin nesting and crossing have been established.[2] Additionally, a large percentage of terrapins come up to nest during a 3-hr window surrounding high tide. A male-biased population has been demonstrated through regular monitoring of creeks surrounding the causeway.[4] These results have been used to design our management strategies and education programs.[3,5]

Key words: Diamondback terrapin, education, motor vehicle mortality, rehabilitation, research

LITERATURE CITED

1. Crawford BA, Maerz JC, Nibbelink NP, Buhlmann KA, Norton TM. Estimating the impacts of multiple threats and management strategies for diamondback terrapins (*Malaclemys terrapin*). J Appl Ecol. 2014;51:359-366.

2. Crawford BA, Maerz JC, Nibbelink NP, Buhlmann KA, Norton TM, Albeke SE. Hot spots and hot moments of diamondback terrapin road-crossing activity. J Appl Ecol. 2014;51:367-375.

3. Crawford BA, Poudyal NC, Maerz JC. When drivers and terrapins collide: assessing stakeholder attitudes toward wildlife management on the Jekyll Island Causeway. Human Dimensions of Wildlife, 2015. DOI:10.1080/10871209.2014.948103,http://dx.doi.org/10.1080/10871209.2014.948103

4. Grosse AM, Crawford BM, Maerz JC, Buhlmann KA, Norton T, Kaylor M, Tuberville TD. Effects of vegetation structure and artificial nesting habitats on hatchling sex determination and nest survival of diamondback terrapins. J Fish Wildl Manag. 2014;6:19-28.

5. Quinn DP, Kaylor SM, Norton TM, Buhlmann KA. (In press). Nesting mounds with protective boxes and an electric wire as tools to mitigate diamond-backed terrapin (*Malaclemys terrapin*) nest predation. Herp Cons Biol.

WORKING WITH, INSTEAD OF AGAINST, THE U.S. DEPARTMENT OF AGRICULTURE'S ANIMAL AND PLANT HEALTH INSPECTION SERVICE: TIPS FOR DEVELOPING A SOLID WORKING RELATIONSHIP

Wm. Kirk Suedmeyer, DVM, Dipl ACZM

Kansas City Zoo, 6800 Zoo Drive, Kansas City, MO 64132 USA

Abstract

The Animal Welfare Act was signed into law in 1966. The regulations are enforced by the U.S. Department of Agriculture's (USDA) Animal and Plant Health Inspection Service (APHIS) Animal Care program unit. The regulations were last updated in 2013. Zoological institutions must abide by these regulations and are inspected on a yearly basis to assure compliance. The USDA has the right to penalize or revoke an institution's exhibit permit if regulations are not adhered to.

The regulations are minimum standards of care and the majority of zoological institutions exceed the minimal requirements for animal welfare. A shift in societal conscience, combined with on-line access incurs additional pressure on an institutions reputation and credibility for providing appropriate welfare. USDA veterinary medical officers (VMOs) were, and in some cases are, still viewed as an antagonist, invoking anxiety and forcing institutions to scramble to comply during inspections. Problems occur with interpretation of regulations, a lack of consistent application of the welfare act, and interruption of daily routines during inspections.

The Kansas City Zoo has taken a proactive approach to working with USDA/APHIS, developing innovative programs that strengthen the relationship with USDA VMOs and strives to achieve "excellence beyond compliance."[1] Our VMO has been invited to and has presented topics dealing with interpretation of the animal welfare regulations in regards to primates, big cats, and marine mammals. These are eagerly received by all levels of staff; some of which have no working knowledge of the regulations. We have developed a "letter of transport," which details whether an animal needs veterinary accompaniment, temperatures the animal should be comfortable with during travel, any medications administered, how often the animal will be observed, and emergency contacts during travel. This letter accompanies the shipment. An email, text or other written form of documentation that the animal arrived safely is required from the receiving institution to complete the animal's files.

It is apparent that communication between the animal care staff and veterinary staff is an area of emphasis and top priority for USDA. To that end, we designed and implemented a two-ply animal health evaluation form, which is filled out by the veterinarian at the time of exam, detailing what the concern is, who was involved in the discussion, what the working diagnosis is and how or if the condition will be treated. The copy is left with the staff for their files, and is referred to by any staff working with the animal. These forms are highly effective and supported by our VMO. During inspections, the veterinarian and Director of Living Collections accompany the VMO to all areas of the zoo. The VMO is advised of current medical issues with regulated animals prior to observation; this decreases the amount of time spent in each area and allows the veterinarian to

prepare the VMO, minimize observational concerns and strengthen trust between USDA and the institution. Concerns are immediately addressed and most of the time the VMO is invited and will re-inspect the addressed concern before writing the final report. Our VMO is routinely updated on animal losses, high-profile procedures, and dispositions. We have also invited the VMO to the zoo for clarification of welfare regulations, in anticipation of any future concerns, such as winter holding, shelters, space requirements, etc.

The zoo has instituted routine USDA self-inspections; selected areas are inspected by the veterinarian, director of living collections, and on occasion, the CEO as well. Items of concern or potential infractions are discussed and addressed with staff. Formalized rounds occur four times weekly with the veterinarian and curator visiting scheduled areas to directly observe animals that may not have been reported for recent weight loss, subtle illness, or disease updates outside of clinical rounds. This minimizes areas of concern during inspections. Medical records, including necropsy reports, clinical notes, documentation of enrichment programs, marine mammal water quality parameters, diet formulation, implementation and review are routinely updated and inspected.

Working with VMOs improves the standards of care and welfare of animals in zoological institutions, lessens anxiety of inspections, and improves communication amongst all stakeholders.

Key words: Animal welfare, APHIS, inspection, USDA, VMO

LITERATURE CITED

1. Gesualdi JF. Excellence beyond compliance: enhancing animal welfare through the constructive use of the animal welfare act. Ana Maria (FL): Basset Publishing; 2014.

BRINGING ARTISTS AND SCIENTISTS TOGETHER TO FOSTER SUSTAINED AND INFORMED SUPPORT FOR ANIMAL CONSERVATION

Lucy H. Spelman, DVM, Dipl ACZM

Division of Liberal Arts, Rhode Island School of Design, Providence, RI 02903 USA

Abstract

The world of animals as we know it is disappearing. The extinction rate today is between one and ten thousand times above background. Science tells us the animal kingdom cannot survive our massive presence on earth—unless we intervene. It also predicts a ripple effect on human health and society: we rely on animals for food, trade, shelter, sport, companionship, medicine, and spirituality. Art deepens our understanding of this interdependency; it helps us explore how we feel about animals and our relationships with them. Yet our response to the problem of species loss has fallen short. Scientific data and artistic expression, presented separately, have not had their intended impact. One solution is to combine these age-old practices. Together, art and science reach a wider audience. Science provides the road map; art motivates people to follow it. The author has been exploring the interface between art, One Health, and endangered species since 2010, when she began teaching at the Rhode Island School of Design. In 2015, she founded *Creature Conserve*, a non-profit dedicated to bringing artists and scientists together to foster informed and sustained support for animal conservation. The organization supports a variety of collaborative art/science projects, including exhibitions, gallery shows, internships, lectures, and workshops. Recently, the author collaborated with sculptor Natalie Tyler on *Ours Theirs: Mountain Gorilla*, an interactive piece that explores the urgent need to recognize the zoonotic risk of metapneumovirus in humans and mountain gorillas. Artists have always been interpreters of our time. Through their eyes, the science of saving species and the importance of taking a one-health approach to conservation becomes accessible, meaningful, and relevant—and, the source of positive change.

Key words: Art, collaboration, conservation, extinction, One Health, science

ACKNOWLEDGMENTS

The author would like to thank her collaborators at the Rhode Island School of Design, including faculty members Susan Doyle, Lindsay French, Nicholas Jainschigg, and Dr. Nicole Merola; recent graduates Chloe Bulpin, Insil Choi, Drea Sullivan, Sarah Sun, and Serena Wu; and, the students whose work appears on www.creatureconserve.

LITERATURE CITED

1. Burns TW, O'Connor DJ, Stocklmayer SM. Science communication: a contemporary definition. Public Understand Sci. 2003;12:183-202.

2. Kahan D. Opinion: Fixing the communications failure. Nature. 2010;463(21):296-297.

3. Negrete A, Lartigue C. Learning from education to communicate science as a good story. Endeavor 2004;28(3):120-124.

4. Palacios G, Lowenstine LJ, Gilardi KV, Spelman LH, Lukasik-Braum M, Kinani JF, Mudakikwa T, Nyirakaragire E, Bussetti AV, Savji N, Hutchison S, Egholm M, Lipiki WI. Human metapneumovirus infection in wild mountain gorillas, Rwanda. Emerg Infect Dis. 2011;17(4):711-713.

HIGH MORTALITY DUE TO STREPTOCOCCAL TOXIC SHOCK SYNDROME IN A CAPTIVE COLONY OF LION-TAILED MACAQUES (*Macaca silenus*)

Maya S. Kummrow, Dr med vet, DVSc, Dipl ACZM, Dipl ECZM (ZHM)[1]* and Kerstin Mätz-Rensing, Dr med vet[2]

[1]Zoo Wuppertal, 42117 Wuppertal, Germany; [2]German Primate Center, 37077 Göttingen, Germany

Abstract

An outbreak of *Streptococcus equi* subsp. *zooepidemicus* (SEZ) infection resulted in peracute death of five lion-tailed macaques (*Macaca silenus*) in a captive colony of 13 animals. The first case was found moribund after playful interaction with other group members and died despite intensive care for suspected head trauma. The necropsy revealed severe splenomegaly and serosanguinous thoracic and abdominal effusion. Over the next 4 days, four more animals died with similar findings. Based on preliminary microbiologic results, streptococcal infection was suspected and when a further animal appeared lethargic, it was immediately treated with antibiotics (marbofloxacin,[a] 2mg/kg, i.v., once; ceftiofur CFA,[b] 20mg/kg, s.c., once) and survived. From submitted post-mortem tissues, SEZ was isolated from all deceased animals. Surviving animals were treated prophylactically with long-term antibiotics (ceftiofur CFA,[b] 20mg/kg, s.c., once),[4] which prevented further cases. The source of infection was not determined. However, four of five dead animals were 3- to 4-yr-old males, and except for one adult female, the remaining three adults and four 1- and 2-yr-old offspring remained unaffected. This signalment potentially indicated competitive behavior amongst the subadults for a contaminated, attractive food item offered by an infected visitor. While fatal streptoccocal infections have been reported in nonhuman primates,[1,2] high mortality due to peracute streptococcal toxic shock syndrome (STSS) has not been reported. Although commonly seen with Group A streptococci (*S. pyogenes*),[5] STSS is caused rarely by Group C streptococci (*S. equi*) but needs to be considered in peracute mortalities with hemolytic shock syndromes in nonhuman primates.[3]

[a]Marbocyl 2%, Vetoquinol GmbH, Ravensburg Germany
[b]Naxcel 10%, Zoetis, Berlin, Germany

Key words: Lion-tailed macaque, *Macaca silenus*, *Streptococcus equi* subsp. *zooepidemicus*, streptoccoccal toxic syndrome

LITERATURE CITED

1. Brack M, Guenther E, Gillhaus H, Salzert W, Meuthen J. An outbreak of *Streptococcus equi* ssp. *zooepidemicus* infection of probable human origin in wanderoos (*Macaca silenus*) - case report. Zentralbl Bakteriol 1997;286:441-446.

2. Maetz-Rensing K, Winkelmann J, Becker T, Burckhardt I, van der Linden M, Koendgen S, Leendertz F, Kaup FJ. Outbreak of *Streptococcus equi* subsp. *zooepidemicus* infection in a group of rhesus monkeys (*Macaca mulatta*). J Med Primatol. 2009;38:328-334.

3. Natoli S, Fimiani C, Faglieri N, Laurenzi L, Frasca AM, Arcuri E. Toxic shock syndrome due to group C Streptococci- a case report. Intensive Care Med 1996;22:985-989.

4. Salyards GW, Knych H, Hill AE, Kelly RK, Christe KL. Pharmacokinetics of ceftiofur crystalline free acid in male rhesus macaques (*Macaca mulatta*) after subcutaneous administration. J Am Assoc Lab Anim Sci 2015;54:1-7.

5. Wong C, Stevens DL. Serious Group A Streptococcal Infections. Med Clin N Am 2013;97:721-736.

TRANSCUTANEOUS ULTRASOUND EVALUATION OF KIDNEY AND ADRENAL GLAND SIZE IN HEALTHY CALLIMICOS (*Callimico goeldii*) AND COMPARISON WITH MEASUREMENTS USING COMPUTED TOMOGRAPHY

James G. Johnson III, DVM,[1,2]* Jennifer N. Langan, DVM, Dipl ACZM, Dipl ECZM (ZHM),[2,3] Sathya K. Chinnadurai, DVM, MS, Dipl ACZM, Dipl ACVAA,[2] Randi Drees, Dr med vet, Dipl ACVR, Dipl ECVDI,[4] Mark Warneke, BS,[2] and Matthew C. Allender, DVM, MS, PhD, Dipl ACZM[3]

[1]Illinois Zoological and Aquatic Animal Residency Program, Urbana, IL 61802 USA; [2]Chicago Zoological Society, Brookfield Zoo, Brookfield, IL 60513 USA; [3]College of Veterinary Medicine, University of Illinois, Urbana IL 60802 USA; [4]Royal Veterinary College, University of London, Hatfield, AL9 7TA, UK

Abstract

Renal disease and adrenal gland hyperplasia are common conditions in callimicos (*Callimico goeldii*) that can be diagnosed in part using ultrasonography (US) and computed tomography (CT).[1,2] Ultrasonography is utilized routinely in suspected renal or adrenal disease to determine size, shape, and echogenicity characteristics of these organs. However, standard US and CT renal and adrenal gland parameters have not been established in this species. During routine examination, 18 callimicos were sedated using isoflurane[a] in oxygen via facemask. Physical examination, hematology, serum chemistry, and urinalysis were performed on each animal to determine health status and kidneys and adrenal glands were measured using US and CT. Ultrasound measurements for length (L), width (W), and height (H) in centimeters (mean ± 1 standard deviation) in 15 healthy animals were: right kidney (L = 1.88 ± 0.21; W = 1.07 ± 0.15; H = 1.59 ± 0.18), left kidney (L = 1.83 ± 0.19; W = 1.17 ± 0.20; H = 1.51 ± 0.17), right adrenal gland (L = 0.39 ± -0.08; H = 0.20 ± 0.06), and left adrenal gland (L = 0.36 ± 0.06; H = 0.19 ± 0.03). All kidney measurements were positively correlated with animal weight ($P \leq 0.05$), but had no significant correlation to age. Ultrasound measurements were confirmed with CT measurements as well as between healthy animals and three with chronic renal disease. Results from this study establish baseline antemortem measurements for kidneys and adrenal glands in this species. Monitoring organ changes using these imaging modalities will allow clinicians to diagnosis renal and adrenal disease and start treatment earlier, improving therapeutic success and welfare.

[a]Isothesia™, Henry Schein®, Dubin, OH 43017 USA

Key words: Adrenal gland, *Callimico goeldii*, computed tomography, Goeldi's monkey, kidney, ultrasound

ACKNOWLEDGMENTS

We thank the Brookfield Zoo's animal care and veterinary technician staff for their care of these animals.

LITERATURE CITED

1. Canizzo, SA, Langan, JN, Warneke, M, Allender, MC. Evaluation of in-house urine dipstick, reference laboratory urinalysis, and urine protein:creatinine ratio from a colony of Goeldi's monkeys (*Callimico goeldii*). Proc Am Assoc Zoo Vet; 2014. p. 128.

2. Crissey, SD, Meehan, TP, Langman, C, Pruett-Jones, MA. Vitamin D metabolites $25(OH)_2D$ and kidney function indices and the relationship to diet in Goeldi's monkeys (*Callimico goeldii*). Zoo Biol. 1999;18:565-574.

BLOOD PRODUCT TRANSFUSIONS IN GREAT APES: RETROSPECTIVE REVIEW OF 11 CASES

A. Hahn, DVM, Dipl ACZM,[1] G. Sturgeon, DVM,[1] and J. Rossi, MD, ABIM[2]*

[1]Pittsburgh Zoo & PPG Aquarium, Pittsburgh, PA 15206 USA; [2]Allegheny General Hospital, 320 E North Ave, Pittsburgh, PA 15212 USA

Abstract

While the administration of blood and blood products can be lifesaving, transfusions in exotic species are uncommon due to the lack of knowledge of blood groups, availability of species-specific donors, and possible adverse effects. Recently blood groups were elucidated in great apes,[1] however, few reports have been published on apes that have received transfusions, including protocol, and the ultimate clinical outcome. This information is critical as poorly executed transfusions can compromise already weakened patients or result in the death of the recipient.[2] In 2014 U.S. zoos housing great apes (n = 67) were surveyed and from responses (n = 45) 11 great ape transfusions were identified in Sumatran orangutan (*Pongo pygmaeus sumatraensis*) (n = 3), chimpanzee (*Pan troglodytes*) (n = 1), and gorilla (*Gorilla gorilla gorilla*) (n = 7). These animals, ranged from 5 mo-31 yr of age, received transfusions of either whole blood or packed red blood cells; human albumin, platelets, or plasma; or oxyglobin. Most transfusions consisted of whole blood collected during concurrent immobilizations and transfused immediately through standard transfusions sets with an appropriate filter. Overall, animals that received transfusions for anemia due chronic illness or blood loss survived, but those with concurrent life threatening issues did not. No reactions related to the transfusion occurred except in one orangutan with human albumin transfusion. Current human parameters to improve future transfusion success and treat potential reactions were assessed for recommendations to reduce these risks.[3-5]

Key words: Anemia, blood products, great ape, reaction, transfusion, whole blood

ACKNOWLEDGMENTS

The authors thank ABQ Biopark, Audubon Zoo, Birmingham Zoo, Wildlife Conservation Society, Buffalo Zoo, Cheyenne Mountain Zoo, Cincinnati Zoo, Cleveland Metro parks Zoo, Columbus Zoo, Como park Zoo, Dallas Zoo, Denver Zoo, Disney's Animal Kingdom, El Paso Zoo, Erie Zoo, Fort Wayne Children's Zoo, Fresno Chaffee Zoo, Gladys Porter Zoo, Henry Vilas Zoo, Indianapolis Zoo, Jackson Zoological Park, Jacksonville Zoo , Kansas City Zoo, Lincoln Park Zoo, Little Rock Zoo, Milwaukee Zoo, Oklahoma City Zoo, Omaha Henry Doorly Zoo, Philadelphia Zoo, Riverbanks Zoo and Garden, Rolling Hills Zoo, St. Louis, San Diego Zoo Global, Santa Barbara Zoo , Seneca park zoo, Sunset Zoo, Lowry Park Zoo, Maryland Zoo, Topeka Zoo, Tulsa Zoo, Hogle Zoo, Virginia Zoo, Woodland Park Zoo, and Zoo Atlanta for their participation in this survey.

LITERATURE CITED

1. Gamble K.C., J.A. Moyse, J.N. Lovestad, C.B. Ober, E.F. Thompson. 2011. Blood groups in the species survival plan, European endangered species program, and managed *In Situ* populations of bonobo (*Pan paniscus*), common chimpanzee (*Pan troglodytes*), gorilla (*Gorilla* spp.), and orangutan (*Pongo pygmaeus* spp.) Zoo. Biol. 2011;30:427-444.

2. Lichtenberger M. Transfusion medicine in exotic pets. Clin Tech Small Anim Prac. 2004;19(2):88-95.

3. National standards for Blood transfusion Service [Internet]. World Health Organization; c2013. [cited 2015 November 28]. Available from: http://www.who.int/bloodsafety/transfusion_services/BhutanNationalStandardsBTServices.pdf

4. Guidelines for the administration of blood and blood components [Internet]. The National Blood Users Group; c2002. [cited 2015 November 28]. Available from: https://www.giveblood.ie/Clinical_Services/Haemovigilance/Publications/Guidelines_for_the_Administration_of_Blood_and_Blood_Components.pdf

5. The clinical use of blood handbook [Internet] World Health Organization for Blood Transfusion Safety; c2001. [cited 2015 November 28]. Available from: http://www.who.int/bloodsafety/clinical_use/en/Handbook_EN.pdf

MANAGING EMERGING FUNGAL INFECTIONS IN WILDLIFE AND AGRICULTURE: DEVELOPING NOVEL TOOLS TO CONTROL NOVEL PATHOGENS

Christopher T. Cornelison, PhD,[1]* Sybill Amelon, PhD,[2] Sarah Hooper, DVM,[3] Kyle Gabriel, MS,[1] Courtney Barlament, MS,[1] Sid Crow, PhD,[1] and George Pierce, PhD[1]

[1]Applied and Environmental Microbiology, Georgia State University, Atlanta GA 30302 USA; [2]US Forest Service Northern Research Station, Columbia, MO 65211 USA; [3]Department of Veterinary Pathobiology, College of Veterinary Medicine, University of Missouri, Columbia, MO 65211 USA

Abstract

Over the past 3 decades the occurrence and severity of fungal disease in wildlife and agriculture have increased markedly. The fungal pathogens responsible vary significantly in host range, virulence, and susceptibility to management efforts. Diseases such as Chytridiomycosis in amphibians, white-nose syndrome of bats, snake fungal disease of reptiles, citrus black spot, Fusarium banana wilt, Aspergillosis of sea coral, and Nosema disease of honeybees have all been attributed to mass mortalities and are noted to precipitate major ecological and agricultural disturbances if unmitigated. Historical examples of fungal epidemics (i.e., chestnut blight) support the theory that fungal pathogens drive regional extirpations of naive hosts and are capable to transforming entire ecosystems and economies. Accordingly the development of novel tools, to facilitate economically and logistically feasible disease management, must be developed to avert these potential disasters. For this lecture white-nose syndrome will serve as an anecdotal example of how the development of these tools may be conducted and the challenges associated with their implementation.

Pseudogymnoascus destructans, the causative agent of bat white-nose syndrome (WNS), was introduced into New York State from Eurasia in the mid 2000's. Mass mortalities due to WNS in North American bats was first documented in 2007. As of 2015 WNS has been confirmed in 30 US states and 5 Canadian provinces and moves westward every winter. Estimating wild animal mortalities is challenging, however most attempts regarding WNS-affected species estimate current WNS related bat mortalities in the 10's of millions with regional population declines exceeding 90%. Due to the saprophytic nature of *P. destructans*, this fungus will likely remain a pervasive component of the environment. Therefore, the fundamental goal of maintaining viable WNS-affected bat populations through time across multiple landscapes requires a multifaceted strategy to reduce WNS related mortalities. WNS has been identified as a strategic priority of numerous federal agencies with research efforts focusing on Integrated Disease Management (IDM). This approach anticipates the occurrence of disease, addresses the mechanisms of host/pathogen interactions, and intervenes at vulnerable points in the disease cycle. The focus is on prevention of pathogen proliferation and/or treatment with appropriate methods with minimal effects on the environment.

Towards these objectives we are evaluating multiple treatments for WNS. Based on lab and field trials to date, our primary treatment efforts focus on the soil bacterium *Rhodococcus rhodochrous*

DAP 96253. The in vitro activity of induced *Rhodococcus rhodochrous* strain DAP96253 against *Pseudogymnoascus destructans* has been well established. In an effort to effectively forecast the in situ efficacy of this potential biocontrol agent at reducing the mortality of bats with WNS, induced *R. rhodochrous* was investigated for potential toxicologic effects on healthy bats, as well as its ability to influence disease outcome in naturally infected bats in vitro. In all cases favorable experimental outcomes were observed and further analysis established a statistical significance to the survival of naturally-infected bats exposed to induced *R. rhodochrous*. Cumulatively, these results represent a significant step towards in situ management of this disease and serve as a model for the development of novel tools to manage emerging fungal diseases of ecological and agricultural significance.

Key words: Bats, microbial control, mycosis, *Pseudogymnoascus destructans*, *Rhodococcus rhodochrous*

GROSS LESION RECOGNITION IN ZOO REPTILES

Michael M. Garner, DVM, Dipl ACVP

Northwest ZooPath, 654 W. Main St., Monroe, WA 98272 USA

Abstract

Gross lesion recognition, like other imaging modalities, is a bit of an art form. Vast zones of grey may confront the investigator when considering what the lesion is, what it could be, and what to do with it. And nobody is good at all of it: A seasoned livestock pathologist could possibly clear an entire days' necropsies without the help of a single histology slide. A bee keeper would recognize immediately the maggot stages that parasitize his colony. A dog-cat pathologist in a busy private laboratory or a companion animal clinician may not have a clue about gross lesions in livestock or bees. Historically, our attempts at accurately diagnosing disease by gross lesion recognition have been a humbling experience, and that has been the impetus for all further diagnostic specialties.

So now that we have put gross pathology in its proper place, why even bother with such an imperfect science? Obviously, gross lesions, or lack thereof, are the first visual indication of what may be wrong with the patient. These are the lumps, the effusions, the asymmetric oddities, the discolorations, the odiferous clues to disease that (hopefully) stimulate a "scientific" thought process culminating in a list of differential diagnoses. The purpose of this masterclass is to present images of common and not so common reptile gross lesions in live and necropsy specimens, and in a participatory manner, establish a differential diagnosis and means for establishing a definitive diagnosis.

Key words: Diagnosis, differential, gross lesion, pathology, recognition, reptile

HEALTH ASSESSMENT IN FREE ROAMING CETACEANS: DETERMINING BASELINE LEVELS FOR CYTOKINE EXPRESSION IN COMMON DOLPHINS

Carolina Bento, DVM, MSc,[1,5]* Pedro Verdelho, UGRD,[1] Catarina Eira, Biology MSc, PhD,[2,5] José Vingada, Biology MSc, PhD,[3,5] Marisa Ferreira, Biology MSc,[3,5] Luís Tavares, DVM, MSc, PhD,[1] and Ana Duarte, DVM, MSc, PhD[1]

[1]CIISA, Faculty of Veterinary Medicine, ULisboa; Avenida da Universidade Técnica 1300-477, Lisboa, Portugal; [2]Centre for Environmental and Marine Studies (CESAM), University of Aveiro, 3810-193 Aveiro, Portugal; [3]Centre for Environmental and Marine Studies, Department of Biology, Minho University, 4710-057 Braga, Portugal; [5]Portuguese Wildlife Society, Department of Biology, Minho University, 4710-057 Braga, Portugal

Abstract

Cytokines play a key role in the establishment of immune response and are crucial in host immunity during infection and inflammatory processes. These small proteins have the ability to modulate the balance between humoral and cell-based response.[2] Viral infections are capable of manipulating cytokine expression in order to favor viral success. Recognising reference values for these cytokines in healthy animals is the first step to allow the detection of immunologic shifts caused by pathogen infections or stress.[1] For the assessment of baseline values for gene expression cetaceans presented at necropsy were sampled (n = 30). These samples were collected from bycaught animals, with no obvious signs of disease at necropsy and negative for cetacean morbillivirus and herpesvirus, recent feeding and good body condition. Specific primers for the amplification of mRNA for cytokines that participate in cellular immunity (IFN-α, TNFα and IL12) and humoral immunity (IL-4, IL-10, IL6 and IL1β) were designed and RPL7 was selected as a housekeeping gene. Total RNA was extracted from lymphnodes and cDNA was synthesized and used to perform quantitative PCR. CT values for each gene were normalised and used to determine means and standard errors for the cytokines in study. Coefficients of variation for each cytokine were calculated and the baseline values for each gene were assessed for this group. Our results allowed the determination of baseline immunologic parameters to be compared with cytokine profile for cetaceans positive to cetacean morbillivirus. These data represent a valuable tool for health assessment in free ranging cetacean populations.

Key words: Cytokines, *Delphinus delphis*, free roaming, gene expression, health status, qPCR

ACKNOWLEDGMENTS

The authors thank the Portuguese Wildlife Society (SPVS) for assistance with data and sample collection. The authors further thank CIISA at FMV-Ulisboa where the laboratory work was developed.

LITERATURE CITED

1. Müller S, Lehnert K, Seibel H, Driver J, Ronnenberg K, Teilmann J, van Elk C, Kristensen J, Everaarts E, Siebert U. Evaluation of immune and stress status in harbour porpoises (*Phocoena phocoena*): can hormones and mRNA expression levels serve as indicators to assess stress? BMC Vet Res [Internet]. 2013 [cited 2014 Sep 26];9:145. Available from: http://www.pubmedcentral.nih.gov/articlerender.fcgi?artid=3734172&tool=pmcentrez&rendertype=abstract

2. Fenner's Veterinary Virology [Internet]. Elsevier; 2011 [cited 2015 Nov 30];75-99. Available from: http://www.sciencedirect.com/science/article/pii/B9780123751584000043

Pseudomonas aeruginosa DERMATITIS IN A CARIBBEAN WHIPTAIL STINGRAY (*Himantura schmardae*)

Erick O. Bernal, MV,* Sac-Nictec Y. Franco, MVZ, and Josue Garduno, MVZ

Xcaret Archaeological Park, Playa del Carmen, Quintana Roo 77710 Mexico

Abstract

A wild-caught female Caribbean whiptail stingray (*Himantura schmardae*) of approximately 3 yr of age and an estimated weight of 37 kg housed in a lagoon at the Xcaret Archaeological Park, presented with ventral ulcerations with an acute degenerative disease. Blood was drawn from the caudal vein for a CBC and blood chemistry panel, a ventral dermis biopsy was performed and submitted for histopathology and bacterial culture. The result from the bacterial culture was *Pseudomonas aeruginosa* and treatment with gentamicin was selected based on sensitivity results. With the appropriate, targeted treatment, the lesions were improving from the first treatment and the integrity of the dermis improved day by day. *P. aeruginosa* is a gram-negative opportunistic bacterium that can colonize in dermal injuries and potentially result in serious sequelae. It can grow in a variety of environments or substrates and importantly, it frequently shows resistance to many antibiotics.[2] Infection with *P. aeruginosa* can cause aggressive and progressive lesions, potentially progressing to septicemia, endangering the life of the animal, if it is not detected and effectively treated.[2] Appropriate administration of antibiotics, can help prevent resistance.[1] Additionally, identifying the effective antibiotic for a given infection may decrease the stress generated by excessive handling for potentially ineffective treatment and improve the prognosis. Institutions that have a collection of Caribbean whiptail stingrays or, potentially any elasmobranch species, should consider this bacteria as a differential diagnosis in dermal infections.[2]

Key words: Caribbean whiptail stingray, dermatitis, elasmobranch, gentamicin, *Himantura schmardae*, *Pseudomonas aeruginosa*

ACKNOWLEDGMENTS

Special thanks to Archaeological Park Xcaret for all the support and for letting me publish this case. Deep thanks to Gabriela Lara, Josue Garduno and Imelda Valladares because without them I would not have accomplished this clinical case. I dedicate this work to Sac Nictec Y. Franco because she was the person who was directly related to the case and with whom I worked each day to treat this case.

LITERATURE CITED

1. Plumb DC. Plumb´s veterinary drug handbook. 7th ed. Stockholm (WI): Pharma Vet Inc; 2011. p. 1553-1564.

2. Noga EJ. Fish disease, diagnosis and treatment, 2nd ed. Raleigh (NC): Wiley Blackwell; 2010. p. 497.

AN INVESTIGATION INTO FACTORS AFFECTING THE AMOUNT OF LEAKAGE FROM INTRAMUSCULAR INJECTIONS IN FISH

Iain Cope, BSc(VetSci)Hons, BVM&S, CertAVP(ZM), MRCVS[1]* and Becca Powell, BA, VetMB[2]

[1]Cambridge Veterinary Group, Cambridge, Cambridgeshire CB1 7BS, UK; [2]West Mount Vets, Todmorden, Lancashire OL14 7BU, UK

Abstract

Leakage from intramuscular injections in fish may have a negative impact on our effectiveness in treating fish. This will contribute to wastage of the drug, excessive dosing or under-dosing, environmental contamination, and to the development of antibiotic resistance. Under controlled conditions, 1 kg dead rainbow trout (*Oncorhynchus mykiss*) were injected intramuscularly in the epaxial muscle using 23-gauge needles. Ranges of volumes of different injectable agents were used, and pressure was applied to the injection site for a range of times. All injectable agents had a small amount of red food dye added to them to allow visual assessment of leakage with time. Leakage was captured using photographic equipment and volumes calculated using a grid volume system. A significant correlation between volume injected and leakage was seen (amoxicillin: $R^2 = 0.32$, $P = 0.01$; dexamethasone: $R^2 = 0.26$, $P = 0.05$; water: $R^2 = 0.36$, $P = 0.007$), indicating that the greater the volume, the more leaked out of the injection site. Application of digital pressure to the injection site reduced this leakage (amoxicillin: $R^2 = 0.31$, $P = 0.001$; water: $R^2 = 0.38$, $P = 0.0004$). There was no significant difference between solutions injected of different viscosity. Thus it can be concluded that the smaller the volume of drug that can be injected, and the longer digital pressure can be applied to the site (at least 3 sec), then the less leakage there is from the fish.

Key words: Fish, injections, leakage, pressure, viscosity, volume

ACKNOWLEDGMENTS

The authors would like to thank Cambridge Veterinary College for their assistance with this project.

TRENDS OF THE FLORIDA MANATEE (*Trichechus manatus* ssp. *latirostris*) REHABILITATION EFFORTS AT TAMPA'S LOWRY PARK ZOO

Kelleen Johnson, BAS[1,2]* and Ray Ball, DVM[3]

[1]Western University of Health Sciences, College of Veterinary Medicine, Pomona, CA 91766 USA; [2]University of South Florida, College of Public Health, Tampa, FL 33620 USA; [3]Tampa's Lowry Park Zoo, Tampa, FL 33604 USA

Abstract

Tampa's Lowry Park Zoo is one of three federally permitted manatee critical care facilities in the state of Florida for rehabilitation of the endangered Florida manatee (*Trichechus manatus* ssp. *latirostris*). Determining the relationship between causes of admittance and re-release outcomes will help to facilitate management practices to increase rehabilitation rates thereby enhancing conservation efforts, allocating funds in the right direction, and improving medical therapies. The database used to determine these relationships consisted of 322 manatees from January 1991 through March 2014. Causes of admittance, location of rescue, mortality rates, and length of stay were analyzed. Causes of admittance included watercraft collisions, natural causes (consisting of cold stress, red tide outbreaks, and miscellaneous nonhuman related), entanglement, entrapment, captive born, mothers of rescued calves, calves of rescued mothers, human, and other. Locations of rescue surrounding Florida included the southwest, southeast, northwest, northeast, Crystal River, and east coast. The admitted population was primarily from the southwest and northwest and was stratified by age and gender. The gender difference was relatively equivocal (54% female) while the adults heavily outnumbered the calves making the adult population the primary focus (80% adults). Watercraft collisions and natural causes combined were 69.88% of the causes of admittance making them the primary focus of causes. Watercraft collisions are more likely to occur during the summer months whereas natural causes of admittance are more likely to occur during the winter months. Outcomes of mortality are more likely to result with watercraft collisions than natural causes [OR: 5.7 95% CI: (3.1,10.4) $P < 0.0005$]. Gender had no influence on outcomes. Those that were re-released into their natural habitat had an increased length of stay compared to those who were not re-released; however, the length of stay for those re-released has been declining. Annual mortality rates declined over time while annual admittance rates increased. Review of these factors provides valuable information to improve rehabilitation efforts of the Florida manatee at Lowry Park Zoo. Future efforts should include evaluation of physical examination findings, blood profiles, ancillary diagnostic testing, and collaboration with the other permitted critical care facilities in Florida.

Key words: Critical care facilities, Florida manatee, mortality rates, red tide, *Trichechus manatus* ssp. *latirostris,* watercraft collisions

ACKNOWLEDGMENTS

The authors would like to thank Tampa's Lowry Park Zoo for sharing their data in the interest of establishing baseline information for the conservation efforts of their program.

CHALLENGES OF MEDICAL THERAPY IN THE TREATMENT OF CORNEAL ABSCESS IN A SUBANTARCTIC FUR SEAL (*Arctocephalus tropicalis*)

Laura C. Reisfeld, DVM,[1]* Paloma C. Henrique, DVM,[1] and Carmen M.H. Colitz, DVM, PhD, Dipl ACVO[2]

[1]Aquário de São Paulo, São Paulo, SP 04275-000 Brazil; [2]All Animal Eye Care, Jupiter, FL 33458 USA

Abstract

Diseases of the cornea and lens are common in captive pinnipeds and can be attributed to environmental factors including water quality, water salinity, and spatial characteristics.[2] Subadult and adult pinnipeds can be affected by mild to moderate ulcerative and non-ulcerative corneal disease. There are numerous anecdotal theories implicating environmental factors for inducing keratopathy in pinnipeds. Otariid keratopathy is a clinically prevalent, painful and progressive.[1] When keratopathy is active with superficial ulcers, it must be treated aggressively because loss of the superficial epithelium predisposes them to secondary infections. Once a secondary infection is identified, it is imperative that aggressive antibiotic and anti-inflammatory therapy be initiated to avoid progression.[1] A 10-yr-old male, Subantarctic fur seal (*Arctocephalus tropicalis*), presented with his right eye closed, blepharedema, and obvious intense discomfort. A day after the beginning of the treatment (ketoprofen 1 mg/kg, p.o., s.i.d.; prednisone 0.5 mg/kg, p.o., s.i.d.; diclofenac sodium and tobramycin eye drops, t.i.d.; dipirone 25 mg/kg, p.o., b.i.d.; tramadol 2 mg/kg, p.o., b.i.d.; doxycycline 10 mg/kg, p.o., b.i.d.; ranitidine 1 mg/kg, p.o., b.i.d.) some improvement could be noticed, but the eye remained closed most of the time. A circular, white lesion, approximately 0.3 cm in diameter, with white exudate was observed, and was suspected to be a corneal abscess. Swab for bacterial culture was collected and growth of *Citrobacter braaki* was observed. With diagnosis of a corneal abscess, a new treatment approach was implemented: doxycycline (5 mg/kg, p.o., b.i.d.,15 days); tramadol (100 mg/animal, p.o., b.i.d.); amoxicillin and clavulanic acid (10 mg/kg, p.o., b.i.d., 14 days), carprofen (2 mg/kg, p.o., s.i.d.), ranitidine (1 mg/kg, p.o., b.i.d.), gatifloxacin ophthalmic solution (3 drops, q.i.d.), tobramycin ophthalmic solution (3 drops, q.i.d.), and tacrolimus 0.02% ophthalmic suspension (3 drops, q.i.d.). The broad spectrum antibiotics were used to address the bacterial infection suspected to be the cause of the abscess, as often occurs in otariid keratopathy.[2] Use of topical tacrolimus was used to to re-establish the tolerance of ocular surface antigens and self-antigens.[2] After 12 days of treatment, the animal was still keeping the eye closed. At this time, doxycycline was continued but amoxicilin and clavulanic acid were replaced by enrofloxacin (2,5 mg/kg, p.o., b.i.d.). The eyedrops were continued. Four days later the animal was opening his eye and a great improvement of the lesion could be noticed. Tacrolimus was continued to help the vessels to resolve and to balance the immune system of the cornea. All other meds were slowly discontinued as the animal was showing improvement and no signs of pain. The causative agent of the lesion was *Citrobacter braaki*. The animal had been kept in saltwater for his entire life, however, due to logistic problems; he had been in freshwater for 1 mo prior to onset of the abscess, which may have contributed to the development of this problem. The other male fur seal at the exhibit did not show any problems at that time.

Key words: *Arctocephalus tropicalis*, corneal abscess, keratopathy, ophthalmology, Subantarctic fur seal

LITERATURE CITED

1. Colitz, CMH, Renner, MS, Manire, CA, Doescher, B, Schmitt, T.L, Osborn, SD, Croft, L, Olds, J, Gehring, E, Mergl, J, Tuttle, AD, Sutherland-Smith, M, Rudnick JC. Characterization of progressive keratitis in Otarids. Vet Ophthalmol. 2010;13(1):47-53.

2. Colitz, CMH, Saville, WJA, Renner, MS, McBain JF, Reidardson, TH, Schmitt, TL, Nolan, EC, Dugan, SJ, Knightly, F, Rodriguez, MM, Mejia-Fava, JC, Osborn, SD, Clough PL, Collins, SP, Osborn, BA and Terrel, K. Risk factors associated with cataracts and lens luxations in captive pinnipeds in the United States and the Bahamas. J Am Vet Med Assoc, 2010;237(4):429-436.

EVALUATION OF FACTORS IMPACTING SERUM CORTISOL CONCENTRATIONS IN ATLANTIC BOTTLENOSE DOLPHINS (*Tursiops truncatus*) AT THE NATIONAL AQUARIUM

Estelle Rousselet, PhD, DVM,[1]* Catherine A. Hadfield, MA, VetMB, MRCVS, Dipl ACZM, Dipl ECZM,[2] Leigh Ann Clayton, DVM, Dipl ABVP (Avian and Reptile/Amphibian),[2] and Allison C. Ginsburg[2]

[1]Aquatic Animal Health Program, Department of Large Animal Clinical Sciences, College of Veterinary Medicine, University of Florida, Gainesville, FL 32608 USA; [2]National Aquarium, Baltimore, MD 21202 USA

Abstract

In Atlantic bottlenose dolphins (*Tursiops truncatus*), serum cortisol has been shown to increase during acute stress and vary in response to diurnal cycles and chronic disease.[1-5] Effects of health status and positive reinforcement training (PRT) on cortisol in managed populations are not well reported. In this retrospective study, 13 animals under managed care were sampled (n = 75) over 10 yr. Samples were categorized as healthy vs. unhealthy (based on clinical signs) and voluntary via PRT (V) vs. manual restraint following lowering of the water (MR). The values for serum cortisol median and ranges are presented (Table 1); median values are compared.[a] Median value for all samples was similar to values in free-ranging bottlenose dolphins and higher than values in small cetaceans under managed care.[1,5] There was no significant difference ($P = 0.7$) between healthy and unhealthy median values. Voluntary median value was significantly lower than MR median value ($P < 0.001$). In cross-category comparisons, the only statistically significant difference was that the median value for healthy/MR was higher than healthy/V ($P < 0.001$). In this review, voluntary blood and desensitization to manual restraint were associated with lower cortisol values. Further research is warranted to investigate normal cortisol responses and optimal management situations for individual animals.

[a]Software package R Project for Statistical Computing (http://www.r-project.org) version 3.0.2 (R Development Core Team)

Key words: Bottlenose dolphin, cortisol, restraint, serum, *Tursiops truncatus*

LITERATURE CITED

1. Hart LB, Wells RS, Kellar N, Balmer BC, Hohn AA, Lamb SV, Rowles T, Zolman ES, Schwacke LH. Adrenal hormones in common bottlenose dolphins (*Tursiops truncatus*): influential factors and reference intervals. PLoS One. 2015;10(5):e0127432.

2. Noda K, Akiyoshi H, Aoki M, Shimada T, Ohashi F. Relationship between transportation stress and polymorphonuclear cell functions of bottlenose dolphins *Tursiops truncatus*. J Vet Med Sci. 2007;69:379-383.

3. Schwacke LH, Smith CR, Townsend FI, Wells RS, Hart LB, Balmer BC, Collier TK, De Guise S, Fry MM, Guillette Jr LJ, Lamb SV, Lane SM, McFee WE, Place NJ, Tumlin MC, Ylitalo GM, Zolman ES, Rowles TK. Health of common bottlenose dolphins (*Tursiops truncatus*) in Barataria Bay, Louisiana, following the Deepwater Horizon oil spill. Environ Sci Technol. 2014;48:93-103.

4. St. Aubin DJ, Ridgway SH, Wells RS, Rhinehart H. Dolphin thyroid and adrenal hormones: circulating levels in wild and semidomesticated *Tursiops truncatus*, and influence of sex, age, and season. Mar Mammal Sci. 1996;12:1-13.

5. Suzuki M, Uchida S, Ueda K, Tobayama T, Katsumata E, Yoshioka M, Aida K. Diurnal and annual changes in serum cortisol concentrations in Indo-Pacific bottlenose dolphins *Tursiops aduncus* and killer whales *Orcinus orca*. Gen Comp Endocrinol. 2003;132:427-433.

Table 1. Serum cortisol concentration descriptive statistics (median and range) for 13 Atlantic bottlenose dolphins (*Tursiops truncatus*) under managed care with data displayed by category (total, healthy, unhealthy, voluntary, manual restraint, and cross-categories).

Category	n	Median (range) µg/dl
Total	75	1.35 (0.15-4.56)
Healthy	52	1.61 (0.15-4.56)
Unhealthy	23	1.08 (0.21-3.66)
Voluntary	29	0.35 (0.15-3.90)
Manual restraint	46	2.01 (0.21-4.56)
Healthy/Voluntary	24	0.43 (0.15-3.90)
Healthy/Manual restraint	28	2.14 (0.47-4.56)
Unhealthy/Voluntary	5	0.35 (0.28-2.66)
Unhealthy/Manual restraint	18	1.24 (0.21-3.66)

VETERINARY ASPECTS OF TRANSPORT AND REINTRODUCTION OF ANTILLEAN MANATEES (*Trichechus manatus manatus*) IN THE GRAND CUL-DE-SAC BAY IN GUADELOUPE, FRENCH LESSER ANTILLES

Natalia M. Rozniewska, DVM,[1]* Jolt Evva, DVM,[1] Ray L. Ball, DVM,[2] and Sébastien Rives[1]

[1]Parc National de la Guadeloupe, Lamentin, Guadeloupe 97129, France; [2]Tampa's Lowry Park Zoo, Tampa, FL 33604 USA

Abstract

Antillean manatee (*Trichechus manatus manatus*) is classified as endangered by the IUCN Red List of Threatened Species. Its populations are in decline in 14 out of 20 countries due to habitat destruction, boat collisions, entanglement in a fishing gear and even hunting. In Lesser Antilles manatees were extirpated in early 20th century. In 2002 the Government of France together with the National Park of Guadeloupe initiated a reintroduction project in order to a) improve the global conservation status of the species by re-establishing a population in the Lesser Antilles where it has disappeared completely, and b) create a transferable model of reintroduction for other marine mammals elsewhere in the world. Reintroduction is designed to be accomplished mainly by translocation of captive manatees from range countries of the Wider Caribbean and supplemented as possible with captive propagation in the care facility in Guadeloupe. This captive propagation could potentially extend into European zoological collections. The initial process, already engaged for years, included defining the founder population, locating sites for facility support, care centers, and soft release sites. Design of the care facilities was intended to account for the immediate care of translocated manatees but also with the vision to care for potentially injured manatees and for any support needed for captive propagation. Close coordination with wildlife authorities in the French National Park and with French regulatory veterinarians was necessary to ensure protection of domestic animal health on Guadeloupe and within the European Union (EU). Selection of initial animals for the project is therefore focused on a captive population. In contrast to the wild ones, these should be less prone to dispersal, their health and genetic status is already recognized and they are accustomed to capture and manipulation. Preliminary health assessment consists of permanent identification, general examination, body measurements (weight, total curvilinear and straight length, girth at umbilicus, axilla and peduncle), blood analyze (CBC and biochemistry), ultrasound fat tissue measurement, genetic study, reproductive history and behavior observation. Chosen manatees will be subjected to secondary examination not more than 30 days prior transportation. It will include repetition of general exam, blood sampling and body measurements. Moreover, to fulfill requirements of French veterinary administration, all the animals will have to be given an anthelminthic. Infectious disease screening has been limited to documentation that *Mycobacterium bovis* has not been reported in the literature in any captive or wild manatees to date. The targeted goal is to obtain a minimum of 15 individuals with the majority of females to constitute the founder population. They are supposed to be relocated to Guadeloupe out of water in a specially designed wooden boxes. Unless overexcited, it is not planned to sedate the animals for a transportation, but keep moistened and monitored by at least one experienced veterinarian and two keepers who accompany the manatees in the plane. Once arrived, manatees will be released directly in the care facility. Following their delivery, calf care and weaning, the first generation will be moved to soft-released enclosure for an adaptation period. Once their health and

behavior will leave no concern, manatees will be equipped with radio tags and released in the Grand Cul-de-Sac bay. It is expected to achieve a population of a hundred manatees in around 40 yr.

Key words: Antillean manatee, conservation, Guadeloupe, reintroduction, transport, *Trichechus manatus manatus*

SURGICAL MANAGEMENT OF CERVICAL AIR SAC RUPTURE IN A JACKASS PENGUIN (*Spheniscus demersus*)

Rui Bernardino, DVM,* Teresa Lobo Fernandes, DVM, Arlete Sogorb, DVM, and Narciso Lapão, DVM

Jardim Zoológico e de Aclimação de Portugal, Estrada de Benfica, 158-160 Lisboa, Portugal

Abstract

Cervical air sac ruptures in birds are usually related to sacullitis or trauma in cases where a specific cause can be diagnosed. A 13-yr-old female *Spheniscus demersus* was brought in for observation due to presumptive cervical swelling. The penguin was submitted to a physical evaluation, blood sampling and radiologic examination that confirmed the subcutaneous emphysema in the projection of the left cervical air sac. Air sacculitis and trauma (evident) were ruled out. A prosthetic valve was adapted (from a valve of an Aquisel® blood collecting tube) and inserted during surgery. The valve was maintained during 8 wk with regular controls. In the x-ray projections the post-op residual air between tissues showed a similar appearance once compared to the pre-op ones, making the physical examination more accurate to evaluate post operatively the cicatrization between tissues. After 8 wk a stopper was inserted in the valve in order to evaluate the possibility of removal of the valve. After 48 hr without air accumulation the valve was removed and the valve bed was left to heal by secondary intention. The post-op period was uneventful and posterior evaluations confirmed the full recovery of the patient. The animal was maintained on prophylactic treatment with 15 mg/kg enrofloxacine p.o. (Baytril® 5%, Bayer Saúde Animal) for 2 wk and 33 mg itraconazol p.o. (Sporanox®, Janssen Farmacêutica Portugal, Lda.) for 3 wk, due to previous cases of aspergillosis in the collection. Although described in several avian species to the author's knowledge, this is the first report of a cervical air sac ruptured and surgical treatment in a penguin species.

Key words: Air sac, penguin, rupture, *Spheniscus demersus*, valve

OVICIDAL EFFECT OF THE FUNGUS *Pochonia chlamydospora* ON THE GASTROINTESTINAL PARASITE *Contracaecum pelagicum* IN THE MAGELLANIC PENGUIN (*Spheniscus magellanicus*)

Cindy Braud, VM,[1]* Fabio Ribeiro Braga, DVM, MS, PhD,[2,3,4] Filippe Elias de Freitas Soares, MS, PhD,[3] Tiago Senna, MS, PhD,[3] Thiago de Hollanda Ayupe, DVM, MS,[3] Leandro Abreu da Fonseca, DVM, MS, PhD,[2] Tracy Lacerda,[3] Anderson Rocha Aguiar,[3] Luis Felipe Mayorga, DVM,[3] and Jackson Victor de Araújo, DVM, MS, PhD[2]

[1]Ecole Nationale Vétérinaire de Toulouse, Toulouse, Midi-Pyrénées, 31300, France; [2]Laboratório de Parasitologia Departemento de Veterinária, Universidade Federal de Viçosa, Viçosa, Minas Gerais, Brazil; [3]Universidade Vila Velha, Vila Velha, Esperito Santo, Brazil; [4]CNPq Scholarship

Abstract

Gastrointestinal parasitism is one of the main causes of mortality of the Magellanic penguin (*Spheniscus magellanicus*).[2,7] *Contracaecum pelagicum* is a nematode found in fish-eating birds.[5] In Magellanic penguins the inflammatory process and obstructions due to high parasite burdons are reported and occasionally lead to the death.[3,4,8] The use of fungus to control parasitic infestations is well known.[1,6] The aim of this study was to evaluate the ability of the fungus *Pochonia chlamydosporia* to clear *Contracaecum pelaginum* eggs from these penguins. *Contracaecum pelagicum* eggs were obtained by dissection of the uterus of an adult parasite found in a Magellanic penguin, cultured in YPSSA medium and incubated at 25°C for 28 days. The ovicidal effect was evaluated under different concentrations (500, 1000, 2000, 3000) of a *Pochonia chlamydosporia isolates (VC4)* in a Petri dish containing 2% WA medium. Each treatment was evaluated after 5 and 7 days and classified according to the alterations of the eggshell and embryo disposal. For each of the four tested concentrations, significant alterations of the egg shell with death of the embryo were identified, highlighting a significant difference ($P < 0.01$) compared to the control group. No difference was noted ($P > 0.01$) for ovicidal activity between the four concentrations used. The highest percentages of ovicidal effect were observed at concentrations of 2000 and 3000 chlamydospores after 7 days of incubation with respectively 45.3% and 46.2% destruction. These findings show that *Pochonia chlamydosporia* could be a promising adjunct as an alternative control strategy of *Contracaecum pelagigum* in the environment.

Key words: Alternative control, *Contracaecum pelagicum,* gastrointestinal parasite*,* Magellanic penguin*, Pochonia chlamydosporia, Spheniscus magellanicus*

ACKNOWLEDGMENTS

The authors would like to thank the Institute of Research and Rehabilitation of Marine Animals (IPRAM) for their assistance in the care of the penguins and Dr. Minh Hyunh, DVM, MRCVS, DECZM (avian) for his pertinent annotations and advice.

LITERATURE CITED

1. Braga FR, Araújo JV. Helminthiasis control of domestic animals, a new approach to an old problem. In: Paz Silva A, Arias-Vazquez MS. (eds). Fungi: Types, environmental impact and role in disease. New York (NY): Nova Science Publishers; 2012. p. 7-10.

2. Carvalho CO, Cuenca SC, Kleeb SR, Gallo H, Baldassin P. Gross and histopathological findings in Magellanic penguins (*Spheniscus magellanicus* Forster, 1781). Arq Bras Med Vet Zootec. 2012;64:769-772.

3. Ederli NB, Oliveira FCR, Monteiro CM, Silveira LS, Rodrigues MLA. Ocorrência de *Contracaecum pelagicum* Johnston & Mawson, 1942 (Nematoda, Anisakidae), em pinguim-de-magalhães (*Spheniscus magellanicus* Forster, 1781) (Aves, Spheniscidae) no litoral do Espírito Santo. Arq Bras Med Vet Zootec. 2009.61:1006-1008.

4. Garbin LE, Navone GT, Diaz JI, Cremont F. Further study of *Contracaecum pelagicum* (Nematoda: Anisakidae) in *Spheniscus magellanicus* (Aves: Spheniscidae) from Argentinean coasts. J Parasitol. 2007;93:143-150.

5. Girisgin AO, Alasonylilar-demirer A. A Case of *Contracaecum* sp. (Ascaridida: Anisakidae) infection in Dalmatian pelican (*Pelecanus crispus*). Kafkas Univ Vet Fak Derg. 2005;18:227-229.

6. Lysek H, Fassatiová O, Pineda NC, Hernández NL. Ovicidal fungi in soils of Cuba. Folia Parasitol. 1982;29:265-270.

7. Martins ML, Santos RS, Marengoni NG, Takahashi HK, Fujimoto RY. Infection and susceptibility of three fish species from the Paraná River, Presidente Epitácio, SP, Brazil to *Contracaecum* sp. larvae (Nematoda: Anisakidae). Acta Sci. 2003;25:73-78.

8. Santos CP. Um nematódeo parasita do pinguim *Spheniscus magellanicus* (Forster) (Ascaridoidea, Anisakidae). Mem Inst Oswaldo Cruz. 1984;79:233-237.

SERUM CONCENTRATIONS OF IONISED CALCIUM, TOTAL CALCIUM AND PHOSPHORUS IN THE CRITICALLY ENDANGERED KĀKĀPŌ (*Strigops habroptilus*)

James Chatterton, BVMS, MSc, CertZooMed, MRCVS,[1]* An Pas, DVM, MVS (ConsMed),[1] Sarah A. Alexander, BSc, BVMS, PGCert,[1] Joanne Paul-Murphy, DVM, Dipl ACZM, Dipl ACAW,[2] Richard Jakob-Hoff, BVMS, MANZCVS,[1] Daryl Eason, PGDipSci,[3] and Andrew Digby, PhD[3]

[1]New Zealand Centre for Conservation Medicine, Auckland Zoo, Auckland, NZ 1245; [2]Department of Veterinary Medicine and Epidemiology, University of California-Davis, Davis, CA 95616 USA; [3]Kākāpō Recovery Team, Department of Conservation, Invercargill, 9840, NZ

Abstract

Kākāpō *(Strigops habroptilus)* are flightless, nocturnal parrots, endemic to New Zealand. They are the heaviest parrot species and, with an extant population of <150, are classified as critically endangered. They are only able to survive on protected (pest and predator-free) islands and the population is actively monitored and managed by the New Zealand Department of Conservation.[1,3] This species exhibit lek breeding behaviour, and a breeding season which correlates with the sporadic (every 3-5 yr) fruiting of the native rimu tree (*Dacrydium cupressinum)* through an unknown mechanism. This makes them unsuitable for breeding in captivity. Kākāpō mothers raise their chicks exclusively on rimu fruit, which has been found to have high calcium levels.[5] There is, however, a paucity of knowledge about the complete calcium status of this species. To investigate, additional blood tests were performed on samples collected during the routine annual health checks for these birds. Blood samples were collected during winter and early spring (not in breeding season) from 33 wild, healthy adult individuals, residing on two islands. Of these 33 individuals, 27 live on Whenua Hou/Codfish Island (46°46'22.4"S 167°38'06.1"E) off the south coast of the south island of New Zealand, and six live on Hauturu-o-toi/Little Barrier Island (36°12'06.1"S 175°04'31.6"E) off the east coast of the north island. The mean (μ) and standard deviation (σ) were as follows: total calcium (μ = 2.19, σ = 0.16 mmol/l), ionised calcium (μ = 1.13, σ = 0.07 mmol/l), phosphorus (μ = 0.98, σ = 0.32 mmol/l), total protein (μ = 39.09, σ = 3.93 g/l), albumin (μ = 17.71, σ = 4.79 g/l). The ionised and total calcium levels were similar to those reported for other parrot species.[2,4] There was no significant difference in ionised calcium or total calcium levels between males or females, or between island locations. This study provides the first reported ionised calcium levels for this critically endangered parrot and important baseline data on the calcium status of healthy adult kākāpō.

Key words: Calcium, kākāpō, *Strigops habroptila*

ACKNOWLEDGMENTS

The authors would like to thank the staff at the following organisations for their support throughout this study: The New Zealand Department of Conservation (Te Papa Atawhai), especially the Kakapo Recovery Group and Kate McInnes, Auckland Zoo, New Zealand Veterinary Pathology/IDEXX and REM Systems Ltd for the loan of their laboratory equipment.

LITERATURE CITED

1. Eason DK, Elliott GP, Merton DV, Jansen PW, Harper GA, Moorhouse RJ. Breeding biology of kakapo (*Strigops habroptilus*) on offshore island sanctuaries, 1990-2002. Notornis. 2006;53:27-36.

2. Howard LL, Kass PH, Lamberski N, Wack RF. Serum concentrations of ionised calcium, vitamin D3 and parathyroid hormone in captive thick-billed parrots (*Rhynchopsitta pachyrhyncha*). J Zoo Wildl Med. 2004;147-153.

3. Jakob-Hoff R, Gartrell B. Veterinary care of kakapo. In: Miller RE, Fowler ME (eds.). Zoo and wild animal medicine, Volume 7, Current therapy. St. Louis (MO): Elsevier; 2012. p. 304-311.

4. Stanford M. Clinical pathology of hypocalcaemia in adult grey parrots (*Psittacus erithacus*). Vet Rec. 2007;456-457.

5. Von Hurst PR, Moorhouse RJ, Raubenheimer D. Preferred natural food of breeding kakapo is a high value source of calcium and vitamin D. J Steroid Biochem Mol Biol [Internet]. 2015 [cited 2015 Nov 1]. Available from doi:10.1016/j.jsbmb.2015.10.017

PLASMID-MEDIATED ANTIMICROBIAL RESISTANCE GENES IN HOUSE SPARROWS (*Passer domesticus*): A COMPARATIVE STUDY BETWEEN LIVESTOCK AND URBAN ENVIRONMENTS

Verónica Delicado, DVM, MSc (Cons. Biol.),[1,2] Fernando Esperón, DVM, PhD,[1]* Matilde Carballo, BS, PhD,[1] José Ignacio Aguirre, BS, PhD,[2] and Ana de la Torre, BS, PhD[1]

[1]Animal Health Research Center (INIA-CISA), Valdeolmos, Madrid, 28130, Spain; [2]Department of Zoology and Physical Anthropology, School of Biology, University Complutense of Madrid, Madrid, 28040, Spain

Abstract

Antimicrobial resistance is increasingly considered an emerging public health concern. In the past 70 yr, the excessive and/or misuse of drugs has led to the emergence of resistant organisms, responsible for serious diseases worldwide.[3,6] While the presence and impact of antimicrobial resistance is being widely studied in humans and domestic animals, there is a large gap related to its effects on the environment, and particularly on wildlife.[2] Recent studies suggest that the presence of antimicrobial resistance in wildlife is mainly anthropogenic, so it is expected that a correlation may exist between levels of resistance and the level of contact wildlife have with humanization.[4]

Among the mechanisms of resistance, those present in mobile elements, particularly plasmid-mediated antimicrobial resistance genes (PM-ARGs), are of major concern due to their ability to be shared between bacteria and spread resistance into the environment. Therefore, the main objective of this study is to obtain relevant information about the impact of livestock on the acquisition of PM-ARGs in synanthropic species. To achieve these goals, we selected two populations of house sparrows (*Passer domesticus*) inhabiting two different scenarios: a livestock environment (intensive sheep farm) and an urban environment without evident antimicrobial exposure. A total of 38 individuals were trapped and sampled, 17 from the sheep farm (8 in 2013 and 9 in 2015) and 21 from the urbanized area (8 in 2013 and 13 in 2015). The 16 individuals captured in 2013 were maintained in captivity (eight from each scenario) during 21 days. A common garden experiment was performed, keeping both captive populations under standardized conditions of situation, exposure and food. Besides during trapping (t_0), fecal samples were taken during days 11 (t_1) and 21 (t_2). We have selected six PM-ARGs (*sul*I, *sul*II, *qnr*S, *tet*(A), *tet*(Q) and *mec*A), detected and quantified by real-time PCR, working directly on the intestinal bacterial metagenome.

Overall, the levels of PM-ARGs found in both scenarios were considered low. These results are in concordance with previous studies in house sparrows.[5] The most frequent PM-ARGs detected in this study were *sul*I. However, two samples from the urbanized environment were positive to *mec*A gene detection, which is present in methicillin-resistant *Staphylococcus aureus* (MRSA) strains, a major concern of public health.[1] This is the first report of *mec*A in house sparrows elsewhere.

On the other hand, sparrows from the sheep farm in the experimental study (t_0) showed a higher percentage of positive individuals to *sul*II (75%) and average number of PM-ARGs per sample

(2.5) than those from urbanized areas (t_0) (0% and 0.75, respectively; P = 0.000). This highlights the importance of farming for the acquisition of PM-ARGs. As a consequence, PM-ARGs could act as indicators of the degree of exposure to livestock farms.

The most relevant result of the experiment was the reduction of the percentage of copies of the *sul*I genes and the average number of PM-ARGs per sample in farm sparrows between t_0 (8.5×10^{-2} copies of *sul*I/100 copies of 16S rRNA gene and 2.5 genes/sample, respectively) and t_2 (1.4×10^{-3} copies of *sul*I/100 copies of 16S rRNA gene and 1.4 genes/sample, respectively) (P = 0.013 and P = 0.008, respectively). Likewise, the reduction in resistance during the experimental period could be related to the lack of exposure to the farming environment until basal levels of resistance were reached.

This is the first study of antimicrobial resistance genes, analyzing directly the digestive metagenome of wildlife. Results have shown the impact of livestock on the presence of antimicrobial resistance genes and how it decreases after exposure disappears; however, it is of great importance to perform future studies in other productive frameworks (e.g., poultry, swine), as well as to evaluate the consequences of these antimicrobial resistance genes on the diversity and abundance of the digestive microbiota and thus, their possible effects over host fitness.

Key words: Antimicrobial resistance genes, house sparrow, *mec*A, *Ovis orientalis*, *Passer domesticus*, sheep

ACKNOWLEDGMENTS

This work has been co-funded by the projects CAM S2013/ABI-2747 and RTA2014-00012-C03-02. The authors want to thank Veronica Nogal and Elena Neves for their technical assistance.

LITERATURE CITED

1. Grundmann H, Aires-de-Sousa M, Boyce J, Tiemersma E. Emergence and resurgence of methicillin-resistant *Staphylococcus aureus* as a public-health threat. Lancet. 2006;368(9538):874-885.

2. Livermore DM, Warner M, Hall LM, Enne VI, Projan SJ, Dunman PM, Wooster SL, Harrison G. Antibiotic resistance in bacteria from magpies (*Pica pica*) and rabbits (*Oryctolagus cuniculus*) from west Wales. Environ Microbiol. 2001;3(10):658-661.

3. Michael CA, Dominey-Howes D, Labbate M. The antimicrobial resistance crisis: causes, consequences, and management. Front Public Health. 2014;2:145.

4. Radhouani H, Silva N, Poeta P, Torres C, Correia S, Igrejas G. Potential impact of antimicrobial resistance in wildlife, environment and human health. Front Microbiol. 2014;5:23.

5. Sacristán C, Esperón F, Herrera-León S, Iglesias I, Neves E, Nogal V, Muñoz MJ, de la Torre A. Virulence genes, antibiotic resistance and integrons in *Escherichia coli* strains isolated from synanthropic birds from Spain. Avian Pathol. 2014;43(2):172-175.

6. Sengupta S, Chattopadhyay MK, Grossart H-P. The multifaceted roles of antibiotics and antibiotic resistance in nature. Front Microbiol. 2013;4:47.

ELECTROCHEMOTHERAPY FOR THE TREATMENT OF FIBROMA IN RED-BILLED CURASSOW (*Crax blumenbachii*)

Suzana B. Hirata, DVM, MS,[1]* Carlos H. M. Brunner, DVM, PhD,[2] and Stéfanie V. Santos, DVM, PhD[3]

[1]Fundação Parque Zoológico de São Paulo, São Paulo, SP, 04301-905, Brazil; [2]Universidade Paulista UNIP, São Paulo, SP, 18465-970, Brazil; [3]A.C. Camargo Cancer Center, São Paulo, SP, 01509-010, Brazil

Abstract

The red-billed curassow (*Crax blumenbachii*) is an endangered bird belonging to the Cracidae family and was formerly widespread in east Brazil, from Bahia south through Espírito Santo and east Minas Gerais to Rio de Janeiro. The range and population are very small and severely fragmented. The species has suffered chronic habitat loss and hunting pressure. Hunting and capture for the bird trade persist in reserves and are likely to have a severe impact on such fragmented populations. A successful reintroduction programme has helped to partially offset an ongoing decline in this species.[4] A 14-yr-old male red-billed-curassow (*Crax blumenbachii*) developed a mass around the uropigial gland and presented self-mutilation in the area. The animal was immobilized, was administered 0.8 mg/kg of midazolam (Dormire® 15 mg, Cristália, São Paulo 13970-000, Brazil) intramuscularly and the patient was maintained under isoflurane (Isoflurano, BioChimico, Rio de Janeiro 27580-000, Brazil) anesthesia. The mass measured 55 × 35 × 33 mm. A biopsy was performed and the mass was histologically identified as a fibroma associated to a chronic dermatitis, characterized by dermal fibroblast proliferation multidirectional with low pleomorphism and atypia, rare typical mitosis associated to moderate collagenous stroma. Also parakeratotic hyerplasia associated with aseptic crusted lesion. Hematology and blood chemistry results were within reference range. Electrochemotherapy (ECT) represented an alternative to surgical excision as the tumor was located near the vent. ECT combines the administration of chemotherapeutic agents and the local application of sequential electric pulses,[2] that lead to electroporation of the cellular membrane of the neoplastic cells, and they facilitate the penetration of the drug, thereby increasing its pharmacologic intracellular concentration, inducing the death of cellular tumoral locally,[1,3] reducing the systemic side effects of conventional chemotherapy and the amount of common recurrence typical of neoplasms of this histogenesis when used only tumor excision, then ensuring a greater therapeutic and prognostic efficiency.[3] After anesthesia, with the same protocol used before, intralesional bleomycin (Cinaleo®, Meizler UCB Biopharma S/A, São Paulo 06455-000, Brazil) was injected at a dose of 1 U/cm³ of lesion. Electroporation was performed in the following manner: high-voltage (1,000V/cm) electric pulses were applied using an electrode composed of a grid of six stainless-steel needles placed 7.0 mm apart (BK 100®, LC Pesquisa, São Paulo 05303-000 Brazil). The electrode needle grid was moved over the surface of the mass. The macroscopic reevaluation 30 days after the first therapy session pointed partial tumor remission and presence of drying exudate in the region. Sixty days after the first treatment, a second session was performed. The tumor measured 37 × 37 × 18 mm. After 49 days the pygostyle was exposed and there were not any macroscopic signs of the tumor. The patient was immobilized and maintained under isoflurane anesthesia for evaluation and radiographic examination, during the procedure the patient had a cardiorespiratory arrest. Cardiopulmonary

resuscitation was immediately initiated, but was stopped unsuccessfully 20 min later. The histopathologic cutaneous analysis post-ECT showed: reaction granulation tissue associated to moderate congestion without atypical mesenchymal cell infiltration compatible with primary neoplasm in adjacent tissues. This is the first report in literature of electrochemotherapy in an avian patient. The complete neoplastic remission was assessed with both macro and microscopic evaluation, and might have led to exhibition of bone noticed in the last evaluation. The death is probably unrelated with the treatment performed, but future research is necessary to establish treatment protocols. Thus, the authors suggest that the ECT can be of use in avian oncology, enabling and benefitting future prognostic analyses.

Key words: Avian, *Crax blumenbachii*, electrochemotherapy, electroporation, fibroma, red-billed curassow

LITERATURE CITED

1. Larkin JO, Collins CG, Aarons S, Tangney M, Whelan M, O'Reily S, Breathnach O, Soden DM, O'Sullivan GC. Electrochemotherapy: aspects of preclinical development and early clinical experience. Ann Surg. 2007;245:469-479.

2. Lebar MA, Sersa G, Groselj A, Miklavcic D. Optimisation of pulse parameters in vitro for in vivo electrochemotherapy. Anticancer Res. 2002;3:1731-1736.

3. Sersa G, Cemazar M, Miklavcic D, Rudolf Z. Electrochemotherapy of tumours. Radiol Oncol. 2006;40:163-174.

4. The IUCN Red List of Threatened Species. Version 2015-4 [Internet]. The IUCN Red List of Threatened Species [cited 2015 Nov 3]. Available from: http://www.iucnredlist.org/details/22678544/0

PUBLIC HEALTH IMPORTANCE OF ANTIBIOTIC-RESISTANT ENTEROBACTERICEAE IN CLOACAL ISOLATIONS FROM FOUR SPECIES OF PSITTACIDAE (*Pyrrhura picta, Primolius couloni, Pionus menstruus AND Pionus chalcopterus*) KEPT IN CAPTIVITY IN LIMA, PERU

María Fernanda Jordán Romero, Bach MV,[1]* Gianmarco Rojas Moreno, MV, Esp, MSc,[1,2] Siever Morales Cauti MV,[1] and Lizzie Ortiz Cam, MVZ, Esp[2]

[1]Facultad de Medicina Veterinaria y Zootecnia, Universidad Científica del Sur; [2] Zoo Huachipa Park, Lima, Peru

Abstract

Psittacidae are the most affected family in illegal trade. Thousands of them are reported every year as ornamental birds having close contact with humans, thus becoming potential agents of zoonotic diseases as the majority of them are immunosuppressed because of poor captive conditions. The principal cause of zoonotic diseases under this circumstance is the Enterobacteriaceae family, as this group has an enormous infection capacity. The aim of this study is to determine the public health importance of Enterobacteriaceae with antibiotic resistance in cloacal isolations in four species of Psittacidae (*Pyrrhura picta, Primolius couloni, Pionus menstruus* and *Pionus chalcopterus*) kept in captivity in Lima, Perú. Samples were taken of apparently healthy individuals. Results indicated that 48.5% (18/35) were Enterobactericeae positive and 82.4% (14/18) of them were *Primolius couloni*. The Enterobacteriaceae found were: *E. coli* 27.78% (5/18), *Providence* 22.22% (4/18) *Enterobacter* 22.22 % (4/18), *Klebsiella* 22.22% (4/18), *Citrobacter* 5.88% (1/18), *Salmonella* 0% (0/35). Also, these Enterobactericeae were processed to identify antibiotic resistance and the results were: penicillin 100% (11/11), amikacin 27.27 % (3/11), ceftiofur 18.18% (2/11), ciprofloxacine 9.09 % (1/11), tetracycline 36.36% (4/11), gentamicin 9.09% (1/11), chloramphenicol 9.09% (1/11), cefuroxime 9.09% (1/11), nalidixic acid 0% (0/11), oxytetracycline 9.09% (1/11), enrofloxacin 45.45 % (5/11). The results of this study show that the presence of Enterobactericeae with antibiotic resistance is of public health importance.

Key words: Enterobactericeae, *Pionus chalcopterus*, *Pionus menstruus*, *Primolius couloni*, *Pyrrhura picta*

ACKNOWLEDGMENTS

The authors would like to thank all the staff of Huachipa Zoological Park and Microbiology Laboratory of Universidad Científica del Sur.

LITERATURE CITED

1. Bowman T.A ando Jacobson E.R. Cloacal flora of Clinically normal captive Psittacine birds. J. Zoo Anim Med. 1980;11:81-85.

2. Rojas M. J, Garcia M, Rejo T, Masdeu V y Acosta I. Hallazgo bacteriológico y micológico en aves psitácidas. Rev Cubana de Ciencia Avícola, 2002;26:125-128.

3. Wanderley H, Hidasi J, Cardoso M, Coelho G, Sá Jayme V and Auxiliadora M. Enterobacterial detection and

Escherichia coli antimicrobial resistance in parrots seized from the illegal wildlife trade. J Zoo Wildl Med. 2013; 44(1):1-7.

EVALUATING A TRICHOMONAS RAPID TEST IN PIGEONS (*Columbia livia f. domestica*) AND BUDGERIGARS (*Melopsittacus undulatus*)

H. Kempf, DVM,[1]* F. Benaglia, Dr,[2] and S. Oefner, DVM[3]

[1]Tieraerztliche Praxis für Exoten, Neuburger Str. 30, 86167 Augsburg, Germany; [2]Mediterraneo Park, Tul il-Kosta, Bahar ic-Caghaq, NXR 9038, Malta; [3]Auffangstation fuer Reptilien, Kaulbachstr. 37, 80539 Muenchen, Germany

Abstract

Trichomonas spp. are common parasites in the crop of many bird species.[2,3] Diagnostis is traditionally accomplished by microscopic evaluation of fresh crop swaps or washings. Especially under field conditions access to a microscope is not always available; therefore, new rapid human tests[1,4] seem to be a helpful alternative. This study evaluates the OSOM® Trichomonas Rapid Test[a] in pigeons (*Columbia livia f. domestica*) and budgerigars (*Melopsittacus undulatus*). The infection rate was pre-evaluated with a microscopic diagnostic of a fresh crop swab: 0-2 *Trichomonas* per field as low infected, 3-10 *Trichomonas* mild infected and 10-30 *Trichomonas* per field as highly infected. For birds with high amounts of *Trichomonas* spp. we showed that the rapid test works well, even after storing the swab for 24 hr in a refrigerator. In animals with a low infection rate the results were not reliable. The test is recommended in evaluating the health status of big flocks.

[a]Sekisui Virotech GmbH, Ruesselsheim, Germany

Key words: *Columbia livia*, *Melopsittacus undulatus*, rapid test, *Trichomonas* spp.

LITERATURE CITED

1. Alonzo T, Pepe M. Using a combination of reference test to assess the accuracy of a new diagnostic test, statistics in medicine. Stat Med. 1999;18(22):2987-3003.

2. McKeon T, Dunsmore J, Raidal SR. Trichomonas gallinae in budgerigars and columbid birds in Perth, Western Australia. Aust Vet J. 1997;75(9):652-655.

3. Narcisi EM, Sevoian M, Honigberg BM. Pathologic changes in pigeons infected with a virulent *Trichomonas gallinae* strain (Eiberg). Avian Dis. 1990;35(1):55-61.

4. Ohlemeyer C, Homberger L, Lynch D, Swierkosz E. Diagnosis of *Trichomonas vaginalis* in adolescent females: InPouch™ TV Culture versus wet-mount microscopy. J Adolesc Health. 1998;22:205-208.

NEWCASTLE VACCINE IN SOUTHERN GROUND-HORNBILLS (*Bucorvus leadbeateri*): A TOOL TO REDUCE MORTALITY IN REINTRODUCTION STOCK

Katja N. Koeppel, Dr Med Vet, BVMS, MSc, CertZooMed, Dipl ECZM (ZHM),[1]* Lucy Kemp, MSc,[2] and Louis Maartens[3]

[1]Wildlife Health, Department of Production Animal, Faculty of Veterinary Science, University of Pretoria, South Africa; [2]Mabula Ground Hornbill Project, Bela-Bela, Limpopo, South Africa; [3]Research and Development Section, Deltamune Pty. Ltd., Lyttelton, 0140, South Africa

Abstract

Newcastle disease (NCD) is highly contagious viral disease to both domestic and wild avian species. It was first reported for South Africa in 1944[4] and recent years (2000 to 2011) have seen, on average, 0.32 outbreaks per 1000 head of poultry reported to the World Organization of Animal Health (OIE).[3] In 2006 a Southern ground-hornbill (*Bucorvus leadbeateri*), part of a conservation reintroduction programme, died of NCD after 113 days at liberty in Mpumalanga province. A second bird from the same release site died within 16 days of the first, presumably of the same aetiology.[1] The reintroduction stock are all hand-reared and appear to have no natural immunity against the virus. In an attempt to prevent further losses, a NCD vaccination program was implemented. Initially, the birds were immunized by administering a live attenuated primer (Ulster strain) in the conjunctiva, followed by an inactivated booster (Struvac**,** Deltamune Pty Ltd) inoculated 4 wk later by the subcutaneous route. Circulating antibodies were demonstrated 4 wk post vaccination, but the levels gradually waned and dropped below the detection threshold after 3 yr, despite annual subcutaneous boosters with the inactivated product. Subsequent trials showed that the humoral responses could be improved, without noticeable side effects, by administering high concentrations of the live attenuated vaccine orally, and by administering the booster vaccine intramuscularly. To date none of the vaccinated released birds have contracted NCD despite repeated outbreaks in January 2012 and July 2011 within Mpumalanga province in wild doves and pigeons.[3]

Key words: *Bucorvus leadbeateri*, Newcastle disease, Southern ground-hornbill, vaccine

ACKNOWLEDGMENTS

We would like to thank Deltamune for their continuous support without which the vaccine protocol could not have been developed. We would like to thanks Montecasino Bird Gardens, Johannesburg Zoo, National Zoological Gardens and Delecia Gunn for their dedication to the project.

LITERATURE CITED

1. Abolnik C, Gerdes GH, Kitching J, Swanepoel S, Romito M. Characterization of pigeon paramyxoviruses (Newcastle disease virus) isolated in South Africa from 2001 to 2006. Onderstepoort J Vet Res. 2008;75:147-152.

2. Department of Agriculture, Forestry & fisheries, Republic of South Africa [Internet]. Disease reporting; c2016 [cited 2015 Nov 29]. Available from http://www.daff.gov.za/daffweb3/Branches/Agricultural-Production-Health-Food-Safety/Animal-Health/Epidemiology/disease-reporting. Accessed 29.11.2015

3. Gardner EG, Alders R. Livestock risks and opportunities: Newcastle disease and avian influenza in Africa. Planet@Risk. 2014;2(4):208-211.

4. Kaschula V, Canham A, Diesel A, Coles J. Newcastle diease in Natal. J S Afr Vet Assoc. 1945;17:1-14.

CHLAMYDIACEAE IN FREE-RANGING HAWKS (*Buteo* sp.) IN NORTHERN CALIFORNIA

Charlene Luján-Vega, Med Vet., MS,[1]* Michelle G. Hawkins, VMD, Dipl ABVP (Avian),[1] Christine Kreuder Johnson, VMD, PhD,[1] Christopher Briggs, MS, PhD,[2] Chris Vennum, BS,[3] Peter Bloom, MS, PhD,[4] Joshua M. Hull, MS, PhD,[5] Carolyn Cray, PhD,[6] Denise Pesti, MS,[7] Bernard Wolff, MS,[7] Paula Ciembor, DVM, PhD,[7] and Branson W. Ritchie, DVM, PhD, Dipl ABVP (Avian) Dipl ECZM (Avian)[7]

[1]Department of Medicine and Epidemiology, School of Veterinary Medicine, University of California, Davis, CA 95616 USA; [2]Golden Gate Raptor Observatory, San Francisco, CA 94123 USA; [3]Biology Department, University of Nevada Reno, Reno, NV 89503 USA; [4]Bloom Biological, Inc., Santa Ana, CA 92705 USA; [5]Department of Animal Science, University of California, Davis, CA 95616 USA, [6]Avian and Wildlife Laboratory, University of Miami, Miami, FL 33136 USA, [7]Infectious Diseases Laboratory, University of Georgia, Athens, GA 30602 USA

Abstract

Chlamydiaceae have a wide range of vertebrate hosts and studies in raptors indicate a large range in estimated prevalence.[1,2] The objective of this study was to estimate the prevalence of *Chlamydia* sp. in free-ranging hawks (*Buteo* sp.) in Northern California. A total of 297 free-ranging *Buteo* sp. were sampled for multi-mucosal swabs and whole blood; however, not all had all samples. Conjunctiva, choana and cloaca were sampled with a single swab for qPCR analysis. Positive samples were sequenced based on the ompA gene and compared by high resolution melt analysis to all known *C. psittaci* strains (A-G, E/B, M56, WC), and *C. pneumoniae*. Plasma aliquots were sent to reference laboratories to perform serology for IgM using the elementary body agglutination test (EBA; n = 78) and for IgY using the indirect immunofluorescent assay (IFA; n = 51). The overall prevalence of Chlamydiaceae in free-ranging *Buteo* species sampled in nine counties of Northern California was 1.37% (4/291) via qPCR analysis of multi-mucosal site swabs. An atypical chlamydial organism was detected by qPCR in red-tailed hawks (*Buteo jamaicensis*) and Swainson's hawks (*Buteo swainsoni*) which was most similar to the mammalian *C. psittaci* strain M56. None of the samples were positive for either serologic test. Due to the lack of antibody titers detected in any sample, it is possible that this chlamydial sequence was from a mammalian prey item passing through the gastrointestinal tract of sampled birds. Further studies will be required to identify this organism and its health impact in wild *Buteo* populations in Northern California.

Key words: *Buteo* sp., Chlamydiaceae, EBA, IFA, Northern California, qPCR

ACKNOWLEDGMENTS

We thank Laura Young, Joe Papp and all the volunteers of the Golden Gate Raptor Observatory for the help in the field. This study was supported by the Phil and Karen Drayer Wildlife Health Center Fellowship Award, School of Veterinary Medicine, University of California, Davis and by the Wild Animal Health Fund from the Association of American and Zoo Veterinarians. We also thank the Programa Nacional de Becas y Crédito Educativo of the Ministry of Education, Peruvian Government for providing the fellowship Beca Presidente de la República for the master studies of Dr. Luján-Vega.

LITERATURE CITED

1. Blomqvist M, Christerson L, Waldenstrom J, Lindberg P, Helander B, Gunnarsson G, Herrmann B, Olsen B. *Chlamydia psittaci* in birds of prey, Sweden. Infect Ecol Epidemiol. 2012;2:8435.

2. Ortega N, Apaza D, Gonzalez F, Salinas J, Caro MR. Occurrence of Chlamydiaceae in non-symptomatic free-living raptors in Spain. Eur J Wildlife Res. 2012;58:351-355.

SERUM BIOCHEMICAL AND HEMATOLOGIC VALUES FROM ALCIDS: A 17-YEAR RETROSPECTIVE STUDY IN THE OCEANÁRIO DE LISBOA, PORTUGAL

Nuno Pereira, DVM,[1]* Salomé Gonçalves, DVM,[2] Bruno Baptista, DVM,[2] Pedro Serra, DVM,[3] Hugo David, DVM,[4] Iara Nogueira, Vet Student,[5] and Núria Baylina, BMarSc[1]

[1]Oceanário de Lisboa, Lisboa 1990-005, Portugal; [2]Faculdade de Medicina Veterinária, Universidade de Lisboa, Lisboa 1300-499 Portugal; [3]National Veterinary Services Ltd, Lancashire FY6 7LJ, UK; [4]Vetset-Hospital Veterinário, Palmela 2950-298, Portugal; [5]Universidade Federal de Minas Gerais, Belo Horizonte MG, 31250-810, Brasil

Abstract

Within the scope of the health control program at Oceanário de Lisboa, blood was drawn from alcids in the collection to evaluate hemogram and serum biochemical parameters. For the purpose of these study only values from birds without signs of disease were included. Three alcid species were sampled: razorbill (*Alca torda;* n = 14), 75 samples; common murre (*Uria aalge* n = 14), 95 samples; and Atlantic puffin (*Fratercula arctica* n = 26), 124 samples. Blood collection was performed regularly from 1998 to 2015. Hemogram (white blood cell count; red blood cells; haematocrit; haemoglobin; thrombocytes; differential count: heterophils, lymphocytes, monocytes and eosinophils and basophils) analysis was performed from EDTA blood samples in the same laboratory. Serum samples were analysed in-house using an IDEXX VetTest^{TM} for aspartate aminotransferase (AST), lactic dehydrogenase (LDH) creatine kinase (CK), uric acid (UA), total protein (TP), albumin (Alb) and globulin (Glob). Each parameter of the collected data (1998-2015) was processed for the average, median, standard deviation, the maximum and minimum values.

Results of average values for razorbills were: WBC 14.1 (x 10^3 cells/µl); RBC 4.4 (x 10^3 cells/µl); hematocrit 45.3 (%); hemoglobin 15.4 (g/dl); thrombocytes 51.8 (x 10^3 cells/µl); AST 241.1 (UI/l); LDH 1623.3 (UI/l); CK 158.9 (UI/l); UA 12.1 (mg/dl); TP 4.2 (g/dl); Alb 1.6 (g/dl); Glob 2.6 (g/dl). Average values for common murre were: WBC 7.4 (x 10^3 cells/µl); RBC 8.7 (x 10^3 cells/µl); hematocrit 45.3 (%); hemoglobin 34.0 (g/dl); thrombocytes 54.1 (x 10^3 cells/µl); AST 49.4 (UI/l); LDH 1867.5 (UI/l); CK 272.8 (UI/l); UA 8.6 (mg/dl); TP 4.3 (g/dl); Alb 1.6 (g/dl); Glob 2.7 (g/dl). Average values for Atlantic puffins were: WBC 11.9 (x 10^3 cells/µl); RBC 2.6 (x 10^3 cells/µl); hematocrit 45.8 (%); hemoglobin 15.7 (g/dl); thrombocytes 76.9 (x 10^3 cells/µl); AST 137.6 (UI/l); LDH 1122.2 (UI/l); CK 284.3 (UI/l); UA 12.0 (mg/dl); TP 4.2 (g/dl); Alb 1.4 (g/dl); Glob 2.8 (g/dl). Obtained data provides useful baseline information to evaluate the health of our alcid collection. Due to the scarcity of available information regarding blood values in captive alcids and this study's substantial sample size, our results will significantly contribute to our understanding and characterization of the blood values of these three alcid species.

Key words: *Alca torda*, blood values, *Fratercula arctica*, hemogram, serum biochemical values, *Uria aalge*

ACKNOWLEDGMENTS

The authors thank the staff at Oceanário de Lisboa for the work and dedication which made this study possible.

CARDIOLOGY IN THE IBIS: CARDIAC TROPONIN I, ECHOCARDIOLOGY, AND POST-MORTEM LESIONS

Kathryn L. Perrin, BVetMed,[1]* Michael M. Garner, DVM, Dipl ACVP,[2] Mark F. Stidworthy, MA, VetMB, PhD, FRCPath,[3] Rebecca Langhorn, DVM, PhD, [4]Jakob L. Willesen, DVM, PhD,[4] Jørgen Koch, DVM, PhD,[4] and Mads F. Bertelsen, DVM, DVSc, Dipl ACZM, Dipl ECZM (Zoo Health Management)[1]

[1]Center for Zoo and Wild Animal Health, Copenhagen Zoo, Frederiksberg, 2000, Denmark; [2]NorthWest ZooPath, Monroe, WA 98272 USA; [3]International Zoo Veterinary Group Pathology, Keighley, BD21 4NQ, United Kingdom; [4]Department of Veterinary Clinical and Animal Sciences, Faculty of Health and Medical Sciences, University of Copenhagen, Frederiksberg, DK-1870, Denmark

Abstract

A retrospective review of ibis disease at the Copenhagen Zoo, Denmark, followed by a wider pathology review of approximately 440 records from two specialist zoo pathology services representing zoo-captive cases from both Europe and North America identified cardiovascular lesions as a substantial cause of morbidity and mortality. Common cardiac lesions included endocarditis (especially vegetative valvular endocarditis), myocarditis, and myocardial degeneration and fibrosis. Atherosclerosis appeared to be more frequently diagnosed in Europe than in North America but this may be related to a higher proportion of necropsies being performed by specialist pathologists in the European data set. Clinical histories rarely recognised cardiovascular disease prior to death, leading to considerations for ante-mortem screening for cardiac pathology. To address this all scarlet ibis (*Eudocimus ruber*) housed at the Copenhagen Zoo (22 male, 22 female) were manually restrained for physical exam, echocardiography, and blood sampling for cardiac troponin I (cTnI) and serum cholesterol measurements. Echocardiographic reference intervals were established for this species using an established transcoelomic avian protocol.[1] Seven individuals were hypercholesterolemic;[2] however, only two of these animals had elevated aortic outflow velocities suggesting stenosis. Three animals had markedly increased concentrations of cTnI (>1.4 ng/ml) which may indicate myocardial injury. No vegetative lesions were identified in this screen. In conclusion preliminary reference values have been established for echocardiography and cTnI concentrations in the scarlet ibis. Particular attention should be paid to the heart and major blood vessels during necropsy examination of ibis species.

Key words: Atherosclerosis, cardiac troponin, echocardiography, *Eudocimus ruber*, ibis, vegetative endocarditis

ACKNOWLEDGMENTS

The authors would like to thank Futte, Ellen, Martin and Mette from the Copenhagen Zoo for their cooperation and patience during this project, as well as the many zoos which have contributed pathological data. The authors also thank Liz Post and Cathy Minogue from Northwest ZooPath for data retrieval.

LITERATURE CITED

1. Krautwald-Junghanns ME, Shulz M, Hagner D, Failing K, Redman T. Transcoelomic two-dimensional echocardiography in the avian patient. J Avian Med Surg. 1995;9:19-31.

2. International Species Inventory System. Physiological data reference values. [CD-ROM] Apple Valley (MN): International Species Inventory System; c2013.

PROVENTRICULAR DISEASE IN THE LITTLE PENGUIN (*Eudyptula minor novaehollandiae*)

Gabrielle Tobias, BVSc, Dipl Vet Clin Stud, MAppSc,[1]* Lydia Tong, DVM,[1] Kimberly Vinette Herrin, MS DVM,[1] Larry Vogelnest, BVSc, MVS, MACVSc,[1] Frances Hulst, BVSc, MVS,[1] Cheryl Sangster, DVM, Dipl ACVP,[1] and Laetitia Volait, DVM, ECZM Resident[2]

[1]Taronga Zoo, Sydney, 2088, NSW, Australia; [2]Ecole Nationale Vétérinaire d'Alfort, France

Abstract

A recent cluster of proventriculopathy was identified at necropsy in three little penguins (*Eudyptula minor novaehollandiae*). Pathology ranged from proventriculitis in one penguin, proventricular carcinoma *in situ* in the second penguin and obstructive adenocarcinoma with metastasis to the coelom in the third penguin.

A historical review of little penguin necropsy findings identified cases of proventriculopathy in captive and wild populations and compared the incidence of proventriculopathy. Between 1998-2015, 6/372 (1.6%) wild penguins versus 5/79 (6.3%) captive penguins had proventriculitis. Four captive penguins had carcinomas [one proventricular carcinoma in-situ (1.3%), three proventricular adenocarcinoma (3.8%)]. Neoplasia was not identified in any wild penguins.

Affected penguins were 7-8 yr old at time of death. Clinical signs included regurgitation, anorexia, and weight loss. Some cases of proventriculitis were identified as incidental findings in animals that died of other causes. Proventricular changes were most common at the oesophageal-proventricular sphincter or the proventricular/ventricular junction. Similarly, inflammatory changes were found within the oesophagus and ventriculus. Gross findings included thickening, ulceration and necrosis. Histopathologic changes included mucosal hypertrophy, multifocal lymphocytic-plasmocytic to heterophilic infiltration and necrosis. Changes were acute, chronic-active and chronic. Neoplastic lesions were expansile, papillomatous, non-encapsulated, poorly circumscribed, and multilobular. Two of three adenocarcinoma cases had evidence of metastasis, and one case had coelomitis secondary to perforation.

There appears to be a spectrum of disease, as demonstrated in the three captive penguins, starting with chronic inflammation and leading to neoplastic transformation. An etiology or predisposing factors were not identified and further investigation is required.

There are only two previous reports of proventricular adenocarcinoma in penguins.[1,2]

Key words: *Eudyptula minor novaehollandiae,* little penguin, proventricular adenocarcinoma, proventriculitis

ACKNOWLEDGMENTS

The authors would like to thank the Michelle Shaw, Nutritionist Taronga Zoo, the Australian Registry of Wildlife Health and the Taronga Zoo marine mammal keepers for their assistance in the care of these birds.

LITERATURE CITED

1. Cho KO, Kimura T, Ochiai K, Itakura C. Gizzard adenocarcinoma in an aged Humboldt penguin (*Spheniscus humboldti*). Avian Pathol.1998;27:100-102.

2. Yonemaru K, Sakai H, Asaoka Y, Yanai T, Fukushi H, Watanabe K, Hirai K, Masegi T. Proventricular adenocarcinoma in a Humboldt penguin (*Spheniscus humboldti*) and a great horned owl (*Bubo virginianus)*; identification of origin by mucin histochemistry. Avian Pathol. 2004;33(1):77-81.

SIGNIFICANCE OF CAUSES OF ADMISSION OF NORTH AMERICAN OSPREY (*Pandion haliaetus*) TO A SOUTH CAROLINA AND A FLORIDA RESCUE CENTER

Anna Vecchione, DVM, PhD,[1]* Debbie Mauney,[2] Renata Schneider, DVM,[3] and Antonia Gardner, DVM[3]

[1]Sea Life Conservation and Arts, Charleston, SC 29414 USA; [2]Avian Conservation Center and The Center for Birds of Prey, Awendaw, SC 29429 USA; [3]South Florida Wildlife Center, Fort Lauderdale, FL 33315 USA

Abstract

The North American osprey (*Pandion haliaetus*; Pandionidae) is a bird of prey that feeds mainly on fish and is considered an important sentinel species for environmental changes.[1,2] As South Carolina and Florida continue to undergo rapid urbanization, the use of osprey as a bio-monitor in these regions has been suggested to be valuable. Wildlife rescue centers can provide data which offer insight into human activities that negatively impact osprey health. Retrospective data from two wildlife rescue centers were reviewed and categorized based on clinical findings at the time of admission. Causes for osprey admission to the South Florida Wildlife Center (SFWC), FL (2009-2014, n = 140) and the Avian Conservation Center (ACC), SC (2009-2012, n = 107) were evaluated. The majority of the cases from SFWC presented with unknown illness 58% (81/140) and trauma 36% (50/140). Causes for admission included: fractures 16% (23/140), emaciation 6% (9/140), gunshots 4% (5/140), and 16% (22/140) had wounds possibly due to interaction between species. Causes for osprey admission at the ACC also showed trauma 47% (57/107) to be the primary finding at admission. Other causes of admission included: collision/suspected collision 28% (30/107), entanglement 9% (10/107), emaciation 7% (8/107), and gunshot 6% (7/107). From 2009-2012 the Avian Conservation Center and the South Florida Wildlife Center, successfully treated and released 28% (30/107) and 26% (24/89) of ospreys admitted to their facilities respectively. This report provides helpful data for future research on osprey health in these regions and highlighted the need to develop standard methods of data collection to evaluate osprey health.

Key words: Osprey, *Pandion haliaetus*, wildlife rehabilitation

ACKNOWLEDGMENTS

The first author would like to thank Thomas Quintel, Dr. Laila Attar, and Rita Dorio for their assistance. Project funding was provided by Sea Life Conservation and Arts. There are no conflicts of interest in this paper.

LITERATURE CITED

1. Grove RA, Henny CJ, Kaiser JL. Osprey: worldwide sentinel species for assessing and monitoring environmental contamination in rivers, lakes, reservoirs, and estuaries. J Toxicol Environ Health Part B 2009;12:25-44.

2. Henny CJ, Grove RA, Kaiser JL, Johnson BL. North American osprey populations and contaminants: historic and contemporary perspectives. J Toxicol Environ Health Part B. 2010;13:579-603.

PHARMACOKINETIC EVALUATION OF A LONG-ACTING FENTANYL SOLUTION AFTER TRANSDERMAL ADMINISTRATION IN HELMETED GUINEAFOWL (*Numida meleagris*)

Lynnette Waugh, DVM,[1]* Heather Knych, DVM, MS, PhD, Dipl ACVCP,[2] Gretchen Cole, DVM, Dipl ACZM, Dipl ECZM (ZHM),[1] and Jennifer D'Agostino, DVM, Dipl ACZM[1]

[1]Oklahoma City Zoo, Oklahoma City, OK 73111 USA; [2]KL Maddy Equine Analytical Chemistry Laboratory, School of Veterinary Medicine, University of California, Davis, CA 95616 USA

Abstract

A new transdermal opiate solution may offer better long term pain management for avian species.[a] A single topical application provides up to 4 days of sustained analgesia in dogs without using a patch or administering subsequent oral doses. This study sought to evaluate its use in helmeted guineafowl (*Numida meleagris*). Twenty-one guineafowl received a single administration of 5 mg/kg of fentanyl transdermal solution to the interscapular skin. No adverse effects were appreciated. Plasma fentanyl concentrations were determined by liquid-chromatography-mass spectrometry analysis of protein-precipitated samples. Mean maximum plasma concentration was 228.8 ng/ml at 4 hr. The mean plasma terminal half life was 33.2 hr. At 168 hr the mean plasma concentration was 1.3 ng/ml. The target plasma concentration for analgesia in helmeted guineafowl or any avian species is unknown. In the current study, mean plasma concentration exceeded the analgesic concentration in dogs at the first time point, 2 hr post administration, and remained above this concentration for the entire study.[1-3] Transdermal fentanyl solution may be superior to fentanyl transdermal patches in birds because of reduced handling, no need for patch removal, and elimination of the possibility that a dislodged fentanyl patch could become accessible to public or other animals. A single topical dose of 5 mg/kg appears to be safe for use in this species and maintained plasma concentrations above those reported to be analgesic in dogs for at least seven days. Transdermal application of fentanyl solution may provide a non-invasive option for long-acting analgesia in birds.

[a]Recuvyra™ transdermal fentanyl solution, Nexcyon Pharmaceuticals, Inc, Madison, WI 53703 USA

Key words: Analgesia, avian, fentanyl solution, guineafowl, *Numida meleagris*, Recuvyra™

ACKNOWLEDGMENTS

The authors would like to thank the staff of the Oklahoma City Zoo for their assistance in sample collection, sample handling, and care of the birds. The authors are grateful to the Oklahoma City Zoo for financial support of resident research.

LITERATURE CITED

1. Gilberto DB, Motzel SL, Das SR. Postoperative pain management using fentanyl patches in dogs. Contemp Top Lab Anim Sci. 2003:42;21-26.

2. Kyles AE, Hardie EM, Hansen BD, Papich MG. Comparison of transdermal fentanyl and intramuscular oxymorphone on post-operative behavior after ovariohysterectomy in dogs. Res Vet Sci. 1998;65:245-251.

3. Robinson TM, Kruse-Elliott KT, Marked MD, Pluhar EG, Massa K, Bjorling DE. A comparison of transdermal fentanyl versus epidural morphine for analgesia in dogs undergoing orthopedic surgery. J Am Anim Hosp Assoc. 1999;35:95-100.

HIGH-DOSE COMBINED CHELATION THERAPY AND CARDIAC EVALUATION IN A BALD EAGLE (*Haliaeetus leucocephalus*) WITH ACUTE HIGH LEAD TOXICITY

Ernesto Domínguez-Villegas, DVM,* Irene Galan-Lecona, DVM, Michelle Willette, DVM, MPH, Dipl ACVPM, Kathleen MacAulay, DVM, and Patrick Redig, DVM, PhD

The Raptor Center, College of Veterinary Medicine-University of Minnesota, St. Paul, MN 55108 USA

Abstract

Lead toxicity from ingestion of spent lead ammunition is a persistent threat to scavenger species, including bald eagles (*Haliaeetus leucocephalus*).[2,3] A male, hatch year bald eagle was presented with low body condition, a heart murmur, clinical signs of lead toxicity, numerous small metal opacities in proventriculus and ventriculus, and elevated plasma lead levels (3.94 ppm). Combined chelation therapy was initiated with calcium disodium salt of ethylene diaminetetraacetic acid (CaEDTA) @100 mg/kg diluted in 60 ml 0.9% saline subcutaneously q12hr, in combination with meso-2,3-dimercaptosuccinic acid (DMSA) @20 mg/kg orally q12hr, for 5 days. Chelation therapy regimens for treatment of lead toxicity in raptors vary widely; the regimen reported here represents a significant departure from the published literature.[4,8] Multiple treatment methods were utilized, including gastric lavage to remove ingested lead particles. Serial rounds of chelation were required to reduce plasma lead levels to the target of <0.2ppm.

Even with treatment, the rehabilitation and release rate for bald eagles with lead poisoning is extremely low owing to irreversible damage to multiple body systems, including the cardiovascular system.[4-7,9] Necropsies of lead poisoned bald eagles that failed to achieve standard endurance parameters during reconditioning,[1] showed degeneration of myocardial arteries and myocardial fibrosis in 43% of submitted cases; less commonly, pericardial effusion and ventricular dilation were noted.[5] In the reported case, cardiac function was assessed via radiographs of the cardiac silhouette, electrocardiography, and trans-esophageal echocardiography. This functional assessment was compared with normal values generated using bald eagles with no history of clinical lead poisoning.[5]

Key words: Bald eagle, cardiac evaluation, chelation therapy, *Haliaeetus leucocephalus*, lead toxicity

ACKNOWLEDGMENTS

The authors would like to thank all the staff of The Raptor Center and the cardiology service of the Veterinary Medical Center of the College of Veterinary Medicine, University of Minnesota.

LITERATURE CITED

1. Chaplin SB, Mueller LR, Degernes LA. Physiological assessment of rehabilitated raptors prior to release. In: Raptor Biomedicine. Minneapolis (MN): University of Minnesota Press; 1993. p. 167-173.

2. Cruz-Martinez L, Redig P, Deen J. Lead from spent ammunition: a source of exposure and poisoning in bald eagles. Human-Wildlife Interactions. 2012;6(1):94-104.

3. Franson JC, Russell RE. Lead and eagles: demographic and pathological characteristics of poisoning, and exposure levels associated with other causes of mortality. Ecotoxicology. 2014;23(9):1722-1731.

4. Hawkins MG, Barron HW. Birds. In: Carpenter, JW. Exotic animal formulary. 4th ed. St. Louis (MO): Elsevier; 2012: 293-295.

5. Lecona IG, Barncord K, Stauthammer C. Cardiac evaluation in the bald eagle (*Haliaeetus leucocephalus*). Proc Assoc Avian Vet; 2015.

6. Nicolas de Francisco O, Feeney D, Armien AG, Redig PT. Magnetic resonance imaging (MRI) for localizing lead-induced CNS lesions in bald eagles. Proc Assoc Avian Vet; 2010.

7. Pattee OH, Wiemeyer SN, Mulhern BM, Sileo L, Carpenter JW. Experimental leadshot poisoning in bald eagles. J Wildl Manage. 1981;45(3):806-810.

8. Redig P, Arent L. Raptor toxicology. Vet Clin Exot Anim. 2008;11:261-282.

9. Sileo L, Jones RN, Hatch RC. The effect of ingested lead shot on the electrocardiogram of Canada geese. Avian Dis. 1973;17(2)308-313.

FEMINIZING ADRENAL TUMOR IN A MALE LION (*Panthera leo*)

Alice Andolfatto, DVM,[1]* Giuliano Ravasio, DVM, PhD,[2] Maurizio Longo, DVM,[2] Donatella De Zani, DVM, PhD,[2] Vanessa Rabbogliatti, DVM,[2] Alessia Giordano, DVM, PhD,[2] Saverio Paltrinieri, DVM, PhD,[2] William Magnone, DVM,[3] Paola Roccabianca, DVM, PhD, Dipl ECVP,[2] and Davide Danilo Zani, DVM, PhD[2]

[1]Parco Safari delle Langhe, Murazzano (CN), Italy; [2]Department of Veterinary Sciences and Public Health (DIVET), Azienda Polo Veterinario di Lodi, Università degli Studi di Milano, Lodi (LO), Italy; [3]Parco Natura Viva, Bussolengo (VR), Italy

Abstract

A captive-born, intact male, 8-yr-old *Panthera leo* presented a diffuse lack of secondary sex characteristics with mane loss and testicular hypotrophy, alopecia, dysorexia, swollen abdomen and weight loss (approximately 50 kg over 2 mo). The patient was anaesthetized to undergo general clinical evaluation, hematologic, serum biochemical and hormonal profile, and FIV/FeLV tests. Three months later a total body computed tomography, abdominal ultrasonography and fine needle aspirates of the liver and left adrenal lesion were performed. Imaging findings showed the presence of a neoplastic lesion on the left adrenal gland with right adrenal gland atrophy and a generalized hepatopathy. Blood tests reported an estradiol concentration of 462 ng/dl, markedly higher in comparison to other species of animals, in particular great cats. The approach to remove the left adrenal gland tumor was a robot-assisted minimally invasive surgery. Histopathology performed after the surgery confirmed the presumed diagnosis of adrenal tumor; a large nodular lesion replaced the normal adrenal architecture, compatible with an adrenocortical carcinoma. Studies concerning this neoplasia indicate that clinical signs have a high variability. To the author's knowledge, no peer-reviewed description of a functional secreting adrenal adenoma in a lion, causing feminization, has ever been published before. The overproduction of sex hormones rather than cortisol from hyperadrenocorticism is reported to be very common in ferrets, in which adrenocortical adenomas account for 15-65% of the cases.[5] Other authors reported the association between pathologic and tomographic findings of adrenal neoplasms in 17 dogs.[3] Contrary to malignant tumours, adrenal adenomas seem to be more circumscribed with defined margins, because they usually display a pseudo-capsule around the nodular lesion, with peripheral contrast enhancement and absence of adjacent vascular invasion, as in our case. Functional adrenal tumours are common in dogs and rare in cats.[1,4] These neoplasms in feline patients can be diagnosed as adenocarcinomas (50%) or adrenocortical adenomas (50%).[4] The majority of these tumours induce an overproduction of adrenal hormones alone or in combination, such as glucocorticoids, mineralocorticoids (aldosterone) or sex hormones (estradiol, testosterone, progesterone):[4] in our case in fact we detected an overproduction of estradiol. Adrenal adenomas can be occasionally observed in asymptomatic patients during tomographic studies while estrogen-secreting tumours have been rarely reported. In humans, feminizing adrenal tumours are rare, prevailing in males with clinical signs of gynecomastia and hypogonadism:[2] we observed hypogonadism, too. To date, the patient is fully recovered, putting on weight and again has secondary sex characteristics.

Key words: Estradiol, estrogen-secreting tumour, feminizing adrenal tumour, lion, *Panthera leo*

ACKNOWLEDGMENTS

The authors would like to thank Sofar for the use of Telelap ALF-X for surgery, the staff of Parco Safari delle Langhe for the lion's assistance and care, and all the colleagues who helped us in each procedure.

LITERATURE CITED

1. Bertazzolo W, Didier M, Gelain ME, Rossi S, Crippa L, Avallone G, Roccabianca P, Bonfanti U, Giori L, Fracassi F. Accuracy of cytology in distinguishing adrenocortical tumors from pheochromocytoma in companion animals. Vet Clin Pathol. 2014;43:453-459.

2. Chentili F, Bekkaye I, Yahiaoui, Souidi S, Fedala NS, Azzoug S. Feminizing adrenal tumors: our experience about three cases. Indian J Endocrinol Metab. 2013;17:509-513.

3. Gregori T, Mantis P, Benigni L, Priestnall SL, Lamb CR. Comparison of computed tomography and pathologic findings in 17 dogs with primary adrenal neoplasia. Vet Radiol Ultrasound. 2015;2:153-159.

4. Meler EN, Scott-Moncrieff CJ, Peter AT, Bennett S, Ramos-Vara J, Salisbury KS, Naughton JF. Cyclic estrous-like behaviour in a spayed cat associated with excessive sex-hormone production by an adrenocortical carcinoma. J Feline Med Surg. 2011;13:473-478.

5. Rosenthal KL, Peterson ME. 1996. Evaluation of plasma androgen and estrogen concentrations in ferrets with hyperadrenocorticism. J Am Vet Med Assoc. 1996;209:1097-1102.

ULTRASONOGRAPHY IN BOBCATS (*Lynx rufus*): ASSESSMENT OF REPRODUCTIVE PERFORMANCE AND GENERAL HEALTH STATUS

Julia Bohner, Vet,[1]* Sergey V. Naidenko, Dr rer nat,[2] Katarina Jewgenow, Prof, Dr rer nat,[1] Johanna Painer, Vet,[1] and Frank Göritz, Dr vet med, MRCVS[1]

[1]Leibniz Institute for Zoo and Wildlife Research (IZW), Berlin, 10315, Germany; [2]Severtsov Institute Ecology and Evolution RAS, Moscow, 119071

Abstract

Assessments of general health with advanced ultrasound techniques have been introduced to many wildlife species, among them several feline species. Once an animal undergoes general anaesthesia a detailed examination of internal organs can be performed within a short time. Benefits include baseline data for every species, as well as an individual health evaluation. From 2014 to 2016 we performed repeated examinations on captive bobcats (n =8) using high resolution ultrasonography and serum hormone analysis. Our aim was the assessment of their annual reproductive cycle with a special focus on the lifespan of corpora lutea (CL), which are known from other lynx species to be persisting over at least 2 yr. Within these examinations we could show the seasonal pattern of luteal tissue by evaluation of total luteal volume (TLV), progesterone (P4) and estradiol (E2). The follow up of single CL over time was achieved through creation of topographic maps. The annual cycle of bobcats was divided into four seasons, with n = 3 examinations during prebreeding season (preBS), n = 5 examinations during breeding season (BS), n = 6 examinations in the postbreeding season (postBS), and n = 6 examination in the nonbreeding season (nonBS). Ovarian dynamic was analysed according to total luteal tissue volume (CL_V), P4 and E2 levels. Data presented as means (± SEM). Each animal was examined at least twice. The results show that luteal activity during BS compared to the postBS was clearly increased. With a 37.4% higher TLV (BS: 1013.94 ± 293.2 mm^3/ postBS: 634.57 ± 139.8 mm^3) as well as higher P4 (BS: 13.49 ± 4.9 ng/ml/ postBS: 9.09 ± 1.9 ng/ml). Furthermore at the transition from postBS to nonBS especially functional ovarian activity drops which is reflected in a 70% decrease of progesterone (postBS: 9.09 ± 1.9 ng/ml/ nonBS: 2.70 ± 0.5 ng/ml). Structural regression of luteal tissue occurs slower with a 14.9% decrease and an additional decline of 53% from nonBS (540.27 ± 91.8 mm^3) to preBS (253.29 ± 88.5 mm^3). In summary structural luteolysis of persistent CL in Bobcats seems to be much faster than in Eurasian and Iberian lynx, with a probability of CL not being detectable by ultrasound after 9 mo. The functional activity of persistent CL is apparent according to their hormonal production (P4). The assessment of general health by sonomorphologic evaluation of internal organs revealed evidence of renal disease in some of the females. Sonopathologic findings—although most individuals did not express any clinical signs of illness—included renal fibrosis (n = 2), calcifications (n = 1), as well as multiple cysts (n = 1). Sonomorphologically renal fibrosis is presented with hyperechoic structures (vessels, glomerular RIM, renal pelvis), than normal kidneys. Calcifications show shadows of no wave intromission below the calcification. A kidney with multiple cysts is characterized by round shaped, fluid filled (hypoechoic), closed structures in various locations of a kidney. Many feline species are susceptible to renal disease due to, amongst others, their carnivorous diet, advanced ages in captivity and genetic predisposition. Clinical signs are often vague. Changes of blood values only appear after 75% (standard tests, Creatinine, BUN) or 25% (new test, SDMA) of renal tissue is irreversible damaged. Thus,

ultrasonography is often the only tool to detect renal pathologies at an early stage, where preventative measures could still decrease or stop further pathologic developments. Improved diagnostics may have an important influence on diets, possible treatments and subsequent decisions regarding breeding.

Key words: Bobcat, chronic renal disease, *Lynx rufus*, sonomorphology, sonopathology, urogenital tract

SUCCESSFUL TREATMENT AND MANAGEMENT OF SEVERE DERMATOPHYTOSIS IN A GROUP OF CAPTIVE SNOW LEOPARDS (*Uncia uncia*)

Sarah Chapman, BVMS, MSc, DZooMed (Mammalian), MRCVS,[1]* Phillipa Dobbs, BSc (Hons), BVetMed (Hons), MRCVS,[1] Kate Griffiths, BVSc, CertVD, PGDip MRCVS,[2] Elizabeth M. Graham, PhD, MRCVS,[3] and Mary Pinborough, ONC, MLS, BTEC, HNC, MLS, Micro Special AIBMS[4]

[1]Twycross Zoo, East Midlands Zoological Society, United Kingdom; [2]University of Nottingham School of Veterinary Medicine and Science, United Kingdom; [3]Veterinary Diagnostic Service Infectious Diseases Unit, School of Veterinary Medicine, Glasgow University, United Kingdom; [4]Pinmoore Animal Laboratory Services Limited, Cheshire, United Kingdom

Abstract

Skin disease is a common medical issue in domestic animal practice and is frequently reported in zoological collections, sometimes due to inappropriate husbandry (e.g., low humidity, nutritional deficiencies). Infectious disease can be a causative factor or a secondary issue following an initial pruritic complaint (e.g., allergic skin disease).[1] Allergies and infectious diseases have been described and diagnosed using techniques from domestic animal practice (e.g., biopsy, allergy testing and culture). Fungal skin disease was diagnosed in a group (3.1) of snow leopards (*Uncia uncia*). Three out of four individuals showed clinical signs which varied in severity. The presenting clinical signs ranged from mild hair loss to severe lameness with deep skin lesions between digits. Diagnostics included skin samples for culture and histopathology which lead to the diagnosis of dermatophytosis and excluded various differential diagnoses (e.g., viral disease).[2] After consultation with a veterinary dermatologist and a literature review,[3,4] treatment was instigated for the group using oral itraconazole at 5 mg/kg once daily given individually for 8 wk. Liver protectants were given at domestic carnivore doses (Denamarin, Protexin®) for 12 wk. Management also included disinfection of the enclosure where practical. Investigation of underlying factors and susceptibility for those worst affected was also undertaken. The source of the infection was explored and theorised to be due to contact with horse hide in conjunction with damp, cold conditions. These cases highlighted the importance of positive reinforcement training which allowed conscious examination, monitoring of lesion progression and successful treatment of the group.

Key words: Dermatophytosis, itraconazole, snow leopard, *Uncia uncia*

ACKNOWLEDGMENTS

The authors would like to thank the keepers involved for their commitment to treatment and training of the snow leopards, to ensure full compliance of all medications, and enclosure management which is now part of the normal husbandry routine.

LITERATURE CITED

1. Moriello KA. Treatment of dermatophytosis in dogs and cats: review of published studies. Vet Dermatol. 2004;15:99-107.

2. Junge RE, Miller RE, Boever WJ, Scherba G, Sundberg J. Persistent cutaneous ulcers associated with feline herpesvirus type 1 infection in a cheetah (*Acinonyx jubatus*). J Am Vet Med Assoc. 1991;198:1057-1058.

3. Sykes J, Ramsay E. Attempted treatment of tigers (*Panthera tigris*) infected with *Microsporum canis*. J Zoo Wildl Med. 2007;382:252-257.

4. Rotstein D, Thomas R, Helmick K, Citino S, Taylor S, Dunbar M. Dermatophyte infections in free-ranging Florida panthers (*Felis concolor coryi*). J Zoo Wildl Med. 1999;302:281-284.

FAMILIAL OCCURRENCE OF SUSPECTED SWEAT GLAND ADENOCARCINOMA IN FOUR AFRICAN HUNTING DOGS (*Lycaon pictus*)

Baptiste Chenet, DVM,[1]* Marion Mosca, DVM,[2] David Gomis, DVM,[1] Karin Lemberger, DVM, Dipl ACVP,[3] and Didier Pin, DVM, Dipl ECVD[2]

[1]Parc de Lunaret - Zoo de Montpellier, 34090 Montpellier, France; [2]VetagroSup, Campus vétérinaire de Lyon, Marcy l'étoile, France; [3]Vetdiagnostics, 69008 Lyon, France

Abstract

Four 9-yr-old female littermate African hunting dogs (*Lycaon pictus*) presented nodules on the dorsal midline. Lesions appeared when the dogs were between 5 and 8 yr old. In two dogs, the nodules were firm, well circumscribed and in the others, they were coalescing and formed a plaque extending from the head to the tail. Masses increased in size over 2-3 yr and became ulcerated. The regionals lymph nodes remained normal.

Neoplasia was suspected based on ultrasound, cytology and negative bacterial culture. Histopathologic exam of biopsies from the four dogs revealed well-defined, non-encapsulated nodular lesions, located in the deep dermis and subcutis. The architecture of the lesions was consistent with sweat gland adenocarcinoma but immunohistochemistry is ongoing to differentiate from neoplasia of sebaceous origin. No signs of embolization were present.

After investigation on ascendants and on the siblings, only one female half-sibling was diagnosed with the same neoplasia. Further investigations are being performed to look for genetic links.

This neoplasm seems common in this species in American zoos[1] but to the authors' knowledge, this is the first description of it occurring in several animals from the same litter. These cases reinforce the gender predilection for females although they infirm the role of contraceptives with which none of these individuals was treated.

In dogs, distant metastases are rare (about 2%) and in African hunting dogs, the malignancy is usually local.[1,2] Here, complete surgical excision was attempted and the dogs are checked regularly to look for metastasis.

Key words: Adenocarcinoma, African wild dog, *Lycaon pictus*, nodules, siblings, sweat gland

ACKNOWLEDGMENTS

The authors would like to thank Dermatology-Dermatopathology Unit, VetAgro Sup Veterinary Campus Lyon and Vetdiagnostics for their expertise and Parc de Lunaret - Zoo de Montpellier keepers for the care of these animals.

LITERATURE CITED

1. Agnew DW, Trupkiewicz J, Newton AC, Garner M. Danger is only skin deep: dermal neoplasms in African hunting dogs (*Lycaon pictus*). Proc Am Assoc Zoo Vet, Am Assoc Wildl Vet, and Wildl Dis Assoc; 2009. p. 28-29.

2. Simko E, Wilcock BP, Yager JA. A retrospective study of 44 canine apocrine sweat gland adenocarcinomas. Can Vet J. 2003;44:38-42.

INFLAMMATORY BOWEL DISEASE IN A CLOUDED LEOPARD (*Neofelis nebulosa*)

Yen Hsueh Lai, DVM,[1] Olivia Hsieh, DVM,[2] and Jun Cheng Guo, DVM[1]*

[1]Taipei Zoo, Taipei City 11656, Taiwan, [2]National Taiwan University Veterinary Hospital, Taipei City 106, Taiwan

Abstract

Inflammatory bowel disease is a commonly diagnosed infiltrative gastrointestinal disease in domesticated house cats; however, cases are seldom diagnosed and reported in captive endangered exotic cats. A 15-yr-old female clouded leopard at Taipei Zoo began to show clinical signs of intermittent vomiting and chronic weight loss in July, 2013. In the following 16 mo, a 33% weight loss (from 16-10.6 kg) was observed. Initial laboratory findings showed normocytic non-regenerative anemia, and no significant changes on abdominal ultrasound and computed tomography. Further diagnostic work-up performed on March 24, 2015 revealed thickening of the small intestines, and a hypoechoeic pancreas on abdominal ultrasound. Gastrointestinal biopsy obtained via endoscopy showed changes consistent with feline inflammatory bowel disease. Therapeutic management for inflammatory bowel disease including oral prednisolone, subcutaneous cobalamin injections, and intramuscular iron dextran injections were instituted to which the clouded leopard responded well with evidence of weight gain and resolution of the anemia.

Key words: Clouded leopard, inflammatory bowel disease, *Neofelis nebulosa*

EFFICIENT TREATMENT OF FLEA INFESTATION WITH ORAL FLURALANER IN EIGHT CAPTIVE MANED WOLVES (*Chrysocyon brachyurus*)

Hanna S. Kokubun, DVM,* André L.M. Costa, DVM, Vanessa L. Ribeiro, DVM, Rode P. Gomes, DVM, Mariana H. Paschoalotti, DVM, and Rodrigo H.F. Teixeira, DVM, MSc

Sorocaba Zoo, Sorocaba, São Paulo, 18020-268, Brazil

Abstract

Fleas are the most common ectoparasite in domestic animals, and also infest all species of wild mammals, such as *Chrysocyon brachyurus*.[1,2] The maned wolf is the biggest canid in South America, reaching 20-30 kg and 90 cm withers tall.[2,6,7] It is classified as a near threatened species by IUCN.[3] In Brazil there is a big effort and conservation programs such as educational campaigns and breeding programs.[2,3,6] The warm weather favors the insect prevalence in the environment and in captive animals.[5] The common species found in important infestation is *Ctenocephalides* which are usually associated as a vector in parasitic disease and its infestation can cause severe anemia and eventually be lethal.[1,2,5] A lot of effort is expressed by trying to control flea infestation in animals (i.e., antiparasitic administered topically, by injection, or orally) and environment (i.e., sweep, aspirate, fire broom and topic insecticide).[2,4,6] Because of the increasing of medicine resistance, new molecules are now being developed.[1,8] Fluralaner (Bravecto®) is a new molecule of isoxazolines used as an alternative therapeutic, once regular principles were widely used and now has resistance. There are good results in dogs treated with this medication showing this effectiveness by oral administration of a palatable pellet every 3 mo, and having superior results in flea control comparing to monthly topical administration of fipronil.[5] In this study, eight maned wolves of Sorocaba Zoo were selected: one female, three males and four cubs (that were born 6 mo after the beginning of the project). They had a cyclic infestation for years showing scratching, probably caused by re-infestation of errant animals living free at the main area (e.g., agouti). The previous treatment used to control the infestation was pour-on fipronil by physical restraint monthly and environmental treatment with sweep, fire broom and pyrethroid. The exhibit was inspected for flea infestation weekly. All four animals were anesthetized for full physical exam, and no fleas were detected in the animals or the environment. The fluralaner pellet was offered in normal feeder place. This protocol was repeated every 3 mo for the total of 9 mo. The concentration of the fluralaner in the pellet was based in estimated weight for all the animals and match by industrial determination. Animals were physically restrained for inspection every 6 mo and weekly the staff inspected the enclosure for flea infestation. In this period, the environment of the exhibit was not treated with any chemical components or physical treatment (i.e., fire broom), being only swept. Six months after the beginning of the study, the adult female gave birth to four cubs. When the cubs reached 4 mo of age, a flea infestation was detected in the environment and the cubs were seen scratching themselves. All cubs were physically restrained to perform physical exams. Although they were evaluated as in good healthy condition, presence of fleas was detected, and they were vaccinated and administrated oral medication with fluralaner. In total, the pellets were administrated three times, every 3 mo. For the cubs, the pellets were administrated one time in total. Prior to the present study, monthly administration of pour-on fipronil did not prevent flea infestation in less than 1 mo, even when the environmental treatment was conducted. The single oral administration of this molecule every 3 mo was more effective as no infestation was observed.

The goals of using fluralaner were to minimize stress of physical restraining, reduce the period of administration and increase efficiency. The choice of treating the environment by sweeping intended to have only fluralaner as the acting agent. The link between studies in domestic animals and its utility for wild animals helps increase welfare for wild animals and therefore their health. Based on data of fipronil resistance and effectiveness using fluralaner, observations were similar in maned wolves.[1,8] Furthermore, changing the administration site of the antiparasitic reduced human contact, minimized the stress caused by physical restraint to administer it topically, and therefore, reduced its consequence for animal welfare.[4] The description of fluralaner being safe in pregnant dogs and safe to use in puppies, and the fact that the female was able to generate four healthy individuals after the start of treatment is an important aspect considering wildlife conservation. Fluralaner has proved great efficiency and safety, and will be continually used, since all animals presented active, with good body condition and eating well. Further studies should be conducted for its use in other species.

Key words: *Chrysocyon brachyurus*, *Ctenocephalides*, ectoparasite, Fluralaner, isoxazoline, maned wolf

LITERATURE CITED

1. Coles TB, Dryden MW. Insecticide/acaricide resistance in fleas and ticks infesting dogs and cats. Parasites Vectors. 2014;7:8. doi:10.1186/1756-3305-7-8.

2. Gomes MS. Carnivora - canidae (lobo-guará, cachorro-do-mato, raposa-do-campo). In: Cubas ZS, Silva JCR, Catão-Dias JL (eds.). Tratado de Animais Selvagens - Medicina Veterinária. São Paulo, Brazil: Roca; 2006. p. 501-502.

3. Holland R. The maned wolf ex situ worldwide. In: Consorte-Mccrea AG, Santos EF (eds.). Ecology and conservation of the maned wolf: multidisciplinary perspectives. Boca Raton (FL): CRC Press; 2013. p. 53-62.

4. Maia OB, Gouveia AMG. Birth and mortality of maned wolves *Chrysocyon brachyurus* (Illiger, 1811) in captivity. Brazilian J Biol. 2002;62:25-32.

5. Pereira MC, Santos AP. *Ctenocephalides felis feli*s: biologia, ecologia e controle integrado. Clin Vet. 1998;3:31-36.

6. Pessutti C, Santiago MEB, Oliveira LTF. Order Carnivora, Family Canidae (dogs, foxes, maned wolves). In: Fowler ME, Cubas ZS (eds.). Biology, medicine and surgery of South American wild animals. Ames (IA); Iowa State University Press; 2001. p. 279-290.

7. Redford KH, Eisenberg JF. Mammals of the neotropics, volume 2: the Southern Cone: Chile, Argentina, Uruguay, Paraguay. Chicago (IL): University of Chicago Press; 1992.

8. Rohdich N, Roepke RKA, Zschiesche E. A randomized, blinded, controlled and multi-centered field study comparing the efficacy and safety of Bravecto™ (fluranaler) against Frontline™ (fipronil) in flea and tick-infested dogs. Parasites Vectors. 2014;7:83. doi: 10.1186/1756-3305-7-83.

SURGICAL APPROACH TO PARTIAL EYELID AGENESIS IN SNOW LEOPARDS (*Uncia uncia*)

Jochen Lengger, Mag med vet,[1]* Hannes Meissel, Dr,[2] Leif Blomqvist,[3] and Barbara Nell, Prof, Dr, Dipl ECVO[4]

[1]Zoologischer Garten Schwerin, 19061 Schwerin, Germany; [2]Veterinary clinic Oberalm, 5411 Oberalm, Austria; [3]Nordens Ark, 456 93 Hunnebostrand, Sweden; [4]University of Veterinary Medicine, Vienna, Department for Small Animals and Horses, 1210 Vienna, Austria

Abstract

Congenital agenesis of the eyelid is a defect caused by the failure of the optic vesicle to close.[1] In 1978 Carl Wahlberg was the first to describe this malformation in snow leopards. Together with other symptoms this syndrome is known as multiple ocular coloboma (MOC).[4] Since then some 66 cases have been reported from 22 institutions worldwide.[2] MOC in Snow leopards is characterized by bilateral or unilateral agenesis of the upper eyelid. Most cases show persisting pupillary membranes and/or iridal colobomata. Less frequently recognized symptoms are dysplasia of the posterior eye segment and microphthalmia. All defects occur in varying degrees, ranging from almost not visible to serious malformations including blindness of the cubs.[2,3] In three MOC diagnosed snow leopard cubs agenesis of the upper eyelid was treated by surgical reconstruction. In a first step the affected portion of the eyelid was excised and sutured. As a second step the temporal canthus was cut through. Finally to restore the correct length of the lower eyelid a wedge excision was set and sutured. As a result the generated wound margin of the upper lid was to substitute the missing lid edge. From a cosmetic point of view this surgical procedure was not able to fully restore the normal shape of a snow leopard's eyelid. But it resolved trichiasis and associated eye infections. From this point of view it was very successful.

Key words: Agenesis eyelid, ocular coloboma, surgery, treatment, *Uncia uncia*

LITERATURE CITED

1. Gregory-Evans CY, Williams MJ, Halford S, Gregory-Evans K. Ocular coloboma: a reassessment in the age of molecular neuroscience. J Med Genet 2004;41:881-891.

2. Lengger J, Walzer C, Blomqvist L. An update on ocular colobomata in snow leopards (*Uncia uncia*). In: Blomqvist L (ed.). International pedigree book for snow leopards, *Uncia uncia*, Volume 10. Hunnebostrand (Sweden): Nordens Ark Foundation; 2013. p. 35-37.

3. Schäffer E, Wiesner H, von Hegel G. Multiple occulare kolobome (MOC) mit persistierenden pupillarmembranen beim schneeleoparden (*Panthera uncia*) Tierärztl Prax. 1988;16:87-91.

4. Wahlberg C. A case of multiple ocular coloboma in a snow leopard. In: International pedigree book for snow leopards, *Panthera uncia*, Volume 1. Helsinki (Fin): Helsinki Zoo; 1978. p. 108-112.

CAUSES OF MORTALITY IN FELIDS AT PARQUE ZOOLOGICO HUACHIPA FROM 1998 TO 2015

Fernando Murillo, DVM,[1]* Gianmarco Rojas, DVM, Esp, MSc (c),[1,2] Lizzie Ortiz, DVM,[1] and Ewerton L. de Lima, DVM[1]

[1]Parque Zoológico Huachipa, Ate Vitarte, Lima-03, Perú; [2]Facultad de Ciencias Veterinarias y Biológicas, Universidad Científica del Sur, Lima, Perú

Abstract

The felids belong to the family Felidae, order Carnivora. They are among the most threatened groups of mammals.[1] The need for understanding the factors causing mortality is of primary importance for conservation efforts. Necropsy reports of 54 felids were analyzed at the veterinary department of Parque Zoologico Huachipa from January 1998 to April 2015 to determine the causes of mortality, and the influence of age and gender. The cases consisted of eleven species; puma (*Puma concolor*), jaguarondi (*Puma yagouaroundi),* jaguar *(Panthera onca)*, lion (*Panthera leo),* tiger (*Panthera tigris*), ocelot (*Leopardus pardalis*), margay (*Leopardus wiedii*), oncilla (*Leopardus tigrinus*)*,* Andean mountain cat (*Leopardus jacobita*) and pampas cat (*Leopardus colocolo*) consisting of 14 neonates (10 females and 4 males), 1 juvenile (1 male) and 32 adults (15 females and 17 males) and 7 geriatrics (5 females and 2 males). Neonatal and juveniles mortalities were caused by neonatal death 26.7%, trauma 26.7%, infection 33.3% and unknown causes 13.3%. Causes of death for adult and geriatric felids included gastrointestinal diseases 20.5%, respiratory diseases 7.7%, renal and urinary diseases 17.9%, reproductive diseases 10.3%, musculoskeletal diseases 5.1%, multisystemic 25.6%, unknown 2.6%, trauma 7.7% and others 7.7%. The most common causes of mortality were trauma, multisystemic and reproductive diseases in females and digestive diseases in males. Neoplasia was identified as the cause of death or reason for euthanasia in females. Identifying common trends in mortality will outline the steps necessary to improve the veterinary care and conservation efforts for these species.

Key words: Diseases, felids, mortality, neoplasia

ACKNOWLEDGMENTS

The authors thank the "Parque Zoológico Huachipa" for allowing the access to the collection of felids and for all logistical support in this research, especially to Lizette Bermudez, Chief of Fauna Area.

LITERATURE CITED

1. Lamberski N. Felidae. In: Miller RE, Fowler ME (eds). Zoo and wild animal medicine, Volume 8. St. Louis (MO): Elsevier Saunders; 2015. p. 467-490.

ANESTHESIA OF EUROPEAN BROWN BEARS (*Ursus arctos*)

Johanna Painer, DVM* and Frank Goeritz, DVM, Dr. med. vet

Leibniz Institute for Zoo and Wildlife Research, Berlin, B 10460 Germany

Abstract

During the last 5 yr we immobilized 98 captive brown bears (*Ursus arctos*) that had been confiscated from private owners or animal parks in Germany, Poland, Kosovo, Ukraine due to animal welfare concerns. Anaesthetic agents were administered via a 3-ml dart equipped with a 2 x 60 mm needle and delivered using a CO_2 powered dart gun. A combination of ketamine (2.4 ± 0.8 mg/kg BW), medetomidine (0.036 ± 0.01 mg/kg BW), midazolam (0.05 ± 0.02 mg/kg BW), and butorphanol (0.05 ± 0.02 mg/kg BW) was administered intramuscularly in the upper front leg or ventral shoulder area as the initial dose. A rapid and smooth induction time of 4 ± 1 min to recumbency was observed. If prolonged immobilisation was required, supplementation was required on average at 40 min (22-75 min) after induction. Bears received intranasal or intratracheal medical oxygen, a catheter in the jugular vein for infusion of isotonic fluids, and had reflexes and vital parameters recorded every 10 min. The heart rate was on average 46 ± 15 beats/min, respiration rate was 8 ± 3 deep breaths/min, pulse-oximetry showed on average of 97 ± 4% oxygen saturation, at 37.6 ± 0.4°C body temperature. Blood samples for blood gas analysis (I-stat), biochemistry, haematology and hormone analysis were also collected. Anesthesia was partially antagonized with 5.9 ± 1.7 mg atipamezole per 1 mg medetomidine plus 4.6 ± 3 mg naltrexone per 1 mg butorphanol i.m., earliest 30 min after the last ketamine injection. The bears were moved into transport cages and transported fully awake to bear sanctuaries. The advantages of this protocol are a rapid induction time without respiratory depression or spontaneous arousals and stable and reliable anaesthesia for at least 40 min after darting, and a smooth recovery.

Key words: Anesthesia, butorphanol, ketamine, medetomidine, midazolam, *Ursus arctos*

SEROLOGIC EVIDENCE OF *Cytauxzoon felis* IN CAPTIVE LIONS OF INDIA

Sujay C. S., BVSc & AH, PGdip,[1]* Muliya S. K., BVSc & AH, MVSc,[2] Gonathinayagam. S., BVSc & AH, MVSc,[1] Senthilkumar. K., BVSc & AH, MVS,[1] Manjunatha. V., BVSc & AH, MVSc,[3] Azhahianambi. P., BVSc & AH, MVSc,[1] and Jayathangaraj. M. G., BVSc & AH, MVSc, PhD[1]

[1]Madras Veterinary College, Chennai, Tamil Nadu, 600007 India; [2]Bannerghatta Biological Park, Bangalore, Karnataka, 560083, India; [3]Wild Animal Disease Diagnostic Lab - Bannerghatta Biological Park, Bangalore, Karnataka560083, India

Abstract

Cytauxzoon species are apicomplexan parasites, related to important human and veterinary pathogens in the genera *Babesia* and *Theileria*. So far, *Cytauxzoon* has been reported from the United States, South America, Europe and Asia. In 2014, during a study to evaluate hemato-biochemistry parameters in captive lions, piroplasms were observed in blood smears of one-fourth of the total lion population housed in a rescue center of Bannerghatta Biological Park. Eight animals subsequently became ill, exhibiting anorexia, lethargy, weakness, pale mucous membranes, hematuria, icterus, pancytopenia and thrombocytopenia as common clinic-pathologic abnormalities. Further to this, the present study was undertaken to identify the piroplasm species based on molecular techniques. Blood samples were aseptically collected from 20 restrained lions in EDTA vacutainer and immediately transported to a laboratory under strict cold chain. DNA was extracted from whole blood using a commercially available DNA isolation kit. Amplification of a portion of the 18S rRNA gene of C. felis was accomplished using PCR and primers specific to C. felis; sequence being 5'- GCGAATCGCATTGCTTTATGCT-3'and 5'-CCAAATG ATACTCCGGAAAGAG-3'. The DNA products from PCR were analyzed by agarose gel electrophoresis and the amplicons obtained were visualized and photographed in Gel documentation system. Seventy percent (i.e., fourteen of the samples, n = 14) showed presence of *Cytauxazoon felis* specific DNA by PCR. The PCR study carried out here, helped to perform differential diagnosis among the piroplasms as well as detection of organism in asymptomatic lions. Findings of the present study also serve as the first confirmatory report for *Cytauxzoon* species in India.

Key words: *Cytauxazoon felis,* India, lion, PCR, piroplasms

ACKNOWLEDGMENTS

The authors would like to acknowledge Member Secretary, ZAK and Executive Director, Bannerghatta Biological Park for necessary permits and Veterinarians and support staff of Bannerghatta Biological Park for their continuing support.

PHYLOGENETIC ANALYSIS OF THE HEMAGGLUTININ GENE OF CANINE DISTEMPER VIRUS FROM NATIVE WILDLIFE IN THE SOUTHEASTERN UNITED STATES

Kellyn M. Sweeley,[1]* Karen L. Bailey, MBA,[1,2] Jerry T. Saliki, DVM, PhD, Dipl ACVM,[3] Michael J. Yabsley, MS, PhD,[1,2] and Daniel G. Mead, MS, MPH, PhD[1]

[1]Southeastern Cooperative Wildlife Disease Study, Department of Population Health, CVM, University of Georgia, Athens, GA 30602 USA; [2]Warnell School of Forestry and Natural Resources, University of Georgia, Athens, GA 30602 USA; [3]Athens Veterinary Diagnostic Laboratory, CVM, University of Georgia, Athens, GA 30602 USA

Abstract

Canine distemper virus (CDV; family Paramyxoviridae, genus *Morbillivirus*) causes a fatal systemic disease in a variety of terrestrial and marine carnivores. The hemagglutinin (H) gene of CDV has considerable genetic diversity and has been used to evaluate phylogenetic relationships of CDV samples worldwide.[1,3] Currently, nine distinct lineages, primarily based on geography, are recognized worldwide. Recent H gene analysis suggests that CDV originated in North America and the most recent ancestor of all CDV likely emerged in the 1880s.[2] However, a limited number of CDV samples from the United States were included in previous analyses. In the current study, thirteen CDV strains from gray fox (*Urocyon cinereoargenteus*), striped skunk (*Mephitis mephitis*), and raccoon (*Procyon lotor*) from the southeastern United States were genetically analyzed by sequence analysis of the full-length H gene. Phylogenetic analysis revealed that eleven of the samples were in the large genetically diverse North America 2 (NA2) clade. Interestingly, two samples clustered in a new clade completely distinct from the previously recognized lineages, including the two recognized North American clades. We confirmed that the NA2 clade is diverse and now includes CDV samples from two new hosts (gray fox and striped skunk). We also identified a new clade which is particularly interesting given that most strains are geographically, not host, associated. Future work will be aimed at acquiring additional sequences from US strains to aid future spatio-temporal phylogenetic analyses of CDV. Combined with epidemiologic data, a better understanding of the epidemiology of CDV should be possible.

Key words: Canine distemper virus, carnivore, hemagglutinin gene, phylogenetic analysis, *Morbillivirus*, wildlife

ACKNOWLEDGMENTS

The authors would like to thank Chris Cleveland and the UGA Veterinary Diagnostic lab personnel for their lab support. We also thank the generous donors to and volunteers at the Kentucky Wildlife Center. Additional support was provided by member states of SCWDS.

LITERATURE CITED

1. Lan NT, Yamaguchi R, Inomata A, Furuya Y, Uchida K, Sugano S, Tateyama S. Comparative analyses of canine distemper viral isolates from clinical cases of canine distemper in vaccinated dogs. Vet Microbiol. 2006;115:32-42.

2. Panzera Y, Sarute N, Iraole G, Hernandez M, Perez R. Molecular phylogeography of canine distemper virus: Geographic origin and global spreading. Mol Phylogenet Evol. 2015;92:147-154.

3. Zhao F, Yan X, Martella V, Luo G, Zhang H, Gao H, Liu Y, Bai X, Zhang L, Chen T, Xu L, Zhao C, Wang F, Shao X, Wu W, Cheng S. Phylogenetic analysis of the haemagglutinin gene of canine distemper virus strains detected from breeding foxes, raccoon dogs and minks in China. Vet Microbiol. 2010;140:34-42.

ULTRASONOGRAPHIC CHARACTERISTICS OF INTESTINAL ASCARIASIS COINCIDENT WITH CHOLECYSTITIS AND CHOLELITHIASIS IN ASIATIC CHEETAH (*Acinonyx jubatus venaticus*)

Yasamin Vali, DVM, DVsc Student,[1]* Iman Memarian, DVM,[2] Mohammad Molazem, DVM, DVsc,[1] and Alireza Shahrdari[2]

[1]Department of Surgery and Radiology, Faculty of Veterinary Medicine, University of Tehran, 14155-6453, Tehran, Iran; [2]Tehran Zoo and Pardisan Wildlife Rehabilitation Center, 1484613111, Tehran, Iran

Abstract

The Asiatic cheetah (*Acinonyx jubatus venaticus*), known as yuz in Iran, is one of the most endangered members of the Felidae family. Captive breeding and preventive medicine examinations are vital to maintaining good health and successful conservation efforts for this species. Ultrasonography of a captive male Asiatic cheetah during routine examination revealed numerous tubular straw-like structures within the dilated intestine and stomach. In longitudinal sections, these structures consisted of two echogenic parallel lines with a central hypoechoic band. Their diameter was approximately 3 mm. Cross sections of the same structures were target-like. Thickening of the gallbladder wall up to 4.6 mm in addition to an echogenic structure associated with a distal acoustic shadow within the gall bladder was also detected. The cheetah was diagnosed with a parasitic infection (ascariasis), cholecystitis and cholelithiasis based on ultrasound findings by a veterinary radiologist. Any blood work changes to suggest cholestasis, infection or elevation in liver enzymes was not found. Although ultrasound examination is commonly used as a safe, fast, inexpensive and non-invasive method of diagnosis of intestinal ascariasis in human medicine[2] it is rarely used as the primary diagnostic test to identify intestinal parasites in veterinary patients. Also reported in humans is a link between parasitic infection, cholecysitis and cholelithiasis.[3] To the best of the authors' knowledge this is the first report of intestinal ascariasis and gall bladder disease in cheetahs. Since *Toxocara* sp. eggs are commonly found in the feces of captive cheetahs,[1] ultrasonography may serve as a useful diagnostic test to diagnosis and monitor ascariasis post treatment in this species. Overally, it should be considered that ascariasis is most commonly diagnosed in felids by parasitologic examination (fecal float) and this is likely much cheaper and more cost effective as anesthesia and veterinarian's time is not needed for a diagnosis and presenting the ultrasonography is of value for further investigations.

Key words: *Acinonyx jubatus venaticus*, ascariasis, Asiatic cheetah, cholecystitis, cholelithiasis, ultrasonography

LITERATURE CITED

1. Caro TM, Holt ME, FitzGibbon CD, Bush M, Hawkey CM, Kock RA. Health of adult free-living cheetahs. J Zool. 1987;4:573-584.

2. Koumanidou C, Manoli E, Anagnostara A, Polyviou P, Vakaki M. Sonographic features of intestinal and biliary ascariasis in childhood: case report and review of the literature. Ann Trop Paediatr. 2004;24:329-335.

3. Schulman A. Intrahepatic biliary stones: imaging features and a possible relationship with ascaris lumbricoides. Clin Radiol. 1993;47:325-332.

ZOONOTIC HELMINTHOSIS IN ZOOKEEPERS AND ZOO ANIMALS IN UNIVERSITY ZOOLOGICAL GARDEN ABEOKUTA, SOUTHWEST NIGERIA

Oluwaseun D. Adisa, DVM, MVPH,[1] Emmanuel C. Uwalaka, DVM, MVSc,[2] Oyeduntan A. Adediran, DVM, MVSc, PhD,[2] Adeniyi O. Egbetade, DVM, MSc,[3] Olufemi I. Olatoye, DVM, MVPH, PhD,[1] and Olufemi B. Adedeji, DVM, MVPH, PhD[1]*

[1]Department of Veterinary Public Health and Preventive Medicine, University of Ibadan; [2]Department of Veterinary Microbiology and Parasitology, University of Ibadan; [3]Department of Veterinary Medicine and Surgery, Federal University of Agriculture, Abeokuta

Abstract

Helminthosis is a major health challenge among captive and wild animals with zoonotic potential among handlers and zoo visitors in contact with infected animals and contaminated environments. This study was conducted to determine the prevalence of zoonotic helminths and control measures in zookeepers and zoo animals in a university zoological garden in southwest Nigeria.

Fresh faecal samples were collected twice from 30 animals at the Federal University of Agriculture Abeokuta, Zoological Garden and from 15 zookeepers with direct and indirect contact with the animals. A structured questionnaire was administered to zoo personnel on prevention and control strategies employed against helminth parasites. The faecal samples were processed using standard parasitologic techniques (flotation, sedimentation and harass-mori methods) for detection of nematode/cestode eggs, detection of trematodes and for larval culture. Data obtained were subjected to bivariate test analysis.

Out of the 15 zookeepers screened, five zookeepers (one with direct and four with indirect contact) (33.3%) tested positive for one or more helmith parasites. The distribution of the parasites found in the zookeepers was: nematode - *Ancylostoma* spp. (40.0%), *Trichuris* spp. (20.0%), trematodes (20.0%), *Ascaris* spp. (20.0%). Also, 10 of the 30 animals (33.3%) were positive for one or more species of helminth parasites. The species prevalence are: 8.0% *Trichuris* spp., 50.0% *Strongyloides* spp., 8.0% nematodes, 9.0% *Trichostrongylus* spp., and 25.0% *Ancylostoma* spp. among the zoo animals. The results of the questionnaire interview showed that 86.7% of the zookeepers were not dewormed. Annual deworming was employed for the zoo animals. Also, 80.0% of the respondents did not have formal training on zoo management and health control. The results of this study showed that zoonotic helminths such as *Trichuris* spp. and *Ancylostoma* spp. are present in the zookeepers and in zoo animals without a regular routine deworming program. This affirms the possibility of transmission of parasites from animal to human and vice-versa. Lack of formal training on zoo management by the majority of the zookeepers and lack of regular deworming are major risk factors contributing to the risk of zoonotic infection and posed a public health threat in the zoological garden. Hence, One Health strategies comprising good sanitary practices and helminth management within the zoological garden and among the zookeepers are strongly recommended.

Key words: One Health, zoological garden, zoonotic helminths

ACKNOWLEDGMENTS

The authors would like to thank the Department of Veterinary Public Health and Preventive Medicine, Department of Veterinary Microbiology and Parasitology, University of Ibadan and University Zoological Garden Abeokuta for their support and contributions.

LITERATURE CITED

1. Bezjian M, Gillespie TR, Chapman CA, Greiner EC. Coprologic evidence of gastrointestinal helminths of forest baboons, *Papio anubis*, in Kibale National Park, Uganda. J Wildl Dis. 2008;44(4):878-887.

2. Dawet A, Yakubu DP, Butu, HM. Survey of gastrointestinal parasites of non-human primates in Jos Zoological Garden. J. Primatol. 2013;2:108. Available from doi:10.4172/2167-6801.1000108

CONSERVATION EDUCATION CENTERS AS BOUNDARY ORGANIZATIONS FOR VETERINARY OUTREACH

Jennifer C.G. Bloodgood, MS,[1]* Gary T. Green, EdD,[1] Nik Heynen, PhD,[2] Katie Higgins,[3] Terry M. Norton, DVM, Dipl ACZM,[3] Lisa A. Hoopes, PhD,[4] and Sonia M. Hernandez, DVM, Dipl ACZM, PhD[1,5]

[1]Daniel B. Warnell School of Forestry and Natural Resources, University of Georgia, Athens, GA 30602 USA; [2]Department of Geography, University of Georgia, Athens, GA 30602 USA; [3]Georgia Sea Turtle Center, Jekyll Island Authority, Jekyll Island, GA 31527 USA; [4]Georgia Aquarium, Atlanta, GA 30313 USA; [5]Southeastern Cooperative Wildlife Disease Study, College of Veterinary Medicine, University of Georgia, Athens, GA 30602 USA

Abstract

On the southeast coast, stranded, injured or diseased turtles are brought into rehabilitation facilities such as the Georgia Sea Turtle Center (GSTC) on Jekyll Island, GA. Research has shown that rehabilitation centers, especially those with a public education initiative, play a critical role in conservation.[1,2] To increase visitor awareness of conservation efforts, the GSTC offers many educational programs. We proposed that through outreach initiatives, the GSTC may serve as a boundary organization. Boundary organizations work at the interface of two social worlds.[3] This term has traditionally been applied to the theoretical boundary between politics and science, however, we proposed that this concept can be used in more diverse situations, such as when the perceived boundary lies between veterinary medicine and the general public. To measure this, a survey was developed to assess the attitudes and perceptions of visitors at the GSTC. Surveys (n = 217) were implemented on two populations: visitors who did or did not participate in a Behind-the-Scenes (BTS) program. The BTS program allows visitors to meet the veterinarian and view treatments up-close. Reliability and validity analyses revealed the survey was psychometrically sound. Overall, BTS program participants were significantly more likely to agree that sea turtles should be protected ($P < 0.05$), rehabilitating sea turtles is important ($P < 0.01$), and humans should help rehabilitate injured sea turtles ($P < 0.001$). This survey could be used to measure the ability of several conservation entities to act as boundary organizations, and could be applied to rehabilitation centers, zoos, aquaria, museums, and other similar facilities worldwide.

Key words: Boundary organization, conservation, environmental education, rehabilitation, sea turtle, survey

ACKNOWLEDGMENTS

This project was supported by funds from the Coca-Cola Company and the University of Georgia Dean's Social Science Award.

LITERATURE CITED

1. Ballantyne R, Packer J, Hughes K, Dierking L. Conservation learning in wildlife tourism settings: lessons from research in zoos and aquariums. Environ Educ Res. 2007;13:367-383.

2. Feck AD, Hamann M. Effect of sea turtle rehabilitation centres in Queensland, Australia, on people's perceptions of conservation. Endanger Species Res. 2013;20:153-165.

3. Guston DH. Boundary organizations in environmental policy and science: an introduction. Sci Technol Human Values. 2001;26:399-408.

TENSILE FAILURE LOAD IN TWO MONOFILAMENT ABSORBABLE SUTURES: A COMPARISON OF THREE INCUBATION TEMPERATURES OVER TIME

Sarah A. Cannizzo, VMD,[1,2]* Simon C. Roe, BVSc, PhD, Dipl ACVS,[1] Craig A. Harms, DVM, PhD, Dipl ACZM,[1,2] and Michael K. Stoskopf, DVM, PhD, Dipl ACZM[1,2]

[1]College of Veterinary Medicine, North Carolina State University, Raleigh, NC 27607 USA; [2]Center for Marine Sciences and Technology, North Carolina State University, Morehead City, NC 28557 USA

Abstract

It has been observed that absorbable sutures persist in cold-water fishes longer than in mammals. It was hypothesized that suture loops incubated at 4°C and 25°C would hydrolyze more slowly than loops incubated at 37°C. Suture loops (n = 6) formed using two absorbable monofilament 3-0 suture materials, poliglecaprone 25 (Monocryl™) and polyglyconate (Maxon™), were incubated in filtered city water for 2, 4, 6, and 8 wk at 4°C, 25°C, and 37°C. The maximum tensile load was measured as each loop was distracted to failure. Median failure loads were compared over time for each temperature. There were no differences in failure loads for Maxon™ at 4°C over time. At 25°C, loop strength was increased to approximately 50N for 2, 4, 6 and 8 wk compared to 28.5N at 0 wk. At 37°C, the 2- and 4-wk loop strength was greater than 0-wk loops. The loop strength decreased at 6 (30N) and 8 wk (15N). For Monocryl™ at 4°C, the 2-, 4- and 8-wk loops were stronger than the 0-wk loops. There was a wide range of values for the 6-wk loops. At 25°C, the 2-wk loops (41N) were stronger than the 0-wk loops (16.5N). Loop strength declined with time, with a failure load of 12.5N by 8 wk. At 37°C, 2-wk loops (25.5N) were stronger than 0-wk loops (16.5N). Only 4 loops were testable after 4 wk (2N), and none after 6 or 8 wk. Findings confirm that sutures designed to be absorbable in warm-blooded mammals will weaken more slowly in poikilotherms.

Key words: Absorbable suture, cold-water fishes, poikilotherms, poliglecaprone 25 (Monocryl™), polyglyconate (Maxon™), tensile failure load

ACKNOWLEDGMENTS

The authors thank the following people for their support of this project: Stasia Bembenak-Bailey, Heather Broadhurst, Chris Eads, Kyle Farmer, Scott Hammer, Suzanne Kennedy-Stoskopf, Jay Levine, Cheryl Moller, Jen Nieumuth, and Kent Passingham.

THE ANIMAL WELFARE ACT: OVERVIEW OF REQUIREMENTS FOR VETERINARY CARE

Laurie J. Gage, DVM, Dipl ACZM

USDA APHIS Animal Care, Center for Animal Welfare, 1131 Second Avenue, Napa, CA 94558 USA

Abstract

The Animal Welfare Act (AWA) requires that minimum standards of care and treatment are provided to certain mammals bred for commercial sale, used in research, transported commercially, or exhibited to the public. Animal Care is the division of the United States Department of Agriculture (USDA) Animal Plant Health Inspection Service (APHIS) that provides leadership for determining standards of humane care and treatment of animals. APHIS' Animal Care program enforces the AWA primarily through inspections of regulated facilities. To ensure that compliance with the AWA is continually maintained, all facilities that keep animals regulated under the Act must be licensed or registered with APHIS.

APHIS achieves compliance through inspection, education, cooperative efforts and enforcement. Specifications for the veterinary care of animals held by licensees are found in the Animal Welfare Act Regulations Part 2- Regulations; Subpart C (Research Facilities - 2.33) and Subpart D (Attending Veterinarian and Veterinary Care - 2.40); and Part 3-Standards; Subparts D (Nonhuman Primates) and E (Marine Mammals - 3.110 veterinary care).

Part 2: Regulations

Subpart C. Research Facilities 2.33 - Attending Veterinarian and Adequate Veterinary Care

This section states that each research facility shall have an attending veterinarian (AV) under formal arrangements; and if the veterinarian is part-time, this shall include a written program of veterinary care and regularly scheduled visits. The veterinarian shall have appropriate authority to ensure the provision of adequate veterinary care and to oversee the adequacy of other aspects of animal care and use. The AV shall be a voting member of the IACUC and shall provide guidance to principal investigators and other personnel involved in the care and use of animals regarding handling, immobilization, anesthesia, analgesia, tranquilization, and euthanasia. Other stipulations listed in this section are also covered in section 2.40.

Subpart D. Attending Veterinarian and Adequate Veterinary Care 2.40 - Attending Veterinarian and Adequate Veterinary Care (Dealers and Exhibitors)

This section states each dealer or exhibitor shall employ an AV under formal arrangements. If part-time, the formal arrangements shall include a written program of veterinary care (PVC) and regularly scheduled visits to the premises. The AV must have the appropriate authority to ensure the provision of adequate veterinary care and to oversee the adequacy of other aspects of animal care and use. Each dealer or exhibitor must establish and maintain PVCs that include the

availability of appropriate facilities, personnel, equipment, and services; the use of methods to prevent, control, diagnose and treat diseases and injuries, and the availability of emergency, weekend and holiday care. There must be daily observation of all animals to assess their health and well-being which may be done by someone other than the AV. There must be direct and frequent communication so that timely and accurate information on problems of animal health, behavior, and well-being is communicated to the veterinarian. Guidance to animal personnel regarding handling, immobilization, anesthesia, analgesia, tranquilization, and euthanasia as well as pre and post-procedural care with established veterinary medical and nursing procedures must be provided.

Part 3: Standards

Subpart D. Specifications for the Humane Handling, Care, Treatment, and Transportation of Nonhuman Primates

The following records requiring veterinary approval are required for nonhuman primates, when applicable:

- Environmental enhancement plan [3.81]
- Health certificates for transport [2.78(a), Policy #18]
- Approval for acclimation to higher temperatures for
  Sheltered housing [(3.77)(a)]
  Outdoor housing [(3.78)(a) & (b)]
  Mobile/traveling housing [(3.79)(a)]
- Humidity levels for:
  Indoor housing [(3.76)(b)]
  Sheltered housing [(3.77)(b)]
- Attending veterinarian approved exemptions

Subpart E. Specifications for the Humane Handling, Care, Treatment, and Transportation of Marine Mammals - 3.110- Veterinary Care

Newly acquired marine mammals must be isolated from resident animals until the animals can be reasonably determined to be in good health by the AV. It the AV's decision if the potential benefits of a resident animal as a companion to the newly acquired animal outweigh the risks to the resident animal. Holding facilities must be available for isolation, separation, medical treatment, and medical training of marine mammals. Marine mammals isolated or separated for non-medical reasons must be held in facilities that meet the minimum space requirements as outlined in 3.104. Holding facilities for medical treatment or medical training need not meet the minimum space requirements, however if animals requiring medical treatment and/or medical training are housed in enclosures that do not meet minimum space requirements for periods longer than 2 wk the extension must be justified in writing by the AV on a weekly basis. Holding facilities that have contained a marine mammal with an infectious or contagious disease must be cleaned and/or sanitized as prescribed by the AV before a healthy animal may be introduced. Marine mammals exposed to a contagious animal must be evaluated by the AV and monitored and/or isolated for a time determined by the AV. Individual animal records must be kept and made available for APHIS

inspection. Medical records must include the animal identification, a physical description including identifying marks, age, and sex. A physical examination must include length, weight, physical examination results by body system, identification of all medical and physical problems with proposed plan of action, all diagnostic test results, and documentation of treatment. A copy of the individual animal medical record must accompany any marine mammal upon transfer to another facility. All marine mammals must be visually examined by the AV at least semiannually and must be physically examined under the supervision of, and when determined to be necessary by the AV. All cetaceans and sirenians must be physically examined by the AV at least annually, unless APHIS grants an exception from this requirement based on considerations related to the health and safety of the cetacean or sirenian. These examinations must include, but are not limited to, a hands-on physical examination, hematology and blood chemistry, and other diagnostic tests as determined by the AV. A complete necropsy, including histopathology samples, microbiologic cultures, and other testing as appropriate, must be conducted by or under the supervision of the AV on all marine mammals that die in captivity. A preliminary necropsy report must be prepared by the veterinarian listing all pathologic lesions observed. The final necropsy report must include all gross and histologic findings, the results of all laboratory tests, and a pathologic diagnosis. Necropsy records will be maintained at the home facility and at the facility at which it died, if different, for a period of 3 yr and presented to APHIS inspectors when requested.

Key words: Animal Welfare Act, veterinary care

DEVELOPMENT OF AN ONLINE TUMOR DATABASE FOR ZOOLOGICAL AND EXOTIC SPECIES

Tara M. Harrison, DVM, MPVM, Dipl AVZM, Dipl ACVPM,[1]* Cassondra Bauer, DVM, MS, Dipl ACVPM,[2] Ryan Colburn, DVM,[3] Joanne Paul-Murphy, DVM, Dipl ACZM, Dipl ACAW,[4] Michelle G. Hawkins, VMD, Dipl ABVP (Avian), [4]Catherine Pfent, DVM, PhD,[5] and Ashley Zehnder, DVM, Dipl ABVP(Avian), PhD[6]

[1]North Carolina State University, College of Veterinary Medicine, Raleigh, NC 27607 USA; [2]WIL Research, Ashland, OH 44805 USA; [3]John Ball Zoo, Grand Rapids, MI 49504 USA; [4]School of Veterinary Medicine, University of California, Davis, CA 95616 USA; [5]Lincoln Memorial University-College of Veterinary Medicine, Harrogate, TN 37752 USA; [6]Stanford University, School of Medicine, Stanford, CA 94305 USA

Abstract

Diagnoses of cancer are increasing in frequency in exotic animal medicine and zoological institutions. Increasingly, there are parallels between human and animal cancer and therapeutics.[5,8] Further, improved preventive medicine and earlier diagnoses of cancer in zoological species has expanded the therapeutic options in zoo animals.

Cancers have been diagnosed and treated in fish, reptiles, birds, and all forms of mammals.[1-4,7] Reported cancers include lymphoma, papillomas, carcinomas, sarcomas, and melanomas. There are likely to be many more cases that have gone unreported, whether as a case report or case series. Treatments in zoo animals have been facilitated by use of vascular access ports for delivery of chemotherapy, and for anesthesia for radiation treatments.[6,9,10] Through operant conditioning, and the development of newer, safer medications, treatment of zoological species is increasingly feasible. The Exotic Species Cancer Research Alliance, in collaboration with Stanford University, North Carolina State University, and U.C. Davis is developing a data base for clinicians in private practice and in zoological institutions to contribute cases, query for parameters related to tumor type, treatment types, adverse effects of treatment and outcomes. Institutions are encouraged to participate through case contributions to this database, which will include diagnoses, plus annotation of any therapeutics employed and outcomes observed. Through these collaborative efforts, we hope to discover trends in cancer incidence, better understand treatment and therapeutic options for exotic and zoological species, and provide a long-term archive of study material for future research.

Key words: Database, exotic, neoplasia, oncology, therapy, zoo

LITERATURE CITED

1. Abou-Madi N, Kern TJ. Squamous cell carcinoma associated with a periorbital mass in a veiled chameleon (*Chamaeleo calyptratus*). Vet Ophthalmol. 2002;5:217-220.

2. Anderson ET, Kennedy-Stoskopf S, Sandy JR, Dorn B, Boyette T, Harms CA. Squamous cell carcinoma with vascular invasion in a diamondback rattlesnake (*Crotalus adamanteus*). J Zoo Wildl Med. 2010;41:745-748.

3. Bertelsen MF, Steele SL, Grondahl C, Baandrup U. Pheochromocytoma in a white rhinoceros (*Ceratotherium simum*). J Zoo Wildl Med. 2011;42:521-523.

4. Dillberger JE, Citino SB, Altman NH. Four cases of neoplasia in captive wild birds. Avian Dis. 1987;31:206-213.

5. Fukumoto S, Hanazono K, Fu DR, Endo Y, Kadosawa T, Iwano H, Uchide T. A new treatment for human malignant melanoma targeting L-type amino acid transporter 1 (LAT1): a pilot study in a canine model. Biochem Biophys Res Commun. 2013;439:103-108.

6. Kent MS. The use of chemotherapy in exotic animals. Vet Clin North Am Exot Anim Pract. 2004;7:807-820, viii.

7. Lombardini ED, Hard GC, Harshbarger JC. Neoplasms of the urinary tract in fish. Vet Pathol. 2014;51(5):1000-1012.

8. Ranieri G, Gadaleta CD, Patruno R, Zizzo, Daidone MG, Hansson MG, Paradiso A, Ribatti D. A model of study for human cancer: spontaneous occurring tumors in dogs. Biological features and translation for new anticancer therapies. Crit Rev Oncol Hematol. 2013;88:187-197.

9. Rassnick KM, Gould WJ III, Flanders JA. Use of a vascular access system for administration of chemotherapeutic agents to a ferret with lymphoma. J Am Vet Med Assoc. 1995;206: 500-504.

10. Roberts WG, Klein MK, Loomis M, Weldy S, Berns MW. Photodynamic therapy of spontaneous cancers in felines, canines, and snakes with chloro-aluminum sulfonated phthalocyanine. J Natl Cancer Inst. 1991;83:18-23.

TO BE OR NOT TO BE: CLINICAL SIGNIFICANCE INDEX (CSI) AS A PROPOSED TOOL TO CATEGORIZE THE IMPORTANCE OF INFECTIOUS PATHOGENS IN WILD ANIMALS

Ezequiel Hidalgo-Hermoso, DVM,* Rodrigo Salgado, DVM, Consuelo Vega, and Rocio Lagos, DVM

Parque Zoologico Buin Zoo, Panamericana Sur Km 32, Buin 10460 Chile

Abstract

Carnivora is an order threatened by infectious agents. It is critical to rank the level of importance of pathogens in the health of individuals and populations. We propose a tool, the clinical significance index (CSI), that categorizes the importance of infectious diseases in wildlife, based on scientific evidence. With the objective of proving the utility of this tool, we used canine parvovirus (CPV) and canine distemper virus (CDV), and conducted a systematic literature review of articles published through November 2015 in the International Scientific Indexing (ISI) peer-reviewed journals reported in Pubmed, Scopus and Web of Science. We identified standards for reporting CPV clinical disease: clinical evidence, histopathology and virology direct diagnostics with characterization of a viral strain. For CDV reporting standards were: clinical evidence, histopathology and virology direct diagnostics. We found 10 and 52 reports that corresponded to the standards and qualified diseases/deaths by CPV and CDV respectively. We found evidence of disease and/or death for CPV in canids, felids, viverrids, procyonids, and mustelids. For CDV, evidence was found in canids, felids, viverrids, procyonids, mustelids, hyaenids, otarids, ursids, phocids, and ailurids. We found only one report of CDV in wild/free ranging carnivores and 41 of CDV that met the standard reporting criteria. CPV single cases represented 60% and CDV 25%. Despite a great amount of literature asserting that CPV is a major threat to the health and conservation of wild carnivores, little scientific evidence exists to support this affirmation. We recommend using CSI or other similar tools for prioritizing the importance of pathogens in wild animal health.

Key words: Canine distemper, canine parvovirus, clinical significance index, infectious diseases, prioritize, tool, wild carnivores

VETERINARIAN STAFFING TO COLLECTION-ANIMALS RATIO: HOW DOES YOUR INSTITUTION STACK UP?

Julia E. Napier, DVM* and Douglas L. Armstrong, DVM

Omaha's Henry Doorly Zoo & Aquarium, 3701 S. 10th Street, Omaha, NE 68107 USA

Abstract

From 2007 to 2014, an annual survey was conducted by the Zoo Hospital for Omaha's Henry Doorly Zoo and Aquarium and the Lee G. Simmons Conservation and Wildlife Safari Park, as supportive data to evaluate appropriate staffing for the veterinary department. Eighteen zoological institutions including both Omaha facilities, representing zoos with large collections and geographic similarity were included. The survey was sent to the senior member of the veterinary department and requested number of: veterinarians (including interns and residents), pathologists, veterinary technicians, hospital keepers, nursery staff, administrative assistants, and hospital managers, if those positions existed, full time keepers, and collection animals. Collection numbers were obtained from the published AZA member directory and the institution's registrar. Collection animals included mammals, marine mammals, reptiles, birds, and amphibians. Fish and invertebrates were excluded. The following ratios were obtained with little change in collection numbers unless an exhibit was added or closed: veterinarian to collection, technician to collection, technician to veterinarian, keepers to veterinarian, and animals per keeper. Full time veterinarians, 3 yr residents, 2 yr interns were counted as one veterinarian. Veterinarians with significant administrative responsibilities and interns were counted as ½ of a full clinical position. Technicians per veterinarian were rounded to the nearest ¼ time. Resulting numbers indicated a wide range of variability. Veterinarian to collection animals ranged from 200 to 1870, technicians to collection from 185 to 2992, technician to veterinarian from ½ to 2, keeper to veterinarian from 5 to 43, and animals per keeper from 8 to 108.

ACKNOWLEDGMENTS

The authors would like to thank the following institutions for their ongoing participation in this survey: Chicago Zoological Society - Brookfield Zoo, Cincinnati Zoo & Botanical Garden, Columbus Zoo & Aquarium, Denver Zoological Gardens, Disney's Animal Kingdom, Fossil Rim Wildlife Center, Houston Zoo, Inc., Kansas City Zoo, Lincoln Park Zoo, Los Angeles Zoo and Botanical Gardens, Minnesota Zoological Garden, Pittsburgh Zoo & PPG Aquarium, Saint Louis Zoo, San Diego Zoo, San Diego Zoo Safari Park, and the Smithsonian National Zoological Park.

INTERNATIONAL TRANSPORT OF ZOO ANIMALS AND THE IMPORTANCE OF OVERLOOKING THE BASIC MANAGEMENT TECHNIQUES TO ACCOMPLISH ANIMAL WELLBEING

Patricia M. Rios, MV, Mg, Dipl DESMAN

Universidad Nacional Mayor de San Marcos, FMV, Lima41, Peru

Abstract

The transportation of animals among zoos, aquariums and safari parks is an activity that has increased over time, especially out of necessity of these organizations to secure global involvement of their conservation programs and to guarantee adequate collection plans with good reproductive stock as well as small surplus lists.[4] Basic guidance for proper treatment of zoo animals during transport is given by the World Association of Zoos and Aquariums (WAZA), and the International Air Transport Association (IATA), which is an organization that represents and serves the airline industry.[3,5] The question is whether animal welfare is fully protected during the transport of zoo animals internationally using this basic guidance, especially over long intercontinental distances.[1,2] The aim of this paper is to point out some of the problems that arise during transfers, despite the clearly defined rules and regulations that describe transport of zoological animals. Also we explore whether rules and regulations can be improved by making simple modifications on cage designs or at preshipment management procedures. Therefore this paper illustrates with examples the most common problems related to animal loss during long-distance transportation and provides alternatives (other than drug management) to improve the percentage of safe animal arrivals.

Key words: Cages for transport, wild animal transportation

ACKNOWLEDGMENTS

The author would like to thank Nature Resource Network Sro and especially to Bojana Bobic Gavrilovic and Slobodam Gavrilovic for their good work in the preparations of the animals before shipment.

LITERATURE CITED

1. Garcés L, Cussen V, Wirth H. Viewpoint of animal welfare organizations on the long distance transportation of farm animals. Vet Ital. 2008;44(1):59-69.

2. Grandin T. Assessment of stress during handling and transport. J Anim Sci. 1997;75:249-257.

3. International Air Transport Association (IATA). Live animals regulations manual. Montreal (Quebec): IATA; 2009.

4. Linhart P, Adams DB, Voracek T. The international transportation of zoo animals: conserving biological diversity and protecting animal welfare. Vet Ital. 2008;44(1):49-57.

5. World Association of Zoos and Aquariums (WAZA). WAZA code of ethics and animal welfare. Liebefeld (Switzerland): WAZA Executive Office; 2007.

THE PAST, PRESENT, AND FUTURE OF THE FROZEN ZOO®

Oliver A. Ryder, PhD,[1] Barbara S. Durrant, PhD,[2] and Marlys L. Houck, CLSp(CG)[1]*

[1]Genetics Division, San Diego Zoo Institute for Conservation Research, San Diego Zoo Global, San Diego, CA 92112 USA; [2]Reproductive Physiology Division, San Diego Zoo Institute for Conservation Research, San Diego Zoo Global, San Diego, CA 92112 USA

Abstract

The San Diego Zoo Institute for Conservation Research established 40 yr ago the first zoo-based repository for viable cell cultures, the Frozen Zoo®. Skin biopsies from mammals were collected aseptically, cultured, and viable early passage diploid fibroblast cells were frozen and maintained in liquid nitrogen storage. Early applications focused on chromosomal evaluation for species identification and potential chromosomally-based reproductive problems, resulting in many significant publications. In the intervening decades, the concept of the Frozen Zoo has been expanded, its taxonomic breadth enlarged, and the scope of its applications broadened in ways unimaginable at the time of its initiation. Now comprising more than 23,500 cryoprotected reproductive tissues and gamete samples, as well as frozen tissues for nucleic acid extraction, DNA samples, and frozen fibroblast cell cultures from approximately 10,000 individuals that encompass all classes of vertebrates. Altogether more than and 1000 species are represented rendering the collections of the Frozen Zoo a unique resource. Viable individuals from two endangered species (*Bos gaurus* and *Bos javanicus*) have been cloned from cells in the Frozen Zoo using somatic cell nuclear transfer.[2] The Frozen Zoo is contributing scores of samples for whole genome sequencing projects of endangered species that pave the way for achieving a deeper understanding of aspects of the biology of numerous endangered species.[3] Cells are now banked in the Frozen Zoo from one extinct species and multiple critically endangered species; these cell-based resources could be a source of genetic variation to rescue populations compromised by inbreeding and low population numbers. With our partners, genetic enrichment of the black-footed ferret, *Mustella nigripes*, utilizing frozen cell cultures banked from wild-caught individuals captured in the mid 1980s through somatic cell nuclear transfer (SCNT) cloning is being explored.[5] The northern white rhinoceros, *Ceratotherium simum cottoni*, is at the brink of extinction with only three surviving individuals comprising an aged population of related animals. Previously, we have generated induced pluripotent stem cells (iPSC) from northern white rhinoceros[1] with the intention of using advanced genetic and reproductive technologies to rescue the species from extinction.[4] Other species, such as Arabian oryx, *Oryx leucoryx*, and Somali wild ass, *Equus africanus somaliensis*, and others, may also benefit from initiatives that potentially increase the impact of the Frozen Zoo for maintaining sustainable populations. The need for establishing multiple centers into a global network of wildlife biobanks, especially including countries rich in biodiversity, in order to collect, establish, and maintain resources for global biodiversity conservation efforts will be discussed.

Key words: Cryopreservation, genetic disease, genetic rescue, genome sequencing, global wildlife Biobank

ACKNOWLEDGMENTS

Supported by IMLS, the Future MacDonald Foundation, Revive and Restore, the Caesar Kleberg Wildlife Research Foundation, and the John and Beverly Stauffer Foundation. The authors thank the numerous veterinarians and their institutions for contributing samples.

LITERATURE CITED

1. Ben-Nun IF, Montague SC, Houck ML, Tran HT, Garitaonandia I, Leonardo TR, Wang Y-C, Charter SJ, Laurent LC, Ryder OA, Loring JF. Induced pluripotent stem cells from highly endangered species. Nature Methods 10:829-831. 2011.

2. Friese C. Cloning wild life: Zoos, captivity, and the future of endangered animals. New York (NY): NYU Press; 2013.

3. Koepfli KP, Paten B, Genome 10K Community of Scientists, O'Brien SJ. The Genome 10K Project: a way forward. Annu Rev Anim Biosci.1: 261-282. 2015.

4. Ryder OA, Hermes R, Goeritz F, Durrant B, Stejskal J, Hrudy J, Vahala, J, Loring, JF, Hildebrandt T. The plight of the northern white rhinocewros: Is there still hope to prevent extinction. Proc Int Conf Dis Zoo Wild Anim; 2015. p. 63-64.

5. Wisely SM, Ryder OA, Santymire RM, Engelhardt JF, Novak BJ. A road map for 21st Century genetic restoration: gene pool enrichment of the black-footed ferret. J Hered. 5:581-92. 2015.

SMALL SEEDS TO MIGHTY TRUNKS: BUILDING A COLLABORATIVE PARTNERSHIP TO STRENGTHEN VETERINARY DIAGNOSTIC PATHOLOGY CAPACITY IN UGANDA

Dale A. Smith, DVM, DVSc,[1,2]* Julius Okuni, BVM, MSc, PhD,[3] Michael Cranfield, DVM,[4] Linda J. Lowenstine, DVM, PhD, Dipl ACVP,[4] Sarah Corner, DVM, MS, Dipl ACVP,[5]* and Tanja S. Zabka, DVM, PhD, Dipl ACVP[6]

[1]University of Guelph, Guelph, Ontario N1G2W1, Canada; [2]Smithsonian Institution, Washington, Washington DC 20013-7012 USA; [3]Department of Biomolecular Resources and Biolab Sciences, College of Veterinary Medicine, Animal Resources and Bio-Security, Kampala, Uganda; [4]University of California & Gorilla Doctors, Davis, CA 95616 USA; [5]Michigan State University, East Lansing, MI 48824 USA; [6]Genentech, South San Francisco, CA Genentech, South San Francisco, CA 94080 USA

Abstract

The zoological medicine community is well recognized for its involvement in and support of international capacity building programs. In 2014, Gorilla Doctors supported the 6-mo visit of a veterinary pathologist to Uganda to promote community capacity development in wildlife pathology using previous and current collaborations as stepping stones. Through a series of stakeholder meetings, the concept of a Ugandan Wildlife Diagnostic Pathology System was developed and later expanded to include domestic species in order to facilitate a one-health approach. Existing systems for enhancing wildlife pathology reporting and diagnosis were supported by the Smithsonian Institution and USAID's Emerging Pandemic Threats program. In recognition of the need for continued and broad support for diagnostic veterinary pathology and pathologists in Uganda, the North American Pathology Network was formed. The role of this network, which now has 14 partners, is to share ideas and expertise with and channel resources towards a common Ugandan infrastructure. In the spring of 2015, a Global Health Network (GHN) was proposed by the American College of Veterinary Pathologists (ACVP). As a proof of concept to obtain GHN approval, a partnership was created including the ACVP, Gorilla Doctors, Heifer International, Michigan State University, University of Georgia/USAID Farmer to Farmer Program, and Veterinarians Without Borders to provide field diagnostic and pathology training workshops to livestock and wildlife veterinarians from multiple districts in Uganda. Going forward, the North American Pathology Network will continue to work towards the development of educational and research partnership opportunities, including remote pathology, as well as continued support for the Ugandan pathology infrastructure.

Key words: Capacity building, collaboration, international development, pathology, Uganda

ACKNOWLEDGMENTS

The authors have submitted this abstract on behalf of all collaborators on this project, both in North America and in Uganda. We gratefully acknowledge the support and participation of the following organizations and their members:

North America - American College of Veterinary Pathologists, Charles Louis Davis DVM Foundation, Gorilla Doctors, Heifer International, Johns Hopkins School of Medicine, Michigan State University, Mississippi State

University, San Diego Zoological Society, Smithsonian Institution, Tufts University, United States Department Of Defense's Defense Threat Reduction Agency, University Of California-Davis, University Of Georgia, University Of Guelph, University Of Minnesota, University Of Wisconsin, USAID's Emerging Pandemic Threats Program, USAID's Farmer To Farmer Program, Veterinarians Without Borders, Western University, and The Wildlife Conservation Society.

Uganda - Budongo Conservation Field Station; Chimp Trust Uganda; Conservation Through Public Health; Makerere University (Central Diagnostic Laboratory; College of Veterinary Medicine, Animal Resources and Bio-Security; Institute of Wildlife and Aquatic Animal Resources); Ecohealth Project; Jane Goodall Institute; Makerere University (Central Diagnostic Laboratory; College of Veterinary Medicine, Animal Resources and Bio-Security; Department of Wildlife and Aquatic Animal Resources); *Ministry of Agriculture, Animal Industry and Fisheries;* National Animal Disease Diagnostics and Epidemiology Centre; National Forestry Authority; Ugandan Wildlife Authority, Uganda Wildlife Education Center, and Uganda Wildlife Veterinary Network.

THE APPLICATION OF ONE HEALTH TO FACILITIES, AQUARIUMS AND ZOOS

Michael T. Walsh, DVM

Aquatic Animal Health Program, College of Veterinary Medicine, University of Florida, Gainesville, FL 32610 USA

Abstract

It is difficult to consider a number of areas of health, research, and zoonotic disease investigation without hearing of or talking about the concept of One Health. The Centers for Disease Control and Prevention (CDC) has assembled a history of One Health at its website (http://www.cdc.gov/onehealth/people-events.html), which is a good review to put the idea and its conceptual development in perspective. The recognition that human, animal and ecosystem health are tied together is not a novel concept but the emphasis on creating true collaboration between interested parties in all three areas is a very real effort when the concept is truly adopted, and the goal is to look at the whole set of interactions. Where veterinarians, scientist, and medical doctors have seen that their separate areas of investigation only tell part of the story, and that they need to seek out the complimentary components in others expertise removed from their own, then the potential for rapid diagnosis, action, prevention, and wellness for all become a realistic opportunity. Cooperation within and between these historically competitive areas of medicine and science, humans and animals, is limited even when many use the term openly in public discussion or when seeking funding. The One Health approach is gaining momentum and the idea of shared interest and responsibility usually precedes the development of shared priorities where the three groups unite to make things better in the realm of science and health. These three areas also contribute to the conservation of the three realms as well, catalyzing efforts to maintain the balance in each area.

In looking in a similar way at zoos and aquariums, there is a great benefit in the adoption of One Health within each organization or facility where there is, or should be, a shared sense of responsibility between veterinarians, scientist, curators and administrators as to the interrelationship of health and wellness. At the present time there is a great deal of attention from organizations and the public on the benefits of maintaining animals in managed environments. The sincere efforts to make their lives as complete as possible and contribute to the long term survival of imperiled or at risk species are rarely accepted by some who feel everything with human intentions is “captive” and automatically negative to the wellness of the species in mind. While the truth is not the concern of those that oppose management of animals, the depth and accuracy of the truth is to those who work with them. The implication is that we are not doing right by the animals under our care. The questions that must always be addressed include: are we doing our best, can we do better, and what are the basic needs that need to be better addressed? Are the areas of medicine, management -care and administration working together and on the same page when considering our programs and the environments for the animals involved. Adopting an internal One Health program at each facility should draw the parties that often seem in competition for authority to common priorities as viewed through the needs of the animals. This then catalyzes the potential for rapid response, better design based on physical and mental needs, prevention, and

wellness to become a realistic opportunity and remove the stigma of inadequate management of individuals and species.

Key words: Aquariums, internal, One Health, zoos

PHARMACOKINETICS OF VORICONAZOLE IN TUATARA (*Sphenodon punctatus*)

Sarah A. Alexander, BSc, BVMS, PGCert,[1,2]* Sharon Paterson, BS,[3] Nick Holford, MB, ChB, MSc, FRACP,[4] Merran Govendir, BVSc, PhD, MACVSc, Med, fHERDSA,[5] Andrew McLachlan, BPharm, PhD, FPS, FACP, MCPA, MSHPA,[6] Richard Jakob-Hoff, BSc, BVMS, MANZCVS,[1] and Kristin Warren, BSc, BVMS, PhD, Dipl ECZM[2]

[1]Auckland Zoo, Western Springs 1022, New Zealand; [2]School of Veterinary and Life Sciences, Murdoch University, Murdoch, WA 6168 Australia; [3]Toxicology, Canterbury Health Laboratories, Christchurch 8011, New Zealand; [4]Department of Pharmacology & Clinical Pharmacology, University of Auckland, Auckland 1142, New Zealand [5]Faculty of Veterinary Science, University of Sydney, Camperdown, NSW 2050 Australia; [6]Faculty of Pharmacy, University of Sydney, Camperdown, NSW 2050 Australia

Abstract

Voriconazole is a second-generation triazole antifungal agent that is increasingly being used to treat dermal and systemic mycotic infections in reptiles, though pharmacokinetic studies in reptiles are limited.[1-3] Tuatara (*Sphenodon punctatus*) at two captive institutions in New Zealand have been diagnosed with dermatomycosis caused by the emerging fungal pathogen, *Paranannizziopsis australasiensis* (PA), necessitating development of an appropriate treatment protocol. The objective of this study was to determine the pharmacokinetics of voriconazole in tuatara at 12 and 20 degrees Celsius, as these temperatures represent the lower and upper limits of the tuatara's preferred optimal temperature zone.

Single dose pharmacokinetic studies were undertaken in four tuatara. Voriconazole was administered at 5 mg/kg orally, and plasma samples were collected 2, 4, 8, 12, 24 and 48 hr post administration. Animals first completed the study at 12ºC, and after a suitable washout period, repeated the study at 20ºC. Pharmacokinetic modelling using NONMEM was then performed to determine a suitable dosing regimen for multiple dose studies. Multiple dose pharmacokinetic studies were undertaken in six tuatara at 12ºC over a period of 8 wk, then again at 20ºC after a suitable washout period.

Plasma levels of voriconazole were determined and the pharmacokinetics calculated. Based on these data, voriconazole reaches plasma concentrations above the MIC of New Zealand PA isolates in tuatara. Presumed induction of liver enzymes towards the end of the treatment period was observed, and significant variations in pharmacokinetics with temperature were documented.

Key words: Pharmacokinetics, *Sphenodon punctatus*, tuatara, voriconazole

ACKNOWLEDGMENTS

The authors would like to thank the Ectotherms team at Auckland Zoo for their assistance in the care of these animals.

LITERATURE CITED

1. Gibbons PM. Therapeutics. In: Mader DR, Divers SJ (eds.). Current therapy in reptile medicine and surgery. St Louis (MO): Saunders Elsevier; 2014. p. 57-69.

2. Hellebuyck T, Baert K, Pasmans F, Van Waeyenberghe L, Beernaert L, Chiers K, De Backer P, Haesebrouck F, Martel A. Cutaneous hyalohyphomycosis in a girdled lizard (*Cordylus giganteus*) caused by the *Chrysosporium* anamorph of *Nannizziopsis vriesii* and successful treatment with voriconazole. Vet Dermatol. 2010;21:429-433.

3. Van Waeyenberghe L, Baert K, Pasmans F, Van Rooij P, Hellebuyck T, Beernaert L, De Backer P, Haesebrouck F, Martel A. Voriconazole, a safe alternative for treating infections caused by the *Chrysosporium* anamorph of *Nannizziopsis vriesii* in bearded dragons (*Pogona vitticeps*). Med Mycol. 2010;48:880-885.

HEALTH SURVEY INCLUDING SELECTED BLOOD PARAMETERS IN THE SLENDER SNOUTED CROCODILE (*Mecistops cataphractus*) AT THE ABIDJAN ZOO IN CÔTE D'IVORIE

Carol Bradford, MS, DVM, Dipl ACZM* and Matt Eschenbrenner

Albuquerque BioPark, Albuquerque, NM 87102 USA

Abstract

The African slender-snouted crocodile (*Mecistops cataphractus*) is an Appendix 1 Convention on International Trade in Endangered Species of Wild Fauna and Flora (CITES) species, listed as critically endangered by the International Union for Conservation of Nature (IUCN) red list and is now considered to be 2 different species, a Central African and a West African lineage.[4,5] The Zoo National d'Abidjan in Côte d'Ivorie holds the world's largest captive population of slender-snouted crocodiles at 36 adults, 16 yearlings, and 23 hatchlings.

Twelve yearling and twelve adult slender-snouted crocodiles at the Abidjan Zoo were restrained for physical exam, body condition scoring, and venipuncture in September, 2015. Blood was drawn for analysis using an I-stat (Abaxis®) with CG8+ cartridges. The adult crocodiles appeared in good general health and demonstrated blood values similar to those of other reptiles, but the yearlings had significantly low ionized calcium values and low hematocrit and hemoglobin levels.[1,3] One yearling crocodile displayed intermittent symptoms of weakness and tetany which may be due to hypocalcemia. Another significant finding of the health survey was the discovery that all of the yearling crocodiles are male. As *Mecistops cataphractus* is a species in which temperature-dependent sex determination is present, an incubator with a temperature gradient or using two incubators is crucial to the development of a balanced gender ratio in the offspring.[2]

These findings may dramatically improve the health of the crocodiles. They may also help to ensure a balanced sex ratio in future clutches.

Key words: African slender-snouted crocodile, hypocalcemia, ionized calcium, *Mecistops cataphractus,* temperature-dependent sex determination

ACKNOWLEDGMENTS

The authors thank the staff at the Zoo National d'Abidjan for their care of and assistance with the crocodiles and the New Mexico BioPark Society for funding for travel.

LITERATURE CITED

1. Dennis PM, Bennett RA, Harr KE, Lock BA. Plasma concentration of ionized calcium in healthy iguanas. J Am Vet Med Assoc. 2001;219(8):1093.

2. Huchzermeyer, FW. Crocodiles: biology, husbandry and diseases. Cambridge (MA): CABI Publishing; 2003.352p.

3. International Species Information Systems Reference Ranges for Physiological Values in Captive Wildlife. [CD-ROM] Eagan (MN): International Species Information Systems; c2013.

4. IUCN Crocodile Specialist Group. [Internet]. [Cited 2015 10 Nov]. Available from http://www.iucnredlist.org/details/5660/0

5. Shirley MH, Vliet KA, Carr AN, Austin JD. Rigorous approaches to species delimitation have significant implications for African crocodilian systematics and conservation. Proc. R. Soc. B. 2014;281.

DIAGNOSIS OF RANAVIRUS USING BONE MARROW HARVESTED FROM MORTALITY EVENTS IN EASTERN BOX TURTLES (*Terrapene carolina carolina*)

Claire E. Butkus, BS,[1]* Matthew C. Allender, DVM, PhD, Dipl ACZM,[1] Laura A. Adamovicz, DVM,[1] and Christopher A. Phillips, PhD[2]

[1]Wildlife Epidemiology Lab, Department of Comparative Biosciences, College of Veterinary Medicine, University of Illinois, Urbana, IL 61802 USA; [2]Illinois Natural History Survey, Champaign, IL 61820 USA

Abstract

Frog virus-3 like ranavirus (FV3) causes significant morbidity and mortality in many species of chelonians. FV3 infection has been documented in eastern box turtles (*Terrapene carolina carolina*) in many states, and is a disease of conservation concern for this vulnerable species.[4,5] Mortality events in free-ranging box turtles have been reported, however turtles skeletonize rapidly after death due to exposure to the elements and the action of scavengers leaving little soft tissue for diagnostic testing.[1,3] There is clear utility for an FV3 diagnostic test that can be performed on skeletal remains, as it is an important differential diagnosis for high mortality outbreaks of free-living box turtles. In this study, a technique to harvest bone marrow from skeletonized box turtle shells was developed. The bone marrow samples were tested for FV3 DNA using an established FV3 TaqMan quantitative PCR assay.[2] Shells (n = 96) collected from box turtle mortality events in central Illinois from 2011-2015 were tested. Fifteen turtles were positive for FV3. Concurrent perimortem FV3 testing was performed on oral swabs, tissue or whole blood for fourteen of the individuals. Three of the fourteen individuals tested positive for FV3 in both bone marrow and perimortem samples, nine individuals were negative on both tests, and two individuals were positive only in bone marrow (substantial agreement). Our procedure is easily performed and can serve as a means for biologists and wildlife veterinarians to improve post-mortem surveillance for ranavirus in box turtles.

Key words: Bone marrow, eastern box turtle, frog virus-3 like virus, ranavirus, *Terrapene carolina carolina*

ACKNOWLEDGMENTS

The authors would like to thank Grace Archer, Kayla Boers, Marta Rzadkowska, Cari Rasmussen, Teri Lloyd, and the team of veterinary students at the University of Illinois who assisted with the collection of these box turtle shells. The authors would also like to thank Elena Dzhaman for her assistance with the lab work associated with this project.

LITERATURE CITED

1. Allender MC, Mitchell MA, McRuer D, Christian S, Byrd J. Prevalence, clinical signs, and natural history characteristics of frog virus 3-like infections in eastern box turtles (*Terrapene carolina carolina*). Herpetol Conserv Biol. 2013;8:308-320.

2. Allender MC, Bunick D, Mitchell MA. Development and validation of TaqMan quantitative PCR for detection of frog 3-like virus in eastern box turtles (*Terrapene carolina carolina*). J Virol Methods. 2013;188:121-125.

3. Brunner JL, Storfer A, Gray MJ, Hoverman JT. Ranavirus ecology and evolution: from epidemiology to extinction. In: Gray MJ, Chinchar VG (eds.). Ranaviruses: lethal pathogenesis of ectothermic vertebrates. New York (NY): Springer International Publishing; 2015. p. 71-104.

4. Johnson AJ, Pessier AP, Wellehan JF, Childress A, Norton TM, Stedman NL, Bloom DC, Belzer W, Titus VR, Wagner R, Brooks JW, Spratt J, Jacobson ER. Ranavirus infection of free-ranging and captive turtles and tortoises in the United States. J Wildl Dis. 2008;44:851-863.

5. van Dijk. PP. 2013. *Terrapene carolina* In: IUCN Red List of Threatened Species.

HEALTH ASSESSMENT OF CAPTIVE-RAISED ALLIGATOR SNAPPING TURTLES (*Macrochelys temminckii*) IN A CONSERVATION INITIATIVE IN LOUISIANA, USA

Peter M. DiGeronimo, VMD,[1]* Nicola Di Girolamo, DMV, GPCert, MSc(EBHC),[2] Hughes Beaufrère, DMV, PhD, Dipl ACZM, Dipl ABVP (Avian), Dipl ECZM (Avian),[3] João Brandão, LMV, MS,[4] Beau B. Gregory,[5] Peter Jowett, PhD,[6] Britton J. Grasperge, DVM, PhD, Dipl ACVP,[1] and Javier G. Nevarez, DVM, PhD, Dipl ACZM, Dipl ECZM (Herpetology)[1]

[1]Department of Veterinary Clinical Sciences, Louisiana State University, Baton Rouge, LA 70803 USA; [2]Clinica per Animali Esotici, Centro Veterinario Specialistico (CVS), Rome 00137 Italy; [3]Health Sciences Center, Ontario Veterinary College, University of Guelph, Guelph, ON N1G 2W1 Canada; [4]Center for Veterinary Health Sciences, Oklahoma State University, Stillwater, OK 74078 USA; [5]Coastal and Nongame Resources Division, Louisiana Department of Wildlife and Fisheries, Lake Charles, LA 70601 USA; [6]Louisiana Animal Disease Diagnostic Laboratory, Baton Rouge, LA 70803 USA

Abstract

The alligator snapping turtle (*Macrochelys temminckii*) is a threatened species native to freshwater drainages of the Gulf of Mexico and is protected throughout its range. Being a large-bodied, long-lived, and high trophic level predator, the alligator snapping turtle is an ideal sentinel species for monitoring ecosystems. Commercially purchased alligator snapping turtles were raised in outdoor artificial ponds from hatchlings for release as juveniles in waterways within their historic range in Louisiana, USA. Prior to release, all individuals (n = 34) were subject to a health assessment including physical examination, plasma biochemistry analysis on two tabletop analyzers, blood iron and trace metal (Hg, Pb, Zn) concentrations, and cholinesterase activity as an indicator of organophosphate exposure. Trace metal and organophosphate concentrations were determined from water samples from the ponds in which the turtles were raised. Agreement was poor between plasma biochemical analyses performed on Olympus and Vetscan analyzers. Reference intervals for biochemical analytes were determined based on the Olympus analyzer and were similar to ranges reported from free-ranging populations, although cholinesterase activity was higher.[1] Trace metal concentrations were low as were metal and organophosphate levels in environmental water samples. This pilot study provides baseline data for this population prior to reintroduction. Future recaptures will allow these parameters to be studied over time and may reflect the health of riparian ecosystems in Louisiana and serve as a model for species reintroduction efforts elsewhere.

Key words: Alligator snapping turtle, biochemistry, cholinesterase, ecosystem health, *Macrochelys temminckii*, trace metals

ACKNOWLEDGMENTS

The authors would like to thank the Louisiana Department of Wildlife and Fisheries for their assistance and collaboration.

LITERATURE CITED

1. Chaffin K, Norton TM, Gilardi K, Poppenga R, Jensen JB, Moler P, Cray C, Dierenfeld ES, Chen T, Oliva M, Origgi FC, Gibbs S, Mazzaro L, Mazet J. Health assessment of free-ranging alligator snapping turtles *Macrochelys temminckii*) in Georgia and Florida. J Wildl Dis. 2008;44:670-686.

MEASURING INTRAOCULAR PRESSURE IN WHITE'S TREE FROGS (*Litoria caerulea*) BY REBOUND TONOMETRY: COMPARING DEVICE, TIME OF DAY, AND MANUAL VERSUS CHEMICAL RESTRAINT

Jennifer C. Hausmann, DVM,* Ashley Krisp, BS, Kurt Sladky, MS, DVM, Dipl ACZM, Dipl ECZM, Paul E. Miller, DVM, Dipl ACVO, and Christoph Mans, Dr Med Vet, Dipl ACZM

Department of Surgical Sciences, School of Veterinary Medicine, University of Wisconsin-Madison, WI 53706 USA

Abstract

Ocular diseases reported in frogs include uveitis and glaucoma, which cause changes in intraocular pressure (IOP). The objectives of this study were to characterize the normal IOP for White's tree frogs (*Litoria caerulea)* using two types of rebound tonometers, and to assess whether time of day or restraint method affected IOP. Eighteen frogs were acclimated to a controlled 12-hr light cycle from 6 a.m. to 6 p.m. TonoVet® and TonoLab® tonometers were used to measure IOP in all 18 conscious, unrestrained, ophthalmically normal frogs, at three time points during the day. A subset of 12 conscious frogs, then had IOP measured using TonoVet® under manual or no restraint. Finally, a subset of nine frogs were anesthetized with two different concentrations of MS-222 (0.5 g/L and 2 g/L) and changes in IOP measured with TonoVet® were evaluated. Mean (± SD) IOP values for the TonoLab® (16.8 ± 3.9 mmHg) were significantly higher than TonoVet® values (14.7 ± 1.6 mmHg; $P < 0.01$). TonoVet® IOP values did not significantly change with time of day. TonoLab® values were significantly lower in the evening (4-6 p.m.; 14.5 ± 3.1 mmHg), compared to morning and mid-day measurements (8-10 a.m. and 12-2 p.m.; 18.0 ± 3.8 mmHg; $P < 0.01$). Manual restraint significantly reduced IOP (13.4±1.5 mmHg) compared to no restraint (15.3 ± 1.2 mmHg; $P < 0.01$). Chemical restraint did not cause significant changes in IOP. In White's tree frogs, IOP can be measured with both types of rebound tonometers, but time of day and manual restraint can affect IOP values. Future studies validating both tonometers using manometry are needed.

Key words: Intraocular pressure, *Litoria caerulea,* MS-222, rebound tonometry, restraint, White's tree frogs

LITERATURE CITED

1. Hahn A, Gilmour MA, Payton ME, D'Agostino J, Cole GA. Intraocular pressure in free-ranging anuran species in Oklahoma. J Zoo Wildl Med. 2014;45:686-689.

2. Keller CB, Shilton CM. The amphibian eye. Vet Clin Exot Anim. 2002;5:261-274.

HUMORAL IMMUNE RESPONSE AND PRESENCE OF VIRAL RNA IN TISSUE OF HATCHLING AMERICAN ALLIGATORS (*Alligator mississippiensis*) AFTER VACCINATION WITH A KILLED WEST NILE VIRUS VACCINE

Christine T. Higbie, DVM,[1]* Javier G. Nevarez, DVM, PhD, Dipl ACZM, Dipl ECZM (Herpetology),[1] Alma F. Roy, MS, PhD,[2] and Fabio Del Piero, DVM, PhD, Dipl ACVP[2]

[1]From the Department of Veterinary Clinical Sciences, School of Veterinary Medicine, Louisiana State University, Baton Rouge, LA 70803 USA; [2] Department of Pathobiological Sciences, School of Veterinary Medicine, Louisiana State University, Baton Rouge, LA 70803 USA

Abstract

West Nile virus (WNV) can cause mortalities in captive reared American alligators.[1] A killed WNV vaccine is commercially available (Vetera WNV, Boehringer Ingelheim Vetmedica, Inc., St. Joseph, Missouri, 64506 USA). A case from an alligator farm in Louisiana revealed that tissues of vaccinated animals were positive for WNV by reverse transcriptase polymerase chain reaction (RT-PCR) while non-vaccinated animals were negative suggesting the RT-PCR might detect the vaccine in the tissues. The vaccine product itself was positive for WNV via RT-PCR. This study was designed to determine if vaccination could lead to positive RT-PCR from tissues and evaluate the antibody response. Eighty-one 7-day old, hatchlings were vaccinated with 0.25 ml WNV vaccine and 26 control alligators were injected with 0.25 ml sterile water into the lateral tail musculature on days 1 and 14. Blood was obtained daily from three animals in the treatment group prior to euthanasia and necropsy until all animals were euthanatized (27 days). Thirteen of the control alligators were sampled on day 14 and the remaining were sampled on day 27. WNV titers were obtained via serum neutralization. Real time RT-PCR was performed on the brain, liver, kidney, and tail musculature from each animal. Preliminary results revealed antibodies in both the control and treatment groups but viral RNA was only identified in the treatment group. The results confirm that RT-PCR can detect viral RNA from the vaccine in tissues of vaccinated alligators. The presence of antibodies in the control group without any mortalities suggests maternal transfer of antibodies.

Key words: *Alligator mississippiensis*, American alligator, enzyme-linked immunosorbent assay, reverse transcriptase polymerase chain reaction, vaccine, West Nile virus

ACKNOWLEDGMENTS

The authors would like to thank the Louisiana Department of Wildlife and Fisheries for their support of this research.

LITERATURE CITED

1. Nevarez JG, Mitchell MA, Morgan T, Roy A, Johnson A. Association of West Nile virus with lymphohistiocytic proliferative cutaneous lesions in American alligators (*Alligator mississippiensis*) detected by RT-PCR. J Zoo Wildl Med. 2008;39:562-566.

HARD SCIENCE FOR SOFTSHELLS: CRYOPRESERVING TURTLE SPERM

Susanne Holtze, DVM, PhD,[1]* Peter Praschag, PhD,[2] Shannon DiRuzzo, Dr med vet,[2] Frank Göritz, Dr med vet,[1] Joseph Saragusty, DVM, PhD,[1] and Thomas Bernd Hildebrandt, Dr med vet, HonFRCVS, Dipl ECZM[1]

[1]Leibniz Institute for Zoo and Wildlife Research (IZW), Berlin, 10315 Germany; [2]Turtle Island, Graz, 8054 Austria

Abstract

Softshell turtles (Trionychidae), a family of mainly freshwater dwelling turtles comprise 32 extant species. Their habitat is rapidly declining so not surprisingly, currently 18 of these species are considered threatened. Knowledge of their reproductive biology is limited and assisted reproductive techniques are largely unestablished; however, these techniques may become crucial to the success of conservation efforts. For the first time, successful cryopreservation and thawing of sperm in two species of softshell turtles (*Nilssonia hurum* and *Trionyx triuguis*) at Turtle Island, Graz, Austria, is described. Combining electrostimulation (5-6 cycles; 2-8 V) and manual massage under anesthesia (0.1 mg/kg medetomidine, 7 mg/kg ketamine i.m.), pure seminal fluid fractions, without urinary or fecal contamination were collected. They were of opaque and viscous appearance with respective volumes of 0.2 and 0.8 ml and progressive sperm motility of 65 and 75%; total sperm concentrations approximated 1.0 x 10^6/ml. Three different extenders were tested in dilutions of 1:1-1:3: Berliner Cryomedium based on egg yolk and glycerol; BotuCrio® additionally containing dimethylformamide; and Memphis extender based on trehalose. Memphis extender immediately reduced sperm motility to zero. Fractions diluted in both BotuCrio® and Berliner Cryomedium largely retained motility and were frozen over liquid nitrogen. Sperm was initially immobile at thawing, but after a delay of ~20 min partially regained progressive motility (3 and 5%, respectively). Sperm morphology was assessed microscopically and by electron microscopy. Further optimization of the presented sperm cryopreservation protocol will be of high value for conservation of various chelonian species facing the risk of extinction.

Key words: Electroejaculation, *Nilssonia hurum,* semen extender, softshell turtles (*Trionychidae*), sperm cryopreservation, *Trionyx triuguis*

COMPARING THE SUCCESS OF TWO HORMONAL BREEDING PROTOCOLS IN HOUSTON TOADS (*Anaxyrus houstonensis*)

Rachel A. Jania, BS,[1]* Tyler Parker,[2] Colin Thompson,[2] Vance L. Trudeau, PhD,[3] and Lauren L. Howard, DVM, Dipl ACZM[2]

[1]Cummings School of Veterinary Medicine, Tufts University, North Grafton, MA 01536 USA; [2]Houston Zoo, Inc., Houston, TX 77030 USA; [3]Department of Biology, University of Ottawa, Ontario, Canada, K1N 6N5

Abstract

Successful reproduction of captive-reared amphibians is multi-factorial and depends on stimulation of the hypothalamic-pituitary-gonadal axis. Environmental conditions needed for stimulation are unknown and difficult to reproduce in captivity for many species. To account for this, the Houston Zoo has been breeding the endangered Houston toad (*Anaxyrus houstonensis*) since 2007 with a 5-day protocol using intracoelomic exogenous hormones that resulted in an 88% fertility rate in 2015. This protocol consists of a 100 IU priming dose of chorionic gonadotropin (hCG; Chorulon 5000 IU/ml, Intervet, Inc., Millsboro, Delaware 19966 USA) and ovulatory doses of 500 IU hCG and 16 µg of a synthetic gonadotropin-releasing hormone (GnRH-A; 0.2 mg/ml, Sigma Aldrich, St. Louis, Missouri 63106 USA) in females and spermiation doses of 300 IU hCG and 8 µg GnRH-A in males. Toads are bred once per year and paired using the Houston Toad Controlled Propagation and Genetics Management Plan[1] to maximize genetic diversity. In an attempt to increase fertility rates and increase management efficiency, the Houston Zoo used 32 breeding pairs to compare their current protocol with a shorter, 2-day hormonal protocol called the Amphiplex method.[2] This method consists of priming both males and females with 0.04 µg/g of GnRH-A, followed 24 hr later with 0.4 µg/gm of GnRH-A and 10 µg/gm metoclopramide. The logistics of the two different protocols varied, but no significant differences were found in the fertility rates, clutch size or egg size between the two protocols.

Key words: Amphibian, Amphiplex, *Anaxyrus houstonensis*, breeding, hormone assisted, Houston toad

LITERATURE CITED

1. McHenry DJ, Forstner M.R.J. Houston toad metapopulation assessment and genetics: Data necessary for effective recovery strategies in a significantly fragmented landscape Section 6 #E-76. United States Fish and Wildlife Service; 2009. p. 110.

2. Trudeau VL, Schueler FW, Navarro-Martin L, Hamilton CK, Bulaeva E, Bennett A, Fletcher W, Taylor L. Efficient induction of spawning of Northern leopard frogs (*Lithobates pipiens*) during and outside the natural breeding season. Reprod Biol Endocrinol. 2013;11:14.

PHARMACOKINETICS OF NEBULIZED AND SUBCUTANEOUSLY IMPLANTED TERBINAFINE IN COTTONMOUTHS (*Agkistrodon piscivorus*)

Lauren P. Kane, DVM, MS,[1]* Matthew C. Allender, DVM, MS, PhD, Dipl ACZM,[1] Grace Archer, BS,[1] Katie Leister, DVM,[1] Marta Rzadkowska, BS,[1] and Sherry Cox, MS, PhD[2]

[1]Wildlife Epidemiology Lab, Department of Comparative Biosciences, College of Veterinary Medicine, University of Illinois, Urbana, IL 61802 USA; [2]Department of Comparative Medicine, College of Veterinary Medicine, University of Tennessee, Knoxville, TN 37996 USA

Abstract

Ophidiomyces ophiodiicola, the causative agent of snake fungal disease, is a serious threat to the conservation of several snake populations. Treatment for this disease has not previously been established. The objective of this study was to determine the pharmacokinetic parameters of subcutaneously implanted and nebulized terbinafine hydrochloride as a potential treatment of *Ophidiomyces* in reptiles. Seven adult cottonmouths (*Agkistrodon piscivorus*) were used in single dose trials. Two administration methods new for snakes were utilized: 1) nebulization, which allowed two mechanisms of therapeutic benefit, inhalation and topical, and 2) sustained subcutaneous implantation. Both methods employed less snake handling compared to previous routes of administration. Each snake was nebulized with a terbinafine concentration of 2 mg/ml for 30 min and had blood collected before nebulization and for 6 timepoints through 12 hr after completion. Following a 5-mo washout, the same snakes were administered a subcutaneous implant containing 24.5 mg terbinafine, and had blood collected at baseline, 1 day post injection, and then once weekly, for 1 mo. Plasma for both studies was analyzed by high-performance liquid chromatography. The mean plasma concentrations of nebulized terbinafine peaked between 4 and 8 hr, while the subcutaneously implanted terbinafine peaked at 3 wk and maintained therapeutic for 6 wk or more. In the nebulized samples, a secondary spike was seen in 57% of the snakes, which may be attributed to the two therapeutic routes of nebulization. These methods and doses are recommended as potential treatment options for snake fungal disease in reptiles.

Key words: *Agkistrodon piscivorous,* implant, nebulization, *Ophidiomyces ophiodiicola,* pharmacokinetics, terbinafine

ANESTHETIC EFFICACY OF MS-222 IN WHITE'S TREE FROGS (*Litoria caerulea*)

Ashley R. Krisp, BS,* Jennifer C. Hausmann, DVM, Christoph Mans, Dr Med Vet, Dipl ACZM, and Kurt Sladky, MS, DVM, Dipl ACZM, Dipl ECZM

Department of Surgical Sciences, School of Veterinary Medicine, University of Wisconsin-Madison, WI 53706 USA

Abstract

MS-222 is a commonly used bath anesthetic agent in amphibians, but few studies have demonstrated its pharmacodynamic characteristics.[1] White's tree frogs (*Litoria caerulea*; n = 9) were used in a randomized, complete cross-over study to assess the anesthetic effects of two MS-222 concentrations. Frogs were placed in 0.5 g/L and 2 g/L MS-222 to induce chemical restraint. Heart rate, gular rate, palpebral, corneal, withdrawal, and righting reflexes and spontaneous movement were measured every 5 min. Frogs were removed from the anesthetic solution and rinsed with fresh, dechlorinated water when withdrawal reflex, righting reflex, and spontaneous movement were lost or after 25 min. Heart rate was not significantly different between concentrations of MS-222. Gular rate decreased over time with both concentrations, and at 15 min, mean gular rate was significantly lower for the 2 g/L group ($P < 0.05$). Mild sedation was induced with 0.5 g/L MS-222 and only the palpebral reflex was consistently lost (6/9) in the frogs. Surgical anesthesia was induced in all frogs with 2 g/L MS-222, which caused consistent loss of the palpebral (range: 5-20 min), righting (5-15 min), and withdrawal (5-20 min) reflexes and spontaneous movement (10-20 min). Time ranges from rinsing to regaining reflexes in the 2 g/L group were: palpebral (14-34 min), righting (29-39 min), withdrawal (10-43 min), and spontaneous movement (14-34 min). These results suggest that 0.5 g/L MS-222 can be used for mild sedation to facilitate diagnostic techniques, while 2 g/L MS-222 can be used to induce surgical anesthesia in White's tree frogs.

Key words: Anesthesia, *Litoria caerulea,* MS-222, reflexes, White's tree frogs

LITERATURE CITED

1. Lalonde-Robert V, Beaudry F, and Vachon P. Pharmacologic parameters of MS222 and physiologic changes in frogs (*Xenopus laevis*) after immersion at anesthetic doses. J Am Assoc Lab Anim Sci. 2012;4:454-458.

IDENTIFICATION OF A NOVEL HERPESVIRUS IN FREE-RANGING BLANDING'S TURTLES (*Emydoidea blandingii*) FROM ILLINOIS

Dana M. Lindemann, DVM,[1]* Matthew C. Allender, DVM, MS, PhD, Dipl ACZM,[1] Dan Thompson, BS,[2] Laura Adamovicz, DVM,[1] and Elena Dzhaman, BS[1]

[1]Wildlife Epidemiology Laboratory, Department of Veterinary Clinical Medicine, College of Veterinary Medicine, University of Illinois at Urbana-Champaign, Urbana, IL 61802 USA; [2]Forest Preserve District of DuPage County, Wheaton, IL 60189 USA

Abstract

Blanding's turtles (*Emydoidea blandingii*), an endangered species in Illinois, have experienced range-wide declines because of habitat loss, degradation, and fragmentation.[6,7] In an attempt to counteract these threats, conservation programs initiated in 1996 included "head-starting," radio-telemetry, and mark-recapture studies. While these ongoing projects have had a positive impact on population sustainability, infectious disease threats remain under-studied. Existing conservation programs are primed to introduce pathogen surveillance and health assessment into Blanding's turtle management plans. Herpesvirus outbreaks have been associated with high morbidity and mortality in populations of captive turtles and tortoises worldwide, including Emydids (pond, water, and box turtles).[1,2,4,8] Herpesviruses have also recently been identified in apparently healthy free-ranging Emydid chelonian populations[3,5]; however, the clinical significance of this finding in the absence of an outbreak is currently unknown. Terrapene herpesvirus 1 (TeHV1), Emydid herpesvirus 1 and 2, and Glyptemys herpesvirus 1 and 2 have been identified by consensus primer PCR and subsequent sequencing.[2,5,8] In a preliminary study, the investigators collected combined oropharyngeal/cloacal swabs from apparently healthy radio-telemetered Blanding's turtles in DuPage County, Illinois. A novel herpesvirus was identified via consensus PCR and shared 95% sequence homology with Emydid and Glaptemys herpesviruses. The overall prevalence of this herpesvirus was 10% (n = 20). A quantitative PCR assay has been developed to characterize the epidemiology of this novel herpesvirus in Illinois and the implications it may have on Blanding's turtle conservation efforts, identifying the potential for management changes that improve sustainability.

Key words: Blanding's turtle, chelonian, *Emydoidea blandingii,* herpesvirus, polymerase chain reaction

LITERATURE CITED

1. Cowan M, Raidal S, Peters A. Herpesvirus in a captive Australian Krefft's river turtle (*Emydura macquarii krefftii*). Aust Vet J. 2015;93(1-2):46-49.

2. Jungwirth N, Bodewes R, Osterhaus ADME, Baumgärtner W, Wohlsein P. First report of a new alphaherpesvirus in a freshwater turtle (*Pseudemys concinna concinna*) kept in Germany. Vet Microbiol. 2014;170(3-4):403-407.

3. Kane L, Allender MC, Archer G, Dhazman E, Byrd J. Epidemiology of terrapene herpesvirus 1 in free-ranging box turtles. Proc Annu Conf Amer Assoc Zoo Vet. 2015;166.

4. Ossiboff RJ, Newton AL, Seimon TA, Moore RP, McAloose D. Emydid herpesvirus 1 infection in northern map turtles (*Graptemys geographica*) and painted turtles (*Chrysemys picta*). J Vet Diagn Invest. 2015;27(3):392-395.

5. Ossiboff RJ, Raphael BL, Ammazzalorso AD, Seimon TA, Newton AL, Chang TY, Zarate B, Whitlock AL, McAloose D. Three Novel Herpesviruses of Endangered Clemmys and Glyptemys Turtles. PLoS ONE. 2015;10(4):e0122901.

6. Rubin CS. Ecology and genetics of Blanding's turtles in an urban landscape. University of Illinois at Urbana-Champaign; 2000.

7. Rubin CS, Warner RE, Bouzat JL, Paige KN. Population genetic structure of Blanding's turtles (*Emydoidea blandingii*) in an urban landscape. Biol Conserv. 2001;99(3):323-330.

8. Sim RR, Norton TM, Bronson E, Allender MC, Stedman N, Childress AL, Wellehan JFX. Identification of a novel herpesvirus in captive Eastern box turtles (*Terrapene carolina carolina*). Vet Microbiol. 2015;175(2-4):218-223.

MODIFIED HIDING PLACE-SHIFTING BOX FOR SAFE VETERINARY TREATMENT OF VENOMOUS SNAKES

Maja Lukac, DVM, PhD,[1] Ivan Cizelj, dipl ing agr,[2] and Ivo Peranić[2]*

[1]Faculty of Veterinary Medicine, University of Zagreb, Zagreb 10000, Croatia; [2]Zagreb Zoo, Zagreb 10000, Croatia

Abstract

Daily work with venomous snakes is one of most dangerous tasks for zoo keepers, but also for veterinarians dealing with venomous snakes. In order to minimize risk, hide boxes are widely used. Snakes use them as hiding places, and daily routine is much safer for people dealing with snakes. To minimise the stress for animals and the risk for people dealing with venomous snakes, we have modified the hide box to make it suitable for veterinary treatment of animals. The standard hide box is part of each terrarium. It is made of a wooden plank 50 × 30 ×15 cm in size, with the opening on one side which can be closed by shifting its doors by a hook. The top cover is made of the upper wooden and the lower transparent acrylic plates. Lifting the wooden part with the fixed acrylic one enables safe checking of the animal. For veterinary needs, this standard hide box was modified to be used also as a shifting box. The acrylic panel was modified by drilling holes 6 mm in diameter for drug delivery. Another modification enabled vertical shifting of the acrylic panel by four built-in vertical iron sticks. The animal in the hide box can be gently pressed down by the acrylic panel and the medication can be administered with no direct contact with animal. For more animal safety, the shifting box bottom is covered by a sponge. In that way, stress on the animal from everyday catching for veterinary care is minimized and the safety of the staff is ensured.

SURGICAL EXCISION OF A SALIVARY GLAND NEOPLASIA IN A PATAGONIAN GREEN RACER (*Philodryas patagoniensis*) IN CAPTIVITY IN BRAZIL

Henrique G. Riva, DVM,[1]* Vanessa L. Ribeiro, DVM,[2] Hanna S. Kokubun, DVM,[2] André Luiz M. da Costa, DVM,[2] Viviane Nemer, DVM,[3] Rodrigo A. Réssio, Bsc, MS,[4] Natália C. Fernandes, B.PHARM, MS,[4] and Marcelo P. N. de Carvalho, DVM, MS[5]

[1]Fundación Botánica y Zoológica de Barranquilla, Barranquilla, Atlántico 28800 Colombia; [2]Sorocaba Zoo (Parque Zoológico Municipal Quinzinho de Barros), Sorocaba, São Paulo 18020-268 Brazil; [3]Autonomous Veterinary Pathologist; [4]Adolfo Lutz Institute, Center of Pathology, Department of Pathological Anatomy, São Paulo 13035-420 Brazil; [5]Laboratory of Wildlife Comparative Pathology, Department of Pathology, School of Veterinary Medicine and Animal Science, University of São Paulo, São Paulo 05508-270 Brazil

Abstract

The Patagonian green racer (*Philodryas patagoniensis*) is a brown snake that belongs to the Dipsadidae family. The animal is mostly terrestrial and its color helps this species to camouflage against the soil of grasslands in South America.[3] The aim of this study is to report a clinical case of successful surgical excision of a mass diagnosed as a neoplasia of a salivary gland in a *P. patagoniensis* kept in captivity at the Sorocaba Zoo (Parque Zoológico Municipal "Quinzinho de Barros"). An adult female of the species *P. patagoniensis* presented a nodule near the right hemimandible. The animal was active, eating and defecating normally. The nodule was firm, not mobile, with approximate size of 3 centimeters in diameter, apparently was subcutaneos and the mass could also be seen from the inside of the oral cavity. A radiographic exam was performed to evaluate bone involvement and an ultrasound was done to rule out a caseous formation and to evaluate the mass. The animal was intubated under physical restraint and anesthetized using isoflurane for induction and maintenance. Aseptic preparation was completed using chlorhexidine gluconate 2% over the mass and close areas. A 0.5-cm incision was made between the scales over the region and a dissection was performed surrounding the nodule. The excised mass was immediately fixed in buffed formalin 10% and sent to histopathologic analysis. The surgical wound was closed with nylon 2-0 with a U pattern. The cardiac frequency was monitored using a doppler over the heart region and the respiratory frequency was also monitored with assisted breathing when necessary. After the procedure, meloxicam (Laboratorios PROVET S.A.S, Bogotá, Cundinamarca, 28800, Colombia; 0.2 mg/kg i.m., s.i.d. for 5 days) and enrofloxacin (Genfar S.A., Bogotá, Cundinamarca, 090613, Colombia; 5 mg/kg i.m., s.i.d. for 7 days) were administered. Even after the histopathology results, some doubts remained about the diagnosis, so the samples were sent to the Adolfo Lutz Institute where immunohistochemistry could be performed. The radiography exam showed a soft tissues radiopacity, without any bone involvement. The ultrasound also revealed a mass with soft tissue echogenicity, compatible with a neoplasia. Macroscopically, the lesion had a white color with some brown areas, and a friable consistency with approximately size of 2.5 cm for 1 cm for 0.7 cm. Half an hour after the procedure, the animal was active, with a good post-anesthetic recuperation. In the next couple of weeks, the animal shed and fed normally. The individual appears to remain healthy 1 yr after the procedure and it remains on exhibit. The histopathology revealed a partially encapsulated mass with proliferation of epithelial cells that in some areas formed ducts with the interior full of

eosinophilic amorphous material. In other areas, pseudo-stratification of cells and loss of cell alignment was visible. A discreet pleomorphism was present and the mitotic index was low with 0 to 4 mitotic figures per field (400X). Atypical mitotic figures were rare. The stroma was made of delicate fibrous beams of ductal support. Furthermore, some areas of necrosis were visible with a heterophilic infiltrate. The histopathology report suggested an adenocarcinoma of the Duvernoy's gland; however, the anatomic location of this gland is just caudal to the eyes of the animal and this mass was found just under the mandible.[6] Besides the Durvenoy's gland, supralabial, premaxillary and infralabial glands are also described in *P. patagoniensis*.[4] The last gland mentioned could be the source of the tumor, as the anatomic location is more suitable. Those salivary glands and the Durvenoy's gland are also described in other dipsadid snakes as *Dipsas indica*, *Sibynomorphus mikanii* and in colubrid snakes as *Natrix tessellate.*[1,5] The immunohistochemistry was performed using the technique of enzyme and secondary antibodies conjugated polymer. The following markers were used: cytokeratin cocktail (AE1 and AE3) showing a positive result and an anti-Ki67 antibody (polyclonal) with a negative result. The immunohistochemistry positive results (AE1 and AE3) show the epithelial nature of the mass, suggesting the diagnosis as an adenoma or a well differentiated adenocarcinoma. The authors could not find any reports of adenocarcinoma or adenoma with or without treatment in the genus *Philodryas* or any other ophistoglyphous snake. An adenoma in the Durvenoy's gland was reported in an Indian water snake (*Xenochrophis piscator*), a non-venomous colubrid. As in the present report, the *X. piscator* also presented with a mass under the jaw with growth visible inside the mouth; however, clinical, surgical or post-operative information about the animal are not available, the histopathology findings are comparable to the present report, showing similarities of areas of necrosis, some mitotic figures, proliferation of epithelial cells and differences like absence of pleomorphism, presence of hemorrhages and amphophilic characteristics.[2] The exams associated with the clinical and anatomic information and a similar report suggested the diagnosis of a well differentiated adenocarcinoma of salivary gland. This is the first case report of a successful surgical extraction of an adenocarcinoma in an ophistoglyphous snake. More case reports and studies are required to determine a basis of treatment and a better diagnostic test for this kind of neoplasia in this species and similar animals.

Key words: Dipsadidae, Duvernoy's gland, gland ablation, neoplasia, Patagonian green racer, *Philodryas pagatoniensis*

LITERATURE CITED

1. Akat E, Cakici O, Dincaslan YE, Arikan H. Histochemical and histological investigations on Duvernoy´s gland in *Natrix tessellate* (Squamata: Colubridae). Kafkas Üniv Vet Fak Derg. 2011;17:285-289.

2**.** Gandhe A, Kamdi BP, Pal P, Zade P, Hatekar DN, Nagpure P, Bhandarkar AG, Kurkure NV. Duvernoy´s (Parotid) gland adenoma in Indian water snake (*Xenohcrophis piscator*). Indian J Vet Pathol. 2015;39:191-192.

3. Hartmann PA, Marques OAV. Diet and hábitat use of two sympatric species of *Philodryas* (Colubridae), in south Brazil. Amphibia-Reptilia. 2005;26:25-31.

4. Lopes RA, Contrera MG, da Costa JR, Petenusci SO, Lima-Verde JS. The salivary glads of *Philodryas patagoniensis* Girard, 1857 (Serpentes, Colubridae). A morphological, morphometric and histological study. Arch Anat Microsc Morphol Exp. 1982;71:175-182.

5. Oliveira L, Jared C, Prudente ALC, Zaher H, Antoniazzi MM. Oral glands in dipsadine ¨goo-eater¨ snakes: morphology and histochemistry of the infralabial glands in *Atractus reticulatus, Dipsas indica,* and *Sibynomorphus mikanii*. Toxicon. 2008;51:898-913.

6. Serapicos EO, Merusse JLB. Morfologia e histoquímica das glândulas de Duvernoy e supralabial de seis espécies de colubrídeos opistoglifodontes (Serpentes, Colubridae). Papéis Avulsos de Zoologia. 2006;46:187-195.

ECTOPIC OSSIFICATION AND SOFT TISSUE MINERALIZATION IN CAPTIVE-RAISED EASTERN INDIGO SNAKES (*Drymarchon couperi*)

John F. Roberts, DVM, Dipl ACVP,[1,2]* Paige Roberts, DVM,[2] Sam Rivera, DVM, MS, Dipl ABVP (Avian),[3] Elizabeth W. Howerth, DVM, PhD, Dipl ACVP,[4] Marie E. Rush, DVM, Dipl ACZM,[5] David A. Steen, PhD,[6] and Craig Guyer, PhD[6]

[1]Thompson Bishop Sparks State Diagnostic, Alabama Dept of Agriculture and Industries, Auburn, AL 36831-2209 USA; [2]College of Veterinary Medicine, Auburn University, Auburn, AL 36849 USA; [3]Dept of Veterinary Services, Zoo Atlanta, Atlanta GA 30114 USA; [4]Dept of Pathology, College of Veterinary Medicine, University of Georgia, Athens, GA 30602 USA; [5]Dept of Pathobiology, School of Veterinary Medicine, St. George's University, True Blue, Grenada, West Indies; [6]Dept of Biological Sciences, College of Sciences and Mathematics, Auburn University, Auburn, AL 36849 USA

Abstract

Metabolic bone disease syndrome is an uncommon diagnosis in any snake species.[1] Four captive-raised Eastern indigo snakes (*Drymarchon couperi*), between the ages of 2-4 yr that were propagated for repatriation into a national forest in Alabama, were diagnosed with varying degrees of tissue ossification or mineralization consisting of dysplastic hepatic mineralization (4/4), dermal ectopic ossification (3/4), gastric mineralization (1/4), boney exostosis (3/4) and anal sac ossification (1/4). One snake with clinical presentation of regurgitation was diagnosed by radiographs and surgical biopsy to have extensive hepatic mineralization. Three other snakes were diagnosed at necropsy and had extensive replacement of dermal collagen by islands of well-differentiated trabecular bone. All snakes had multifocal areas of liver with hepatic basement membrane mineralization. Larger focal areas of hepatic mineralization were surrounded by fibrosis. Multifocal areas of dermal ectopic ossification were distributed on the dorsum and ventrum and formed skin ulcers. The incidence of ectopic ossification and soft tissue mineralization in captive raised snakes from genus Drymarchon is currently unknown and the survival rate for affected Eastern Indigo snakes is undetermined. Early detection methods should be used and research into pathophysiology of this disease should focus on captive husbandry and diet.

Key words: *Drymarchon couperi,* Eastern indigo snake, ectopic ossification, hepatic mineralization, metabolic bone disease

ACKNOWLEDGMENTS

Funding was provided by US Fish and Wildlife Service, the US Forest Service, AL Department of Conservation and Natural Resources., Project Orianne, The Orianne Society, Clayton GA.

LITERATURE CITED

1. Klaphake E. A fresh look at metabolic bone diseases in reptiles and amphibians. Vet Clin Exot Anim. 2010;13:375-392.

DERMATITIS-ASSOCIATED MORBIDITY AND MORTALITY, AND SUCCESSFUL TREATMENT IN ENDANGERED HOUSTON TOADS (*Anaxyrus houstonensis*)

Jacobo Romano Noriega, MVZ,[1]* Paul S. Crump, BS,[2] Tyler Parker,[3] and Lauren L. Howard, DVM, Dipl ACZM[3]

[1]Banfield Pet Hospital, Chula Vista, CA 91911 USA; [2]University of New Brunswick - Saint John, Biology Department, Canadian Rivers Institute, Saint John, New Brunswick, E21 4L5 Canada; [3]Houston Zoo Inc., Houston, TX 77030 USA

Abstract

The Houston toad (*Anaxyrus houstonensis*) is the first amphibian that is protected under the U.S. Endangered Species Act and is endemic to the Southeastern region of Texas. It is estimated there are less than 300 individuals remaining in the wild. Since 2007, the Houston Zoo Inc. has been a major participant in the Houston toad recovery project through captive breeding, reintroduction and maintenance of a captive assurance colony in a facility on the Houston Zoo campus. During 2012 and 2013 the Houston toad colony experienced increased morbidity and mortality due to dermatitis of various etiologies, with approximately 114 deaths. An 8-mo time period from September 2012 to April 2013 was selected for detailed analysis to evaluate disease etiology, treatments administered, and success of therapy. During this time period, 52 toads died due to fungal or bacterial dermatitis or a combination of both. An additional 196 toads survived following treatment with oral enrofloxacin (10 mg/kg p.o., s.i.d.), itraconazole baths (0.01% solution × 10-15 min s.i.d.), increased nutrition, or a combination of these therapies.

Key words: Amphibian, *Anaxyrus houstonensis,* dermatitis, Houston toad

ACKNOWLEDGMENTS

The author would like to thank the Houston Zoo Inc. Veterinary staff and Houston toad keepers for providing information needed regarding their animals and for their conservation efforts for this species.

PELVIC LIMB AMPUTATION AND OUTRIGGER WHEEL PROSTHESIS IN A SULCATA TORTOISE (*Geochelone sulcata*)

Michelle C. Whitehead, BSc, DVM,[1]* J. Jill Heatley, DVM, MS, Dipl ABVP (Avian, Reptilian & Amphibian), Dipl ACZM,[1] Bill Bickley, BA, CPO,[2] Jennifer L. Perkins, LVT,[1] and Sharman M. Hoppes, DVM, Dipl AVBP (Avian)[1]

[1] Department of Veterinary Small Animal Clinical Sciences, Texas A&M University, College Station, TX 77843 USA; [2]Pet Artificial Limbs & Supports (PALS), Houston, TX 77035 USA

Abstract

A 3-yr-old female sulcata tortoise (*Geochelone sulcata*) presented with a chronic progressive osteomyelitis and grossly deformed pes of the left pelvic limb that was unresponsive to nociceptive stimuli. Clinical pathology revealed an active heterophilic inflammatory response. Whole body computed tomography identified severe lysis of the left pes and complete minimally displaced fractures of the mid left tibial and fibular diaphyses. Surgical amputation was curative via disarticulation at the left stifle, distal to the femur. Histopathology confirmed severe, chronic, diffuse inflammation of the skin, soft tissue, and bone, with clean surgical margins. Following post-operative care, a novel outrigger wheel prosthetic device was constructed to simulate natural mobility and positively impact her quality of life. Prosthetic devices are an emerging avenue in the veterinary community to assist in improvement of function and life quality.[1,2] This prosthesis was designed to be donned and doffed as needed, whereby a single plastic base is conformed to the plastron and easily secured with two fastening across-the-heart straps over the carapace. The craniolateral aspect of the plastron base fixates a single lateral semi-flexible strut that extends caudally to a rubber wheel set in an outrigger fashion to replace the function of the left pelvic limb. Continued modifications may be necessary to provide optimal support and functionality as she grows. This is the first reported case of an outrigger wheel prosthesis successfully fitted for a tortoise.

Key words: Amputation, *Geochelone sulcata*, osteomyelitis, outrigger wheel device, prosthesis, sulcata tortoise

ACKNOWLEDGMENTS

The authors would like to thank the Department of Small Animal Clinical Sciences at the Texas A&M University Veterinary Teaching Hospital as well as Bill Bickley and the team at Pet Artificial Limbs & Supports (PALS) for their assistance in the care of this tortoise.

LITERATURE CITED

1. Clabaugh KK, Haag M, Hanley CS, Latimer KS, Hernandez-Divers SJ. Undifferentiated sarcoma resolved by forelimb amputation and prosthesis in a radiated tortoise (*Geochelone radiata*). J Zoo Wildl Med. 2005;36(1):117-120.

2. Ueda K, Murakami M, Kato J, Miyahara H, Izumisawa Y. Intervention to improve the quality of life of a bottlenose dolphin that developed necrosis on the tail flukes. J Phys Ther Sci. 2013;25(9):1201-1207.

CASE REPORT: TOXOPLASMOSIS IN A RED KANGAROO (*Macropus rufus*) AND MARA (*Dolichotis patagonum*) IN CAPTIVITY

Nataly Díaz-Ayala, DVM,[1]* Constanza Cabello, DVM,[1] Ezequiel Hidalgo-Hermoso, DVM,[2] and Francisco R. Carvallo, DVM, DCs, Dipl ACVP[1,3]

[1]Department of Animal Pathology, School of Veterinary Science, University of Chile, Santiago 8820808 Chile; [2]Department of Research and Conservation, Buin Zoo, Panamericana Sur Km 32 Buin, Chile; [3]California Animal Health and Food safety Laboratory, San Bernardino, CA 92408 USA

Abstract

Toxoplasma gondii is a protozoa that causes toxoplasmosis, a zoonotic disease with worldwide distribution.[2] This report describes toxoplasmosis in two captive animals of a Chilean zoo: a red kangaroo (*Macropus rufus*) and a mara (*Dolichotis patagonum*). Both animals died in 2012 without premonitory signs. The necropsy displayed unspecific lesions, with pulmonary edema and serosanguineous fluid in abdominal cavity of both animals. Histopathology revealed lesions in different tissues, and parasitic structures consistent with *T. gondii*. In the kangaroo, small numbers of basophilic, round to oval, 2-3 μm long protozoal structures were noted in the heart, brain and lung. Mild mononuclear inflammation was noted. The mara had diffuse lymphoplasmacytic myocarditis with presence of intralesional structures compatible with *T. gondii* tachyzoites. The diagnosis was confirmed with immunohistochemistry. This report adds a new animal species as an intermediary host (mara, *Dolichotis patagonum*) and it is the first one describing pathologic findings of this disease in wild animal species in Chile. Previous studies have reported seropositivity only, with a prevalence of 27.5% in wild animals in zoological gardens.[4] The origin of the infection is unknown, but the transmission probably originated from domestic cats.[5] Finally, macroscopic and microscopic lesions identified in both animals are in agreement with previously described findings by other authors.[1,3,5-10] We highlight the importance of performing routine post mortem examination in captive maras, in order to identify new features of the disease in this species.

Key words: *Dolichotis patagonum, Macropus rufus,* mara, red kangaroo, *Toxoplasma gondii,* toxoplasmosis

ACKNOWLEDGMENTS

We thank the Buin Zoo for allowing us to present these cases and also the Department of Animal Pathology, University of Chile, especially to Miguel Sepulveda and Manuel Carreño for help with our study.

LITERATURE CITED

1. Candfield PJ, Hartley WJ, Dubey JP. Lesions of toxoplasmosis in Australian marsupials. J Comp Pathol. 1990;103:159-167.

2. Dubey JP. Toxoplasmosis of animals and humans. 2nd ed. Boca Ratón (FL): CRC press; 2010. 336 p.

3. Forzán MJ, Frasca S. Systemic toxoplasmosis in a five-month-old beaver, (*Castor canadensis*). J Zoo Wildl Med. 2004;35:113-115.

4. Gorman T, Riveros V, Alcaino H, Salas D, Thiermann E. Helminthiasis and toxoplasmosis among exotic mammals at the Santiago National Zoo. J Am Vet Med Assoc. 1986;189:1068-1070.

5. Harrison TM, Moorman JM, Bolin SR, Grosjean NL, Lim A, Fitzgerald SD. *Toxoplasma gondii* in an African crested porcupine (*Hystrix cristata*). J Vet Diagn Invest. 2007;19:191-194.

6. Jokelainen P, Nylund M. Acute fatal toxoplasmosis in three Eurasian red squirrels (*Sciurus vulgaris*) caused by genotype II of *Toxoplasma gondii*. J Wildl Dis. 2012;48:454-457.

7. Moré G, Pardini L, Basso W, Machuca M, Bacigalupe D, Villanueva MC, Schares G, Venturini MC, Venturini L. Toxoplasmosis and genotyping of *Toxoplasma gondii* in *Macropus rufus* and *Macropus giganteus* in Argentina. Vet Parasitol. 2010;169:57-61.

8. Ochoa-Amaya JE, Ciuoderis-Aponte KA, Lim A, Bolin S, Langohr I. Toxoplasmosis Sistémica en un Canguro Rojo (*Macropus rufus*) Cautivo. Int J Morphol. 2012;30:70-76.

9. Portas TJ. Toxoplasmosis in macropodids: A Review. J Zoo Wildl Med. 2010;41:1-6.

10. Stern A. A retrospective study of disease in captive kangaroos from Oklahoma State University, 1995-2009. J Vet Diagn Invest. 2010;22:324-326.

DENTAL FRACTURE IN A BENNETT'S WALLABY (*Macropus rufogriseus*): CASE PROGRESSION AND DIAGNOSTIC CHALLENGES

Paloma C. Henrique, DVM,[1]* Laura C. Reisfeld, DVM,[1] and Damiana C. F. Pimenta, DVM[2]

[1]Aquário de São Paulo, São Paulo, SP 04275-000 Brazil; [2]Vet Autonomous, São Paulo, SP, Brazil

Abstract

Alterations in the oral cavity are common in wallabies and other macropods. This report is about an adult, female, albino Bennett's wallaby (*Macropus rufogriseus*) with a pouch joey that was housed with other wallabies and red kangaroos (*Macropus rufus*). The animal was observed with anorexia, intense ptyalism and swelling on the lateral right mandible. The animal was chemically restrained (ketamine 4 mg/kg and midazolam 0.2 mg/kg i.m. by hand injection) for clinical examination. Soft tissue swelling in the rostral mandibular region and congestion of the gingiva were observed along with mobility of the mandibular incisors. Complete blood work and thoracic radiographs did not show any significant findings. Culture from the oral cavity yielded *Klebsiella pneumonia* that was sensitive to ceftiofur. Skull radiographs showed a radiolucent line at the region of the mandibular incisors suggestive of a fracture of the lower right incisor with suspected mandible involvement. Treatment was started with long-acting ceftiofur (Excede®, 5 mg/kg i.m.), vitamin E (5 mg/kg s.c.), flunixin meglumine (1 mg/kg i.m.), meloxicam (0.2 mg/kg s.c.) and fluid therapy with a multivitamin and aminoacids. In the following three days, the animal was alert, with no ptyalism, and eating normally during which fluid therapy and meloxicam were continued. On the fourth day the animal was chemically restrained for reevaluation. Intra-oral radiographs confirmed a fracture of the right mandibular incisor with periapical abscess formation and boney reaction. Bacterial culture of the abscess yielded *Moraxella catarrhalis* and *Streptococcus* spp., both sensitive to ceftiofur. Treatment with meloxicam and supportive care were maintained. After 2 days, the animal was anesthetized again for lower incisor extraction. Tramadol (4 mg/kg p.o.) and meloxicam were given for analgesia. The next day the animal was eating normally, was active, and remained stable for the next 13 days. The animal represented due to clinical signs of dyspnea, decreased appetite and lethargy. The animal was well hydrated, had pink mucous membranes but had a foul odor originating from oral and nasal region. Treatment with ceftiofur, tramadol and meloxicam were reinstituted. The following day the animal died. Pyogranulomatous septic bronchopneumonia with fibrinous necrosis was the major finding on histopathologic exam. A post mortem blood culture was positive for *Staphylococcus kloosii.* We hypothesize that this animal's fractured tooth caused hyporexia, anorexia, stress, which in combination with the increased energy expenditure of lactation led to immunosuppression resulting in an acute fatal pneumonia. The major challenges of this case were that 1) hematologic and biochemical diagnostic testing, as well as the thoracic radiographs did not show any signs of alterations and 2) skull radiographs were not sufficiently sensitive, requiring intra-oral dental radiograph techniques for diagnosis.

Key words: Bennett's wallaby, dental fracture, diagnostic challenges, *Macropus rufogriseus*

A SLOTH, ANTEATER AND ARMADILLO WALK INTO THE CLINIC: VETERINARY HUSBANDRY BEHAVIORS IN XENARTHRANS

Dominique L. Keller, DVM, PhD, Dipl ACZM,* Sarah Graham, Tara Jimenez, and Kristina Ellis

Busch Gardens Tampa, Tampa, FL 33612 USA

Abstract

Operant conditioning for veterinary medical procedures can reduce the need for anesthesia, sedation or even manual restraint for sample collection and diagnostic evaluation. Behavioral training for these procedures has been used in animals across many taxa including reptiles, large and small mammals and avians.[1-3] However, one distinctive group of animals in which there is little information available on these techniques is the xenarthrans. Xenarthrans have unique anatomic specializations which can pose challenges for venipuncture and other veterinary procedures. In addition, the sharp claws and teeth in some species can compromise trainer or keeper safety. At Busch Gardens Tampa, staff and veterinarians have developed techniques to allow safe, un-anesthetized venipuncture, ultrasound examination, radiography and basic physical examination in two-toed sloths (*Choloepus* sp.), three-banded armadillo (*Tolypeutes matacus*) and Southern tamandua (*Tamandua tetradactyla*). Many of these procedures are performed in guest viewing areas, so that the procedures serve both a veterinary medical purpose and fulfill our education and outreach mission to inform guests about veterinary care in a zoological setting.

Key words: Armadillo, operant conditioning, tamandua, two-toed sloth, Xenarthra

ACKNOWLEDGMENTS

The authors would like to thank the animal care staff and management for their assistance and support in the care and training of these animals.

LITERATURE CITED

1. Hellmuth H, Augustine L, Watkins B, Hope K. Using operant conditioning and desensitization to facilitate veterinary care with captive reptiles. Vet Clin Exot Anim Pract. 2012;3:425-443.

2. Laule GE, Whittaker M. The use of positive reinforcement techniques in the medical management of captive animals. Proc Am Assoc Zoo Vet and Am Assoc Wildl Vet; 1998. p. 383-387.

3. Mattison S. Training birds and small mammals for medical behaviors. Vet Clin Exot Anim Pract. 2012;3:487-499.

DIAGNOSIS AND MEDICAL MANAGEMENT OF THORACIC ACTINOMYCOSIS AND PULMONARY HYPERTROPHIC OSTEOPATHY IN A RED KANGAROO (*Macropus rufus*)

Patricia E. Kunze, BSc, BVMS,[1]* Carlos R. Sanchez, DVM, MSc,[2] Ashley Pich, BSc, LVT,[2] and Stuart Aronson, MD[3]

[1]University of São Paulo, College of Veterinary Medicine and Animal Sciences, São Paulo, SP 05508-900, Brazil; [2]Fort Worth Zoo, Veterinary Services, Fort Worth, TX 76110 USA; [3]Radiology Associates of North Texas, Fort Worth, TX 76104 USA

Abstract

A 5-yr-old, female, red kangaroo (*Macropus rufus*) with unremarkable medical history presented with swollen distal limbs. On examination, bilateral reduction of range of motion of the humeral radio-ulnar and tibio-tarsal-metatarsal joints was noticed. The animal presented with bilateral, firm, thickening of the radius, ulna, and metatarsal bones with increased local temperature. Radiographs revealed a soft tissue dense thoracic mass, left, cranial to the heart and bilateral extensive areas of periosteal proliferation with palisade appearance of the radius, ulna, and metatarsus. Cytology of the thoracic mass aspirate showed long, slender, branching filamentous-like organisms suggestive of *Actinomyces* spp. Serum electrophoresis (EPH) showed an increase in beta globulins indicative of an underlying inflammatory process. A computed tomography scan of the thorax demonstrated a 6 × 4 cm solid pulmonary parenchymal mass in the left anterior lung, abutting the pleural surface. Although an initial culture was negative, a second thoracic aspirate yielded a pure culture of *Actinomyces* spp. Speciation by PCR yielded *Actinomyces denticolens*. A final diagnosis of pulmonary parenchymal actinomycosis was reached. Treatment consisted of penicillin G benzathine and penicillin G procaine (20 mg/kg s.c., q 5 days) and oral amoxicillin/clavulanic acid (15 mg/kg p.o., s.i.d.) for a total of 90 days. Tramadol (1 mg/kg p.o., s.i.d.) was used for pain control for 30 days. Three months after presentation the animal's clinical condition had remarkably improved; the mass had started to calcify and the EPH had normalized. This is the first report of an ante-mortem diagnosis and successful medical management of secondary pulmonary hypertrophic osteopathy (PHO) associated with thoracic actinomycosis in a marsupial. Primary HO is a hereditary disease and has only been described in humans; secondary HO develops in association with a primary chronic intra- or extra-thoracic lesion, and has been the only form of HO described in animals.[1]

Key words: *Actinomyces* spp., *Macropus rufus*, red kangaroo, secondary hypertrophic osteopathy, thoracic actinomycosis

ACKNOWLEDGMENTS

The authors would like to thank the keepers at the Fort Worth Zoo for their assistance managing this case.

LITERATURE CITED

1. Lenehan TM, Fetter AW. Hypertrophic osteopathy. In: Newton CD, Nunamaker DM (eds.). Textbook of small animal orthopaedics, 1st ed. Philadelphia (PA): Lippincott Williams & Wilkins; 1985 [cited on 2015 November 26]. Available from: http://cal.vet.upenn.edu/projects/saortho/chapter_51/51mast.htm

KOALA (*Phascolarctos cinereus adustus*) DIGIT AMPUTATION DUE TO DEEP CRYPTOCOCCOSIS

Teresa Lobo Fernandes, DVM,[1]* Rui Bernardino, DVM,[1] and Hugo Pissarra, MD, DVM, MSc[2]

[1]Jardim Zoológico e de Aclimação de Lisboa, Estrada de Benfica 158-160, 1549-004 Lisboa; [2]CIISA, Laboratório de anatomia patológica, Faculdade de Medicina Veterinária, Universidade Técnica de Lisboa, Portugal

Abstract

Cryptococcosis is an important systemic mycosis of animals and humans. It is the second most common infectious disease in koalas, particularly in captive populations.[1]

The most common result from infection with *Cryptococcus* spp. in koalas is the establishment of colonisation of the nasal passages or subclinical localised tissue invasion of the sinonasal region. Clinical disease is usually associated with high environmental loads but subclinical cryptococcosis is likely to be an important entity in all species.

In February 2015 a 5-yr-old koala male, presented with a swollen digit in the left hand. Antibiotic therapy was started with cephalexin, (Ceporex Vet® 180 mg/ml, Intervet Portugal, Schering-Plough, Animal Health) and dexamethasone (Dexacortin® 2 mg/ml, Intervet Portugal, Schering-Plough, Animal Health). Only 2 days after initiating treatment the digit was even more swollen. On radiographic examination it was possible to identify osteolysis of the phalanges and at this time a tumour was suspected. Due to this rapid progression and apparent aggressiveness of disease, the III digit of the left hand was surgically removed and sent to the laboratory of anatomic pathology of the Faculty of Veterinary Medicine (Lisbon University).

The result was deep mycosis by *Cryptococcus* sp. causing skin ulceration and periosteal invasion. At this point, treatment with itraconazole (Itrafungol® 10 mg/ml, Veterinaria Esteve, Portugal) was begun at the dosage of 20 mg/kg. The animal has had no other clinical sign of disease.

According to a retrospective study[2] about 80% of cases affect the respiratory system, with only 7% of the cases affecting the skin and no report of bone involvement (except nasal bones). To our knowledge this is the first report of non-nasal bone invasion by *Cryptococcus* sp.

Key words: Cryptoccocosis, digit amputation, koala, *Phascolarctus cinereus adustus*

LITERATURE CITED

1. Australian Wildlife Health Network. Koala cryptococcosis fact sheet.

2. Krockenberger MB, Canfield PJ, Malik R. *Cryptococcus neoformans var. gattii* in the koala (*Phascolarctos cinereus*): a review of 43 cases of cryptococcosis. Med Mycol. 2003;41(3):225-34.

3. Krockenberger MB, Stalder K, Malik R, Canfield P. Cryptococcosis in Australian wildlife. Microbiol Aust. 2005;69-71.

SEROLOGIC ASSESSMENT OF DISEASE EXPOSURE AND VACCINE EFFICACY OF WILD RACCOONS (*Procyon lotor*) AND OPOSSUM (*Didelphis virginiana*) WITHIN A ZOOLOGIC INSTITUTION

Dennis Michels, VMD,[1]* Britany Rizzo, DVM,[2] Kim Rainwater, DVM,[1] Ric Berlinski, DVM,[1] and Yousuf Jafarey, DVM[3]

[1]Wild Toledo Program, Toledo Zoo & Aquarium, Toledo OH 43614 USA; [2]Akron Zoo, Akron OH 44307 USA; [3]Zoo Miami, Miami FL 33177 USA

Abstract

Raccoons (*Procyon lotor*) and Virginia opossum (*Didelphis virginiana*) are two common species that inhabit the urban ecosystem found in most large cities within the United States and can act as a reservoir for infectious disease and creating a potential risk factor for captive animals within zoological parks.[1-3] Over 3 yr, the serum of 36 raccoons and 18 opossums that were captured, vaccinated, and released were analyzed for exposure to several clinically significant disease agents: rabies, canine distemper, canine parvovirus, canine adenovirus 1, feline panleukopenia, *Toxoplasma gondii*, and *Leptospira interrogans*. Animals captured multiple times were retested to evaluate the effect of commercial canine vaccines on serum titers. Amongst raccoon samples, 90% were positive for exposure to feline panleukopenia, 31% for canine parvovirus, 8% for canine distemper virus, and none for rabies. 28% of raccoons sampled for *Leptospira interrogans* were positive and included six animals for *L. grippotyphosa*, and one animal for *L. ictohemorrhagica*, *L. automnalis*, *L. bratislava*, and *L. canicola* simultaneously. No positive results for any infectious agent were detected in the serum from sampled opossum. Vaccination with commercial canine vaccines had little to no effect on serum titer levels for raccoons, but results were limited by a small sample size (n = 8). Thus, raccoons in the area were found to be exposed to several disease agents of clinical importance to captive zoo species and inoculation with commercial vaccine products appeared minimally effective at creating immunity within the population. Opossum in contrast, showed no exposure and are most likely of minimal risk to zoo animals with regard to these diseases.

Key words: Canine adenovirus, canine distemper, canine parvovirus, *Didelphis virginiana,* feline panleukopenia, *Leptospira interrogans*, *Procyon lotor*, rabies virus, *Toxoplasma gondii*

ACKNOWLEDGMENTS

The authors would like to thank the staff of Wild Toledo and the veterinary technicians at the Toledo Zoo for the capture, care, and release of study animals.

LITERATURE CITED

1. Gardner A, Sunquist M. Opossum. In: Feldhamer G, Thompson B, Chapman J (eds). Wild mammals of North America, 2nd ed. Baltimore (MD): The Johns Hopkins University Press; 2003. p. 3-29.

2. Gehrt, S. Raccoon (*Procyon* and *Allies*). In: Feldhamer G, Thompson B, Chapman J (eds). Wild mammals of North America, 2nd ed. Baltimore (MD): The Johns Hopkins University Press; 2003. p. 611-634.

3. Junge, RE, Bauman K, King M, Gompper M. A serologic assessment of exposure to viral pathogens and *Leptospira* in an urban raccoon (*Procyon lotor*) population inhabiting a large zoological park. J Zoo Wildl Med. 2007;38(1):18-26.

BACK TO AFRICA: TRANSLOCATION OF EUROPEAN CAPTIVE ANIMALS TO A SEMI-FREE EXHIBIT IN DJIBOUTI

Baptiste Mulot, DMV,[1]* Romain Potier, DMV,[2] Thierry Petit, DMV,[3] and Bertrand Lafrance, DMV[4]

[1]ZooParc de Beauval, 41110 Saint-Aignan, France; [2]FauneVet, 44200 Nantes, France; [3]Zoo de la Palmyre, 17570 Les Mathes, France; [4]Refuge DECAN, Djibouti ville, Djibouti

Abstract

In 2009, ZooParc de Beauval launched its conservation and research association Beauval Nature. One of the main programs of the association focuses on the Republic of Djibouti and aims to protect the flora and fauna of Djibouti and to educate the people about conservation. The first action was to create an educational display for the people of Djibouti based primarily on an emblematic species supposed to have disappeared from the country: the Somali wild ass (*Equus asinus somalicus*). An additional area was dedicated to the exhibition of some specimens born in Europe: seven Somali wild asses, two Grevy's zebras (*Equus grevyi*) and two East African oryx (*Oryx gazella beisa*) were transported from their country of origin through Paris to the reserve in 2009. Despite the lack of preshipment health requirements from the Djibouti government, the animals went through a complete health screening protocol (Ruminants: tuberculosis, brucellosis, leucosis and infectious bovine rhinotracheitis (IBR) testing; pasteurellosis, clostridiosis and rabies vaccination; country, area or institution certified free from peste des petits ruminants, foot and mouth disease, rinderpest, contagious bovine pleuropneumonia, epizootic hemorrhagic disease, Rift valley fever, vesicular stomatitis, tuberculosis, paratuberculosis, rabies and anthrax. Equids: infectious anemia, dourine, glanders, African horse sickness, strangles and equine viral arteritis testing; rabies vaccination; country, area or institution certified free from African horse sickness, dourine, glanders, equine encephalomyelitis equine infectious anemia, vesicular stomatitis rabies, bacterial anthrax and contagious metritis). They were accompanied by a veterinarian during transportation until release. A year later, all the animals were immobilized for a complete health check-up and a comprehensive disease test panel (Ruminants: brucellosis, foot-and-mouth disease, bluetongue, equine hemorrhagic disease, vesicular stomatitis, leucosis, infectious bovine rhinotracheitis, malignant catarrhal fever, babesiosis, theileriosis, trypanosomiasis, Rift valley fever, Q fever, blood parasites, toxoplasmosis, rinderpest, peste des petits ruminants, contagious bovine pleuropneumonia, contagious caprine pleuropneumonia, sheep pox and goat pox, lumpy skin disease. Equids: equine infectious anemia, dourine, equine viral arteritis, glanders, African horse sickness, vesicular stomatitis, strangles, equine piroplasmosis, rhinopneumonia, babesiosis, theileriosis, trypanosomiasis, Q fever, West Nile virus, leptospirosis). As official information about the health status of domestic animals in Djibouti is sparse and OIE reports records incomplete, local domestic horses (*Equus caballus*), domestic donkeys (*Equus asinus*), dromedary camels (*Camelus dromedarius*) and domestic goats (*Capra aegagrus hircus*) were sampled in the same time frame to assess the sanitary status of the area. Despite the presence of several contagious diseases among the domestic fauna and the proximity with the translocated European captive animals due to ranching, the latter remained healthy and free from severe diseases.

Key words: Ass, disease, Djibouti, domestic, oryx, zebra

MANAGING REPRODUCTION AND SOCIAL DYNAMICS IN A NAKED MOLE RAT (*Heterocephalus glaber*) COLONY: WHICH CONTRACEPTION IS BEST?

Janis A. Raines, DVM,[1]* Elizabeth Bickenese, DVM, MPVM, cVMA,[2] and Linda Penfold, PhD[3]

[1]Dallas Zoo and Children's Aquarium at Fair Park, Dallas, TX 75243 USA; [2]San Diego Zoo, San Diego, CA 92112 USA; [3]South-East Zoological Alliance for Reproduction and Conservation, Yulee, FL 32097 USA

Abstract

Naked mole rats (*Heterocephalus glaber)* are a small eusocial species with a unique reproductive strategy whereby only the dominant queen reproduces, with the other females in the colony assisting with pup rearing, nest defense and colony maintenance. Under managed care, queens can reproduce every couple of months, producing litters from 1-27 pups.[4] The dominant queen suppresses the other females using pheromones, but when the colony grows too large, or the queen is removed, other females can develop into queens and start reproduction.[1-3] New colony formation or the challenge of the queen by an underling female can result in significant colony unrest. The resultant multiple deaths create significant animal welfare concerns. With limited space, reproduction must be controlled, but it was unknown whether reducing circulating sex steroid hormones would remove the queen from her dominant role, allowing another female to become reproductively active, and potentially create colony unrest. At the same time, removing females for surgical sterilization can also be challenging as re-introduction of animals to a colony is not always successful (Table 1). These compiled case studies investigate surgical (tubal ligation in a queen and a hysterectomy in a subordinate female), hormonal (melengesterol acetate implant [MGA] 0.15 mg/kg) and vaccinal (porcine zona pellucida [PZP] at 0.2 ml i.p. of PZP emulsion) approaches to contraception in naked mole rats while maintaining the social structure. Interestingly, although MGA and surgery were predicted to be less effective than PZP, all methods of contraception were effective in preventing reproduction and allowed the females to be reintroduced to the colony post-surgery. A flank hysterectomy where the uterus was removed from a single incision sparing the ovaries was accomplished in a subordinate female who was introduced without incident following the procedure. The tubal ligation surgery was by a more traditional ventral midline approach, again with successful return to the colony. The female treated with MGA had an average of 10 pups/yr for 4.5 yr but following placement of implant there has been no pups approaching 24 mo to date. The queen treated with a PZP vaccine regime of one injection followed by a booster injection 2 wk later, had previously had 3-4 litters of 14 pups/litter/yr for multiple years. With the initial series and an annual PZP booster schedule there have been no pups to date. Results demonstrate multiple successful approaches to controlling reproduction in naked mole rats while maintaining colony structure, providing clinicians with a range of options for managing naked mole rats in captivity.

Key words: Contraception, *Heterocephalus glaber*, MGA, naked mole rats, PZP

LITERATURE CITED

1. Braude S. Dispersal and new colony formation in wild naked mole-rats: evidence against inbreeding as the system of mating. Behav. Ecol. 2000;11:7-12.

2. Cisek D. New colony formation in the "highly inbred" eusocial naked mole-rat: outbreeding is preferred. Behav. Ecol. 2000;11:1-6.

3. Margulis SW, Saltzman W,Abbott DH. Behavioral and hormonal changes in female naked mole-rats (*Heterocephalus glaber*) following removal of the breeding female from a colony. Horm Behav. 1995; 29:227-247.

4. Nowak, RM. Rodentia. In: Walker's Mammals of the World 6th ed. Baltimore (MD): The Johns Hopkins University Press; 1999. p. 1642-1644.

Table 1. Techniques for re-introducing naked mole rats into colony post-procedure.

- Attempt to wear latex gloves at all time while handling animals to reduce scent transmission.
- Do not perform surgical prep with fragrance containing items.
- If animal does not have transponder, then can temporarily identify using a marker for any follow-up monitoring.
- Remove multiple animals from colony and re-introduce lone animal to that group first, then re-introduce entire group.
- Maximum time out of colony no more than 2 hr.
- Have soiled shavings available so animal can be scented with them prior to returning to colony.

WHAT RISK DO PROGRAM ANIMALS POSE TO OUR COLLECTIONS?

Edward C. Ramsay, DVM, Dipl ACZM and Vanessa Rabito, BA*

Department of Small Animal Clinical Sciences, College of Veterinary Medicine, University of Tennessee, Knoxville, TN 37996 USA

Abstract

Program animals are members of a zoo's collection which typically leave zoo grounds for presentations at schools, clubs, and other venues. These program animals might also be used on-grounds for keeper chats, 'meet and greet' presentations, and donor events. Association of Zoo and Aquariums' guidelines recommend these animals be housed, and cared for, separate from the remainder of the collection; however, maintaining this separation is difficult, especially in small collections with limited keeper staff. To ascertain the risk the Knoxville Zoo's program animals pose to the remainder of the collection, medical and necropsy records for all the animals housed in the Program Animal Building, between 1 January 2010 and 15 October 2015, were reviewed for signs and diagnoses of infectious diseases. One hundred eighteen animals' and four naked mole rat colonies' records were reviewed. Fifteen animals or colonies had signs (diarrhea, respiratory signs, or skin lesions) or diagnoses compatible with infectious disease in their medical records, and 33 animals, including eight of those with signs identified in medical records, had lesions suggestive of infectious disease. All definitive diagnoses of infectious disease were for internal parasites; none of which could have been acquired off-zoo grounds. Our review identified no infectious diseases in the Knoxville Zoo's program animals of potential harm to the existing collection, during the study period. We suggest the risk these animals pose to the collection is limited, and justification for isolation of these animals from the remainder of the collection is dubious.

Key words: Biosecurity, program animals, quarantine

EVALUATION OF THE IMPACT OF INVASIVE BLACK RATS (*Rattus rattus*) ON MALAGASY ENDEMIC RODENTS: HABITAT OCCUPANCY AND PARASITISM

Emilie Ribault,[1,2]* Fidisoa T. Rasambainarivo, DVM, MSc,[3,4] Alexis Ribas, PhD[5] and Emmanuelle Gilot-Fromont, DVM, PhD, Dipl ECZM (WPH)[1,6]

[1]Vetagro-Sup Campus Vétérinaire, Université de Lyon, Marcy-l'Etoile, 69280 France; [2]Manchester Metropolitan University, Manchester, M15 6BH UK; [3]University of Missouri Saint-Louis, Saint-Louis, MO 63121 USA; [4]Madagascar Fauna and Flora Group, Toamasina, 501 Madagascar; [5]Biodiversity Research Group, Udon Thani Rajabhat University, Udon Thani, 41000 Thailand; [6]UMR CNRS 5558 Laboratoire de Biométrie et Biologie Evolutive, Université Lyon 1, Villeurbanne, 69100 France

Abstract

Madagascar has a unique rodent diversity which invasive black rats (*Rattus rattus*) are thought to threaten in several natural reserves.[1-3] In Betampona Natural Reserve (BNR), guides' observations have revealed an important decrease of the red forest rat (*Nesomys rufus*) population since 2008 while the black rat population is increasing within the forest and the surrounding villages (BNR staff pers. com.). In order to better assess the impact of black rats in terms of habitat occupancy and parasitism, 66 Sherman traps were used to capture rodents at 11 sites corresponding to different habitat types and altitudes. Camera traps were also employed to assess the presence of endemic and invasive carnivores at each capture site. Coproscopy and blood smears were performed to evaluate parasite diversity and load in the trapped rodents. 63 black rats were captured during 39 trap nights. They were mostly found in the village, in degraded and secondary forests, at an altitude of less than 405m, and were not encountered in primary forest. Black rat occupancy was estimated at 73% among the sites and was not affected by the presence of carnivores. 85% of the rats were infested with *Trichostrongylid* nematode parasites. Parasite load was not significantly different between sexes but was significantly influenced by the interactive effect of age classes and habitat types. Unfortunately, no endemic rodents were captured during the study and further research should be conducted to investigate this apparent absence.

Key words: Black rat, endemic rodents, Madagascar, occupancy modeling, parasitism, *Rattus rattus*

ACKNOWLEDGMENTS

The authors would like to thank the staff of the NGO Madagascar Fauna and Flora Group for its valuable contribution to the project.

LITERATURE CITED

1. Goodman SM. *Rattus* on Madagascar and the dilemma of protecting the endemic rodent fauna. Conserv Biol. 1995;9:450-453.

2. Goodman SM, Andrianarimisa A, Olson LE, Soarimalala V. Patterns of elevational distribution of birds and small mammals in the humid forests of Montagne d'Ambre, Madagascar. Ecotropica. 1996;2:87-98.

3. Laakkonen J, Goodman SM, Duchemin JB, Duplantier JM. Trypomastigotes and potential flea vectors of the endemic rodents and the introduced *Rattus rattus* in the rainforests of Madagascar. Biodivers Conserv. 2003;12:1775-1783.

POISONING OF WILDLIFE IN ENVIRONMENTAL PARKS OF BRAZIL

Elisângela de Albuquerque Sobreia* and Sheila Canevese Rahal

UnivEstadualPaulista (UNESP), School of Veterinary Medicine and Animal Science, Botucatu-SP, Brazil

Abstract

The city of Anapolis located in the state of Goiás, Brazil, has several environmental parks that serve as habitat and refuge for many wild animals. The parks represent the last refuge for some wild animals such as marmoset, possum, armadillo, capuchin monkey, owl, and lapwing, among others. In addition, the parks play an important role for climate mitigation and preservation of the ecosystem, and represent an important recreational area for residents. Recently, mortality rates have increased in nonhuman primates, including capuchin monkeys and marmosets, as well as skunks from environmental parks as Ipiranga, Matinha, and Central Park. Based on history and clinical signs (rapid onset, tetanic seizures and pupils dilated) strychnine poisoning was suspected. Necropsies were performed on 15 marmosets (*Callithrix penicillata*). Of the 13 marmosets from Central Park, nine showed petechiae in the pancreas, and presence of green strychnine-laced grain in the digestive tract. However, marmosets from Matinha and Ipiranga parks showed no specific necropsy lesions. The Central Park was under renovation. The hypothesis was that the employees were poisoning marmosets since they consistently stole the employees' meals. To address this finding, an environmental education program was held in all three parks of the city. Employees and visitors of the parks were instructed about the importance of wildlife conservation and maintaining biodiversity. A positive result was obtained after the education program was conducted as no further animal deaths have been observed in the parks.

Key words: Brazil, *Callithrix penicillata*, environmental parks, strychnine poisoning

LITERATURE CITED

1. Martin DP. Primates. In: Fowler ME (ed). Zoo and wild animal medicine. Philadelphia (PA): WB Saunders; 1986. p. 658.

2. Wells-Mikota SK. Wildlife laws, regulations, and policies. In: Fowler ME (ed). Zoo and wildlife medicine, Volume 3, Current therapy. Philadelphia (PA): Saunders; 1993. p. 3-10.

HEPATITIS E VIRUS-RELATED VIRUSES: DO THEY ALSO OCCUR IN ZOO ANIMALS?

Carina Spahr,[1]* Reimar Johne, Prof. Dr. med. vet.,[2] Tobias Knauf-Witzens, Dr. med. vet., FTA Zoo- und Wildtiere,[1] and Rainer G. Ulrich, Dr. rer. nat.[3]

[1]Wilhelma Zoological-Botanical Gardens Stuttgart, 70376 Stuttgart, Germany; [2]Federal Institute for Risk Assessment, 10589 Berlin, Germany; [3]Friedrich-Loeffler-Institut, Federal Research Institute for Animal Health, 17493 Greifswald-Insel Riems, Germany

Abstract

The family Hepeviridae contains the human pathogenic hepatitis E virus (HEV) genotypes 1, 2, 3 and 4, but additional hepeviruses have recently been described in other mammals, such as the Norway rat and different carnivores, but also chicken and trout. Domestic pig, wild boar, rabbit and deer represent the most important reservoirs of zoonotic HEV genotypes 3 and 4. The epidemiologic significance of other mammalian hepeviruses is still uncertain. Hepatitis E is a notifiable infectious disease in Germany. The number of recorded cases has been steadily increasing during recent years. The knowledge on HEV infections in animals within zoological gardens is scarce. In a precedent survey the presence of rat HEV in pest rats was confirmed in two zoological gardens, but there was no evidence for genotype 3 in these rats. Two potential groups of reservoirs may therefore exist in zoological gardens: pest animals, like rats, house mice, rabbits and foxes, and zoo animals of the family Suidae, like babirusas, peccaries, domestic pigs, and others. Within an ongoing project, both groups of animals as well as other mammal species including great apes are being tested for HEV infection by standard serologic assays as well as different reverse transcription polymerase chain reaction methods. The results will contribute to investigate potential health threats to zoo animals as well as to human beings related to pest rats and house mice in zoological gardens.

Key words: Hepatitis E virus, *Hepeviridae*, notifiable infectious disease, pest animals, reservoir, zoonosis

ACKNOWLEDGMENTS

The authors would like to thank the Grimminger-Stiftung für Zoonosenforschung for supporting this study with a grant to perform a doctoral thesis. The directors of the Wilhelma and Zoo Osnabruck are thanked for supporting this study and their staff for collecting samples.

DISSEMINATED PROTOTHECOSIS IN A RUWENZORI LONG-HAIRED FRUIT BAT (*Rousettus lanosus*)

Brian G. Stockinger, DVM,[1]* Douglas L. Armstrong, DVM,[2] and Alan R. Doster, DVM, PhD, Dipl ACVP[3]

[1]Kansas City Zoo, Kansas City, MO 64132 USA; [2]Omaha's Henry Doorly Zoo and Aquarium, Omaha, NE 68107 USA; [3]University of Nebraska-Lincoln, Lincoln, NE 68588 USA

Abstract

An approximately 9-yr-old male Ruwenzori long-haired fruit bat (*Rousettus lanosus*) presented with lethargy, cranial alopecia, general unthriftiness, mandibular ulceration, and dehydration. The bat was initially treated with subcutaneous 0.9% saline and oral enrofloxacin. The animal was then isolated for supportive care and continued enrofloxacin treatment, as well as to reduce conspecific resource competition. The bat was found deceased 2 days after presentation. Gross necropsy revealed areas of alopecia or thinning of the pelage on the head and body, exposed dried bone on the rostral tip of the mandible, a notable volume of clear pleural fluid, dark red lungs with diffuse pinpoint white foci throughout the parenchyma, a partially black liver, and no appreciable adipose stores. The animal's skin appeared normal. Histologic examination identified in multiple tissues large irregular spherical organisms containing a large, basophilic central nucleus surrounded by a distinct outer capsule. Many of the larger organisms contained endospores. The organisms were observed in the heart, lung, spleen, testicle, skin, jejunum, pancreas, and peripancreatic lymph nodes. Protothecosis was suspected based on the morphologic appearance of the organisms. Polymerase chain reaction amplification using universal fungal primers revealed a 100% sequence identity match with *Prototheca zopfii*. Protothecosis has been previously reported in a single bat, Lyle's flying fox (*Pteropus lylei*), in Switzerland, but definitive speciation was not possible.[1] To the authors' knowledge this is the first report of protothecosis, speciated or otherwise, in a bat in the United States.

Key words: Disseminated protothecosis, fruit bat, *Rousettus lanosus*

LITERATURE CITED

1. Mettler, F. Generalized protothecosis in a fruit bat (*Pteropus lylei*). Vet Pathol. 1975;12:118-124.

INDIVIDUAL ASSESSMENT OF THE WESTERN LOWLAND GORILLA (*Gorilla g. gorilla*) DIET IN THE ZOO BASEL

Sara Abreu,[1]* Christina Simon, Dr med vet,[2] Stefan Hoby, Dr med vet,[3] Adrian Baumeyer, MSc Biol,[3] and Christian Wenker, Dr med vet, Dipl ECZM[3]

[1]Faculdade de Medicina Veterinária, Universidade de Lisboa, 1300-477 Lisbon, Portugal; [2]Protector Zoofeed, Cargill Feed and Nutrition Switzerland, Provimi Kliba SA, CH-4303 Kaiseraugst, Switzerland; [3]Zoo Basel, CH-4054 Basel, Switzerland

Abstract

Although there are nutrient reference ranges for primates in the literature,[1] most zoos use group feeding, therefore formulating diets by calculating what a group might be consuming. This may lead to nutrient imbalances on an individual basis, as it does not account for individual preferences, physiologic, age- or hierarchy-related specific requirements.

During this study Zoo Basel kept two male gorillas, one silverback (16 yr) and one blackback (12 yr), two late-stage pregnant females (25 and 32 yr) and two geriatric females (47 and 55 yr). On 14 randomly selected days over the course of 2 mo, each food item was weighed and recorded along with the observation of individual intake during group feeding. A total of 66 different food items were offered and divided by nutrient composition categories. The individual consumption of each category was assessed.

Daily dry matter intake varied between 1.09% and 1.67% of body weight between individuals. The percentage that each feed item contributed to the whole diet also varied. For example, easily digestible carbohydrates like root vegetables were found to constitute 30% of the diet of a geriatric female and 16% for a pregnant female. The individual intake was below the recommended values for all animals in nutrients like linoleic acid and phosphorus, while other nutrients like folate were only insufficient in one pregnant female.

An individual analysis of the diet consumed can help identify nutrient imbalances and adjust the diet to individual requirements. Together with monitoring of weight, feeding behavior and other parameters it's an important tool to assess diet adequacy.

Key words: Diet, *Gorilla g. gorilla,* nutrient intake, Western lowland gorilla

ACKNOWLEDGMENTS

The authors would like to thank Zoo Basel and Provimi Kliba for the support provided in the completion of this study.

LITERATURE CITED

1. National Research Council. Nutrient requirements. In: Nutrient requirements of nonhuman primates (2nd ed). Washington (DC): The National Academies Press; 2003. p. 191-194.

CHARACTERIZATION AND TREATMENT OF A NEW WASTING DISEASE OF OWL MONKEYS (*Aotus* sp.)

Alan G. Brady, DVM, Dipl ACLAM,* Gregory K. Wilkerson, DVM, Dipl ACVP, Lawrence E. Williams, PhD, and George W. Tustin, BS

Dept. of Veterinary Sciences, Michale E. Keeling Center for Comparative Medicine & Research, UT MD Anderson Cancer Center, Bastrop TX 78602 USA

Abstract

Owl monkeys are small (< 2 kg) arboreal primates, native to the Amazon Basin. They are the only Neotropical nocturnal primate. A wasting disease characterized by chronic weight loss, profound leukopenia, hypoproteinemia, but normal feces, was identified in a research colony of owl monkeys (*Aotus nancymaae, A. azarae, A. vociferans*). Weight loss in affected animals became sufficiently severe that euthanasia was required for humane reasons. Terminally, there was depletion of serum vitamin B12. Vacuolar change in central nervous system (CNS) white matter was noted post-mortem. In a 7-yr period, of 496 live colony-housed animals, 48 (9.7% of the colony) were found at necropsy to have lesions consistent with owl monkey wasting disease (OMWD). The cause of OMWD has not been determined. Etiologies investigated include infectious, nutritional, metabolic, and toxic causes. A possible heritable component is suggested by 17 OMWD cases traced to a single sire. Lesion appearance of OMWD cases is suggestive of malabsorption or maldigestion. An effective treatment regimen using vitamin B12 (cyanocobalamin) and traditional Chinese acupuncture was developed that reversed the effects of OMWD (n = 8 animals). Unanesthetized OMWD animals were hand restrained and given 0.05-0.10 ml of B12 (5 mg/ml) at four of the traditional published acupuncture points: pericardium 6, stomach 36, gallbladder 34, spleen 6.[1] Weight gain began within 2 wk. Treatment was continued twice weekly until body weight and white blood cell counts returned to normal values (usually, about 3 mo). Since this treatment was started, no animals have required euthanasia due to OMWD.

Key words: Acupuncture, *Aotus* sp., B12, cyanocobalamin, wasting disease

LITERATURE CITED

1. Xie H, Preast V. Traditional Chinese veterinary medicine; fundamental principles. Reddick (FL): Chi Institute; 2007. p. 106-129.

SEVERE PROTEIN-ENERGY MALNUTRITION: KWASHIORKOR IN A JUVENILE CHIMPANZEE (*Pan troglodytes*)

Thalita Simões Calvi, BVetMed, MSc WAH

Chimfunshi Wildlife Orphanage Trust, Chingola, P.O. Box 11190, Zambia

Abstract

Severe protein-energy malnutrition express a multifactorial condition that increases the risk of morbidity and mortality.[1] Causes are related to improper or unbalanced intake and metabolism of nutrients, infections, physiologic deprivation or environmental stressors. It is the result of chronic and cumulative failure to meet physiologic energy and nutrient requirements. Kwashiorkor is one of two clinical forms described and mostly seen in children of developing countries. The complete etiology is not fully understood; however, it is related to low protein with adequate energy intake, absorption or metabolism. A captive-born juvenile, male chimpanzee (*Pan troglodytes*), "Darwin," was presented for evaluation due to weight loss, general weakness, apathy, hair and skin discoloration. Physical examination revealed severe periocular edema, pale mucous membranes, cold extremities, mild icterus, stunt growth and muscle wasting. Coproparasitology showed mild nematode infection, and empirical treatment was initiated with albendazole (500mg SID 3days), azytromicin (200 mg s.i.d. 5 days) and daily supplementation with oral polivitamins and human protein-energy shake until further diagnostics were available. Blood results collected under chemical immobilization after 40 days of treatment with no clinical improvement, showed marked normocytic normochromic anemia, severe hypoproteinemia (plasma protein-4.4 mg/dl, total protein-36 g/L), hypoalbuminemia (8.0 g/L), and suspected dyslipedemia. Preliminary clinicopathologic evidence suggests protein losing nephropathy [3,5] as the most probable cause. Further analyses are necessary for complete case elucidation. To the author's knowledge, this is the first report of Kwashiorkor malnutrition syndrome in a great ape species, where the main clinical sign was the marked periocular edema.

Key words: Chimpanzee*,* hypoproteinemia, kwashiorkor, malnutrition, *Pan troglodytes,* protein-energy

ACKNOWLEDGMENTS

The authors would like to thank the Chimfunshi Wildlife Orphanage Trust for their general support and keeper staff for their special care with "Darwin."

LITERATURE CITED

1. Blössner M, de Onis M. Malnutrition: quantifying the health impact at national and local levels. Geneva, World Health Organization, 2005. WHO Environmental Burden of Disease Series, No. 12.

2. Mundy NI, Ancrenaz M, Wickings EJ, Lunn PG. Protein deficiency in a colony of Western lowland gorillas (*Gorilla g. gorilla*). J Zoo Wildl Med. 1998;29(3):261-268.

3. Nunamaker E, Lee R, Lammey ML. Chronic diseases in captive geriatric female chimpanzees (*Pan troglodytes*). Comp Med. 2012;62(2):131-136.

4. Penny M. Protein-energy malnutrition: pathophysiology, clinical consequences and treatment in nutrition. In: Walker W, Duggan C, Watkins JB, (eds.). Nutrition in pediatrics: basic science and clinical application. Hamilton (ON): Decker Inc; 2003. p. 174-194.

5. Rosenburg S, Snyder P. Myocardial failure in a two-toed sloth (*Choloepus didactulus*). Proc Am Assoc Zoo Vet, and Int Assoc Aquat Anim Med; 2000. p. 246-249.

COMPARISON OF THREE METHODS OF PREVENTING PERI-ANESTHETIC HYPOTHERMIA IN CALLIMICO (*Callimico goeldii*)

Sathya K. Chinnadurai, DVM, MS, Dipl ACZM, Dipl ACVAA,[1]* James G. Johnson III, DVM,[1,2] and Jennifer N. Langan, DVM, Dipl ACZM, Dipl ECZM (ZHM)[1,3]

[1]Chicago Zoological Society, Brookfield Zoo, Brookfield, IL 60513 USA; [2]Illinois Zoological and Aquatic Animal Residency Program, Urbana, IL 61802 USA; [3]University of Illinois, College of Veterinary Medicine, Urbana, IL 61802 USA

Abstract

Peri-anesthetic hypothermia is one of the most common complications in veterinary anesthesia, especially in small patients with a large body surface area to mass ratio.[1,2] During an anesthetic episode body heat is typically lost by four mechanisms: radiation, convection, conduction and evaporation.[3] Frequently, an anesthetist may only address one of the four mechanisms at a time. The goal of this study was to evaluate the routes of heat loss and methods of peri-anesthetic hypothermia prevention in callimico (*Callimico goeldii*). In the authors' experience, these animals routinely become hypothermic under even brief gas anesthesia. To address multiple routes of heat loss, animals were assigned to one of three treatment groups: 1) a reflective blanket[a] placed over the patient to limit radiative heat loss to the surrounding environment, 2) a commercially available heated anesthetic circuit,[b] designed for veterinary use, with an active air heating mechanism to warm the inspired air in the anesthetic circuit to 40°C, or 3) forced air warming blanket[c] under the patient. Sources of radiative heat loss were assessed using infrared thermography. Each animal was anesthetized with isoflurane, maintained in sternal recumbence in a temperature controlled room at 18°C and esophageal core body temperature was monitored every 5 min for a 30-min period. No difference was found in the rate of heat loss between treatments 1 and 2. Animals in group 3 experienced a slight increase in average body temperature. Based on these findings, an underbody warm air blanket provided the best protection against hypothermia.

[a]Emergency Mylar Thermal Blankets, Quiverr, CA USA
[b]Darvall Heated Breathing Circuit, Advanced Anesthesia Specialists, AU
[c]Bair Hugger, 3M, MN USA

Key words: Anesthesia, *Callimico goeldii*, Goeldi's monkey, hypothermia, primate

LITERATURE CITED

1. Machon R, Raffe M, Robinson E. Warming with a forced air warming blanket minimizes anesthetic-induced hypothermia in cats. Vet Surg. 1999;28:301-310.

2. Pottie RG, Dart CM, Perkins NR, Hodgson DR. Effect of hypothermia on recovery from general anaesthesia in the dog. Aust Vet J. 2007;85:158-162.

3. Stoelting RK, Hillier SC. Thermoregulation. In: Stoelting RK, Hillier SC (eds.). Pharmacology and physiology in anesthetic practice, 4th Ed. Philadelphia (PA): Lippincot Williams and Wilkins; 2006. p. 688-695.

ALLOMETRIC SCALING OF ECHOCARDIOGRAPHIC VARIABLES IN WILD-BORN CAPTIVE CHIMPANZEES (*Pan troglodytes*)

Aimee L. Drane, BSc,[1]* Alan M. Batterham, PhD,[2] Pablo Rodriguez, DVM, MSc,[3] Carlos Sanchez, DVM, MSc,[4] Michael Stembridge, PhD,[1] Sarah Simcox, BSc,[1] Yedra Feltrer, DVM, MSc, MRCV,[1,5] Bruce Peck, DVM,[6] Jacyn Eng, BVM&S, MSc, MRCVS,[7] Glyn Howaston, PhD,[1,8] Rebeca Atencia, BSc,[1,9] and Rob Shave, PhD[1]

[1]International Primate Heart Project (IPHP), Cardiff Metropolitan University, Cardiff Cf23 6XD, UK; [2]Teesside University, Middlesborough TS1 3BA, UK; [3]The Logical Zoo Consultancy ltd, Santiago, Chile; [4]Fort Worth Zoo, Texas, TX 76110 USA; [5]Zoological Society of London, London, NW1 4RY, UK; [6]Chimfunshi Wildlife Orphanage, Chingola T5, Zambia; [7]International Animal Rescue, Ketapang, West Kalimantan, Indonesia; [8]Northumbria University, Newcastle-upon-Tyne, NE1 8ST, UK; [9]Tchimpounga Chimpanzee Sanctuary, Pointe Noire, Congo

Abstract

Heart disease, the leading cause of death among captive chimpanzees (*Pan troglodytes*), may be diagnosed using echocardiography. However, cardiac structure scales with body size and so appropriate scaling of echocardiographic data is required so as to rule out this influence prior to clinical interpretation. Allometric scaling has been shown to eliminate the effects of body size on cardiac structure more robustly than ratiometric methods. Here we have applied a nonlinear allometric model of the form $Y=aX^b$ to a large chimpanzee data set collected from two sanctuary populations (n = 118 males [14 ± 8 y; 43 ± 17 kg], n = 91 females [16 ± 7 y; 38 ± 12 kg]) to derive prediction equations for left ventricular (LV) posterior wall thickness and LV internal diameters in diastole and systole, and end diastolic volume. Using the typical prediction error from each equation, we can construct 90% (green), 95% (amber), and 99% (red) individual reference intervals for these variables based on a chimpanzee's age, body mass and sex. Subsequent measured values for an individual chimp falling outside of the reference range (upper or lower limit) would be defined as 'atypical' with probabilities of <5% (green), <2.5% (amber), or <0.5% (red). For illustration purposes, reference ranges are presented in Table 1 for two example animals: a young female (6 yr, 22 kg) and an older male (25 yr, 52 kg). This approach may help clinicians caring for chimpanzees to more confidently identify abnormal cardiac structure using echocardiography.

Key words: Allometry, cardiac disease, chimpanzee, echocardiography, *Pan troglodytes*, reference intervals

Table 1. Reference ranges for two chimpanzee example animals: a young female (6-yr-old, 22 kg) and an older male (25-yr-old, 52 kg).

Chimpanzee	Variable	Green	Amber	Red
Female	LV posterior wall thickness diastole (cm)	0.32-0.66	0.29-0.69	0.23-0.75
6-yr-old	LV posterior wall thickness systole (cm)	0.60-1.14	0.55-1.19	0.44-1.30
22 kg	LV internal diameter diastole (cm)	2.9-4.0	2.8-4.1	2.6-4.3
	LV internal diameter systole (cm)	1.8-3.1	1.7-3.2	1.4-3.5
	End diastolic volume (ml)	22-56	19-59	12-66
Male	LV posterior wall thickness diastole (cm)	0.67-1.11	0.62-1.16	0.54-1.24
25-yr-old	LV posterior wall thickness systole (cm)	1.0-1.6	0.9-1.7	0.8-1.8
52 kg	LV internal diameter diastole (cm)	4.4-5.5	4.2-5.6	4.0-5.8
	LV internal diameter systole (cm)	2.9-4.5	2.8-4.6	2.5-4.9
	End diastolic volume (ml)	70-120	65-125	56-134

LONG-TERM SURVEILLANCE OF HERPES B-LIKE VIRUS IN CAPTIVE SILVERED LEAF MONKEYS (*Trachypithecus cristatus*)

Kate A. Gustavsen, PhD, DVM,[1]* Julia K. Hilliard, PhD,[2] Bonnie L. Raphael, DVM, Dipl ACZM,[1] and Paul P. Calle, VMD, Dipl ACZM[1]

[1]Wildlife Conservation Society, Zoological Health Program, Bronx, NY 10460 USA; National B Virus Resource Center, Georgia State University, Atlanta, GA 30303 USA

Abstract

A novel alphaherpesvirus, closely related to *Macacine herpesvirus 1* (B virus), was identified in silvered leaf monkeys (*Trachypithecus cristatus*) at the Bronx Zoo in 1991.[1] The virus was provisionally named herpesvirus langur (HVL).[2] Retrospective analysis found an overall seroprevalence of 38% (13/34 animals tested) from 1984 to 1994, with evidence of primary and recurrent exposure.[1] Clinical signs potentially attributable to HVL have been rare. One individual developed orogenital vesicles, and three developed ulcerative pharyngitis and were subsequently found to be seropositive. HVL was cultured from the pharyngeal lesions in one individual at necropsy.[1] The zoonotic potential of HVL is unknown, but because of its similarity to B virus we employ the same personal protective measures used with macaques, and have collected opportunistic samples for ongoing surveillance. From 1991 to 2015, we obtained 235 serum samples and 232 buccal and conjunctival swabs from 78 individuals. Seroprevalence was calculated in 5-yr intervals; previously positive animals were assumed to remain positive, and animals were assumed to have been negative in intervals prior to a negative result. Prevalence was 59% in 1991-95 (20/34 animals tested), 59% (13/22) in 1996-2000, 48% (12/25) in 2001-05, 44% (14/32) in 2006-10, and 41% (7/17) in 2011-15. The slight decrease was due to attrition of seropositive animals and declining incidence of new cases. Virus isolation was negative on all swabs, suggesting the frequency of viral shedding was low. Identification of novel alphaherpesviruses related to B virus highlights the importance of taking proper precautions when handling all primate species.

Key words: B virus, herpesvirus, langur, *Macacine herpesvirus 1*, silvered leaf monkey, silvery langur, silvery lutung, *Trachypithecus cristatus*

ACKNOWLEDGMENTS

The authors acknowledge the staff of the WCS Zoological Health Program Clinical and Pathology Departments, the WCS Department of Mammalogy, the Southwest Foundation for Biomedical Research, and the National B Virus Resource Center for continued assistance throughout the course of this study.

LITERATURE CITED

1. Calle PP, Raphael BL, Stetter MD, Walberg JA, Trupkiewicz JG, McNamara TS, Cook RA, Hilliard JK, Mirkozic R, Ward J. Novel herpes-B like infection of silver leaf langurs (*Presbytis cristata*). Proc Am Assoc Zoo Vet. 1996;457-459.

2. Eberle R, Hilliard J. The simian herpesviruses. Infect Agents Dis. 1995;4(2):55-70.

DISEASE MONITORING OF REHABILITATED WESTERN CHIMPANZEES (*Pan troglodytes verus*) IN SIERRA LEONE

Sophie Moittié, LV,[1]* Rosa Garriga, LV,[1] Jenny Jaffe, DVM,[2] and Carles Juan-Sallés, LV, Dipl ACVP[3]

[1]Tacugama Chimpanzee Sanctuary, Freetown, Sierra Leone; [2]Institute of Zoology, Zoological Society of London, London, NW1 4RY, UK; [3]Noah's Path, 03203 Elche, Spain

Abstract

Since 1995 Tacugama Chimpanzee Sanctuary has been rehabilitating wild western chimpanzees (*Pan troglodytes verus*) that have been captured for the bushmeat or pet trade. It currently cares for about 75 chimpanzees that live in a semi-wild environment in the Western Area Peninsula National Park near Freetown, in Sierra Leone. In past years, standard operating procedures and medical protocols and disease monitoring have been implemented by the sanctuary veterinarians in collaboration with the Pan African Sanctuary Alliance to improve the preventive medicine program and response against diseases. During the last decade, 50 of the resident chimpanzees have died with no premonitory signs or after the onset of neurologic symptoms. This syndrome was formally identified beginning in 2005 and shows a seasonal distribution but the cause is still unidentified. Cases only occur amongst chimpanzees kept in the large forest enclosures. Affected animals were usually 5-27 yr old and clinical signs, present in approximately 65% of them, included lethargy, poor appetite, ataxia, neuromuscular weakness, seizures, vomiting, and signs of abdominal discomfort. A variety of treatments (antibiotics, corticosteroids, opioids, fluid therapy) and preventive measures (encephalomyocarditis virus vaccinations) have been tried but were not effective. Histopathologic findings include pulmonary and pancreatic edema and hemorrhage, and acute shock. Bronchiolointerstitial pneumonia with syncytia (suspected respiratory syncytial virus or metapneumovirus infection), encephalomyocarditis virus infection (confirmed by PCR and sequencing), and mycobacteriosis have each been found in one chimpanzee. Myocardial lesions are frequent, particularly nuclear hypertrophy with rowing of nuclei. Cardiomyopathy characterized by cardiomyocyte degeneration and necrosis with edema and mild myocarditis, and associated with pulmonary thrombosis and possible incipient congestive heart failure appeared to contribute to the demise of one chimpanzee. Concurrent lesions and diseases considered unrelated to the cause of death include eosinophilic enteritis associated with invasive enterobiasis or strongylidiasis, and pulmonary acariasis associated with eosinophilic bronchitis. Affected chimpanzees usually have abundant adipose tissue stores. Next generation sequencing on tissues of 12 animals found no virus in the samples. Currently, the possibility of intoxication with the plant *Dichapetalum heudelotii*, present in the enclosures where fatalities have occurred, is being investigated. The plant´s toxin, sodium monofluoroacetate (1080), is known to produce symptoms similar to those seen in these chimpanzees.[1] Molecular analysis performed on vomit and stool of 19 chimpanzees with acute symptoms resulted inconclusive (in eight of the samples no DNA was extracted). Eradication of the plant from the enclosures is being carried out without any significant change in mortality. A team of international consultants, including pathologists, toxicologists, botanists, molecular biologists, and primate veterinarians are collaborating to identify the root cause(s) of this syndrome and help implement the most appropriate measures. The lack of specialized laboratories and experts within the country as well as the financial shutdown associated

with the recent Ebola crisis add difficulties to syndrome investigation, and stress the importance of building on site diagnostic for the immediate future and long term. Toxicology analysis, consistent sampling during the acute phase of the disease, improved postmortem diagnostic evaluations and comprehensive health checks including cardiac assessments for all the chimpanzees are some of the actions planned to identify the cause.

Key words: Ataxia, chimpanzee, *Pan troglodytes verus*, Sierra Leone, sudden death, toxicity

LITERATURE CITED

1. Parton KH. Sodium monofluoroacetate (1080). In Talcott PA, Peterson ME, (eds.). Small animal toxicology. 3rd ed. Philadelphia (PA): Saunders; 2001. p. 811-816.

SUCCESSFUL SURGICAL TREATMENT OF A CECO-CUTANEOUS FISTULA IN A CROWNED SIFAKA (*Propithecus coronatus*)

Benoît Quintard, DVM,[1]* Xavier Ferreira, DVM,[2] Mélanie Berthet, DVM,[3] Brice Lefaux, DVM,[1] Alexandrine Vesz,[3] DVM, and Karin Lemberger, DVM, Dipl ACVP[4]

[1]Parc Zoologique et botanique de Mulhouse, 68100 Mulhouse, France; [2]Clinique vétérinaire des Halles, 67000 Strasbourg, France; [3]Citadelle de Besançon, 25000 Besançon, France; [4]Vet Diagnostics, 69008 Lyon, France

Abstract

A 6-yr-old male crowned sifaka (*Propithecus coronatus*) presented a small muco-purulent discharge from a well-delimited 8-mm wound in the groin region, close to the scrotum. Two successive antibiotic treatments (Ciprofloxacine, 20 mg/kg, s.i.d., 10 days and amoxicillin-clavulanic acid, 12.5 mg/kg, b.i.d., 7 days) were unsuccessful. Anesthesia was decided and exploration of the lesion revealed a deep wound with insertion of a 10-cm long probe without resistance. A CT scan performed with contrast liquid (Iodixanol) inserted through the probe showed a fistula passing through the right inguinal ring towards the caecal region in the abdominal cavity. Laparotomy under isoflurane anesthesia was decided. A 10% dilution of fluorescein solution was administered through the probe to help the surgeon visualize the precise localization of the fistula and its stoma in the caecum which could not be precisely identified with the CT scan. Classic surgery of similar cases in human beings consists of the removal of the appendix.[1] In this case, the folivorous regime of the sifaka and the importance of the caecum in its digestive process made the complete removal of the caecum impossible.[2] Thus a 4-cm portion of the fistula was removed right after the theoretical caecal end to stop the progression of digestive material to the wound and allow the lesion to dry. Oral amoxicillin and clavulanic acid (Synulox, 12.5 mg/kg, bid) were used as treatment for 7 days and complete recovery was achieved without any digestive complication. Histology of the fistula was consistent with an intestinal endodermic cyst or a diverticulum. To the author's knowledge this is the first case of a caeco-cutaneous fistula in a nonhuman primate.

Key words: Appendico-cutaneous, ceco-cutaneous, crowned sifaka, fistula, *Propithecus coronatus,* surgical resection

ACKNOWLEDGMENTS

The authors would like to thank the lemur keepers from Mulhouse and Besançon zoos for their dedicated care to this sifaka.

LITTERATURE CITED

1. Campbell J. L., Eisemann J. H., Williams C. V. and Glenn K. M. Description of the gastrointestinal tract of five lemur species: Propithecus tattersalli, Propithecus verreauxi coquereli, Varecia variegata, Hapalemur griseus, and Lemur catta. Am J Primatol. 2000;52:133-142.

2. Koak Y., Jeddy T. A., Giddings A. E. B. Appendico-cutaneous fistula. J R Soc Med. 1999; 92:639-640.

GENE ANALYSIS AND COMPARISION OF GENES INVOLVED IN IRON METABOLISM IN THREE DIFFERENT LEMUR SPECIES

Maja Ruetten, Dr med vet, Dipl ECVP, FVH (Pathology),[1]* Hanspeter Steinmetz , Dr med vet, Dipl ACZM,[2] Vidhya Jagannathan, PhD,[3] Markus Thiersch, PhD,[5] Regina Hoffmann-Lehmann, Dr med vet, FVH,[4] Tosso Leeb, Dr rer nat,[3] and Max Gassmann, Dr med vet[5]

[1]Institute of Veterinary Pathology, Vetsuisse faculty Zürich, Switzerland; [2]Knie's Kinderzoo, Rapperswil, Switzerland; [3]Institute of genetics, Vetsuisse faculty Bern, Switzerland; [4]Clinical laboratory, Vetsuisse faculty Zürich, Switzerland; [5]Institute of Veterinary Physiology, Vetsuisse faculty Zürich, Switzerland

Abstract

Iron storage disease (ISD) is a major concern of many endangered wildlife species populations in zoological gardens. One of the critical factors is the provision of a diet appropriate for the species concerned. The aim of this project was to sequence genes involved in iron uptake and metabolism to provide a comparative molecular basis for delineating the pathogenesis of ISD. Additionally, we hypothesised that the disease in human medicine known as "secondary haemosiderosis," caused by other diseases as for example chronic inflammation, exists in the animal kingdom as well. From three different lemur species, *Lemur catta*, *Hapalemur griseus* and *Varecia rubra,* DNA was isolated from blood or liver tissue using a Qiagen kit® and the entire genome was sequenced by high seq Illumina® sequencer. The coverage was 9.14 to 10.3. The first gene (hepcidin, primary iron regulating hormone) could be predicted and compared with other species. Although highly conserved, the amino acid sequences of all tested lemur species differed from their nearest primate relatives by ten amino acids over the full length of 84 amino acid proteins. Within the lemurs, the mouse lemur sequence differed at eight positions from the three new sequences we have obtained and between these three, there are also differences. Even within the 25 amino acid active peptide, *H. griseus*, *L. catta* and *V. rubra* differ from *M. murinus* at two positions and from the primates at three positions. In those regions where mutations have been described in humans as causing haemochromatosis, there are no changes in the lemur sequences.

Key words: *Hapalemur griseus*, iron metabolism, lemur, *Lemur catta*, *Varecia rubra*

A RETROSPECTIVE REVIEW OF MORTALITY AMONG ZOO-HOUSED GREAT APES BETWEEN 2004-2014

Victoria Strong, BVSc, BSc (Hons), MRCVS,[1,2]* Kerstin Baiker, Dipl ECVP, MRCVS,[1] Marnie Brennan, BVMS, PhD, PGCHE, FHEA, MRCVS,[1] Victoria L. Clyde, DVM, Sharon Redrobe, BVetMed, DZooMed,[2] and Kate White, MA, VetMB, Dipl ECVAA, DVA[1]

[1]University of Nottingham School of Veterinary Medicine, Sutton Bonington Campus, Leicestershire, LE12 5RD, United Kingdom; [2]Twycross Zoo, Atherstone, Warwickshire, CV9 3PX, United Kingdom; [3]Milwaukee County Zoo, Milwaukee, WI 53226 USA

Abstract

No reviews of mortality among the European chimpanzee (*Pan troglodytes*), Western lowland gorilla (*Gorilla gorilla gorilla*) and orangutan (*Pongo pygmaeus, Pongo abelii*) population nor the combined European and North American bonobo (*Pan paniscus*) population have been performed. This study is the first ever review of mortality among these animals and the largest review captive great ape mortality performed to date.

Animals were categorised according to sex and age at death. Deaths were classified by cause. For each taxa, the main causes of death overall, in each age and sex category were identified. The populations were also assessed for sex and species variation in longevity and cause of death.

A total of 704 animals (151 gorillas, 47 bonobos, 386 chimpanzees and 120 orangutans) died during the period under study. The main causes of death were: disease of the alimentary system (25%); cardiovascular disease (15%); and death due to external causes (15%) among gorillas; and disease of the circulatory (34%) and respiratory (32%) systems among bonobos. Sex variation in longevity and cause of death were observed. Cause of death data analysis for chimpanzees will be complete by the end of December 2015. Orangutan data analysis will be complete by May 2016.

This review identified a number of diseases of significance for captive great ape health. It highlighted areas of interest for future work, which should be aimed at investigating the epidemiology of the main causes of death among these animals, with observed differences between sexes and taxa requiring particular attention.

Key words: Captive, epidemiology, *Gorilla*, *Hominidae*, *Pan*, *Pongo*

ACKNOWLEDGMENTS

The authors would like to acknowledge all committee members of the EAZA Great Ape Taxon Advisory Group (TAG), especially the TAG chair and EEP co-ordinators. Also to thank all zoos and pathologists that have contributed data to the study. Finally to staff and colleagues at the named institutions for their assistance and support.

IMPROVING THE WAY WE DART: REVIEWING TRENDS IN DARTING WILD PRIMATES

Elena Cunningham, PhD,[1] Steve Unwin, BSc, BVSc, Dipl ECZM, MRCVS,[2]* and Joanna M. Setchell, PhD[3]

[1]New York University College of Dentistry, NY 10010 USA; [2]Animal Health Centre, Chester Zoo, Caughall Road, Upton-By-Chester, Chester CH21LH, UK; [3]Department of Anthropology, Durham University, Durham, DH1 3UP UK

Abstract

While use of non-invasive methods for data collection in wild primates is encouraged, direct access to animals often remains necessary. Thus, field anaesthesia remains an important tool for conservation management and research.[6] There are currently no specific guidelines for darting wild primates.[1,3] There are many published dose ranges for primate anaesthesia in darting situations.[4,7,9] Data from a literature review from (1940-2010) were combined with two anonymous surveys using Survey Monkey. Research published since 2000 is less likely to share information on darting than studies published earlier, in particular from dartings in which injuries or fatalities occur. The majority of cases used ketamine HCl for immobilization (n = 219). Doses of ketamine HCl ranged 3.5-50 mg/kg, mean 12.9 mg/kg, SD 12.2. The upper dose of 50 mg/kg was used in 9.6% of dartings. The recommended dose range of ketamine is 2-10 mg/kg in combination and up to 15 mg/kg on its own.[4,7-9] Although doses as high as 250 mg/kg have been used experimentally in squirrel monkeys without causing death,[2] 50 mg/kg remains far higher than needed even in field conditions. In the survey phencyclidine HCl was used in 151 cases, either alone or in combination with other drugs. It has not been used in clinical primate anaesthesia since the 1960s, when ketamine became more widely available.[5] These and other data in the survey highlight a requirement by the primate scientific community as a whole to move towards improving medical and humane approaches to remote primate capture.

Key words: Darting, primates, review, wild

LITERATURE CITED

1. Fedigan LM. Ethical issues faced by field primatologists: asking the relevant questions. Am J Primatol. 2010; 72:754-771.

2. Greenstein ET. Ketamine HCl, a dissociative anasthetic for squirrel monkeys. Lab Anim Sci. 1975;25:774-777.

3. Gruen L, Fultz A, Pruetz J. Ethical issues in African great ape field studies. ILAR J. 2013;54:24-32.

4. Olberg RA. Monkeys and gibbons. In: West G, Heard D, Caulkett N (eds.). Zoo animal and wildlife immobilization and anesthesia. Ames (IA): Blackwell Publishing; 2007. p. 375-386.

5. Popilskis SJ, Kohn DF. Anaesthesia and analgesia in nonhuman primates. In: Kohn DF, Wixson SK, White WJ, Benson GJ (eds). Anesthesia and analgesia in laboratory animals. San Diego (CA): Academic Press; 1997. p. 233-254.

6. Radcliffe RW, Morkel P vdB. Rhinoceroses. In: West G, Heard D, Caulkett N (eds.). Zoo animal and wildlife immobilization and anesthesia. Ames (IA): Blackwell Publishing; 2007. p. 543-566.

7. Sleeman J. Great apes. In: West G, Heard D, Caulkett N (eds.). Zoo animal and wildlife immobilization and anesthesia. Ames (IA): Blackwell Publishing; 2007. p. 387-394.

8. Valverde CR, Lemoy MJ. Chemical restraint agents used in primates. In: Carpenter JW (ed.). Exotic animal formulary, 4th ed. St. Louis (MO): Elsevier Saunders; 2013. p. 627-638.

9. Williams CV, Junge RE. Prosimians. In: West G, Heard D, Caulkett N (eds.). Zoo animal and wildlife immobilization and anesthesia. Ames (IA): Blackwell Publishing; 2007. p. 367-374.

SAFETY OF AZAPERONE FOR REPEATED ANESTHESIA ON WILD BOAR (*Sus scrofa scrofa*)

Barbara Blanc, DVM,[1]* Katia Ortiz, DVM,[1,2] Yann Locatelli, PhD,[1] and Thomas Cucchi, PhD[3]

[1]Réserve zoologique de la Haute Touche, Muséum National d'Histoire Naturelle, 36290 Obterre, France; [2]Institut de Systématique, Évolution, Biodiversité, ISYEB - UMR 7205 - CNRS, MNHM, UPMC, EPHE, Muséum National d'Histoire Naturelle, Sorbonne Universités, 57 rue Cuvier, F-75005, Paris, France; [3]CNRS - Muséum national d'Histoire naturelle, UMR 7209 "Archéozoologie, Archéobotanique: Sociétés, Pratiques et Environnements," USM 303 - Département Ecologie et Gestion de la Biodiversité, case postale 56 (bâtiment d'anatomie comparée), 55 rue Buffon, F-75231 Paris cedex 05, France

Abstract

As part of an experimental study of a zooarcheological project, 24 wild boars (*Sus scrofa scrofa*) had to be anesthetized every 3 mo from the age of 6 mo-2 yr for CT and MRI imaging. The challenge was to anesthetize six animals in the same half day of experiment with a rapid recovery. A safe handling of this species could be delicate.[1,3,4] We took the opportunity of these repeated anesthetic events to document an azaperone-based protocol adapted to wild boars. Each animal was restrained in an individual crate and received an azaperone injection (2 mg/kg, i.m.), prior to a 2-hr transfer time.[3] Pigs were then anesthetized with a standard combination of medetomidine (60 µg/kg, i.m.) and ketamine (6 mg/kg, i.m.), followed by 1% isoflurane maintenance by endotracheal tube.[2,3] This protocol was insufficient when animals exceeded 30 kg. Adjusted doses of azaperone were added for anesthesia induction (1-2 mg/kg, i.m., depending on time after premedication). This anesthesia depth permitted i.v. catheter placement. Intubation sometimes required an additional dose of ketamine (1 mg/kg, i.v.). Anesthesia was closely monitored particularly body temperature (hypothermia and malignant hyperthermia prevention[4]). Animals were reversed in the crate with atipamezole (300 µg/kg, i.m.). This azaperone-based protocol provided safety for the boars as well as for the veterinary team handling these dangerous animals. Moreover, it allowed us to avoid increasing the medetomidine dosage and its potential adverse effects on animals that will reach up to 100 kg.

Key words: Anesthesia, azaperone, repeat, safety, *Sus scrofa scrofa*, wild boar

ACKNOWLEDGMENTS

The authors would like to thank the team of zoo keepers of the Réserve zoologique de la Haute Touche and the team of CIRE platform at INRA Nouzilly for their assistance in the care of wild boars and manipulations.

LITERATURE CITED

1. Barasona JA, López-Olvera JR, Beltrán-Beck B, Gortázar C, Vicente J. Trap-effectiveness and response to tiletamine-zolazepam and medetomidine anaesthesia in Eurasian wild boar captured with cage and corral traps. BMC Vet Res. 2013;9:107.

2. Dotson T, Winand CJ. Immobilization of European wild hogs with azaperone and ketamine: an alternative. Proc Annu Conf Southeast Assoc Fish Wildl Agencies. 1991; 45:175-177.

3. Padilla LR, Jeff CH. Non-domestic suids. In: West G, Heard D, Caulkett N (eds.). Zoo animal and wildlife immobilization and anesthesia. Ames (IA): Blackwell Publishing. 2007. p. 567-577.

4. Thurmon JC, Smith GW. Swine. In: Tranquilli WJ, Thurmon JC, Grimm KA (eds.). Lumb & Jones' veterinary anesthesia and analgesia. Fourth edition. Ames (IA): Blackwell Publishing. 2007. p. 747-763.

PERIODONTAL DISEASE IN TWO ZOO-BASED SOUTHERN BLACK RHINOCEROS (*Diceros bicornis minor*)

Benn Bryant, BVSc, MVS, MANZCVSc* and Michelle Campbell-Ward, BSc, BVSc, DZooMed (Mammalian) MANZCVSc

Taronga Western Plains Zoo, Obley Rd, Dubbo, NSW, 2830, Australia

Abstract

Painful periodontal disease often goes undetected in horses due to inadequate oral cavity examination. This is also likely the case for stoic zoo Rhinocerotidae which typically express only mild signs of disease and in which examination is challenged by orofacial anatomy.

Longstanding severe, extensive periodontal disease characterised by multifocal apical abscessation and lysis of perialveolar bone, gingival pathology, diastemata and hypercementosis was identified in two ex-wild, aged, female southern black rhinoceros fed long-term on a predominantly grass based forage in an open range zoo. Clinical signs were mild (i.e., infrequent) quidding. Animals maintained good body condition and appetite. Despite worn, smooth occlusal surfaces, other features of wear (hooks, points, wave mouth etc) were not present. Clinical examination was challenging and dental radiography was necessary to characterise disease.

Browse is less abrasive than grass which contains significant silica. Accordingly, browsing species (e.g., black rhinoceros) have evolved a different dentition, including a lesser degree of hypsodonty, than grazers (e.g., horses). Horses develop periodontal disease where pathologic dental wear (points etc) and altered chewing patterns generate abnormal forces on the peridontia.[1,2] Conversely, we speculate that abnormal forces contributing to periodontal disease in zoo black rhinoceros fed predominantly grass forage arise subsequent to the grinding of a ration for which the dentition is unsuitable. Potential consequences of chronic inflammatory dental disease in black rhinoceros include systemic abscessation, sub-fertility and exacerbation of excessive iron uptake.

Thorough, regular orodental examination, including dental radiography, should be part of zoo black rhinoceros preventative health.

Key words: Black rhinoceros, *Diceros bicornis,* hypercementosis, periodontal disease

LITERATURE CITED

1. Dacre IT. Equine dental pathology. In: Baker GJ, Easley J (eds.). Equine Dentistry 2nd edition. Philadelphia (PA): Elsevier Saunders; 2005. p. 91-109.

2. Baker GJ. Abnormalities of wear and periodontal disease. In: Baker GJ, Easley J (eds.). Equine Dentistry 2nd edition. Philadelphia (PA): Elsevier Saunders; 2005. p. 111-119.

DIAGNOSIS AND TREATMENT OF TWO SUBADULT BAIRD'S TAPIR (*Tapir bairdii*) WITH BILATERAL GUTTURAL POUCH INFECTION

Genevieve Dumonceaux, DVM, Dipl ECZM (ZHM)

Palm Beach Zoo, West Palm Beach, FL 33405 USA

Abstract

An 11.5-mo-old hand reared male Baird's tapir, *Tapirus bairdii*, experienced acute onset of muscle weakness, ataxia and disorientation. This was especially apparent when this calf would raise its head to shoulder level to feed. After a visual assessment by a veterinary neurologist, a plan was formulated to anesthetize this animal for transport to a nearby veterinary specialty clinic for computed tomography (CT) and magnetic resonance imaging (MRI) of the skull.

Anesthetic induction included butorphanol 0.132 mg/kg, medetomidine 98.68 µg/kg, and ketamine 2.2 mg/kg all delivered together intramuscularly. Anesthesia was maintained with isoflurane via endotracheal intubation and lasted over 4 hr.

The CT scan revealed a healed skull fracture at the level of the midbrain left of midline. MRI revealed flattening of the left hemisphere likely secondary to a hematoma related to the fracture. Evidence of hydrocephalus of the right ventricle was present. Locculated fluid was visible bilaterally in the guttural pouches. Cerebrospinal fluid analysis was unremarkable. Differentials included atlanto-axial or antlanto-occipital instability, or vestibular disease.

Treatment included 28 days of oral marbofloxacin (based on deep nasal cavity culture and sensitivity) at 5 mg/kg s.i.d., oral meclizine at 82 µg/kg s.i.d. for 3 days, 1 g sucralfate orally s.i.d. for 7 days, and omeprazole at 4 mg/kg orally s.i.d. for 14 days.[1] This calf made a complete recovery with no evidence of persistent neurologic deficits.

Two years after this animal was born, a female was born from the same parents and raised by the dam without issues. At 10 mo of age staff reported this animal behaving in a bizarre fashion. When she would lift her head to take food from staff her legs would buckle and she would fall to the ground. Upon visual exam and cursory neurologic evaluation by the staff veterinarian, a presumptive diagnosis of inner ear (guttural pouch) infection was made. Signs were identical to the presentation of the male less than 2 yr prior. Treatment was begun with oral meclizine, marbofloxacin, sucralfate and omeprazole administered at the same dosages as the male.

This female showed favorable response to the treatment regimen within 24 hr and made a full and successful recovery to normal within days. Medications were fully completed within 28 days with 100 percent compliance.

Both of these calves were raised in similar outdoor natural substrate habitats that shared a natural pond feature. Both calves learned to use water and swim in this pond feature. The author surmises that during this learning period water may have gotten into the ear canals or nasal cavity, allowing bacteria to enter the guttural pouches, leading to bacterial infection.

Key words: Baird's tapir, guttural pouch infection, *Tapir bairdii*

ACKNOWLEDGMENTS

The authors thank the staff of the Palm Beach Zoo for the excellent and continuous care provided to this calf. We thank the staff of Palm Beach Veterinary Specialists for the use of their state of the art facility and their expertise. We thank Pamela Govett, DVM, Dipl ACZM for assistance with the anesthetic procedure and monitoring of the male calf. We thank the Los Angeles Zoo and the San Diego Zoo for aiding in the seamless relocation of these calves to allow for participation in the SSP Baird's Tapir breeding program.

LITERATURE CITED

1. Plumb DC. Plumb's Veterinary Drug Handbook, 7th edition. Ames (IA): Wiley-Blackwell Publishing; 2011.

PHARMACOKINETICS OF A SINGLE ORAL DOSE OF FLUNIXIN MEGLUMINE IN THE WHITE RHINOCEROS (*Ceratotherium simum*)

Brittni East, BS,[1]* Lisa Tell, DVM, Dipl ACZM, Dipl ABVP,[3] Scott B. Citino, DVM, Dipl ACZM,[2] Daniel V. Fredholm, MS, DVM, Dipl ACZM,[2] Kathryn C. Gamble, DVM, MS, Dipl ACZM, Dipl ECZM (ZHM),[4] and Virginia Fajt, DVM, PhD, Dipl ACVCP[1]

[1]Texas A&M University, College Station, TX 77843 USA; [2]White Oak Conservation Center, Yulee, FL 32097 USA; [3]University of California at Davis, Davis, CA 95616 USA; [4]Lincoln Park Zoo, Chicago, IL 60614 USA

Abstract

Appropriate analgesia for colic, lameness, osteoarthritis management, and other medical conditions in white rhinoceroses (*Ceratotherium simum*) is critical. Flunixin meglumine is one of the most common non-steroidal anti-inflammatories used for analgesia in megavertebrates but its pharmacokinetics in rhinoceroses have not been published.[2] Due to this lack of data, equine pharmacokinetic and pharmacodynamic data are commonly used for dosing rhinoceroses. However, there are dangers in extrapolating drug doses when limited species-specific pharmacokinetic information exists.[1,3] Adult white rhinoceroses (n = 5) were administered flunixin meglumine[a] (1 mg/kg, p.o.). Blood samples were collected from each animal at pre-determined time points after drug administration. Plasma flunixin and 5-OH flunixin concentrations were determined, and pharmacokinetic analysis was performed using industry standard software.[b] Mean maximum plasma concentrations (C_{max}) of 1207 ± 601 ng/ml were reached at an average of 3 hr. The geometric mean apparent elimination half-life was approximately 8.3 h ± 1.2 hr. Phase I metabolite 5-hydroxy flunixin concentrations averaged 10% of flunixin concentration for most of the time points. These data demonstrate important differences in drug disposition from horses: one study reported mean C_{max} of 2500 ng/ml, which is approximately twice the concentrations found in this study, and an apparent elimination half-life of 1.5 hr, which is considerably shorter than estimated in this study.[4] Our results support that oral flunixin meglumine (1 mg/kg) may provide therapeutic drug concentrations in white rhinoceroses based on efficacy data in other species.[5] Further studies are necessary to investigate long-term safety and efficacy after multiple doses of flunixin meglumine in this species.

[a]Banamine Paste, Merck Animal Health
[b]Phoenix WinNonLin, Certera USA, Inc.

Key words: *Ceratotherium simum*, flunixin meglumine, pharmacokinetics, white rhinoceros

ACKNOWLEDGMENTS

The authors thank the dedicated wildlife specialist and veterinary care team at White Oak Conservation Center for their assistance in collecting blood samples for this study. The Morris Animal Foundation Veterinary Student Scholars Program provided the student research stipend.

LITERATURE CITED

1. Hunter RP, Isaza R. Concepts and issues with interspecies scaling in zoological pharmacology. J Zoo Wildl Med.

2008;39:517-526.

2. Kottwitz J, Boothe M, Harmon R, Citino SB, Zuba J, and Boothe D. Results of the 2012-2013 megavertebrate analgesia survey: hippopotamus and giraffe. Proc Am Assoc Zoo Vet; 2014. p. 175.

3. Mahmood I, Martinez M, Hunter RP. Interspecies allometric scaling. Part I: prediction of clearance in large animals. J Vet Pharmacol Ther. 2006;29:415-423.

4. Soma, LR, Behrend E, Rudy J, Sweeney RW. Disposition and excretion of flunixin meglumine in horses. Am J Vet Res. 1988;49:1894-1898.

5. Toutain, PL, Autefage A, Legrand C, and Alvinerie M. Plasma concentrations and therapeutic efficacy of phenylbutazone and flunixin meglumine in the horse: pharmacokinetic/pharmacodynamic modelling. J Vet Pharmacol Ther. 1994;17:459-469.

EFFECT OF A PHYTOESTROGEN-RICH DIET ON THE MARE (*Equus caballus*) ESTROUS CYCLE: A MODEL FOR EXOTIC PERISSODACTYLA

Rachel Ferris, BS,[1]* Bruce Christensen, DVM, MS, Dipl ACT,[2] Ghislaine Dujovne, DVM, MS, Dipl ACT,[2] and Camilla Scott, DVM, Dipl ACT[2]

[1]UC Davis School of Veterinary Medicine, Davis, CA 95616 USA; [2]Department of Population Health and Reproduction, UC Davis School of Veterinary Medicine, Davis, CA 95616 USA

Abstract

Phytoestrogens are compounds in plants that possess estrogenic properties.[2] Many pelleted concentrates contain phytoestrogens, and exposure is associated with uterine changes and infertility in livestock, and reflected in mare plasma.[1,3] Phytoestrogens may hinder captive breeding success in zoological species such as the Southern white rhinoceros.[4] The goals of the study were to determine if phytoestrogen-rich diets correlate with abnormal ovulation, and to use a domestic mare model (*Equus caballus*) to evaluate risk to captive perissodactyls. The hypothesis is that mares fed a phytoestrogen-rich diet (Mazuri Herbivore, alfalfa) will show abnormal estrous cyclicity compared to a control diet (grass hay).

Study mares were placed in two treatment groups based on diet: phytoestrogen-rich (n = 6) and low phytoestrogen control (n = 6). Estrous cycles of all mares were monitored via transrectal palpation and ultrasound, evaluating interestrous intervals using cervical tone, uterine edema, and ovarian follicular growth and luteal structures. Blood samples were taken weekly for progesterone and estradiol quantification. Endometrial biopsies were taken pre and post and evaluated for pathology.

A significantly higher estradiol concentration in the treatment group suggests phytoestrogen concentrations correlate with immunoreactive estrogens in serum (P = 0.049). Differences in progesterone suggest phytoestrogens may affect progesterone production (P = 0.07). Hormone levels can affect reproductive behavior, estrous cycling, and uterine health. No gross differences were seen evaluating endometrial biopsies. Overall there was not a significant difference in abnormal cycles; however changes at the end of the study suggest time as a factor. Research with increased study period is warranted to further evaluate risks to exotic species.

Key words: Endocrine disruptor, *Equus caballus*, estradiol, estrous cycle, Perissodactyla, phytoestrogen

ACKNOWLEDGMENTS

The author would like to thank the UC Davis Theriogenology Service for help collecting data, the UC Davis School of Veterinary Medicine Students Training in Advanced Research (STAR) Program for funding the project, the Center for Equine Health for providing the research subjects, and Mazuri Exotic Animal Feed for providing the pelleted diet for this project.

LITERATURE CITED

1. Adams NR. Detection of the effects of phytoestrogens on sheep and cattle. J Anim Sci. 1995;73:1509-1515.

2. Committee on Toxicity of Chemicals in Food, Consumer Products, and the Environment. Phytoestrogens and health. London (UK): Food Standards Agency; 2003.

3. Ferreira-Dias G, Botelho M, Zagrajczuk A, Rebordao MR, Galvao AM, Bravo PP, Piotrowska-Tomala K, Szostek AZ, Wiczkowski W, Piskula M, Fradinho MJ, Skarzynski DJ. Coumestrol and its metabolite in mares' plasma after ingestion of phytoestrogen-rich plants: potent endocine disruptors inducing infertility. Theriogenology. 2013;80:684-692.

4. Swaisgood RR, Dickman DM, White AM. A captive population in crisis: testing hypotheses for reproductive failure in captive-born southern white rhinoceros females. Biol Conserv. 2006;129:468-476.

UPDATE ON ELEPHANT ENDOTHELIOTROPIC HERPESVIRUS (EEHV) IN ASIAN ELEPHANT (*Elephas maximus*) RANGE COUNTRIES: A REPORT FROM THE FIRST ASIAN EEHV STRATEGY MEETING

Lauren L. Howard, DVM, Dipl ACZM,[1]* Khajohnpat Boonprasert, DVM,[2] Chatchote Thitaram, DVM, PhD,[3] Christopher Stremme, DVM,[4] Zaw Min Oo, PhD,[5] Arun Zachariah, MSc,[6] and Sonja Luz, DVM, PhD[7]

[1]Denton A. Cooley Animal Hospital, Houston Zoo, Inc., 1513 Cambridge Street, Houston, TX USA 77030 USA; [2]Elephant Hospital, National Elephant Institute, Forest Industry Organization, Lampang, Thailand 52190; [3]Center of Excellence in Elephant Research and Education, Chiang Mai University, Chiang Mai 50100, Thailand; [4]Veterinary Faculty Center for Wildlife Studies, Syiah Kuala University, Banda Aceh / Indonesia; [5]Myanma Timber Enterprise, Department of Timber Extraction, Insein 11012, Yongon, Myanamar; [6]Centre for Wildlife Studies, Kerala Veterinary and Animal Sciences University, Pookode, Kerala, India 673576; [7]Conservation and Research, Wildlife Reserves Singapore, 80 Mandai Lake Road, Singapore 729826

Abstract

The prevalence of elephant endotheliotropic herpesvirus (EEHV) in captive Asian elephants (*Elephas maximus*) in North America is well characterized, with an estimated mortality rate of 70% in captive born elephants that become ill from the virus. Little is known about the prevalence and impact of EEHV on captive and wild Asian elephant populations in their home range countries.

In November 2015, Wildlife Reserves Singapore hosted the 1st Asian EEHV Strategy Meeting. Over 3 days, 38 veterinarians, researchers, conservationists and elephant specialists shared information, identified regional needs, and prioritized future EEHV-related projects. Eight Asian elephant range countries were represented (Thailand, Myanmar, Indonesia, Cambodia, Sri Lanka, India, Vietnam, and Malaysia) along with delegates from Singapore, the United States, Canada, and the Netherlands.

The epidemiology of EEHV in these countries remains largely unknown. More than forty cases of EEHV fatalities were identified in captive Asian elephants in this region. Three young elephants in Thailand survived EEHV infection through aggressive treatment. Twelve EEHV deaths in wild elephants were documented in India. Establishment of EEHV PCR laboratories is needed; of the countries that are home to wild Asian elephants, only three have established laboratories that can diagnose EEHV. Education of mahouts, veterinarians and governments in range countries is the first step in establishing an awareness of EEHV, which can lead to more rapid diagnosis of clinical cases and will facilitate sample collection for future epidemiologic study. Networking between and within countries will allow veterinarians to share knowledge and assist each other with sample testing and diagnosis.

Key words: EEHV, elephant endotheliotropic herpesvirus, *Elephas maximus*

DIAGNOSIS OF PREGNANCY IN WILD BOVIDAE SPECIES USING A BOVINE ASSAY FOR PREGNANCY-ASSOCIATED GLYCOPROTEINS

Benjamin Lamglait, DVM, MSc[1]* and Thomas Rambaud, DVM[2]

[1]Réserve Africaine de Sigean, Sigean, 11130, France; [2]Laboratoire Agro-Vétérinaire de Seine Maritime, Rouen, 76175, France

Abstract

Pregnancy diagnosis is an important part in reproduction management of wild ruminants involved in free-ranging and captive programs. The pregnancy-associated glycoproteins (PAGs) are a polymorphic family of placenta-expressed proteins, and released into maternal blood circulation where they can be assayed by different RIA and ELISA systems.[12] These tests have been developed and validated in domestic species; PAGs have also been isolated in a few non domestic species of the Bovidae and Cervidae families.[6,7,10] Assays have been used in many cervid species,[1,2,5,8,9,11,13-17] but in very few wild Bovidae species,[3,4] with high specificity. One hundred and twenty-six sera samples collected from mature females of 13 species were tested using a commercial ELISA test (IDEXX Bovine Pregnancy Test Kit, IDEXX Europe BV, Hoofddorp, The Netherlands). Pregnancy was determined either at necropsy (n = 7), by palpation during chemical immobilization (n = 3), or by visualization of birth (n = 42). The other sera were controls from known non-pregnant females (n = 74). Four false negatives were identified, three of them from sera collected within 30 days after mating. Following the range of use recommended by the manufacturer in domestic bovids, this test gets the following values: sensitivity = 97.9%, specificity = 100%, positive predictive value = 100%, and negative predictive value = 98.7%. Using an ELISA validated in domestic species for the detection of PAGs appears to be a rapid and inexpensive test for pregnancy diagnosis in wild Bovidae. Nevertheless, more samples are needed to determine a better range of use, and intrinsic and extrinsic values for each species.

Key words: Bovidae, diagnosis, ELISA, PAG, pregnancy, protein-associated glycoproteins

LITERATURE CITED

1. Haigh JC, Cranfield M, Sasser RG. Estrus synchronization and pregnancy diagnosis in red deer. J Zoo Anim Med. 1988;19:202-207.

2. Haigh JC, Dalton WJ, Ruder CA, Sasser RG. Diagnosis of pregnancy in moose using a bovine assay for PSPB. Theriogenology. 1993;40:905-911.

3. Haigh JC, Gates C, Ruder A, Sasser RG. Diagnosis of pregnancy in wood bison using a bovine assay for pregnancy-specific protein B. Theriogenology. 1991;36:749-754.

4. Houston BD, Robbins CT, Ruder CA, Sasser RG. Pregnancy detection in mountain goats by assay for PSPB. J Wildl Manag. 1986;50:740-742.

5. Huang F, Cockrell DC, Stephenson TR, Noyes JH, Sasser RG. A serum pregnancy test with a specific radioimmunoassay for moose and elk pregnancy-specific protein B. J Wildl Manag. 2000;64:492-499.

6. Huang F, Cockrell DC, Stephenson TR, Noyes JH, Sasser RG. Isolation, purification, and characterization of pregnancy-specific protein B from elk and moose placenta. Biol Reprod. 1999;61:1056-1061.

7. Kiewisz J, Sousa NM, Beckers JF, Vervaecke H, Panasiewicz G, Szafranska B. Isolation of pregnancy-associated glycoproteins from placenta of the American bison (*Bison bison*) at first half of pregnancy. Gen Comp Endocrinol. 2008;155:164-175.

8. Osborn DA, Beckers JF, Sulon J, Gassett JW, Muller LI, Murphy BP, Miller KV, Marchinton RL. Use of glycoprotein assays for pregnancy diagnosis in white-tailed deer. J Wildl Manag. 1996;60:388-393.

9. Ropstad E, Johansen O, King C, Dahl E, Albon SD, Langvant RL, Irvine RJ, Halvorsen O, Sasser G. Comparison of plasma progesterone, transrectal ultrasound and pregnancy specific proteins (PSPB) used for pregnancy diagnosis in reindeer. Acta Vet Scand 1999;40:151-162.

10. Rowell JE, Flood PF, Ruder CA, Sasser RG. Pregnancy-associated protein in the plasma of captive musk-oxen. J Wildl Manag. 1989;53:899-901.

11. Russel DE, Gerhart KL, White RG, Wetering DV. Detection of early pregnancy in caribou: evidence for embryonic mortality. J Wildl Manag. 1998;62:1066-1075.

12. Sousa NM, Ayad A, Beckers JF, Gajewski Z. Pregnancy-associated glycoproteins (PAG) as pregnancy markers in the ruminants. J Physiol Pharmacol. 2006;57:153-171.

13. Willard ST, Hughes DM, Bringans M, Sasser RG, White DR, Jaques JT, Godfrey RW, Welsh TH, Randel RD. Artificial insemination, hybridization and pregnancy detection in sika deer (*Cervus nippon*). Theriogenology. 1996;46:779-789.

14. Willard ST, Sasser RG, Bringans M, Hughes DM, Welsh TH, Jaques JT, Randel RD. Methods for pregnancy detection in sika deer (*Cervus nippon*). J Anim Sci. 1994;72:1309.

15. Willard ST, Sasser RG, Gillespie JC, Jacques JT, Welsh TH, Randel RD. Early pregnancy detection and embryonic mortality in fallow deer (*Dama dama*). J Anim Sci. 1994;72:67.

16. Willard ST, Sasser RG, Gillespie JC, Jaques JT, Welsh TH, Randel RD. Methods for pregnancy determination and the effects of body condition on pregnancy status in rocky mountain elk (*Cervus elephus nelsoni*). Theriogenology. 1994;42:1095-1102.

17. Wood AK, Short RE, Darling AE, Dusek GL, Sasser RG, Ruder CA. Serum assays for detecting pregnancy in mule and white-tailed deer. J Wildl Manag. 1986;50:684-687.

COMPARING FECAL EGG COUNTS TO TIME SPENT EATING IN A GROUP OF GIRAFFES (*Giraffa camelopardalis*) IN A ZOOLOGICAL PARK: A RETROSPECTIVE STUDY

Denise Lukacs, MSc[1]* and Ray Ball, DVM[2]

[1]Ontario Veterinary College, Guelph, Ontario, Canada N1G 2W1; [2] Tampa's Lowry Park Zoo, Tampa, FL 33604 USA

Abstract

Gastrointestinal parasitism in giraffes (*Giraffa camelopardalis*) has been related to significant morbidity and mortality in zoological parks.[1,4,5] Furthermore, anthelmintic resistance has been documented to *Haemonchus contortus*, a common nematode of giraffes, which has led to investigations of alternative control methods.[4-6] In this study, the average time spent eating during guest feeding programs, and individual feeding patterns, were compared retrospectively to monthly fecal egg counts in a group of four male giraffes. McMaster fecal egg counts were measured monthly for each giraffe. Amount of time spent eating during guest feeding programs was recorded daily. Previous data on daily activity time budgets in this group of giraffes was used to compare individual feeding patterns. All animals had equal opportunity to eat, with feed spread out throughout the habitat, all animals on habitat at the same time, and forage available throughout observation periods. The giraffes with higher average eating times tended to have lower fecal egg counts, while the giraffe with lower average eating times tended to have higher fecal egg counts. Interactions between diet and gastrointestinal parasitism have been suggested previously.[2,3] This study suggests that feeding management may impact gastrointestinal parasites, and warrants further investigation.

Key words: Feeding behavior, gastrointestinal parasites, *Giraffa camelopardalis*, giraffe

LITERATURE CITED

1. Clauss M, Rose P, Hummel J, Hatt J-M. Serous fat atrophy and other nutrition-related health problems in captive giraffe (*Giraffa camelopardalis*) - an evaluation of 83 necropsy reports. European Assoc Zoo Wildl Vet; 2006

2. Coop RL, Kyriazakis I. Influence of host nutrition on the development and consequences of nematode parasitism in ruminants. Trends in Parasitol. 2001;17(7):325-330.

3. Ezenwa VO. Interactions among host diet, nutritional status and gastrointestinal parasite infection in wild bovids. Int J Parasitol. 2004;34(4):535-542.

4. Fontenot DK, Miller JE. Alternatives for gastrointestinal parasite control in exotic ruminants. In: Miller RE, Fowler M (eds.). Zoo and wild animal medicine, Volume 7, Current therapy. St. Louis (MO): Elsevier; 2012. p. 581-588.

5. Garretson PD, Hammond EE, Craig TM, Holman PJ. Anthelmintic resistant *Haemonchus contortus* in a giraffe (*Giraffa camelopardalis*) in Florida. J Zoo Wildl Med. 2009;40(1):131-139.

6. Kinney A. Copper oxide wire particles for controlling intestinal parasites in giraffe. Giraffa. 2008;2(1):23.

COAGULOPATHY ASSOCIATED WITH FACTOR VII DEFICIENCY IN AN ASIAN ELEPHANT (*Elephas maximus*)

Michael Lynch, BVSc, PhD,[1]* Ken McGrath, PhD,[2] Karthik Raj, MS,[3] Philippa McLaren, BVMS, MVS,[4] Karen Payne, BVSc, MPhil,[5] Richard McCoy, PhD,[4] and Urs Giger, Dr. med. vet., MS[3]

[1]Melbourne Zoo, Parkville VIC 3052; [2]Australian Genome Research Facility, St Lucia, Qld 4072; [3]School of Veterinary Medicine, University of Pennsylvania, Philadelphia, PA 19104-6010 USA; [4]Gribbles Veterinary Pathology, Clayton VIC 3168; [5]Perth Zoo, South Perth WA 6951

Abstract

Hereditary disorders and genetic predispositions to disease have been rarely reported in captive and free-ranging wildlife; none have been thus far described in elephants. A wild caught, 41-yr-old, male Asian elephant without an apparent increased bleeding tendency was found to have consistently prolonged prothrombin times (mean PT = 55 ± 36 sec) compared to 12 other elephants (PT = 9 ± 2 sec). The proband's partial thromboplastin times fell within the range of the other elephants (12-30 sec). An isolated prolonged PT suggests a coagulation factor VII (FVII) deficiency. Indeed, the plasma FVII activity was very low (2%) compared to that of 15 other elephants (57-80%) and other coagulation factors were normal.

Sequencing of genomic DNA from EDTA blood revealed a single homozygous point mutation in the F7 gene of the FVII deficient elephant which was not present in unrelated elephants. This mutation causes an amino acid substitution which is predicted to result in reduced FVII activity. Two offspring of the affected elephant were heterozygote for the mutation and had normal plasma FVII activity and coagulation profiles. A simple DNA test has been developed to enable the screening of additional elephants for this mutation.

In conclusion, this is the first hereditary disease and coagulopathy characterized in Asian elephants. Similar to other species, FVII deficiency does not appear to cause a serious bleeding tendency. The DNA screening test will be of benefit in investigating for the presence of this mutation in other elephant populations.

Key words: Asian elephant, coagulopathy, *Elephas maximus*

ACKNOWLEDGMENTS

The authors would like to thank the staff at the Perth and Taronga Zoos for their support of this investigation. In particular we acknowledge Paul Thompson from Taronga Zoo for his coordination of sample collection and processing of samples from their elephant group. We also thank Bron Oke for her collation of data in the early stages of this investigation. Supported in part by grant NIH OD 010939.

PREVALENCE OF *Cobboldia elephantis* (Cobbold, 1866) IN FREE-RANGING ASIATIC ELEPHANTS (*Elephas maximus*) OF TAMIL NADU, INDIA

Nachimutu Sadiyappan Manoharan, MVSc,[1]* Kadirvelu Senthilkumar, MVSc, PhD,[2] Sankaralingam Gomathinayagam, MVSc, PhD,[3] and Madurai Ganesan Jayathangaraj, MVSc, PhD[2]

[1]Forest Veterinary Officer, O/o the Additional Principal Chief conservator of Forests (Project Tiger), Coimbatore-641 043, India; [2]-Faculty of Wildlife Science, Madras Veterinary College, TANUVAS, Chennai-600 007, India; [3]- Faculty of Veterinary Parasitology, Madras Veterinary College, TANUVAS, Chennai, India

Abstract

Cobboldiasis is commonly reported in Asiatic elephants.[1-5,7] Parasite loads were evaluated[6], and maggots of the fly *Cobboldia elephantis* were recovered from the stomach contents of 42 wild Asiatic elephants (28 males, 14 females) of Tamil Nadu, Southern India during the period 2005-2015. Amongst the multiple infections of parasites, high prevalence of *C. elephantis* (45%) was observed followed by 36% prevalence of mixed infection and 9% Strongyles. To date, only a single species of *C. elephantis* has been reported in India which is identified based on the morphologic features of mature bots, such as the anterior end containing two powerful oral hooks with cephalopharyngeal skeleton and the abdominal segments with a row of belt like spines. In addition to this, the characteristic posterior spiracles with three longitudinal parallel slits in each posterior spiracle confirm the bots as the larvae of *C. elephantis*. The length of an adult fly ranges from 2 to 3 cm. From each elephant, a total number of more than 500 stomach bots were recovered. On removal of these maggots the gastric wall was found to contain small sized ulcers. Congestion and severe inflammation of the gastric mucosa was also noticed. Histopathologic examination revealed epithelial cells with hydropic or ballooning changes. Eggs of these flies were noticed on the teeth and the base of the tusks.

Key words: Asian elephant, cobboldiasis, *Elephas maximus*

LITERATURE CITED

1. Chakraborthy A, Gogoi AR, Chaudhury B. Prevalence of parasitic infection in captive wild herbivores in a Zoo in Assam. Int J Anim Sci. 1994;9:149-152.

2. Colwell DD, Otranto D, Stevens JR. Oestrid flies: eradication and extinction versus biodiversity. Trends Parasitol. 2009;25(11):500-504.

3. Miller D, Jackson B, Riddle HS, Stremme C, Schmitt D, Miller T. Elephant (*Elephas maximus*) health and management in Asia: variations in veterinary perspectives. Vet Med Int. 2015: Article ID 614690

4. Panda SK, Panda DN, Parhi NK. Occurrence of *Cobboldia elephantis* (Cobbold, 1866) larvae in a wild elephant. J Vet Parasitol. 2005; 19(2):163-164.

5. Sanyathitiseree P, Pinyopanuwat N, Phasuk J, Prasitiphol S, Yatbantoong N, Mueangthong N, Kasorndorkbua C. Prevalence of stomach bot flies in a wild elephant from Kanchanaburi province. J Kasetsart Vet. 2009;19(1):42-47.

6. Vanitha V, Thiyagesan K, Baskaran N. Prevalence of intestinal parasites among captive Asian Elephants *Elephas maximus*: effect of season, host demography, and management systems in Tamil Nadu, India. J Threat Taxa. 2011; 3(2):1535-1541.

7. Venu R., Singh TT, Veeraharin R, Rajesh D, Srilatha C. First report of *Cobboldia elephantis* (Cobbold, 1866) larvae in a free ranging wild elephant from Andhra Pradesh, India. J Parasitol Dis. 2013:39(2):168-170.

EFFECT OF IMPROVAC® ON SPERM VARIABLES, TESTOSTERONE SECRETION AND ACCESSORY SEXUAL GLANDS SIZE OF PYGMY GOAT (*Capra hircus*): A MODEL FOR CONTRACEPTIVE TREATMENT OF WILD RUMINANTS

Eva Martínez-Nevado, DVM,[1]* Adolfo Toledano-Díaz, Dr. biol. sci., PhD,[2] Juncal García García, DVM,[1] Rosario Velázquez, CHEM,[2] Cristina Castaño, DVM,[2] Milagros C. Esteso, DVM, PhD,[2] Antonio López-Sebastián, DVM, PhD,[2] Rodolfo Ungerfeld, Dr. biol. sci., PhD,[3] and Julián Santiago-Moreno, DVM, PhD[2]

[1]Zoo-Aquarium Madrid, 28011 Madrid, Spain; [2]Department of Animal Reproduction, INIA, 28040 Madrid, Spain; [3]Faculty of Veterinary Sciences, Universidad de la República, 11600 Montevideo, Uruguay

Abstract

Pygmy goats (*Capra hircus*) are common in zoos and easy to handle. Hence, they may be a useful model to study the effects of contraceptive treatment on reproductive function of wild ruminants. To determine the effect of Improvac (Pfizer, Kent, CT139NJ, UK), an anti-GnRH vaccine, 10 adult bucks were divided into three groups: controls without treatment (C group, n = 3), long-treated with Improvac (2 ml s.c. every 6 mo in 2012, 2013 and 2014; LT group, n = 3), and short-treated with Improvac (two doses of 2 ml s.c. 4 wk apart, in January and February 2014; ST group, n = 4). Reproductive parameters were analysed twice monthly in winter, and monthly in spring, summer and autumn of 2014. The treatment had significant influence ($P < 0.05$) on maintaining testosterone secretion with basal plasma concentrations through the experimental period in LT group. The testes, bulbourethral glands, and seminal vesicles did not vary over the studied period, and remained a small size in LT, unlike C and ST groups. One buck of LT group did not ejaculate, or the sample obtained was azoospermic, during winter 2014. Sperm concentration and sperm morphologic abnormalities showed the lowest ($P < 0.05$) values in LT group. Treatment did not affect other sperm variables, such as sperm viability and plasma membrane integrity. In conclusion, LT but not ST treatment was effective to decrease reproductive activity. However, this treatment did not prevent fully spermatogenesis activity, and thus animals were not sterile throughout the experimental period.

Key words: Anti-GnRH, *Capra hircus*, contraception, Improvac®, pygmy goat, ultrasonography

CAPTURE OF FREE-RANGING MULE DEER (*Odocoileus hemionus*) WITH A COMBINATION OF MEDETOMIDINE, AZAPERONE AND ALFAXALONE

Amélie Mathieu, DMV,[1]* Nigel Caulkett, DVM, MVetSc, Dipl ACVAA,[2] Patrick M. Stent, RPBio,[3] and Helen M. Schwantje, DVM, MSc[4]

[1]College of Veterinary Medicine, The Ohio State University, Columbus, OH 43210 USA; [2]Department of Veterinary Clinical Sciences, Faculty of Veterinary Medicine, University of Calgary, Calgary, AB T2N 41N4 Canada; [3]British Columbia Ministry of Forests, Lands and Natural Resource Operations, Cranbrook, BC V1C 7G5 Canada; [4]British Columbia Ministry of Forests, Lands and Natural Resource Operations, Victoria, BC V8W 9M1 Canada

Abstract

The combination of medetomidine, azaperone and alfaxalone has been successfully used to anesthetize captive and free-ranging white-tailed deer (*Odocoileus virginanus*).[1, 2] This same combination was utilized to immobilize 14 free-ranging female mule deer (*Odocoileus hemionus*) in the East Kootenay region, British Columbia, Canada for radio collaring. Physiologic data were collected to assess the safety and reliability of this drug combination in this species. Medetomidine (0.16 ± 0.05 mgkg^{-1} [mean ± SD]), azaperone (0.21 ± 0.07 mgkg^{-1}) and alfaxalone (0.47 ± 0.2 mgkg^{-1}) were administered IM, via a Dan-Inject^{R} darting system. Time to sternal recumbency was 8.2 ± 4.2 min. Sternal recumbency was achieved in all animals with one dart. Five deer received partial injection due to dart failure and required supplemental drugs to induce lateral recumbency. Inductions were calm, (mean time to lateral recumbency of 16.7 ± 9.5 min) and recoveries were smooth and uneventful (time to standing, 9.0 ± 3.4 min) for all but one deer, who died shortly after atipamezole administration (5 times the medetomidine dose). Histopathology of this deer revealed mild bronchopneumonia along with *Echinococcus* cysts and lung worms. The major side effects of the combination were hypoxemia (PaO_2 42.8 ± 10.3 mmHg), and hypercapnia ($PaCO_2$ 57.0 ± 4.8 mmHg). Although commonly encountered in deer anaesthetized with medetomidine-based combinations, the observed hypoxemia and hypercapnia was more pronounced, in some individuals, than expected and may be reflective of subclinical respiratory diseases in this population. This is a potentially useful combination for capture of wild mule deer.

Key words: Anesthesia, alfaxalone, azaperone, medetomidine, mule deer, *Odocoileus hemionus*

LITERATURE CITED

1. Caulkett N, Mathieu A, Schwantje H. Capture of free-ranging white-tailed deer (*Odocoileus virginanus*) with a combination of medetomidine, azaparone and alfaxalone. Proc Int Conf Dis Zoo Wild Anim; 2015. p. 35.

2. Pon K, Caulkett N, Woodbury M. Efficacy and safety of medetomidine-azaperone-alfaxalone combination in captive white-tailed deer (*Odocoileus virginianus*). Proc Am Assoc Zoo Vet; 2015. p. 76-77.

PROPOSED GUIDELINES FOR NATIONAL MOVEMENT OF BOVIDAE SEMEN BETWEEN ZOOLOGICAL INSTITUTIONS

Linda M. Penfold, PhD,[1]* Natalie Hall, DVM, Dipl ACZM,[2] and Geoff Pye, DVM, Dipl ACZM[2]

[1]South-East Zoo & Aquariums for Reproduction & Conservation, Yulee, Fl 32097; [2]Disney's Animal Programs and Environmental Initiatives, Bay Lake, FL 32830 USA

Abstract

Managed programs in zoos and aquariums are increasing efforts to generate sustainable animal populations drawing upon technologies such as artificial insemination (AI) with frozen-thawed sperm. The movement of bovidae semen rather than translocation of a herd male allows the potential to increase productivity by the male remaining with a herd while collecting and shipping semen for use in another herd. It is important to remember that most bacterial and viral diseases can be transmitted via semen and AI, and the transfer of semen from an animal to cryostorage is equivalent to moving animals from one zoological collection to another. Appropriate donor disease testing along with semen collection, handling, processing and cryopreservation is imperative to reduce the risk of inadvertent introduction of disease into an animal collection or cryostorage tank. Each storage tank should be considered a 'zoo collection' and transfer of biomaterials into it should follow normal risk-based management for pathogen hazards. Health exams and disease screening of the semen donor are no less important than if the live animal was shipped because of the risk of recipient transfection through AI. This includes identification and risk assessment of the potential pathogen hazards and risk mitigation by labelling straws to track individuals, testing of the donor to determine the semen is disease-free, and isolation of the semen in a quarantine tank until the pathogen status is known to prevent cross contamination of other stored samples (similar to zoo collection quarantine). Development of standardized guidelines ensures reliability and repeatability of research techniques as they are translated to management tools.

Key words: Guidelines, semen

PORCINE ZONA PELLUCIDA (PZP) VACCINATION IN A FREE-ROAMING FERAL HORSE POPULATION FOLLOWING INDIVIDUAL CHEMICAL IMMOBILISATION AND REMOTE BOOSTER: IS IT FEASIBLE?

Ovidiu Rosu, DVM,[1,2]* Alin I. Birtoiu, DVM, Prof[2] and Schwarzenberger Franz, DVM, A. Prof[3]

[1]University of Agronomic Sciences and Veterinary Medicine Bucharest, Faculty of Veterinary Medicine, 050097 Bucharest, ROMANIA; [2]Vier Pfoten Romania, Maica Alexandra 24, 011243 Bucharest, Romania; [3]University of Veterinary Medicine, Veterinarplatz 1210 Vienna, Austria

Abstract

The objective of this study was to assess the outcome of a porcine zona pellucida (PZP) immuno-contraceptive program in a free ranging feral horse population (n = 530) in the Romanian Danube Delta. Specifically, the feasibility of PZP administration to individually immobilized mares, with subsequent remote booster administration by dart gun was tested. Until 2011, the management of our study population consisted of frequent round-ups for slaughter. Those activities were cruel and actively condemned by the public. For the PZP contraception program a total of 150 mares were chemically immobilized, marked, and vaccinated. Mares were divided into a PZP treatment and a control group. The mares in the treatment group (n = 101) were vaccinated and then partially boostered (n = 49) with PZP during October 2013-May 2014. From this group, freshly dropped fecal samples of 41 individuals were collected after 12-15 mo (in December 2014-May 2015). During this later period, 49 additional mares were immobilized. These mares were used as a control group for endocrine pregnancy diagnosis and blood and fecal samples from n = 38 mares were analyzed. Samples were tested for estrogens and 20α-OH-pregnanes to assess for pregnancy rates. The pregnancy rate of the PZP treated mares was 14.6% as compared to 81.5% of the control group, although 44% of the mares did not receive a booster injection. The horses showed a cumulative behavioral aversion to darting, with first darts being delivered from a distance of about 25-30 m but the following darts from 40-60 m. We conclude that a PZP contraception program through individual immobilization followed by remote booster administration is a feasible alternative solution to the traditional stressful roundups. Nevertheless this approach is time and resource consuming, stressing the need of a reliable product with multiple year effectiveness without booster.

Key words: Chemical immobilization, feral horse, immuno-contraception, porcine zona pellucida, PZP

Introduction

Local high numbers of feral horses (*Equus caballus*) can rapidly deplete available resources through overgrazing. To avoid negative ecological effects, management tools to regulate horse population sizes are needed. The management practice for a population of free-ranging feral horses in the Romanian Danube Delta until 2011 consisted of frequent round-ups of horses for slaughter. These procedures were organized on the basis of overgrazing and equine infectious anemia (EIA)

outbreaks. Those activities were done in brutal ways, were highly stressful for the animals, and actively condemned by the public.[4,6]

Fertility control has emerged as a valuable alternative to such methods. In recent decades, immuno-contraceptive vaccines using antigens such as porcine zona pellucida (PZP) or gonadotropin- releasing hormone (GnRH) have been used to limit reproduction in feral horses.[3,5,7,9,12] Because of the relative ease of their application, expected efficacy and duration, and anticipated lack of side-effects, these vaccines are of special interest for free-ranging animals.

The most common approach uses PZP protein antigens, which elicit antibodies that act primarily by occupying sperm-binding sites on the surface of the mammalian ovum, thus blocking fertilization.[7,10,17] These vaccines require a primary inoculation followed by one or two boosters over a period of a few weeks. The effective duration of these vaccines has typically been <1 yr; consequently, annual boosters are required.[8]

A commonly used method for the application of immuno-contraceptive vaccines is to round up free-ranging horses in corals. The objective of this study was to assess the feasibility and outcome of a PZP immune-contraceptive program on an approximately 530 free-roaming feral horse population, in the Romanian Danube Delta, following individual capture and remote booster delivery.

Study Area

The study area, Grindul Letea, is located in Tulcea county, in the North-West of the Romanian Danube Delta (latitude 45 º 20'N, longitude 29º 30'E). This area is encircled by river branches (in the North the Chilia Channel, in the South the Sulina Channel, in the East- fish farms) and the Black Sea in the West. Due to the natural barriers it is assumed that the horses are limited to the area of Grindul Letea. The human population in this area is 700 people living in five villages (Cardon on the South, Letea, C.A. Rosetti , Sfistofca in the middle and Periprava in the North).

The size of Grindul Letea is approximately 10000 ha, including about 3800 ha grazing pastures and 5400 ha of forest. Part of this forest is the 2825 ha Letea forest, a UNESCO heritage strictly protected area, managed by the Danube Delta Biosphere Reserve Authority and ROMSILVA. The landscape and vegetation consists of dunes with forest and dune pastures, saline pastures, Hippophae shrubs, swamps and water channels. The main forest trees are oak species (*Quercus robur*, *Q. pedunculiforma*), poplar (*Populus alba*, *P. canescens*, *P. tremula*), ash trees (*Fraxinus angustifolia*, *F. excelsior*, *F. pallisae*), and different other shrubs and climbers (*Vitis silvestris*, *Periploca praeca*). The pastures are represented mainly by graminoids (46%), Juncaceae-Cyperaceae (31%) and legume (18%).[11]

Aerial counts of free-ranging horses and cows were performed in May 2013, April 2014 and March 2015. The estimated population size was 530 horses and 800 cows.[14] The foaling period of Grindul Letea horses starts from March and lasts until May, however some foals are born as soon as February and as late as June. The estrous period lasts from March to July.

Materials and Methods

The fieldwork for this study was conducted during two periods, October 2013-May 2014 (first season) and December 2014-May 2015 (second season). A core team of two people and occasionally a volunteer were involved in the vaccination. About 40 days per vaccination season were spent in the field, regardless of weather. During the fieldwork ambient temperatures ranged from -13.4ºC to 21ºC with an average of 6.2ºC. The average wind speed was of 6.3 m/sec with a maximum of 21 m/sec.

Results are presented for two distinct groups of mares. The treatment group is comprised of the horses immobilized, vaccinated with PZP, fecal/blood sampled and boostered during October 2013-May 2014 (first season). From this group fresh fecal droppings were collected for pregnancy analysis during the second fieldwork period (December 2014-May 2015).

During this second fieldwork period additional mares were immobilized, PZP treated and fecal/blood sampled. As pregnancy outcomes for these mares were not available during the submission process of these proceedings, samples collected from these mares are referred to as the control group.

PZP Vaccine Preparation

The PZP was provided by the Science and Conservation Center, Billings, MT 59106 USA and imported to Romania under the 14924 research study permit issued by the ANSVSA on 15 October 2012.

The primer portion of the vaccine consisted of an emulsion of 0.5 ml Freund's Complete Adjuvant with 100 µg lyophilized PZP dissolved in 0.5 ml sterile saline. The vaccine components were mixed using two connected sterile 3-ml plastic syringes; 100 plunger strokes were made following the producer indications.[7] The milky emulsion was injected i.m. deep in the rump of the immobilized mares using an 18-gauge, 3.8-cm needle, after the injection site was scrubbed with ethanol (70%).

After a period of at least 1 mo elapsed, the recipient horses were tracked and the second PZP (booster) was administered remotely by dart gun. The booster vaccines were prepared as the primer, and consisted of an emulsion of 100 µg PZP and 0.5 ml of Freund's Incomplete Adjuvant. For remote delivery, a 1-ml gel barbed Pneudart type ("P"® darts, Pneudart, Inc., Wiliamsport, USA) with a 3.8-cm needle was used.

Accessing and Inoculating Horses

For the application of the primer dose of PZP, feral mares were chemically immobilized from distance.[15,16] Depending on the body size, mares at least 2 yr old were selected.

After being located, the mares were slowly approached and darted from the car or by foot. Distances between 15-60 m allowed targeting the rump while the individuals remained relaxed and not moving fast. The horses showed a cumulative behavioral aversion to darting. The first

darts were shot from a distance of about 25-30 m but the following darts from 40-60 m. Different approaches to get closer to the animals for safe darting had to be developed. In some cases the horses were pushed with the car towards a hidden person that could dart them. Others were approached by slowly crawling on the ground or hiding through the vegetation.

The identification and vaccination protocol included a general health check, ear tagging on both ears, microchipping, photographing of individual characteristics, age determination based on dentition and physical condition. Fecal and blood samples for reproductive hormone testing, as well as location coordinates were collected, and PZP vaccination was applied. This protocol took up to 40 min. After about 60-70 min from the time of anesthesia induction the animals were awake and standing.[16] During the first season, the dimensions of the ear tags used was 4.9 × 1.8 cm. Later bigger ear tags (4.5 × 6.1 cm) were used.

For the booster shots, as many animals as possible were targeted. Booster shots were remotely administered to individually identified PZP treated mares approximately after 1 mo. The recipient horses were spotted using a 50x optical zoom photo-camera (Canon SX50 HS), a 22-66x100 mm spotting scope (Celestron Ultima 100). Pelage color, ear tags, and individual markings were compared with the photographs, band adhesion, and specific markings database.

The PZP-producer recommends the booster darts should aim for the rump. However, due to the terrain conditions, in several instances neck muscles, front leg muscle mass, abdomen, and thorax were hit. In most occasions the darts were seen discharging on impact through the dart gun scope. The darts usually remained attached on the animal for a couple of minutes until they fell off and whenever possible they were picked up.

The average gestation period for a horse is 335-342 days[1]; thus, mares are often pregnant when they receive a contraceptive agent, and the effect of contraception is not seen until the second foaling season following immunization.

Sample Collection

During the immobilization procedures, blood and fecal samples were collected in 20 ml containers. For management purposes mares at least 2 yr old were immobilized and vaccinated, but for the analysis of endocrine results, only reproductively mature ones (>3 yr old and >250 kg BW), were taken into account. Some of the fecal and blood samples collected from the field were lost because labels could not be identified after thawing in the laboratory.

The samples were labeled, stored on ice, and frozen at -20° C within 12 hr of collection. For endocrine analysis samples were sent to the University of Veterinary Medicine Vienna, Austria. The serum was tested for 20α-OH-pregnanes (20α-OH-P) and the feces for 20α-OH-P and estrogens (EG).[18] In the feces the cut off for positive pregnancy diagnosis was considered to be >15 ng/g for EG and >1000 ng/g for 20α-OH-P. In the serum this value was >2 ng/ml for 20α-OH-P. The cut off for negative pregnancy diagnosis was <10 ng/g for EG and <700 ng/g for 20α-OH-P from the feces and <1 ng/ml for 20α-OH-P from the serum.[18]

Other results that were in between those levels were labeled as likely pregnant or likely non-

pregnant. Criteria for these assessments were made by evaluating endocrine results of fecal and serum samples in accordance with estimated age, time of sampling and mare body weight and shape, choosing the most logical probability of positive or negative pregnancy.

Results and Discussion

Individuals Reached and Sampling

During the two fieldwork seasons a total of 150 free-range mares were chemically immobilized: 101 mares in the first season, (October 2013-May 2014), and 49 in the second season (December 2014-May 2015).

Although 101 mares were immobilized and vaccinated with the primer PZP by the end of the first vaccination season (May 2014), remote delivery of the booster could only be administered to 49 mares. Reasons were difficult identification of the mares, horse skittish behavior, and harsh terrain. From the 101 vaccinated mares, 41 freshly dropped fecal samples were collected in the period of December 2014-May 2015. Feces were collected whenever a sample could unequivocally be assigned to an individual, regardless whether or not the mare received a booster in the previous season.

Fecal/blood Pregnancy Results

From all samples collected in the first season, only the fecal and blood samples of 85 distinct individuals were suitable for hormone analysis and pregnancy interpretation (shown in Table 1). Pregnancy rates were calculated for the periods before the PZP vaccine could elicit an immune response. Including the likely pregnant (n = 9) and likely non-pregnant (n = 1) results, the gestation rate was of 67%.

The pregnancy rate for the control group of mares immobilized during the second field season was of 81.5%. This result was calculated from (n = 38) mares for which fecal and blood samples were available and includes one likely pregnant and one likely non-pregnant individual.

The pregnancy rate in 2015 for the treatment group immunized in the first season with the PZP vaccine was 14.6 %, including likely pregnant (n = 0) and likely non-pregnant (n = 4) individuals. Pregnancy was assessed from fresh, individually identified fecal samples collected from December 2014 to May 2015 (n = 41). From these mares 23 (56%) females received a booster and 18 (44%) did not. Two mares were pregnant despite receiving previously the booster and another four were also pregnant but without receiving the booster.

Twelve juveniles (2-3 yr old, 175-225 kg) were captured in the first season, from which seven were sampled in the second season showing no signs of pregnancy. If we would include these juveniles in the treatment group, considering that the vaccine could have started to work just before the juveniles become reproductively mature, the overall pregnancy rate for the treatment group in season two would drop from 14.6% to 12.5%.

Three pregnant mares were dismissed from the calculations of the post treatment PZP group (Table

1) because we cannot say for sure whether the animals were pregnant during the PZP application in the first season and the sample collection for endocrine diagnosis in the second season. From those mares, one was non-pregnant when it received the PZP vaccination and the PZP booster in 2014. After 14 mo a fecal sample collected from this mare in April 2015, indicated early pregnancy. We assume that the effect of the vaccine wore off before or during the breeding period in 2014 and once mounted she eventually became pregnant. The other two mares, both showing early pregnancy hormone levels at the time of the vaccination (April 2014), one of them receiving also the booster, were sampled in February 2015. The samples showed they were pregnant, thus most probably the vaccine was made just after the females were fertilized.

Other Findings

Comparing with other populations of feral horses, the Danube Delta ones have generally black and bay robes (98%), with few individual markings that made the identification of individual horses extremely difficult. Darted mares (n = 150) were mainly bay (55.3%) and black (42.6%) with a couple of greys (2%). From the bays and blacks only 26.5 % and respectively 20.3% had small, natural markings such as stars or head and leg white stripes, relatively clearly visible from distance. The average age of all darted mares was $\bar{x}$ =5.36 yr with a minimum of 2 and a maximum of 17 yr. Pregnancy rate within the group of older animals (more than 8 yr old; n = 31) was 51.61 %, and thus lower than the population average of about 80%. These results confirm previous studies describing foaling rates in sexually mature feral horses remaining high through middle age, and a decrease in older mares.[2,13] One case of ear infections and frequent light head shaking was seen due to the ear tags, nevertheless no negative impact on animal welfare and behavior was observed. During both seasons, eight mares out of 150 captured died. Four deaths were directly attributed to the anesthesia: two died during the anesthesia due to hypoxemia; one was euthanatized due to capture myopathy complications and one died 3 days after the capture due to a progressive degenerative state which could have been associated with stress induced toxemia. The other four horses presumably died of natural causes, months after the vaccination. They were found dead on the field by chance or we were informed by the locals about their body.

Summary

Until 2011, frequent round-ups were organized in Danube Delta to extract free ranging feral horses on the basis of overgrazing and EIA outbreaks. Groups of horses were chased and directed by motorcycles and horse riders into corrals where the adult animals were selected for slaughter and the foals were left behind. Those activities were done in brutal ways, were highly stressful for the animals and actively condemned by the public. Backed up by the media and general public the Animal Welfare NGO 'Vier Pfoten' (Four Paws) in collaboration with the Faculty of Veterinary Medicine, Bucharest and NSVSFA (National Sanitary, Veterinary and Food Safety Authority) proposed the start of a pilot birth control program as an alternative measure to the roundups.

In total, 150 mares were chemically immobilized from October 2013 to May 2015 during 80 days of fieldwork. Results showed that the pregnancy rate of the treated mares in the year post vaccination decreased to 14.6% as compared to 81.5% of the control group, although 44% of the females did not receive a booster. This supports a previous study, where contraception was achieved with only one PZP application.[7] Although the PZP vaccine in the first season seems to

have been very efficient for contraception, follow up studies are necessary to determine how long the vaccination is effective, and the effect of a PZP booster injection. The specific period of the vaccination before the beginning of breeding period obviously was a good timing.

Beside the usual identification by pelage colour, band association and natural markings, ear tagging the animals and reading the numbers from distance with a big lens photo-camera and a scope improved considerably the identification of horses. In the second season of vaccination bigger eartags were used, making the identification from distance and boostering easier. Considerable time was spent searching the dropped darts and identifying the horses based on the ear tags to administer the booster. Finding the treated mares to deliver the booster was considered the most difficult task.

The project costs summed up to around 450€/immunised horse, which included the vaccines, chemical immobilizations, medicines, transport, accommodation, logistics and salaries for 3 people. All logistics were bought and used according with the birth control program requirements. Except logistics, the specific cost for one vaccination including vaccine, anesthetic related substances, dart syringes, ear tags, microchips, medical materials summed up to 100 €/ immunized horse.

The authors of this article conclude that a PZP contraception program through individual immobilization followed by remote delivery is a feasible alternative solution to the classical stressful roundups. Nevertheless this approach is time and resource consuming, stressing the need of a reliable product with multiple year effectiveness without booster. To this author's knowledge this is the first study done on a free ranging feral horse population, using individual chemical immobilisation, with the aim of identifying mare for further application of PZP boosters and with the possibility of studying the long term outcome of the program.

LITERATURE CITED

1. Card CE, Hillman RB. Parturition. In: McKinnon AO, Voss JL (eds.). Equine reproduction: Williams & Wilkins. 1993;567-573.

2. Garrott R A, Taylor L. Dynamics of a feral horse population in Montana. J Wildl Manage. 1990;54:603-612.

3. Gray ME, Thain DS, Cameron EZ, Miller LA. Multi-year fertility reduction in free-roaming feral horses with single injection immunocontraceptive formulations. Wildl Res. 2010;37:475-481.

4. Hobbs NT, Bowden DC, Baker DL. Effects of fertility control on populations of ungulates: general, stage-structured models. J Wildl Manag; 2000:64:473-491.

5. Killian G, Thain D, Diehl NK, Rhyan J, Miller L. Four-year contraception rates of mares treated with single-injection porcine zona pellucida and GnRH vaccines and intrauterine devices. Wildl Res. 2008;35:531-539.

6. Kirkpatrick JF, Frank IKM. Wildlife contraception. In: Asa CS, Porton IJ Contraception in free-ranging wildlife. Baltimore (MD): Johns Hopkins University Press. 2005; p. 195-221.

7. Kirkpatrick JF, Liu IKM, Turner, JW Jr. Remotely delivered immunocontraception in feral horses. Wildl Soc Bull. 1990;18:326-330.

8. Kirkpatrick JF Turner JWJr, Liu IKM, FAYRER-HOSKEN A. Applications of pig zona pellucida

immunocontraception to wildlife fertility control. J Reprod Fertil. Suppl. 1996;50:183-189.

9. Kirkpatrick JF, Turner A. Achieving population goals in a long-lived wildlife species (Equus caballus) with contraception. Wildl Res. 2008;35:513-519.

10. Liu IKM, Bernoco M, Feldman M. Contraception in mares heteroimmunized with pig zonae pellucidae. J Reprod Fertil. 1989;85:19-29.

11. Pîrvulescu R, Torok L, Covaliov S. Cercetarea evolutiei zonei cu regim de protectie integrala Padurea Letea din R.B.D.D., in contextul impactului asupra vegetatiei produse de populatia de cai semi-salbatici. contract 422 / 2010 In: Forests, M. O. E. A. (ed.). Tulcea: Danube Delta National Institute for Research and Development (INCDD). 2012; p. 43-46.

12. Ransom JI, Roelle JE, Cade BS, Coates-Markle L, Kane AJ. Foaling Rates in Feral Horses Treated With the Immunocontraceptive Porcine Zona Pellucida. Wildl Soc Bull. 2011;9999:1-9.

13. Roelle JE, Singer FJ, Zeigenfuss LC, Ransom JI, Coates-Markle L, Schoenecker KA. 2010. Demography of the Pryor Mountain wild horses, 1993-2007 Reston, Virginia, USA. U.S. Geological Survey Scientific Investigations Report; 2010. p. 5125.

14. Rosu O, Roman E, Raport privind numaratoarea cabalinelor din Grindul Letea, Vier Pfoten DGCO - ANSVSA Bucharest, Romania, nr. Report 2014-288

15. Rosu O, Udrescu LA, Birtoiu A. Alternative chemical immobilisation in a group of captive feral horses using a homemade remote delivery. Proc Int Conf Dis Zoo Wild Anim. 2012; p.176-180.

16. Rosu O, Udrescu LA, Birtoiu D, Manu E. Chemical immobilisation of Letea feral horses (Equus caballus) using ketamine and medetomidine. Proc Int Conf Dis Zoo Wild Anim. 2014; p.190-195.

17. Sacco AG. Antigenic cross-reactivity between human and pig zona pellucida. Biol Reprod. 1977; 16:164-173.

18. Schwarzenberger F, Mostl E, Bamberg E, Pammer J, Schmehlik O. Concentration of progestagens and oestrogens in the faeces of pregnant Lipizzan, Trotter and Thoroughbred mares. J Reprod Fertil Suppl. 1991;44: 489-499.

Table 1. Pregnancy rate before and after vaccination with PZP.

		PREGNANT				NON PREGNANT				Total no. of adult mares tested	Total no. of mares tested including immunised juveniles
TREATMENT GROUP PRE PZP (1st Season)	Samples pregnancy assessment	Clear		Likely		Clear		Likely			
	No. of mares tested pre PZP	48		9		27		1		85	
	Pregnancy rate	67 %				33 %					
TREATMENT GROUP POST PZP (2nd Season)	Booster delivered in 1st Season	yes		no		yes		no			
	Samples pregnancy assessment	Clear	Likely	Clear	Likely	Clear	Likely	Clear	Likely		
	No. of mares tested post PZP	2	0	4	0	19	2	12	2	41	48
	Pregnancy rate	**14,6 %**				**85,3 %**					
	Juveniles	0		0		1		6			
	Pregnancy rate including juveniles	12,5 %				87,5 %					
CONTROL GROUP (2nd Season)	No. of mares tested	30		1		6		1		38	
	Pregnancy rate	**81,5 %**				**18,4 %**					

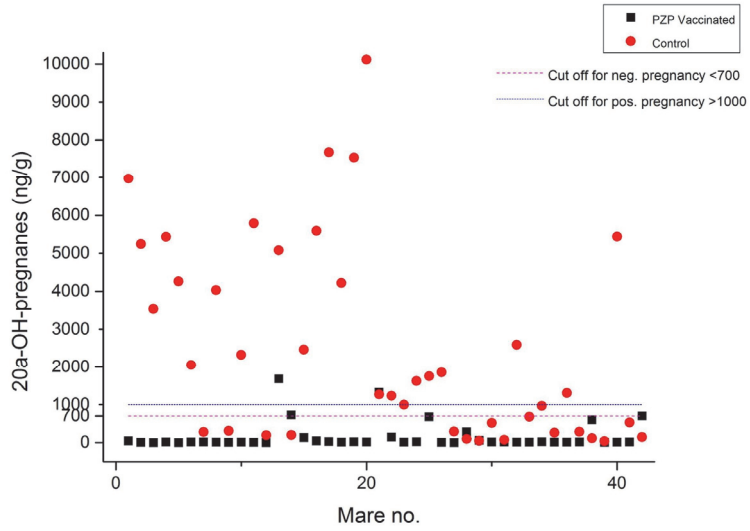

Figure 1. Fecal 20α-OH-pregnane level of the PZP vaccinated and the control mares.

TREATMENT OF AN ASIAN ELEPHANT (*Elephas maximus*) WITH FLUOXETINE

Valarie V. Tynes, DVM, Dipl ACVB,[1]* Steven E. Scott, DVM,[2] and Lydia P. Young, DVM[2]

[1]Veterinary Services, Ceva Animal Health, Lenexa, KS 66215 USA; [2]The Elephant Sanctuary in Tennessee, Hohenwald, TN 38462 USA

Abstract

A 51-yr-old female Asian elephant (*Elephas maximus*) was examined due to a recent increase in aggression towards keepers and herd mates. She also regularly exhibited many behaviors considered to be associated with anxiety or stress in elephants such as frequent trunk sucking, "tongue play" and repetitive rubbing on the bars of her pen. She was housed with two other elephants in a partly wooded 15 acre paddock with a barn, in which the elephants were confined at night and during the coldest winter months. Historically, haloperidol had been used intermittently to decrease her aggression with varying degrees of success reported by different keepers and veterinarians. At the time of evaluation by a veterinary behaviorist, she had been receiving haloperidol for approximately 4 mo with an increase in dose approximately 3 mo earlier. At the conclusion of the visit, the haloperidol dosage was decreased slowly over a period of several weeks and fluoxetine begun at a low dose of 0.25 mg/kg and increased slowly over a period of 2-4 wk.[1] Within 2 mo, fluoxetine was being administered at 1 mg/kg daily with minimal effects on appetite and a slight decrease in aggressive and anxiety related behaviors. Over the following months, anxiety related behaviors and aggression continued to decrease, and blood counts and serum chemistry profiles repeated at 6 mo and 1 yr demonstrated no abnormalities likely to be associated with the administration of fluoxetine. This case suggests that fluoxetine is safe and may be useful at managing aggression associated with anxiety in Asian elephants.

Key words: Aggression, anxiety, Asian elephant, *Elephas maximus*, fluoxetine, haloperidol

LITERATURE CITED

1. Crowell-Davis SL. Selective serotonin reuptake inhibitors. In: Crowell-Davis SL, Murray T (eds.). Veterinary psychopharmacology. Ames (IA): Blackwell Publishing; 2006. p. 80-110.

DIAGNOSIS AND SHEDDING INCIDENCE OF ELEPHANT ENDOTHELIOTROPIC HERPESVIRUS IN SWISS CAPTIVE ASIAN ELEPHANTS (*Elephas maximus*)

Sandra Wenger, Dr med vet, Dipl ECVAA, Dipl ACZM,[1]* Jean-Michel Hatt, Prof Dr med vet, Dipl ECZM (avian), Dipl ACZM,[1] Hanspeter Steinmetz, Dr med vet, Dipl ACZM,[2] and Mathias Ackermann, Prof Dr med vet[3]

[1]University of Zurich, Vetsuisse Faculty, Clinic for Zoo Animals, Exotic Pets and Wildlife, 8057 Zurich, Switzerland; [2]Knies Kinderzoo, 8640 Rapperswil, Switzerland; [3]University of Zurich, Vetsuisse Faculty, Institute for Virology, 8057 Zurich, Switzerland

Abstract

Elephant endotheliotropic herpesviruses (EEHV) can cause fatal hemorrhagic disease in Asian elephants (*Elephas maximus*).[1,2] At Zurich zoo, routine trunk washes using 50 ml saline were performed weekly in two male and five female Asian elephants, representing two matrilinear lines, over 6 wk. DNA was extracted from the nasal secretions and assessed by real-time qPCR assay for EEHV1 - 6 and TNFα, respectively, as described by Stanton et al.[1,2] In the first week, zero samples contained enough cells to allow amplification of the TNFα target. Subsequent modifications to the trunk washes increased the cell content of the samples. Of the 42 samples analysed, 19 trunk washes (45%) produced a TNFα signal, thus, validating the presence of amplifiable cellular DNA in the sample. EEHV1 excretion was found in one male and three female elephants resulting in a shedding incidence of 57%. The matrilinear line (three animals), which had no previous or current case of clinical herpesvirus, regularly excreted EEHV and the highest amount of shedding was seen in the youngest female (16 mo old). In contrast, excretion of EEHV was not detected in samples from the other line (two animals), which had two fatal cases in 1999 and 2003. A parallel study at Knies Kinderzoo, in an independent group of five elephants with no history of fatal EEHV, did not reveal viral shedding by adult elephants, although EEHV1 was detected from a calf. These observations suggest that EEHV1 circulates among Asian elephants in Switzerland, although fatal cases are rare. Fatal cases may be influenced by the presence of frequent virus shedders in contact with calves from rare virus shedders.

Key words: Asian elephant, *Elephas maximus,* endotheliotropic herpesvirus, qPCR, TNFα

ACKNOWLEDGMENTS

The authors would like to thank the curator and keepers of the elephant section for collection of trunk washes, Paul D. Ling, Houston for providing the qPCR protocols and Nelli Schetle for technical work in the laboratory.

LITERATURE CITED

1. Stanton JJ, Zong JC, Latimer E, Tan J, Herron A, Hayward GS, Ling PD. Detection of pathogenic elephant endotheliotropic herpesvirus in routine trunk washes from healthy adult Asian elephants (*Elephas maximus*) by use of a real-time quantitative polymerase chain reaction assay. Am J Vet Res. 2010;71:925-933.

2. Stanton JJ Zong JC, Eng C, Howard L, Flanagan J, Stevens M, Schmitt D, Wiedner E, Graham D, Junge RE, Weber MA, Fischer M, Mejia A, Tan J, Latimer E, Herron A, Hayward GS, Ling PD. Kinetics of viral loads and genotypic analysis of elephant endotheliotropic herpesvirus-1 infection in captive Asian elephants (*Elephas maximus*). J Zoo Wildl Med. 2013;44:42-54.

DELICATE TRANSATLANTIC ADVENTURE: OKAPI (*Okapia johnstoni*) AND LESSER KUDU (*Tragelaphus imberbis*) TRANSFER FROM THE UNITED STATES TO SWITZERLAND

Christian Wenker, Dr med vet, Dipl ECZM,* Stefan Hoby, Dr med vet, Friederike von Houwald, Dr med vet, and Beatrice Steck, Dipl Biol

Zoo Basel, CH 4054 Switzerland

Abstract

Endangered species breeding programs of small captive subpopulations like the European Endangered Species Program (EEP) for okapi (*Okapia johnstoni*) or the European Studbook Program (ESB) for lesser kudu (*Tragelaphus imberbis*) are in need for intercontinental animal exchange to stop the decline of genetic variety and to ensure the growth of a healthy captive breeding population. However, legal and financial barriers often influence institutional decision-makers to abandon such projects. The okapi EEP and the lesser kudu ESB were discussing the possibility to import genetically valuable animals from the Species Survival Plan (SSP) programs. The implementation of existing European Community (EU) regulations to import ungulates from the United States to an EU country were impossible by the time of the planning of these imports. Therefore, the Zoo Basel in Switzerland, which is a non-EU member and has slightly different regulations, was approached to perform these transfers. One male and one female okapi, and three subadult male lesser kudus were successfully transported to Switzerland in April 2013 and January 2015, respectively. In the near future, the possibility of non-European institutions (e.g., for American zoos) to apply for approval under EU council directive 92/65/EEC (BALAI directive) offers the potential of facilitating transatlantic zoo animal transfers substantially.

The purpose of this presentation is to identify key points for the successful planning and implementation of such a project and to encourage other institutions to take similar initiatives. It proved valuable to actively approach and support governmental authorities to develop a risk assessment for quarantine measures and individual animal examination and testing. The Transmissible Diseases Handbooks of the European Association of Zoo and Wildlife Veterinarians (EAZWV) and the American Association of Zoo Veterinarians (AAZV) were valuable tools in these discussions. Quarantine requirements included a 30-day external quarantine in another Swiss zoo for the okapis to strictly ensure no contact with other ruminants. For the lesser kudus, quarantine was permitted to be implemented in the recipient zoo, but precautionary measures had to be taken to prevent access to flying insects because of their potential to act as disease vectors. Transmissible diseases were listed and most of them ruled out by clinical examination without testing. Testing was focused on diseases with long-incubation periods (e.g., enzootic bovine leucosis), subclinical or latent infection (e.g., babesiosis, tuberculosis) or legal requirements (e.g., bovine herpes virus type 1). Animal welfare and animal safety are important aspects in transatlantic air and road transports. For okapi and lesser kudu it was mandatory to cooperate with a globally active company in live animal air transportation. Its networks at the airports allowed timely veterinary surveillance and helped to reduce waiting times for the animals. Finally, transatlantic communication between zoo veterinarians (i.e., exchanging medical and biological data) was extremely valuable. The costs of the okapi transfer were 21’525 Euros for the intercontinental air

transport, 4’000 Euro road transport from Frankfurt airport to Switzerland, and 9‘800 Euros for the external quarantine. The estimated lesser kudu transfer costs were 7‘000 Euros per animal. In the meantime, the female okapi and two male lesser kudus were safely moved to other EEP and ESB institutions.

Key words: Animal transport, BALAI directive, lesser kudu, okapi, *Okapia johnstoni, Tragelaphus imberbis*

ACKNOWLEDGMENTS

The authors would like to thank the Zurich Zoo, Dallas Zoo and the San Diego Zoo for their cooperation, Marianne Imhof from ACE pet moving for excellent organisation of the air transport and customs affairs for the benefit of these animals, and Dr. Guido Vogel from the Cantonal Veterinary Office Basel-Stadt and Dr. Edoardo Giani from the Swiss Veterinary Office, International affairs, for their support.

SERUM CONCENTRATIONS OF ANTIMYCOBACTERIAL DRUGS IN ASIAN ELEPHANTS (*Elephas maximus*)

Lydia Young, DVM,[1]* Steve Scott, DVM,[1] Max Salfinger, MD, FAAM, FIDSA,[2] and Ed Ramsay, DVM, Dipl ACZM[3]

[1]The Elephant Sanctuary, Hohenwald, TN 38462 USA; [2]National Jewish Health, Denver, CO 80206 USA; [3]Department of Small Animal Clinical Sciences, College of Veterinary Medicine, University of Tennessee, Knoxville, TN 37996 USA

Abstract

Mycobacterium tuberculosis is an important disease of captive Asian elephants (*Elephas maximus*.) In this study six adult Asian elephants which had *Mycobacterium tuberculosis* cultured from trunk wash samples or had reactive DPP/MAPIA serologic responses were treated, concurrently, with one to three antimycobacterial drugs. Enrofloxacin hydrochloride, 2.5 mg/kg p.o., s.i.d., was administered to all animals in various foodstuffs for 9-15 mo. Serum enrofloxacin concentrations ranged from 230-2380 µg/ml (targeted concentrations = 125-1000 µg/ml).[1] Pyrazinamide (PZA), 30 mg/kg p.o., s.i.d., was administered to five elephants in various foodstuffs for 9-12 mo. Serum PZA concentrations ranged from 26-57 µg/ml (targeted concentrations = 20-60 µg/ml).[2] Ethambutol (EMB), 30 mg/kg p.o., s.i.d., was administered to one elephant for 12 mo. A serum EMB concentration of 4.07 µg/ml was achieved (targeted concentration = 2-6 µg/ml).[2] Rifampin (RIF), 10 mg/kg p.o., s.i.d., was administered to one elephant for 9 mo. A serum RIF concentration of 16 µg/ml was achieved (targeted concentration = 8-24 µg/ml).[2] All elephants were monitored for adverse clinical effects throughout treatments. Notable side effects were limited to excess, foamy lacrimation, believed to have occurred secondary to PZA administration. Clinical chemistries and complete blood counts were monitored in all animals and values remained within reference intervals throughout treatments. This study shows antimycobacterial drug dosages may require individuation, but concurrent, long-term, multidrug regimens for the treatment of *Mycobacterium tuberculosis* in Asian elephants can achieve appropriate therapeutic levels with minimal detrimental side effects.

Key words: *Elephas maximus*, enrofloxacin, ethambutol, *Mycobacterium tuberculosis*, pyrazinamide, rifampin

ACKNOWLEDGMENTS

The authors would like to acknowledge Walter Cook, the Tennessee Wildlife Resources Agency, for his input and support of elephants in Sanctuary, the Auburn University Clinical Pharmacology lab for measuring enrofloxacin levels, and the elephant caregivers, whose dedicated daily care makes individualized veterinary care possible.

LITERATURE CITED

1. Sanchez CR, Murray SZ, Isaza R, Papich MG. Pharmacokinetics of a single dose of enrofloxacin administered orally to captive Asian elephants (*Elephas maximus*). Am J Vet Res. 2005;66:1948-1953.

2. Brock A, Isaza R, Egelund EF, Hunter RP, Peloquin CA. Pharmacokinetics of a single oral or rectal dose of concurrently administered isoniazid, rifampin, pyrazinamide, and ethambutol in Asian elephants (*Elephas maximus*). J Vet Pharmacol Ther. 2014;37:47-29.

INDEX

[A]

Acinonyx jubatus, 140, 210, 222
acoustic transmitter tracking system, 90
addax, 129
Addax nasomaculatus, 129
adenocarcinoma, 198, 199, 211, 261
adenovirus, 14, 272
adrenal tumor, 205, 206
advanced imaging, 67
Aepyceros melampus, 53
African hunting dogs, 211
African lion, 96
Agkistrodon piscivorus, 255
air sac rupture, 179
alcids, 195
alfaxalone, 315
algorithm, 95, 146, 152
Alligator mississippiensis, 252
alligator snapping turtles, 249, 250
alligators, 252
allometric scaling, 288, 304
alopecia, 69, 73, 205, 282
Amazona ventralis, 56
American alligator, 252
amphibian, 27, 85, 89, 130, 175, 251, 254, 264, 265
amputation, 25, 64, 65, 66, 265, 271
amyloidosis, 135
analgesia, 1, 26, 27, 201, 202, 229, 230, 268, 296, 299, 303, 304
analgesics, 26, 65
Anaxyrus houstonensis, 24, 254, 264
Andean condor, 59
anesthesia, 1, 3, 20, 25, 142, 145, 151, 186, 222, 229, 230, 232, 253, 256, 269, 287, 293, 296, 297, 298, 299, 320, 322
anesthetic, 1, 256, 260, 287, 298, 302, 323
Angiostrongylus cantonensis, 107, 108
Animal and Plant Health Inspection Service, 155
animal care and use protocols, 2
animal health, 6, 8, 9, 85, 155, 177, 230, 234
animal welfare, 2, 93, 146, 155, 156, 215, 218, 236, 275, 322
Animal Welfare Act, 156, 229
anteater, 269
antelope, 53, 129
antibiotic-resistant, 188
antimicrobial resistance, 8, 126, 184, 185, 189
antimycobacterial drugs, 330
anurans, 25
Aotus sp., 284
aquariums, 22, 32, 47, 50, 53, 82, 149, 226, 236, 241, 316
Arabian oryx, 31, 237
Arbovirus, 11
Arctocephalus tropicalis, 173, 174
armadillo, 269, 280
arthritis, 125
artificial insemination, 30, 121, 316
artists, 157
ascariasis, 222
Asian elephant, 16, 17, 34, 35, 36, 37, 38, 39, 40, 41, 43, 44, 45, 46, 74, 77, 100, 113, 115, 117, 122, 307, 311, 312, 326, 327, 330
Asiatic black bears, 93
Aspergillus, 89
autoimmune encephalitis, 91
avian, 2, 13, 54, 56, 58, 64, 65, 105, 106, 129, 145, 179, 180, 187, 191, 192, 196, 197, 201, 327
avian influenza, 54, 105, 106, 192
azaperone, 123, 124, 298, 315

[B]

Babesia capreoli, 101, 102, 103, 104
babesiosis, 101, 274, 328
Bacillus cereus biovar *anthracis*, 111
bald eagle, 59, 66, 203, 204
ball pythons, 26
Batrachochytrium dendrobatidis, 89
Batrachochytrium salamandrivorans, 89
bears, 91, 93, 94, 218
behavior, 2, 7, 36, 49, 53, 67, 68, 69, 70, 71, 72, 73, 74, 75, 159, 177, 202, 230, 283, 305, 310, 321, 322
bighorn sheep, 101
bird, 13, 59, 62, 64, 65, 105, 106, 186, 190, 191, 200
black rats, 278
black rhinoceros, 118, 119, 300
blood parameters, 80, 245
blood pressure, 36, 128, 131
boar, 281, 298
bobcats, 207
body condition scoring, 245
body weight, 36, 64, 120, 283, 284, 321
bone marrow, 109, 247
bonobo, 163, 295
Bos grunniens, 101
Bradypus variegatus, 11
breeding, 14, 22, 34, 47, 50, 51, 53, 54, 61, 67, 85, 86, 140, 143, 148, 182, 183, 207, 214, 221, 222, 254, 264, 276, 302, 305, 322, 323, 328
brodifacoum, 59, 60
brodifacoum toxicosis, 59

bronchoalveolar lavage, 113
bronchopneumonia, 268, 315
Bucorvus leadbeateri, 191
budgerigars, 64, 190
Buteo sp., 193
butorphanol, 25, 26, 27, 90, 113, 123, 124, 126, 218, 301

[C]

calcium, 78, 140, 182, 183, 203, 245
California sea lions, 90
Callimico, 287
Callimico goeldii, 161, 162, 287
cancer, 19, 49, 232, 233
canine distemper, 220, 221, 234, 272
canine distemper virus, 220, 221, 234, 272
capacity building, 10, 239
Capra hircus, 314
capture, 29, 74, 75, 90, 120, 123, 177, 186, 272, 278, 296, 315, 318, 322
capuchin monkey, 107, 280
carcinoma in situ, 198
cardiac, 20, 25, 68, 85, 141, 196, 203, 260, 288, 292
cardiac evaluation, 203
cardiology, 196, 203
cardiomyopathy, 141
cardiovascular disease, 20, 93, 196, 295
carpus valgus, 140
case series, 62, 232
Cebus capucinus, 107
ceco-cutaneous fistula, 293
ceftiofur, 125, 159, 160, 188, 268
Centers for Disease Control and Prevention (CDC), 32
Ceratotherium simum, 118, 123, 124, 126, 127, 233, 237, 303
Cervus elaphus, 101, 103
cestode, 224
cetaceans, 168, 175, 231
cheetah, 140, 210, 222
chelation therapy, 203
Chelonia mydas, 18
chemical castration, 53
chemical restraint, 251, 256
Chilean flamingo, 54
chimpanzee, 111, 163, 285, 288, 289, 291, 292, 295
Chlamydia, 13, 24, 89, 193, 194
Chlamydiaceae, 193
Chlamydophila, 24
Chlorocebus pygerythus, 97
cholecystitis, 222
cholelithiasis, 222
Chrysocyon brachyurus, 214, 215
Chyloscyllium plagiosum, 82, 83
clinical chemistry profiles, 85
clinical pathology, 94
clinical significance index, 234
cloacitis, 143, 144
clouded leopard, 213
coagulation, 87, 117, 311
coagulopathy, 87, 311
Cobboldia elephantis, 312, 313
coelomic fluid, 78
cold stress syndrome, 87, 88
Columbia livia, 190
complete blood count, 135, 330
conservation, 8, 9, 50, 73, 74, 80, 93, 111, 153, 157, 172, 177, 178, 191, 214, 215, 217, 222, 226, 227, 234, 236, 237, 241, 246, 247, 253, 255, 257, 264, 274, 280, 296
conservation education centers, 226
conservation medicine, 8, 9
Contracaecum pelagicum, 180, 181
contraception, 47, 48, 53, 275, 314, 317, 320, 322, 323, 324
contraceptives, 47, 49, 211
corn snake, 26, 27
corneal abscess, 173, 174
corneal disease, 173
cottonmouths, 255
Crax blumenbachii, 186, 187
crocodile, 245
crop, 190
cryopreservation, 253, 316
cryptococcosis, 135, 271
Cryptococcus neoformans, 135, 136, 271
curassow, 186, 187
cyst, 293
Cytauxzoon felis, 219
cytokine, 168

[D]

darting, 90, 218, 296, 315, 317, 319
Dasyatis americana, 50
data, 1, 11, 22, 24, 27, 36, 39, 50, 56, 63, 64, 71, 72, 80, 107, 109, 118, 123, 128, 146, 148, 149, 150, 151, 152, 157, 168, 172, 176, 182, 195, 196, 197, 200, 207, 215, 220, 232, 235, 243, 249, 288, 295, 296, 303, 305, 310, 311, 315, 328
data mining, 148, 150, 152
data sharing, 148, 149
database, 47, 149, 150, 151, 152, 172, 232, 320
dermatitis, 31, 69, 72, 119, 143, 170, 186, 264
dermatophytosis, 209
diagnostic pathology, 239
Diceros bicornis, 118, 119, 300
Didelphis virginiana, 272
diet, 55, 82, 129, 141, 143, 156, 162, 207, 263, 283, 294, 305, 310
digestive tract, 129, 280

disease, 6, 7, 8, 13, 17, 20, 21, 22, 23, 24, 29, 31, 34, 35, 37, 38, 39, 40, 41, 43, 45, 46, 50, 62, 72, 76, 77, 78, 79, 80, 82, 87, 91, 93, 95, 96, 97, 99, 100, 101, 107, 109, 110, 111, 114, 115, 116, 117, 118, 126, 127, 130, 135, 141, 143, 156, 161, 165, 166, 167, 168, 170, 173, 175, 177, 181, 191, 192, 195, 196, 198, 207, 208, 209, 213, 214, 220, 222, 230, 234, 237, 241, 247, 255, 257, 263, 264, 266, 267, 270, 271, 272, 274, 277, 281, 284, 288, 291, 294, 295, 300, 301, 311, 316, 327, 328, 330
disease investigation, 7, 241
disease management, 165
disease monitoring, 291
disseminated intravascular coagulation, 87
disseminated protothecosis, 282
distemper virus, 220, 221, 234, 272
DNA, 4, 24, 61, 135, 219, 237, 247, 291, 294, 311, 327
Dolichotis patagonum, 266
dolphins, 168, 175, 176
Drymarchon couperi, 263

[E]

Eastern box turtle, 247, 258
Eastern indigo snakes, 263
eating, 145, 180, 215, 260, 268, 310
echocardiographic variables, 288
ecosystem health, 8, 85, 241, 249
ectopic ossification, 263
education, 9, 32, 37, 153, 157, 226, 229, 269, 280
EEHV, 34, 35, 36, 37, 38, 39, 40, 41, 43, 44, 45, 117, 307, 327
elasmobranch, 82, 83, 170
electric eel, 145
electrocardiographic monitoring, 20
electrochemotherapy, 186, 187
Electrophorus electricus, 145
elephant endotheliotropic herpesvirus, 34, 37, 38, 39, 40, 41, 42, 43, 45, 77, 117, 307, 327
Elephas maximus, 16, 17, 34, 37, 38, 39, 40, 41, 43, 44, 45, 77, 113, 115, 117, 122, 307, 311, 312, 313, 326, 327, 330
ELISA, 38, 105, 308
elk, 101, 308, 309
embryo development, 51
emerging infectious diseases, 8, 9
Emydoidea blandingii, 257, 258
encephalitis, 24, 91, 92
encephalomyelitis, 24, 274
endoscopy, 25, 51, 67, 113, 213
enteritis, 291
epizootic hemorrhagic disease, 274
Equus caballus, 274, 305, 317, 324
erythrocyte micronucleus test, 18
estradiol, 50, 120, 205, 207, 305
estrous cycle, 305
etorphine, 123, 124, 131
Eudyptula minor, 198
exercise, 140, 142
eyelid agenesis, 216

[F]

factor vii, 311
factor vii deficiency, 311
famciclovir, 34, 35, 36, 38
fecal egg, 310
feeding regime, 129
felids, 47, 49, 72, 99, 217, 222, 234
fentanyl, 26, 201, 202
fibroma, 186, 187
fish, 19, 107, 145, 171, 180, 181, 200, 232, 233, 318
flea infestation, 214
florida manatee, 80, 81, 87, 88, 172
flotac, 133, 134
flunixin meglumine, 268, 303, 304
fluoxetine, 68, 326
fluralaner, 214
fracture, 64, 130, 268, 301
free-ranging wildlife, 1, 96, 99, 311, 323
frogs, 25, 27, 107, 251, 254, 256
fruit bat, 282
fungal infections, 165
fungus, 165, 180
fur seal, 14, 173, 174

[G]

gabapentin, 68
gastric foreign body, 145
gastrointestinal parasites, 133, 225, 310
gene analysis, 220, 294
genotoxicity, 18
Geochelone sulcata, 265
Giraffa camelopardalis reticulata, 130, 137
giraffe, 99, 130, 137, 304, 310
global information resources, 148
glucocorticoids, 56, 58, 205
goat pox virus, 31
Gorilla g. gorilla, 111, 163, 283, 285, 295
gray fox, 220
great ape, 75, 111, 112, 163, 281, 285, 295, 296
green sea turtle, 18
gross lesion recognition, 167
guide, 20, 73
guidelines, 1, 2, 35, 37, 54, 72, 94, 137, 148, 277, 296, 316
guineafowl, 201
guttural pouch infection, 301, 302

[H]

Haemonchus contortus, 310
half-life, 303
Haliaeetus leucocephalus, 59, 203, 204
haloperidol, 74, 326
hand-rearing, 54, 55
hawks, 193
health assessment, 8, 80, 85, 87, 89, 126, 127, 168, 177, 249, 257
health evaluation, 22, 207
health parameters, 22
health survey, 245
heart, 20, 25, 36, 131, 196, 203, 218, 260, 265, 266, 270, 282, 291
heart disease, 288
heart surgery, 25
helminthosis, 224
hemagglutinin gene, 220
hemorrhagic disease, 34, 35, 38, 39, 40, 41, 45, 46, 117, 274, 327
hepatitis E, 281
herpes B-like virus, 290
herpesvirus, 34, 37, 38, 39, 40, 41, 43, 45, 46, 77, 117, 168, 210, 257, 258, 290, 307, 327
Heterocephalus glaber, 275, 276
Heterodontus portusjacksoni, 51, 52
hiding place, 259
Himantura schmardae, 170
Hispaniolan Amazon parrots, 56
hormone assisted, 254
hornbills, 191
horse, 66, 209, 274, 304, 317, 318, 320, 321, 322, 323
horseshoe crabs, 85, 86
Houston toads, 24, 254, 264
humoral immune response, 252
hypothermia, 87, 287, 298

[I]

ibis, 196
imaging, 67, 161, 167, 204, 223, 298, 301
immobilization, 1, 2, 3, 90, 124, 131, 132, 229, 230, 285, 296, 297, 299, 308, 317, 320, 323
impala, 53
Improvac®, 314
infertility, 47, 48, 49, 305, 306
inflammatory bowel disease, 213
injection, 25, 27, 53, 125, 171, 214, 218, 255, 268, 275, 298, 315, 317, 319, 323
integrative research, 8
international transport, 236
intestinal parasites, 222, 310, 313
intraocular pressure, 251
iodine, 50, 82, 83
iron metabolism, 294

[J]

jaguar, 68, 217

[K]

kākāpō, 143, 182
kangaroo, 135, 266, 270
ketamine, 20, 131, 145, 218, 253, 268, 296, 298, 301, 324
kidney, 94, 161, 162, 207, 252
koala, 109, 110, 271
kudu, 328, 329
kwashiorkor, 285

[L]

lameness, 36, 64, 130, 209, 303
lead toxicity, 203
leadership, 229
lemur, 293, 294
Leopardus wiedii, 72, 217
Leptospira, 272, 273
leptospirosis, 274
leukopenia, 35, 137, 284
lidocaine, 59, 113
limb injuries, 65
Limulus polyphemus, 85, 86
lion, 12, 90, 95, 205, 206, 217, 219
lion-tailed macaques, 159
Litoria caerulea, 27, 251, 256
local capacity, 8, 10
local conservation, 8
Loxodonta africana, 29, 34, 41, 74, 113, 120, 125
Lycaon pictus, 211
Lynx rufus, 207, 208

[M]

Macaca silenus, 159
Macrochelys temminckii, 249, 250
Macropus rufogriseus, 128, 268
Macropus rufus, 135, 266, 267, 268, 270
Madagascar, 278, 279
Malaclemys terrapin, 153, 154
malnutrition, 77, 285, 286
manatee, 80, 81, 87, 88, 172, 177, 178
maned wolves, 214, 215
mara, 266
mare, 305, 321, 322, 323
margay, 72, 217
marine animal, 14
Mecistops cataphractus, 245

medetomidine, 90, 126, 131, 145, 218, 253, 298, 301, 315, 324
Melopsittacus undulatus, 190
meloxicam, 25, 145, 260, 268
metagenomics, 143
metapopulation, 254
metronidazole, 125
microbiome, 144
Mirounga angustirostris, 76, 77
mission, 269
mongooses, 95
morbidity, 31, 65, 72, 90, 99, 196, 247, 257, 264, 285, 310
morphine, 26, 27, 202
mortality, 24, 31, 35, 39, 43, 45, 65, 76, 79, 80, 90, 122, 153, 159, 166, 172, 180, 196, 204, 215, 217, 247, 257, 264, 280, 285, 291, 295, 307, 309, 310
MS-222, 25, 251, 256
mule deer, 129, 315
Mungos mungo, 95, 96
musk ox, 131
mycobacteriosis, 100, 291
Mycobacterium bovis, 95, 96, 97, 99, 100, 177
Mycobacterium tuberculosis, 16, 17, 96, 97, 98, 99, 100, 113, 115, 330
myelodysplasia, 109

[N]

naked mole rat, 275, 276, 277
Neofelis nebulosa, 213
neoplasia, 109, 139, 205, 206, 211, 217, 232, 233, 260, 261
neuropathic pain, 68
Newcastle vaccine, 191
nonhuman primate, 32, 33, 97, 99, 107, 159, 230, 280, 283, 293, 296
northern elephant seals, 76, 77
Numida meleagris, 201
nutrition, 7, 55, 83, 264, 286, 310

[O]

Odocoileus hemionus, 129, 315
okapi, 328, 329
Okapia johnstoni, 328, 329
One Health, 8, 9, 10, 11, 94, 152, 157, 224, 241, 242
Ophidiomyces ophiodiicola, 255
opioids, 26, 28, 36, 291
opossum, 272
orangutan, 108, 163, 295
orthotics, 65
Oryx leucoryx, 31, 237
osprey, 200
ostectomy, 140
osteitis, 125, 130
osteoarthritis, 130, 303
Otostrongylus, 76, 77
outrigger wheel prosthesis, 265
ovariohysterectomy, 202
Ovibos moschatus, 101, 131
oviposition, 51
Ovis canadensis, 101
ovulation, 305
owl monkeys, 284
oxidative stress markers, 118

[P]

Pan paniscus, 163, 295
Pan troglodytes, 111, 163, 285, 288, 291, 292, 295
Pandion haliaetus, 200
Panthera leo, 95, 96, 205, 217
Panthera onca, 68, 217
Panthera tigris, 67, 210, 217
parasitic infections, 133
parasitism, 22, 72, 180, 278, 310
Passer domesticus, 184, 185
passive transfer, 137
Patagonian green racer, 260
pathogen screening, 22
pathology, 47, 48, 50, 62, 93, 94, 97, 100, 109, 142, 148, 167, 183, 196, 239, 265, 271, 300, 305
pelvic limb amputation, 265
penguin, 14, 179, 180, 198, 199
periodontal disease, 300
pharmacokinetics, 26, 243, 255, 303
Phascolarctos cinereus, 109, 110, 271
pheromone fraction F3 (FFP), 72
pheromone therapy, 72
Philodryas patagoniensis, 260, 261
Phoenicopterus chilensis, 54
phosphorus, 182, 283
Phrynosoma cornutum, 22, 23
phytoestrogen, 305, 306
pigeons, 190, 191
pinnipeds, 84, 173, 174
Pionus menstruus, 188
Pochonia chlamydospora, 180
poisoning, 59, 203, 204, 280
polar bear, 91, 92
polymerase chain reaction, 26, 34, 36, 38, 41, 42, 252, 257, 281, 327
polymerase chain reaction assay, 38, 41, 42, 327
Pongo abelii, 295
Pongo pygmaeus, 108, 163, 295
porcine zona pellucida, 275, 317, 318, 323
portable field diagnostic equipment, 4
pregnancy, 29, 43, 117, 308, 309, 317, 319, 320, 321, 322

preparedness, 34, 35
primate, 33, 107, 284, 287, 290, 291, 293, 294, 296
Primolius couloni, 188
Procyon lotor, 220, 272, 273
Propithecus coronatus, 293
prosthetics, 65
Proteus anguinus, 89
proventricular acuariid spiruridiasis, 62
proventricular disease, 62, 198
Pseudomonas aeruginosa, 170
Psittacidae, 188
public health, 11, 111, 184, 188, 224
pulmonary hypertrophic osteopathy, 270
pygmy goat, 314
pyometra, 49
Pyrrhura picta, 188
PZP, 275, 317, 318, 319, 320, 321, 322, 323, 324, 325

[Q]

quality-of-life, 141

[R]

raccoons, 272
Ranavirus, 247
Rangifer tarandus, 101, 103
Rattus rattus, 107, 278, 279
rehabilitation, 87, 122, 153, 172, 200, 203, 226, 227
reindeer, 101, 103, 309
reintroduction, 22, 61, 177, 178, 186, 191, 249, 264
renal, 93, 135, 138, 161, 207, 208, 217
renal amyloidosis, 135
reproduction, 48, 50, 120, 122, 254, 275, 308, 318, 323
reproductive disease, 50, 217
reproductive management, 47
reptiles, 2, 20, 165, 232, 235, 243, 245, 255, 263, 269
research, 1, 2, 3, 4, 8, 10, 12, 14, 16, 20, 23, 24, 25, 27, 34, 35, 37, 41, 47, 50, 70, 71, 73, 76, 80, 82, 87, 89, 110, 153, 165, 175, 187, 200, 201, 217, 226, 229, 232, 239, 241, 252, 263, 274, 278, 284, 296, 303, 305, 316, 319
reticulated giraffe, 137
retinol, 118
rhinoceros, 99, 118, 119, 123, 124, 233, 237, 300, 303, 305, 306
risk, 1, 8, 11, 13, 19, 29, 30, 34, 36, 39, 44, 46, 48, 49, 50, 59, 84, 93, 99, 113, 126, 130, 146, 157, 224, 241, 253, 259, 272, 277, 285, 305, 316, 328
risk factors, 13, 49, 224
river otter, 141
rodenticide, 59
Rousettus lanosus, 282
ruminant, 102, 129

[S]

salivary gland neoplasia, 260
Salmonella, 13, 22, 188
sea star, 78
sea star wasting disease, 78
seasonality, 143
second generation anticoagulant rodenticide, 59
semen, 29, 30, 48, 53, 120, 121, 253, 316
semen collection, 48, 120, 316
semiochemicals, 70, 71, 73
septic osteitis, 125
serum amyloid A, 76
sharks, 51, 82, 83
shifting box, 259
sifaka, 293
silvered leaf monkeys, 290
skeletal, 66, 123, 247
skin, 25, 31, 32, 67, 68, 80, 89, 97, 145, 201, 209, 211, 263, 265, 271, 274, 277, 282, 285
sloth, 269, 286
smartphone EKG software, 20
snake, 35, 165, 255, 260, 261, 263
snow leopards, 138, 139, 209, 216
social dynamics, 275
soft tissue mineralization, 263
softshells, 253
sparrows, 184, 185
sperm, 53, 120, 253, 314, 316, 318
sperm quality, 120
Spheniscus demersus, 179
Sphenodon punctatus, 243
spillover, 16
squamous cell carcinoma, 138, 232
stereotypic behavior, 74
stingray, 50, 170
stress, 43, 56, 57, 58, 70, 71, 72, 118, 168, 170, 172, 175, 215, 236, 259, 268, 292, 322, 326
Strigops habroptilus, 144, 182, 183
sulcata tortoise, 265
supplementation, 82, 83, 137, 218, 285
surveillance, 11, 16, 17, 84, 100, 105, 115, 247, 257, 290, 328
survey, 11, 23, 48, 119, 163, 226, 235, 281, 296, 304
Sus scrofa, 298

[T]

Tapir bairdii, 301, 302
tensile failure load, 228
terbinafine, 142, 255
Terrapene carolina, 247, 248, 258
terrapin, 153, 154
testosterone secretion, 314
Texas horned lizards, 22
The Frozen Zoo®, 237

thoracic actinomycosis, 270
thromboelastography, 87, 117
tiger, 67, 217
tiletamine-zolazepam, 298
tonometry, 251
toxic shock syndrome, 159
toxicity, 19, 60, 118, 203, 292
toxoplasmosis, 266, 267, 274
tracheal mass, 142
Trachypithecus cristatus, 290
Tragelaphus imberbis, 328, 329
training, 6, 7, 8, 34, 36, 124, 130, 175, 209, 224, 230, 239, 269
tramadol, 27, 69, 173, 268
transdisciplinary collaborations, 8
transfusion, 46, 59, 163, 164
translocation, 22, 30, 74, 99, 177, 316
transport, 56, 78, 117, 155, 178, 218, 230, 236, 301, 323, 329
trauma, 25, 90, 159, 179, 200, 217
Trichechus manatus, 77, 80, 81, 87, 172, 177, 178
Trichomonas, 190
tuatara, 243
tuberculosis, 16, 17, 32, 33, 84, 95, 96, 97, 98, 99, 100, 113, 115, 116, 274, 328, 330
tumor database, 232

[U]

ultrasonography, 51, 120, 161, 205, 207, 222, 314
ultrasound, 4, 48, 51, 89, 125, 135, 141, 161, 177, 207, 211, 213, 222, 260, 269, 305, 309
Uncia uncia, 138, 139, 209, 216
ungulates, 99, 323, 328
Uria aalge, 195
Ursus arctos, 218
Ursus maritimus, 91, 92
Ursus thibetanus, 68, 93, 94

[V]

vaccination, 31, 105, 106, 191, 252, 274, 319, 320, 321, 322, 323, 324
vaccine, 37, 105, 106, 191, 252, 272, 275, 314, 319, 321, 322, 323
vaccine efficacy, 272
venomous snakes, 259
vervet monkeys, 97
veterinarian staffing, 235
veterinary outreach, 226
veterinary pathology, 239
veterinary technician, 161, 235, 272
virus, 11, 31, 34, 35, 37, 40, 45, 105, 106, 191, 220, 221, 234, 247, 252, 272, 274, 281, 290, 291, 307, 327, 328
vision, 177
vitamin D, 140, 183
voriconazole, 243, 244
Vultur gryphus, 59

[W]

wallabies, 128, 268
wasting disease, 78, 79, 284
waterfowl, 65
welfare, 2, 72, 73, 93, 94, 127, 134, 141, 146, 155, 156, 161, 215, 218, 236, 275, 322, 328
West Nile virus, 252
West Nile virus vaccine, 252
Western lowland gorilla, 111, 283
white-tailed deer, 101, 309, 315
wild carnivores, 234
wildlife, 1, 2, 3, 6, 7, 8, 9, 10, 11, 17, 23, 24, 29, 31, 49, 60, 78, 91, 92, 96, 99, 111, 143, 149, 153, 165, 177, 184, 185, 189, 200, 207, 215, 220, 226, 234, 237, 239, 247, 271, 280, 294, 296, 297, 299, 303, 311, 323, 324
wildlife health, 6, 7
wildlife veterinarian, 2, 9, 239, 247

[X]

xenarthrans, 269

[Y]

yellow fever, 11

[Z]

Zalophus californianus, 90
Zeuterin™, 53
zoo animals, 67, 84, 100, 133, 134, 224, 232, 236, 272, 281
zookeepers, 224
zoos, 6, 27, 32, 39, 45, 47, 105, 106, 130, 149, 163, 196, 226, 235, 236, 241, 242, 283, 293, 295, 314, 316, 328

NOTES