

ESSKA **Meniscus Consensus Project:** Degenerative meniscus lesions

Chairmen: Philippe Beaufils, Roland Becker

Project Chairmen



Roland Becker



Philippe Beaufils

Steering Group:

S. Kopf - Germany

M. Ollivier - France

M. Englund - Sweden

R. Verdonk - Belgium

N. Darabos - Croatia

A. Gokeler - The Netherlands

M. Hirschmann - Switzerland

C. Hulet - France

T. Järvelä - Finland

H. Mayr - Germany

P. Ntigiopoulos - Greece

H. Pereira - Portugal

N. Rotigliano - Italy

Introduction

The ESSKA Meniscus Consensus Project was initiated by the ESSKA Board after the congress in Amsterdam in 2014. It has been commissioned to two world-renowned experts in the field, Prof. Philippe Beaufils (France) and Prof. Roland Becker (Germany).

The goal of the initiative is to find a European consensus on the treatment of meniscus pathologies. Finding a consensus in such a diverse continent like Europe where medical culture and healthcare systems vary from country to country is not easy. A strict methodology has therefore been applied and numerous

European experts have been involved in this process.

It is due to the merit of the two leaders of this group that we are able to come up with this document which shall be understood as guidance to ESSKA members. We thank Profs. Beaufils and Becker as well as the members of the steering, rating and evaluation groups for their efforts and dedication. A special acknowledgement also for our staff, and particularly Mrs. Anna Hansen Rak, without whom this would not have been possible.

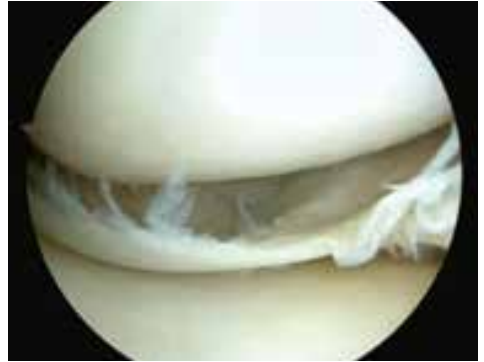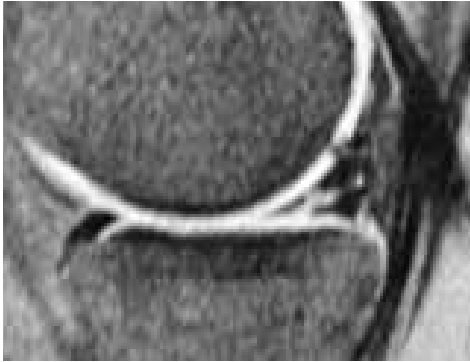Milan and Luxembourg, March 2016



Matteo Denti
ESSKA President



Romain Seil
ESSKA incoming President



The Meniscus Consensus Project

Arthroscopic partial meniscectomy is one of the most popular orthopaedic procedures, especially in the field of degenerative meniscus lesions (DML).

Recent publications stated that non-operative treatments have similar results to arthroscopic surgery. Several editorials and letters have been published either by medical physicians or orthopaedic surgeons in the defence of their own practice. These exchanges are confusing and have not been useful to the clinician in making treatment decisions. Therefore, there was a need for a more uniform and clear message and the treatment of DML should be related to both scientific evidence and clinical expertise.

ESSKA decided to develop a Meniscus Consensus Project at the European level with goal to propose a “framework” rather than strict guidelines. This project has been set up according to the so called “Formal Consensus Project” in which more than 80 European physicians, surgeons and scientists have been involved.

We hope the following recommendations will take into account these messages, avoid any conflicting or political statements, and provide a well balanced treatment algorithm with a place for both non-operative and arthroscopic treatment in the orthopaedic armamentarium.

This flyer is a summary. The complete text is available on www.esska.org

Degenerative Meniscus Lesion

What is it exactly?

A degenerative meniscus lesion is a slowly developing lesion, typically involving a horizontal cleavage of the meniscus, generally in a middle-aged or older person.

Such meniscus lesions are frequent in the general population and often incidental findings on knee MRI. There is often no clear history of an acute knee injury. *Grade B*

What is the prevalence of degenerative meniscus lesions?

The prevalence of meniscus lesions in the general population (intrameniscal signal extending to surface according to the two-slice touch rule) has been evaluated as follows:

- Age 50-59 years ≈ 25%
- 60-69 years ≈ 35%
- 70-79 years ≈ 45%
- Patients with knee osteoarthritis ≈ 75-95%

Grade B

Do degenerative meniscus lesions cause knee symptoms?

There is very limited evidence that pain in the degenerative knee is directly attributable to a degenerative meniscus lesion even if the lesion is considered to be unstable. Great caution must be taken before arriving at the conclusion that the degenerative meniscus lesion is the direct cause to the patient's knee symptoms.

Grade B

What is the role of knee radiographs in the assessment of middle-aged or older patients with a painful knee?

Knee radiographs should be used as a first-line imaging tool to support a diagnosis of osteoarthritis or to detect certain more rare pathologies of the knee. Therefore, at least anteroposterior weight-bearing semi-flexed knee radiographs including a lateral view should be included in the work up of the middle-aged or older patient with knee pain. *Grade B* [figure 1]

What is the role of knee MRI in the assessment of a middle-aged or older patient with a painful knee?

Knee MRI is typically not indicated in the first line work up of middle-aged or older patients with knee joint symptoms. However, knee MRI may be indicated in selected patients with refractory symptoms or in the presence of 'warning flags' or localized symptoms indicating more rare disease

If a surgical indication is considered, based on history, symptoms, clinical exam and knee radiographs, knee MRI may be useful to identify structural knee pathologies that may (or may not) be relevant for the symptoms. *Grade B* [figure2]

Which outcomes can be expected after arthroscopic partial meniscectomy (APM)?

- Improvement of functional outcomes can be expected after APM. *Grade A*
- However, most of the RCTs found no difference in terms of clinical outcomes after surgery compared to non-operative treatment. *Grade A*

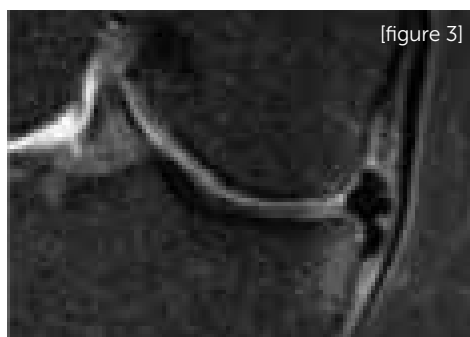
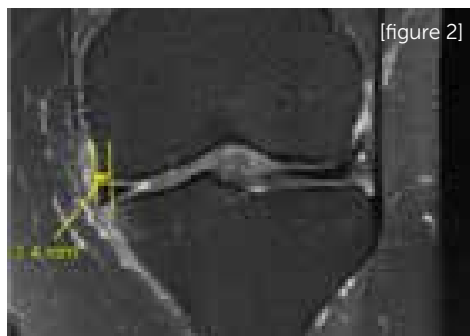
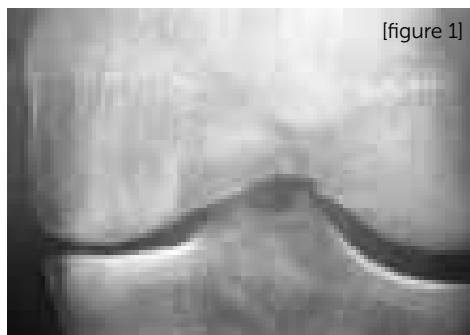
What is the rate of conversion to surgery of patients receiving an initial conservative treatment?

Non-operative treatment is converted to surgery (cross – over) in 0 to 35% of patients. *Grade A*

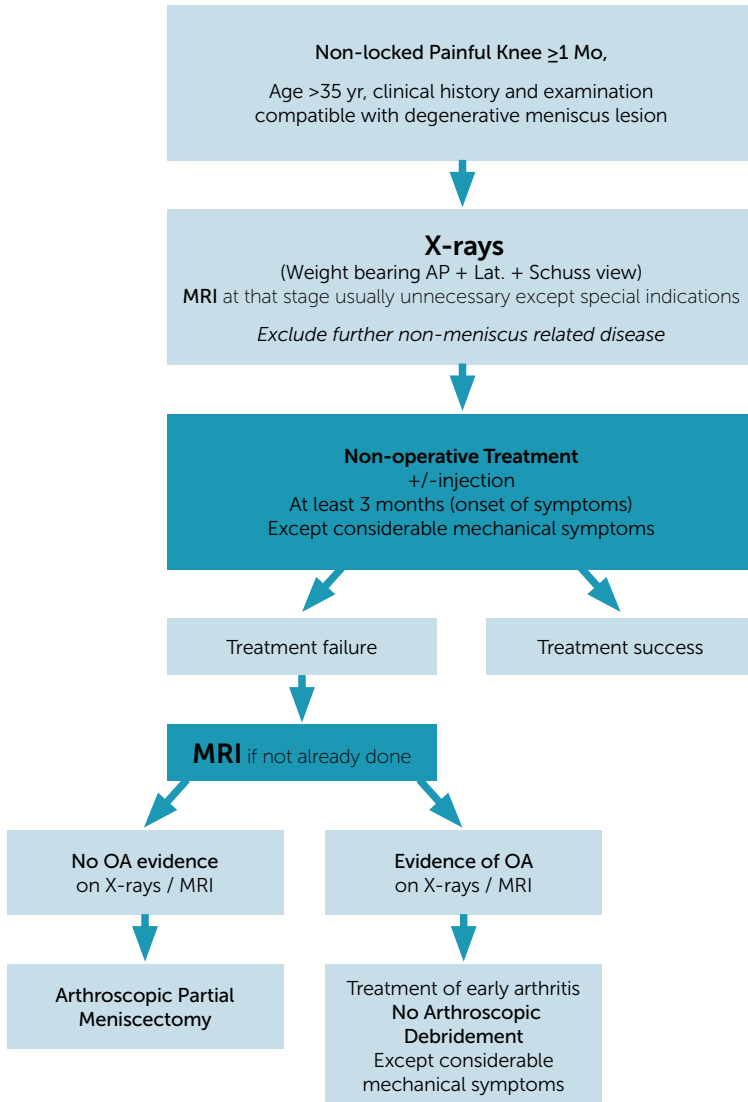
When should APM be proposed?

- Surgery should not be proposed as a first line of treatment of degenerative meniscus lesions. *Grade A*
- After three months with persistent pain / mechanical symptoms: for a degenerative meniscus with normal X-rays/ abnormal MRI (grade III meniscus lesion), APM may be proposed. *Grade B*
- Surgery can be proposed earlier for patients presenting considerable mechanical symptoms. *Grade D* [figure 3]
- No arthroscopic surgery should be proposed for a degenerative meniscus lesion with advanced osteoarthritis on weight bearing radiographs. *Grade A*

Exceptions should be discussed for young patients with considerable symptoms.



ESSKA Meniscus Consensus algorithm



Rating rules and score analysis

Grading description

- *Grade A: high scientific level*
- *Grade B: scientific presumption*
- *Grade C: low scientific level*
- *Grade D: expert opinion*

Each question of the text was rated according to discrete numerical scale running from 1 to 9 conforming to the "Formal consensus" method:

Meaning of the discontinuous numerical scale running from 1 to 9								
1	2	3	4	5	6	7	8	9
Totally inappropriate	Undecided						Totally appropriate	

Contact Information

ESSKA Office

Anna Hansen Rak
Project Coordinator
Phone: +352 4411 7026
Fax: +352 4411 7678
e-mail: info@esska.org

www.esska.org