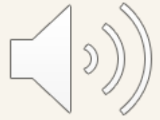





# DISCLOSURE STATEMENT

- I have no conflicts of interest to report and attest I have no financial relationship with any commercial interests relevant to this presentation and received no monetary support for providing this continuing education opportunity.



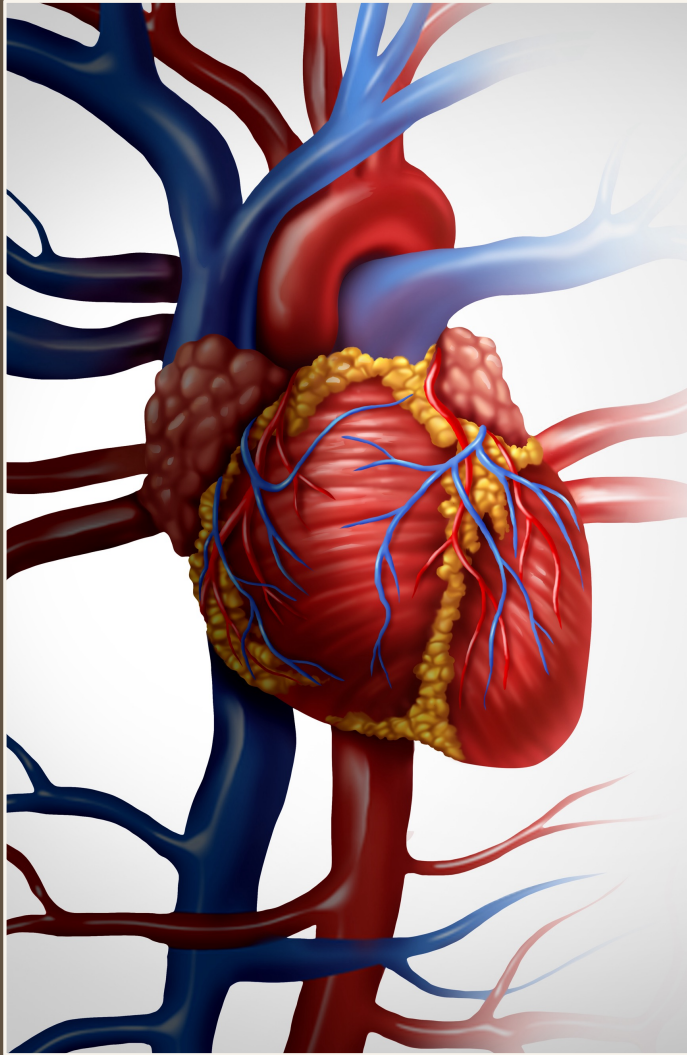
# OBJECTIVES

- Review the prevalence of substance use disorders in the U.S.
- Discuss the cardiovascular, hepatic, renal, and gastrointestinal impact of substances of abuse.



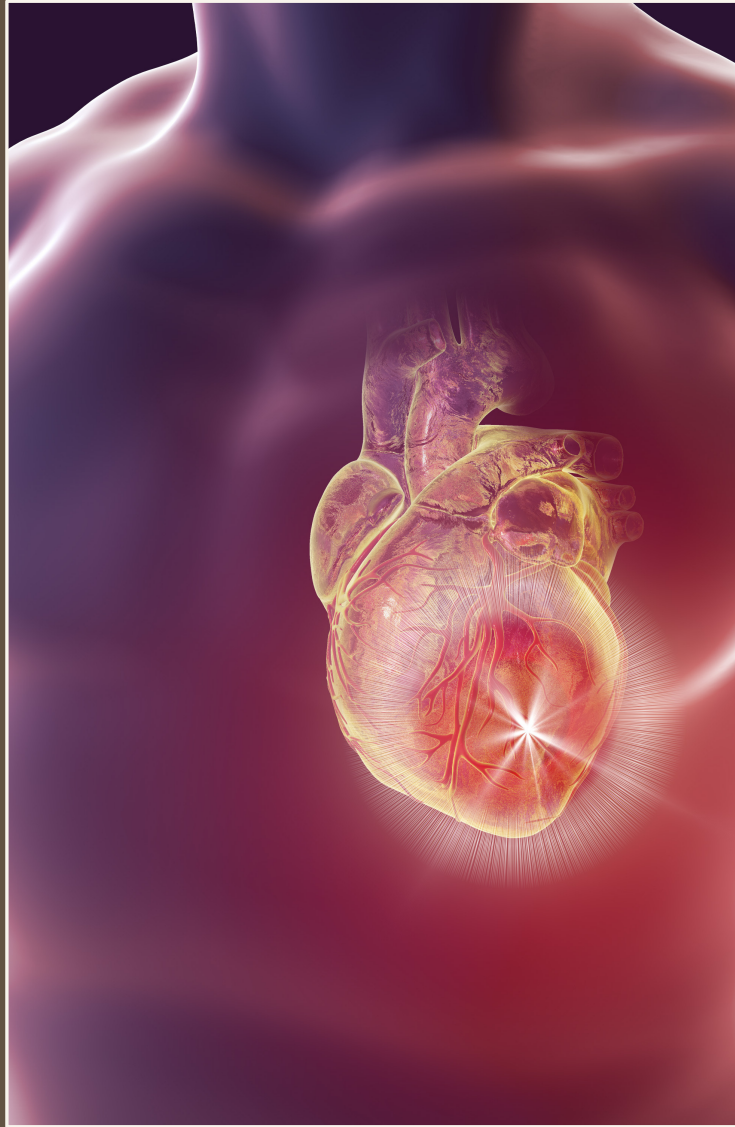# STATISTICS AMONG PEOPLE AGED 12 AND OLDER IN THE U.S.

- 20.7% used nicotine products in the past month
- 50% used alcohol in the last month
- 21.4% used illicit drugs in the past year, including 17.9% who used marijuana
- 3.4% misused opioids in the past year
- 14.5% had a substance use disorder in the past year
- 14.9% needed substance abuse treatment in the past year
- 1.4% received substance use treatment in the past year



# CARDIOVASCULAR ALCOHOL

Left ventricular dysfunction  
Cardiomyopathy  
Sudden cardiac death  
Hypertension  
Atrial fibrillation  
Ventricular arrhythmias  
Ischemic stroke



# CARDIOVASCULAR COCAINE

Chest pain

Acute myocardial infarction

Aortic dissection

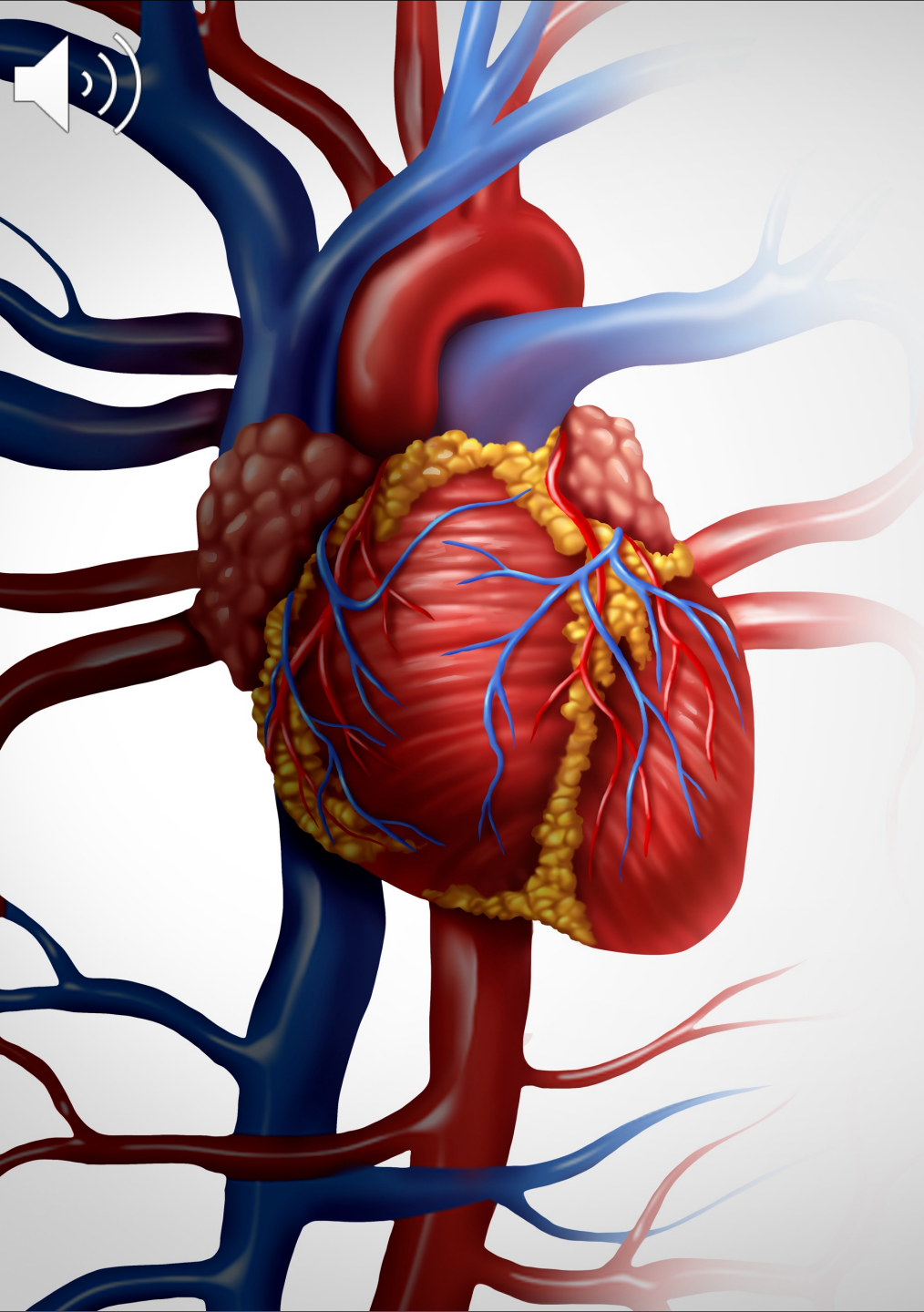
Stroke (ischemic and intracerebral hemorrhage)

Heart failure

Sudden cardiac death

Atherosclerosis

Hypertension



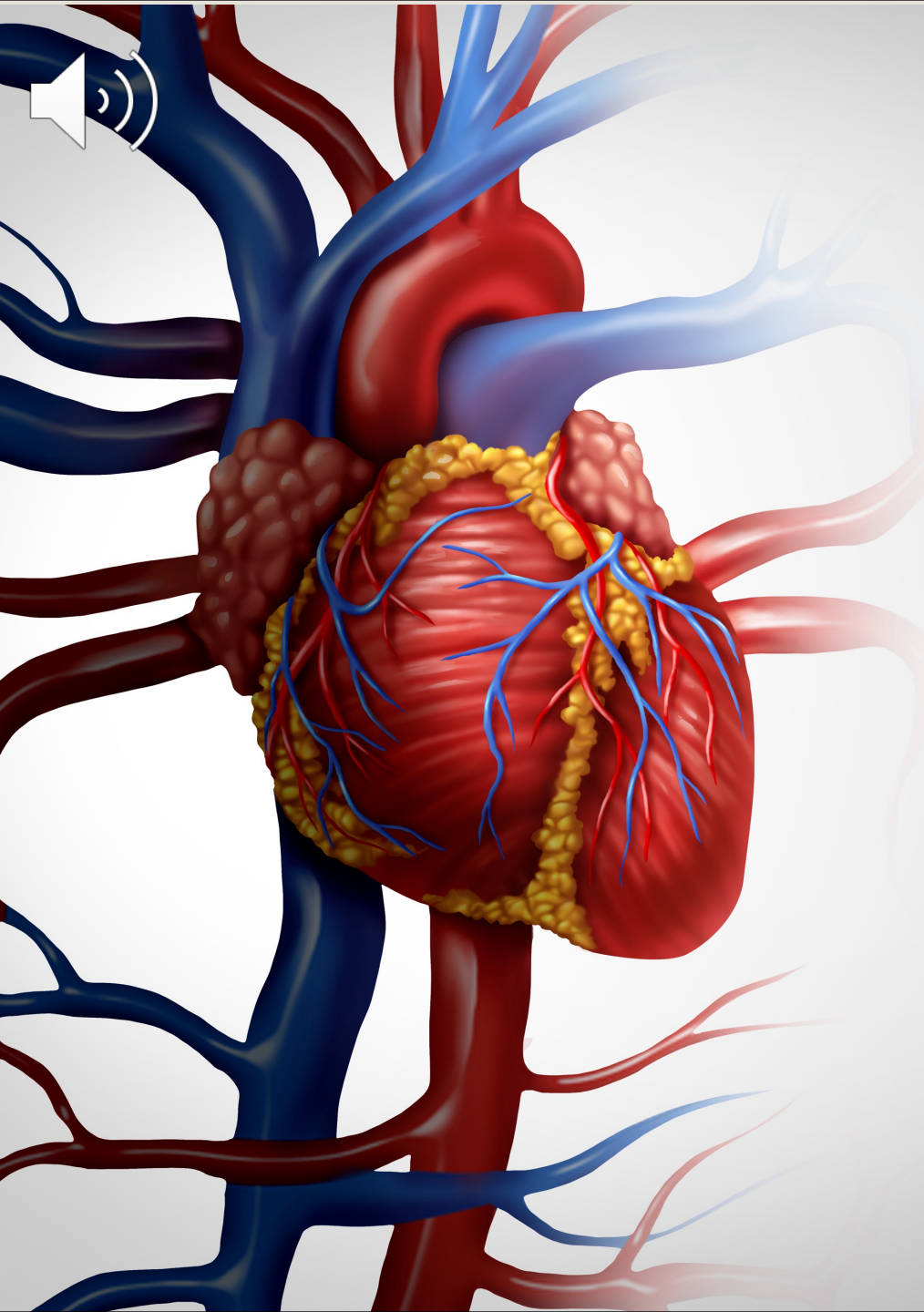
# CARDIOVASCULAR

## Nicotine

- Cardiac arrhythmias, especially atrial fibrillation
- Coronary atherosclerosis
- Alters normal platelet function

## Cannabis

- Tachycardia
- Atherosclerosis
- Ischemic stroke



# CARDIOVASCULAR

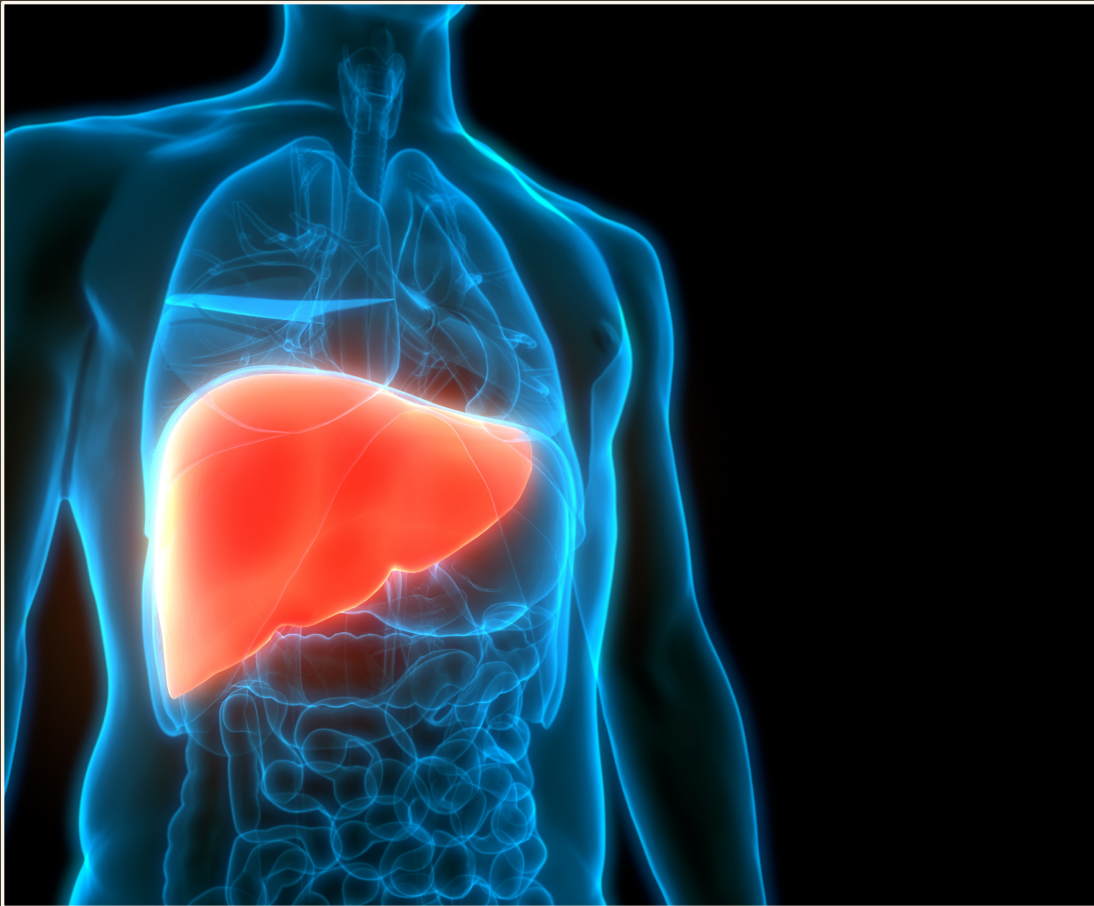## Opioids

- Infectious endocarditis

## Amphetamines

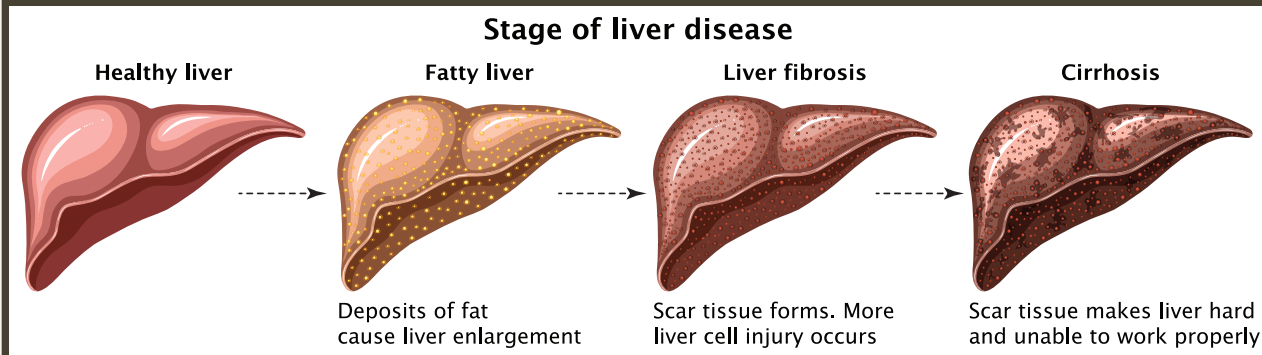
- Tachycardia
- Hypertension
- Acute myocardial infarction
- Cardiomyopathy and decompensated heart failure

# HEPATIC

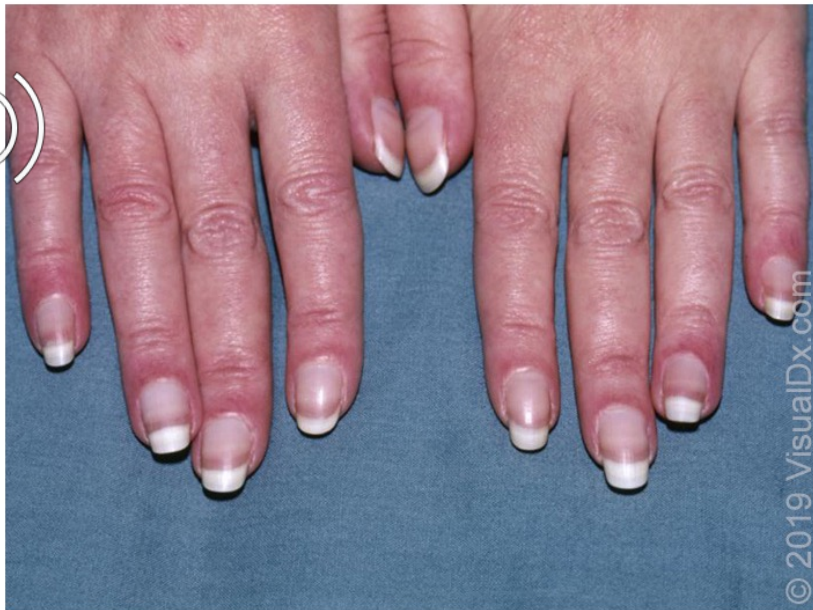

## ALCOHOLIC LIVER DISEASE

- Clinical features: decreased muscle mass, palmar erythema, spider naevi, nail changes (e.g., Terry nails, Muehrcke nails), loss of body hair (males), hirsutism (women), gynecomastia, testicular atrophy, splenomegaly, caput medusa (portal hypertension)
- Decompensation: jaundice, encephalopathy, petechial hemorrhage or ecchymoses, ascites
- Labs:  $\uparrow$ INR,  $\downarrow$  albumin,  $\uparrow$  bilirubin,  $\uparrow$  serum globulin, thrombocytopenia, macrocytic anemia, hypoglycemia



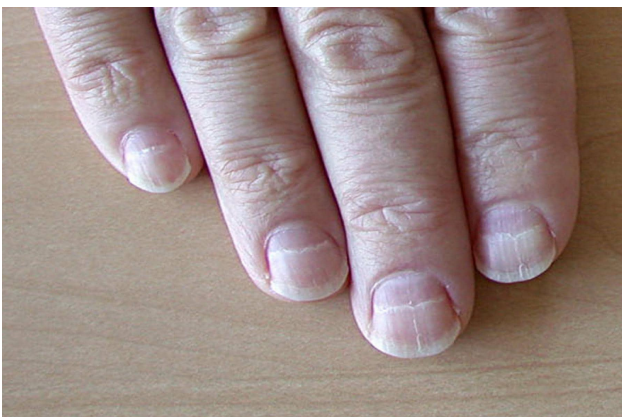
## Terry nails



White discoloration of the proximal nail plate in a patient with liver cirrhosis.

Reproduced with permission from: [www.visualdx.com](http://www.visualdx.com). Copyright VisualDx. All rights reserved.

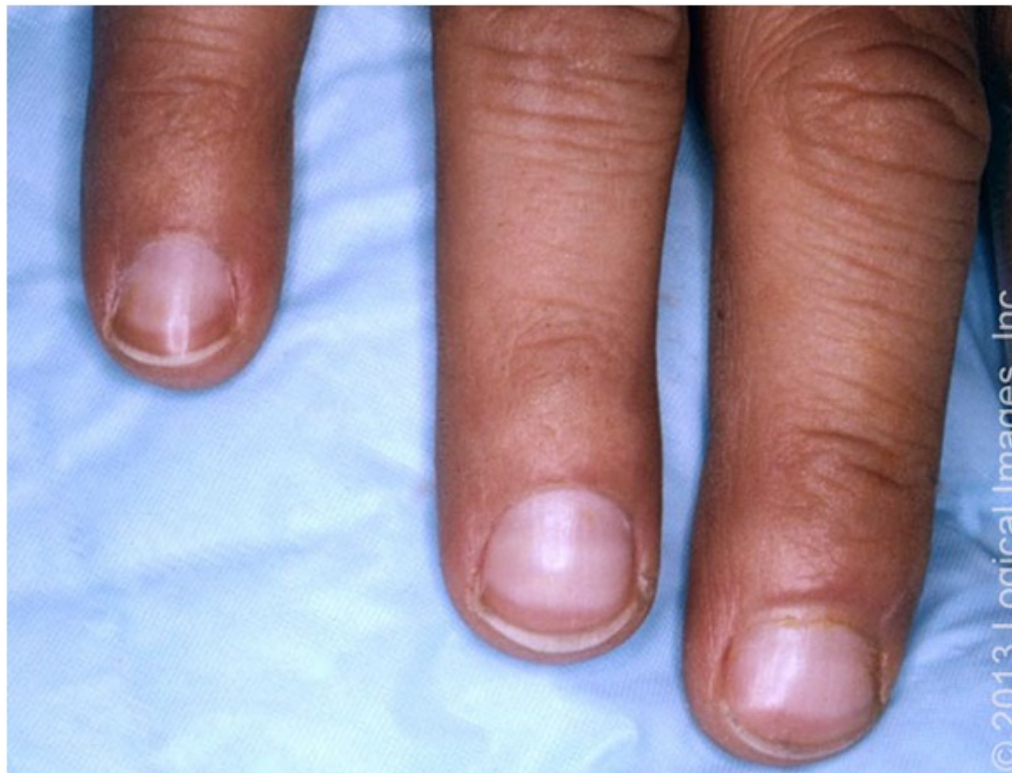UpToDate®



## Muehrcke Lines

Copyrights apply

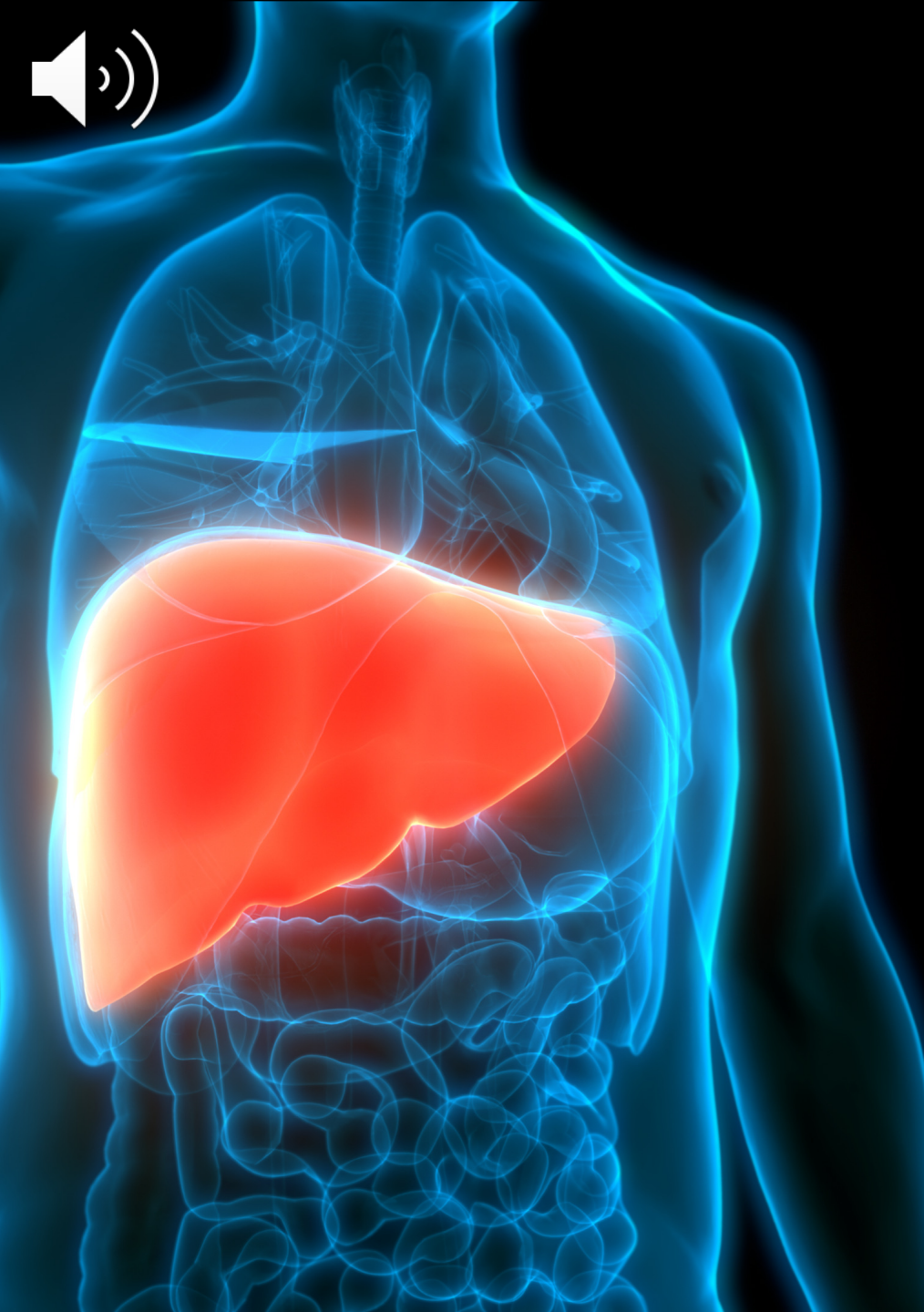## Terry nails



Patients with cirrhosis may have a finding known as Terry nails. In patients with Terry nails, the proximal two-thirds of the nail plate appears white, whereas the distal one-third is red. This finding is believed to be secondary to a low serum albumin. Terry nails may also be seen in patients with renal failure, diabetes, and heart failure.

Reproduced with permission from: [www.visualdx.com](http://www.visualdx.com). Copyright VisualDx. All rights reserved.

UpToDate®



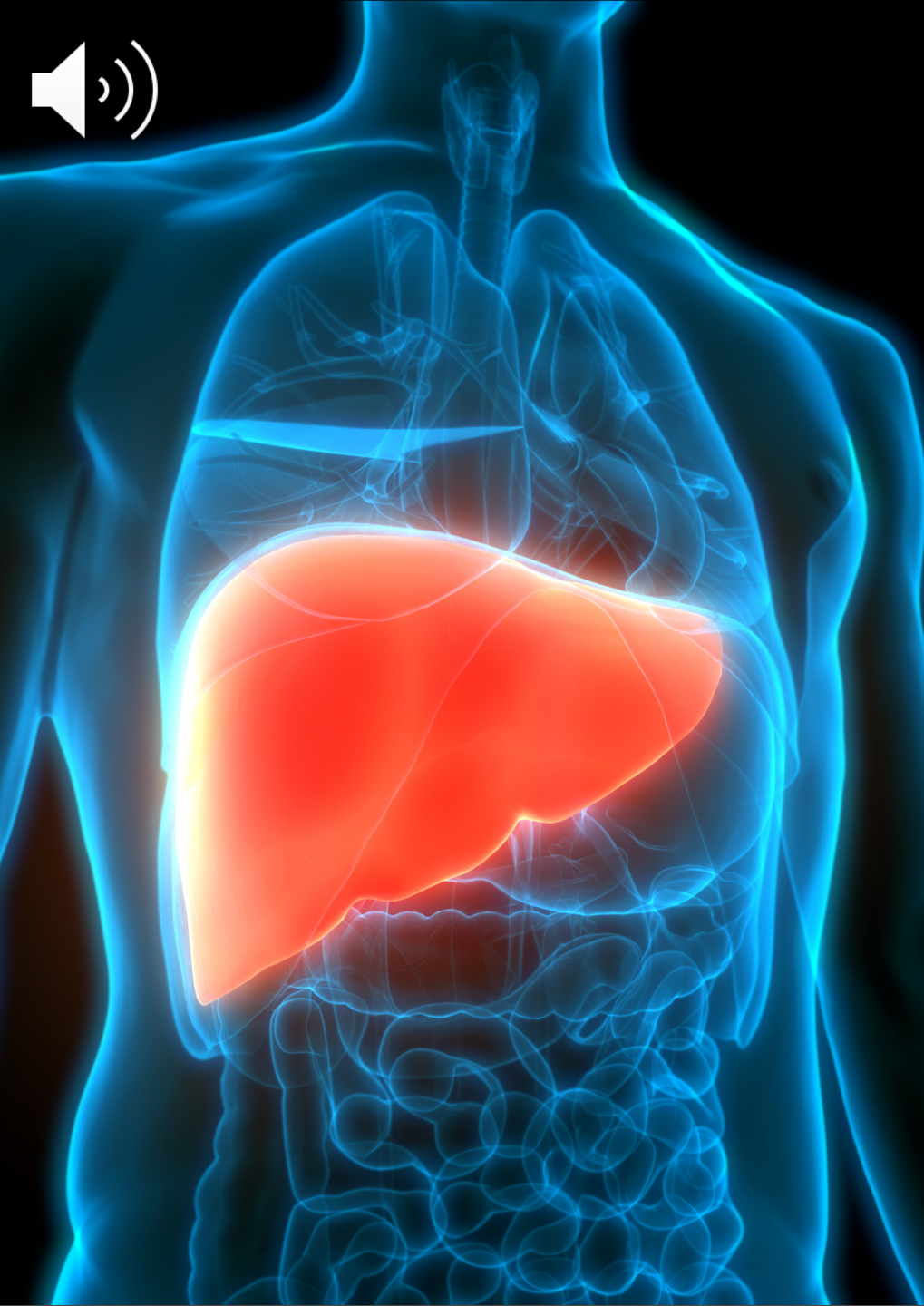# HEPATIC

## Cannabis

- Accentuate other hepatic injuries
- Steatosis
- Fibrosis

## Androgenic/Anabolic Steroids

- Cholestasis
- Toxic hepatitis
- Hepatic adenomas and carcinomas



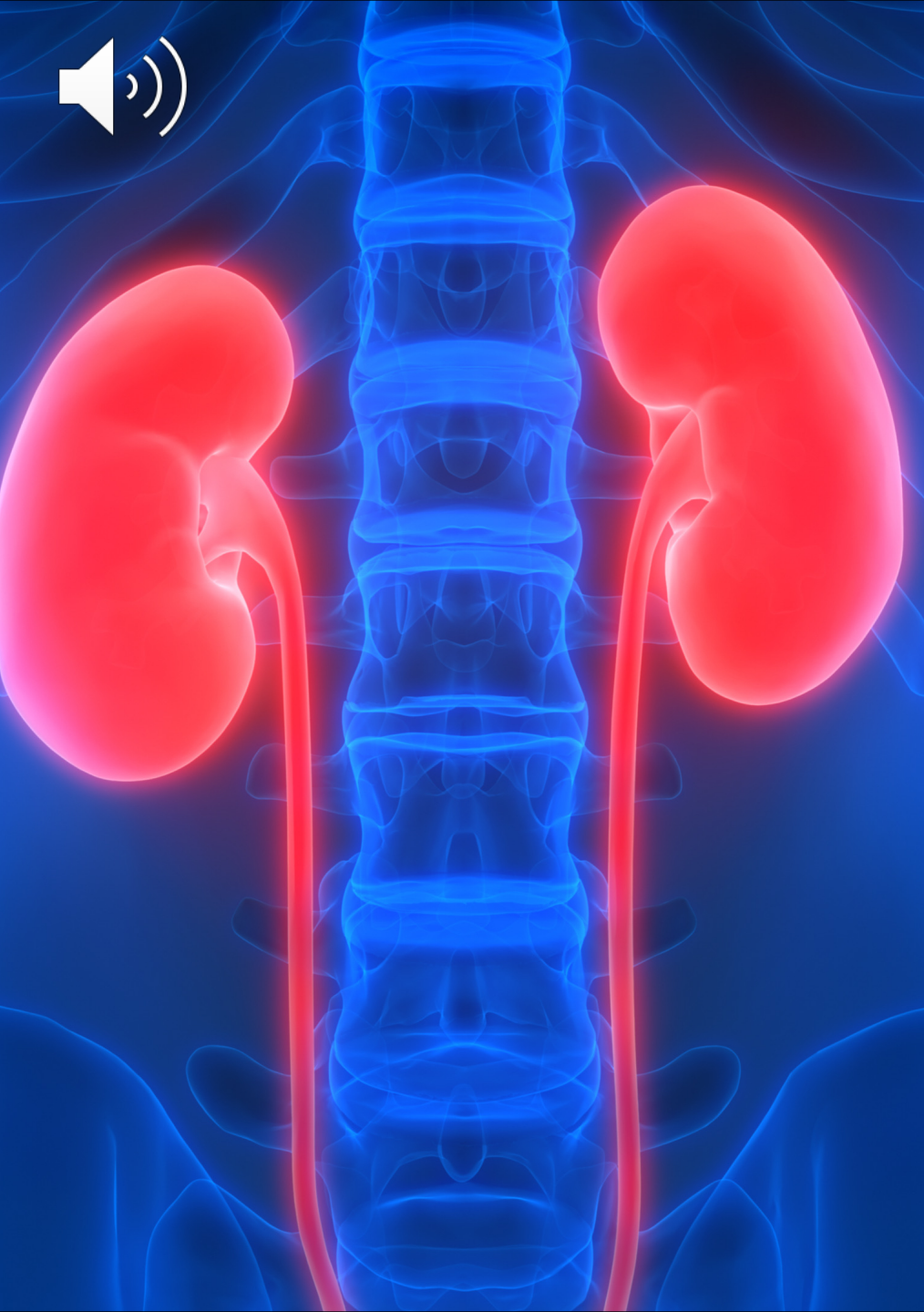
# HEPATIC RARE COMPLICATIONS

## Cocaine Hepatitis

- Hyperthermia
- Rhabdomyolysis
- Hypoxia
- Hypotension

## Liver Injury/Failure

- MDMA, Ecstasy
- Bath salts
- Khat
- Phencyclidine (PCP)



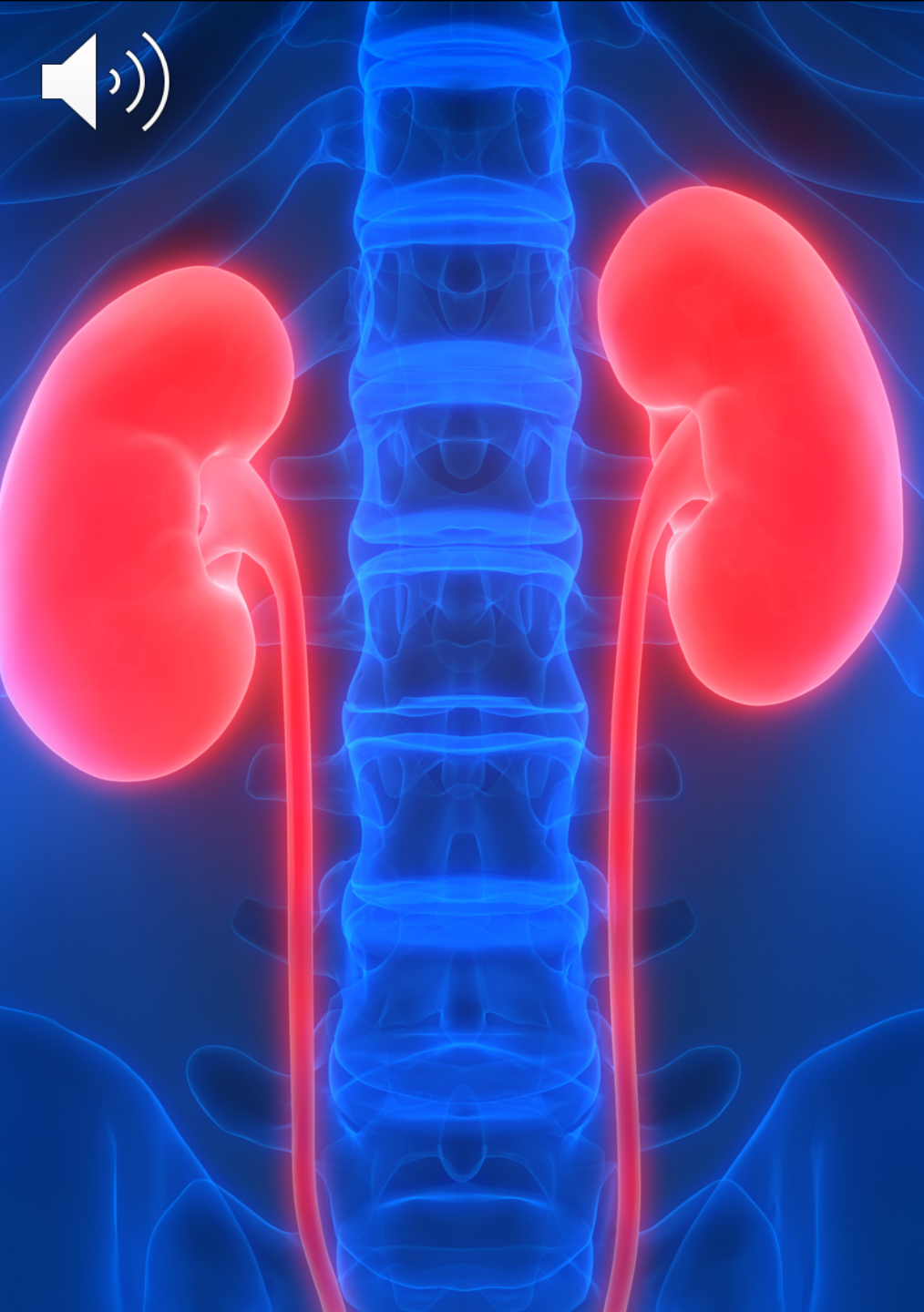# RENAL AND METABOLIC

## Alcohol

- Ketoacidosis
- Inhibition of gluconeogenesis
- Acceleration of lipolysis
- Hypomagnesemia
- Hypocalcemia
- Hypokalemia
- Hypophosphatemia

## Hepatorenal syndrome

- Toxic alcohols
  - Ethylene glycol (antifreeze)
  - Isopropyl alcohol
  - Methanol
  - Varnish or shellac
- Organ damage
- Anion gap acidosis



# RENAL AND METABOLIC OPIOIDS AND HEROIN

## Nephrotic Syndromes

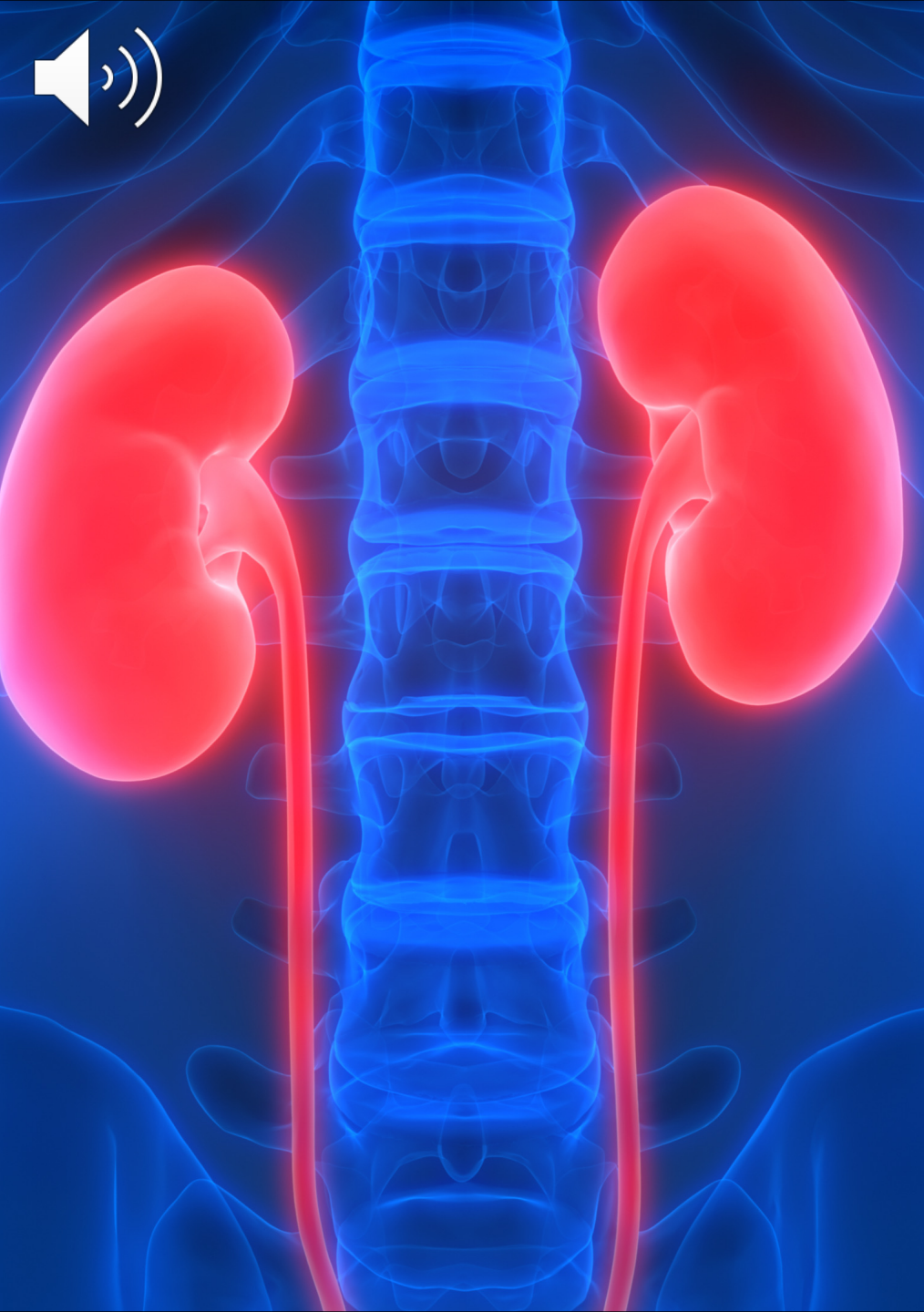- HIV-associated neuropathy
- Hepatitis Virus-Associated Nephrotic Syndrome
- Heroin-Associated Neuropathy
- Subcutaneous Drug Use-Associated Amyloidosis

## Nephritic-Nephrotic Syndromes

- Hepatitis C Virus-Related Glomerulonephritis

## Nephritic Syndromes

- Postinfectious Glomerulonephritis
- Rhabdomyolysis
- Intravenous Use of Prescription Opioids
- Other Renal Effects



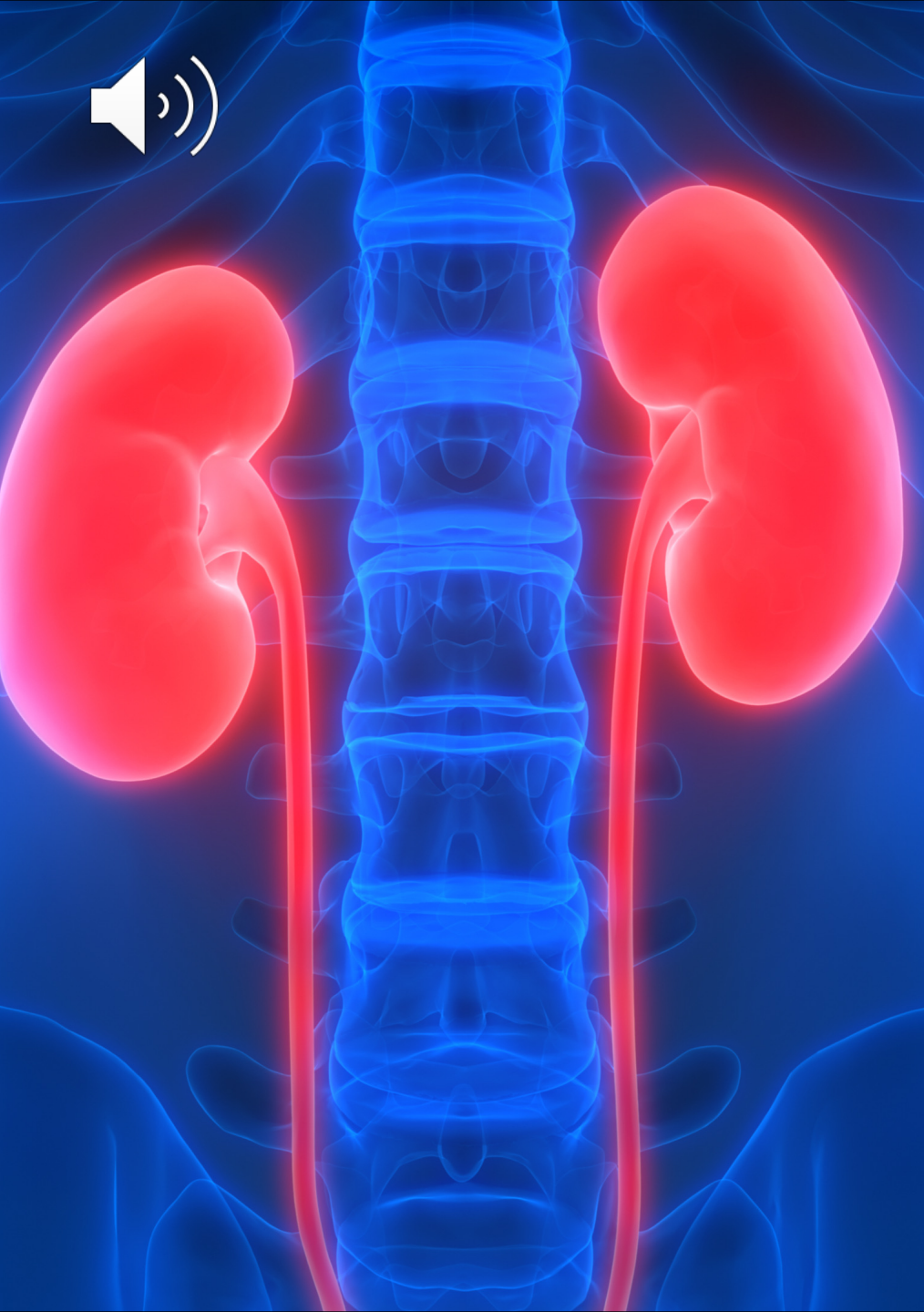# RENAL AND METABOLIC

## Cocaine

- Cocaine-Related Vasculitis
- AKI and Rhabdomyolysis Associated with Cocaine Use
- Cocaine, hypertension, and renal disease
- Cocaine-induced thrombotic microangiopathy-hemolytic uremic syndrome

## MDMA (Ecstasy)

- Hyponatremia
- Rhabdomyolysis
- Acute hyperthermia
- Cardiac and neurological injury
- Acute kidney injury



# RENAL AND METABOLIC

## Amphetamines

- Polyarteritis nodosa
- Acute kidney injury
- Rhabdomyolysis
- Hypertension

## Bath salts

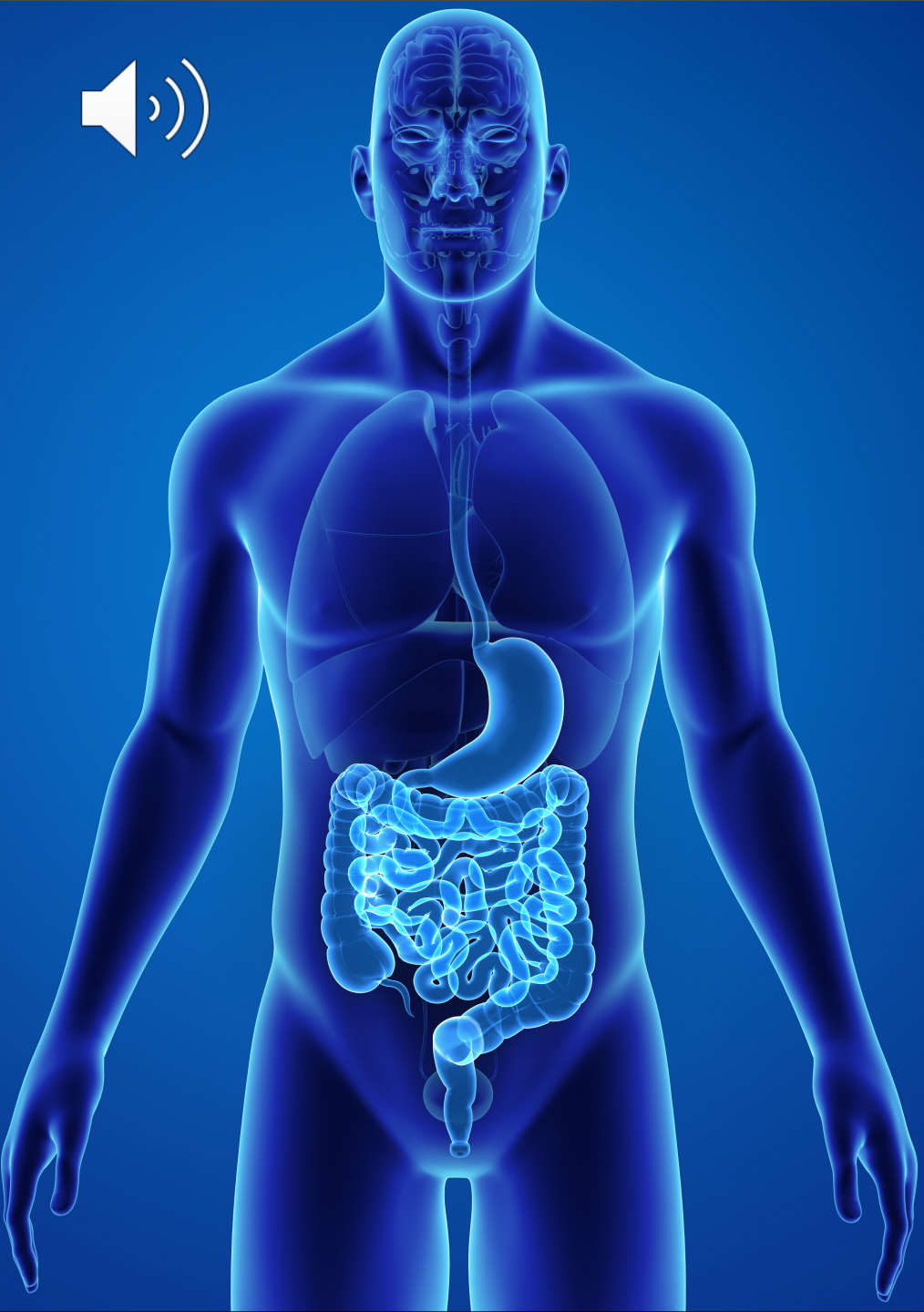- Renal hypoperfusion
- Renal ischemia
- Acute tubular necrosis
- Rhabdomyolysis
- Hyperuricemia

## Inhalants

- Acute renal failure
- Metabolic acidosis
- Hypokalemia

## Cannabinoids

- Acute renal failure



# GASTROINTESTINAL ALCOHOL

## Parotid Glands and Oral Cavity

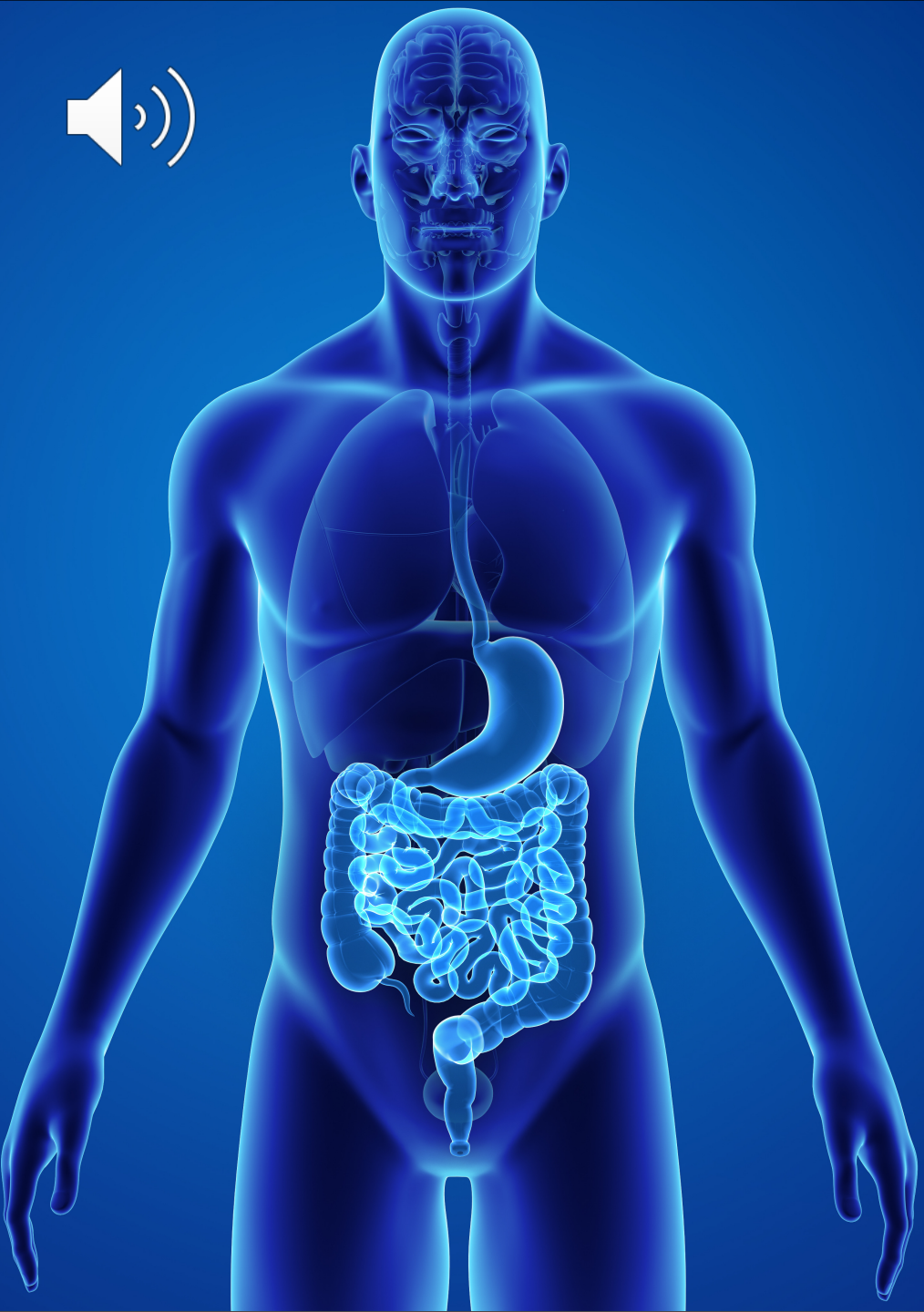
- Sialosis
- Dental caries
- Glossitis
- Stomatitis
- Cancers

## Esophagus

- Heartburn
- GERD
- Mallory-Weiss syndrome

## Stomach

- Alcoholic gastritis
- Gastric hemorrhage
- Erosive lesions
- Gastric ulcers



# GASTROINTESTINAL- ALCOHOL

## Pancreas

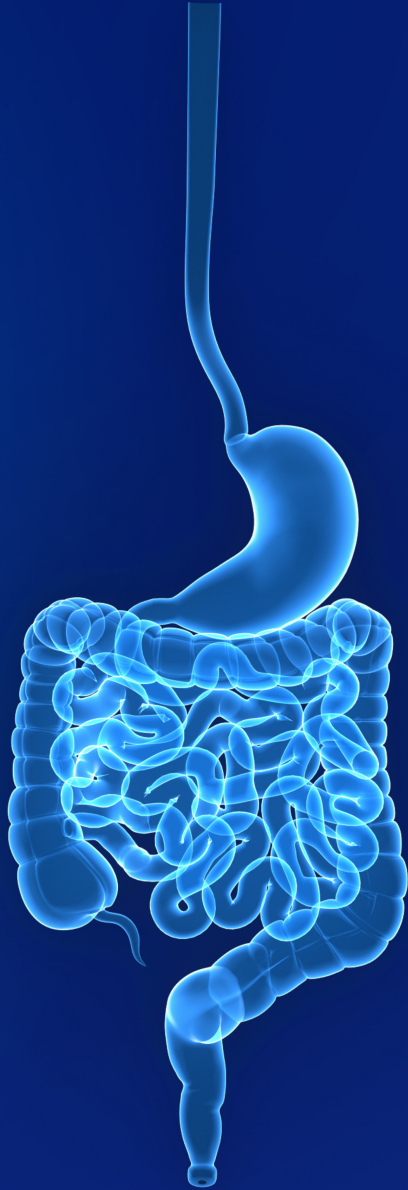- Alcohol-related pancreatitis

## Small intestine

- Diarrhea
- Mucosal injury
- Inhibits absorption
- Exacerbates lactase deficiency

## Colon

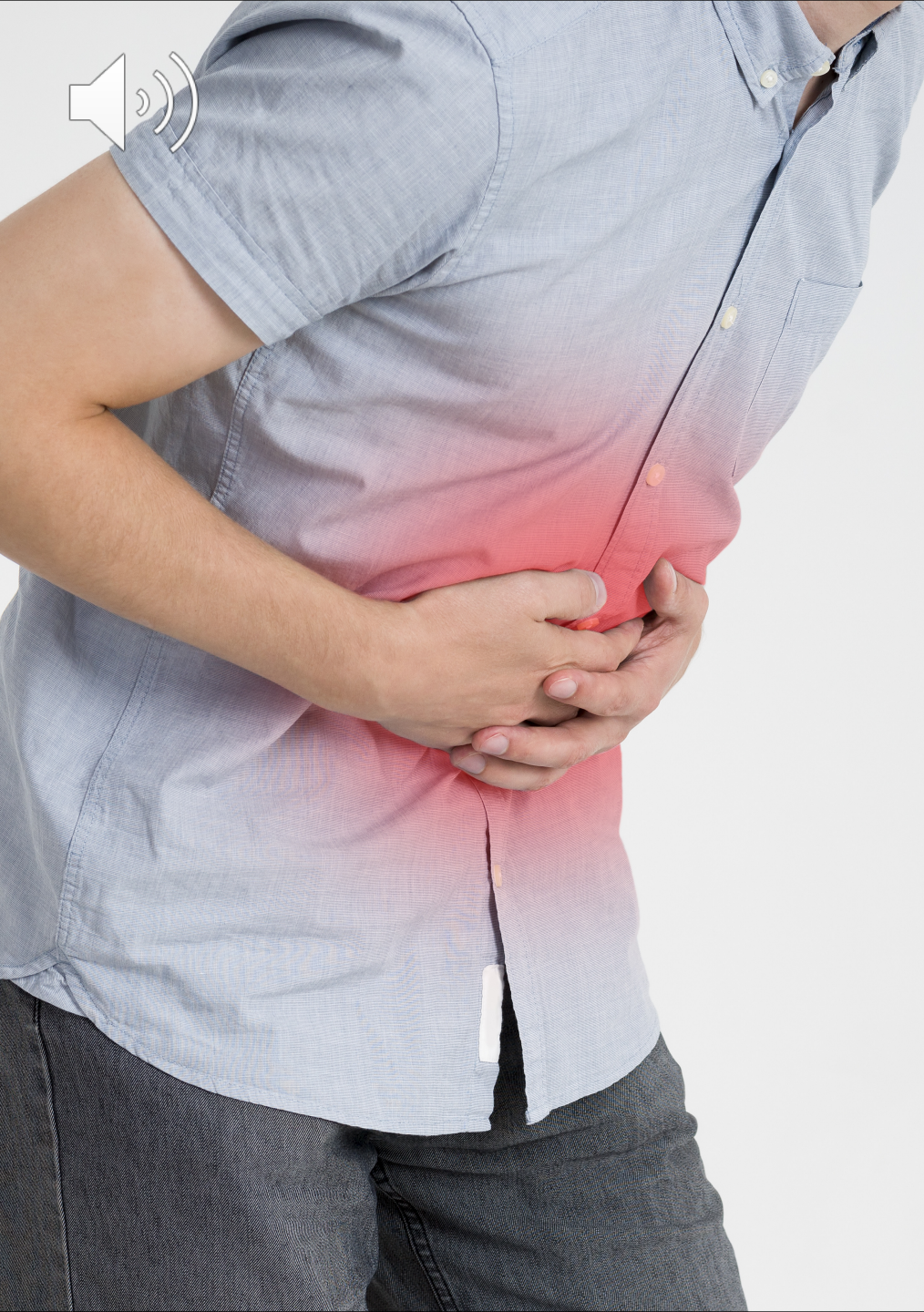- Colonic varices
- Nonulcerative inflammatory changes



# GASTROINTESTINAL CANCERS

## ALCOHOL

- Tongue
- Mouth
- Pharynx
- Larynx
- Esophagus
- Stomach
- Pancreas
- Colon
- Liver



# GASTROINTESTINAL

## Opioids

- Constipation
- Ileus

## Laxative misuse

- Chronic diarrhea

## Anticholinergics

- Constipation
- Abdominal pain
- Dry mouth
- Blurred vision
- Delirium

## Psychostimulants

- Intestinal perforation
- Infarction of the gut
- Ischemic colitis

## Drug packets seen in stomach on plain abdominal radiograph



# GASTROINTESTINAL

## Tobacco

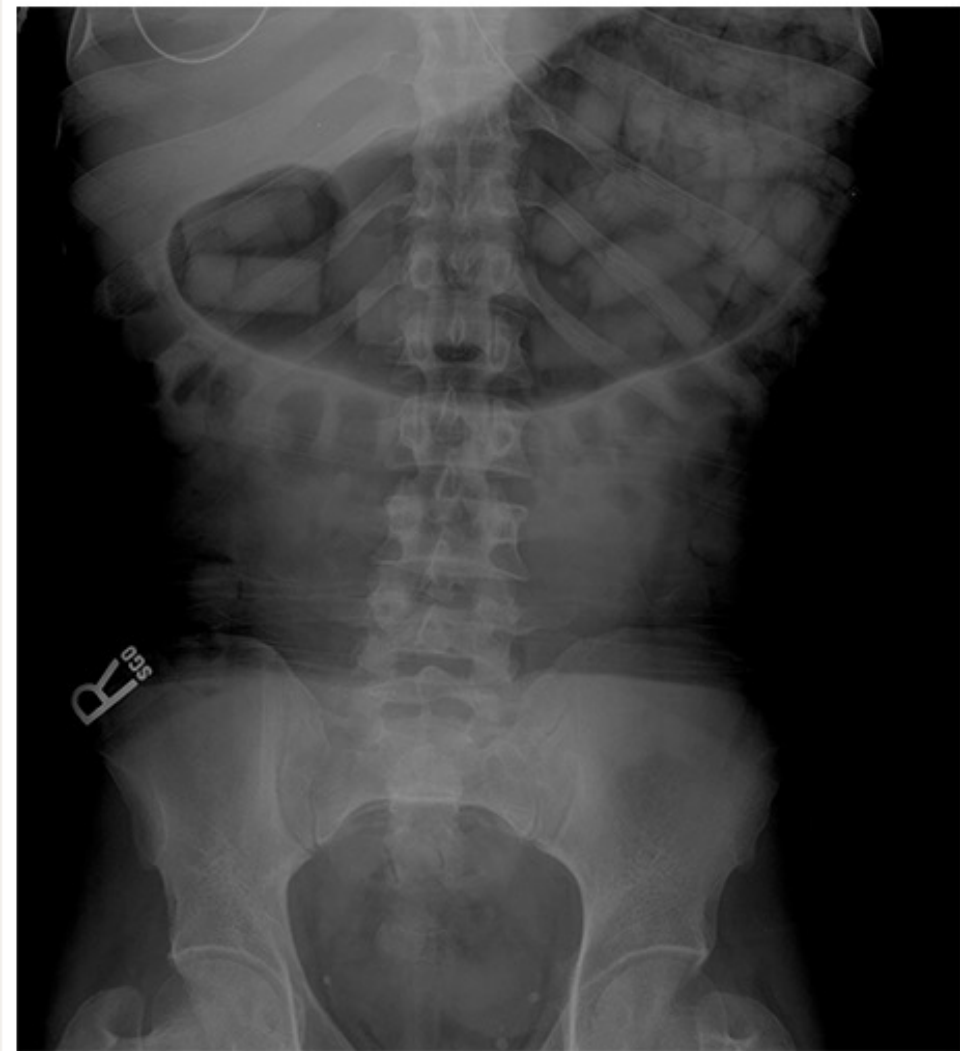- GERD
- Peptic ulceration
- Pancreatic disease
- Inflammatory bowel disease
- Gastrointestinal malignancy

## Cannabis

- Cannabis hyperemesis syndrome

## “Body Packing Syndrome”

- Life-threatening intoxication



In this plain radiograph, multiple drug packets are seen in the stomach of a patient who presented with vomiting secondary to gastric outlet obstruction.

Courtesy of Robert Hoffman, MD



THANK YOU  
FOR LISTENING!

Feel free to contact me at  
[karenzak@flanp.org](mailto:karenzak@flanp.org)

# REFERENCE

Miller, S. (2018). *The ASAM Principles of Addiction Medicine* (6th Edition). Wolters Kluwer Health.

NHTSA. 2022. Traffic safety facts. Retrieved from <https://crashstats.nhtsa.dot.gov/Api/Public/ViewPublication/813294>

Patel, A.K. Reddy, V, Shumway, K.R., & Araujo, J.F. (2022). Physiology, sleep stages. StatPearls [Internet]. Treasure Island, FL: StatPearls Publishing Available from: <https://www.ncbi.nlm.nih.gov/books/NBK526132/>

SAMHSA. 2020. Highlights for the 2020 national survey on drug use and health. Retrieved from [https://www.samhsa.gov/data/sites/default/files/2021-10/2020\\_NSDUH\\_Highlights.pdf](https://www.samhsa.gov/data/sites/default/files/2021-10/2020_NSDUH_Highlights.pdf)

Vuong, C., Van Uum, S.H.M., O'Dell, L.E., Kabirullah, L., & Friedman, T.C. (2010). The effects of opioids and opioid analogs on animal and human endocrine systems. *Endocrine Reviews* 31(1):9–132.

# REFERENCE—IMAGES

Medscape. 2021. Muehrcke lines of the fingernails. Retrieved from: <https://emedicine.medscape.com/article/1106423-overview>

All other images were obtained online from Pexels and Shutterstock