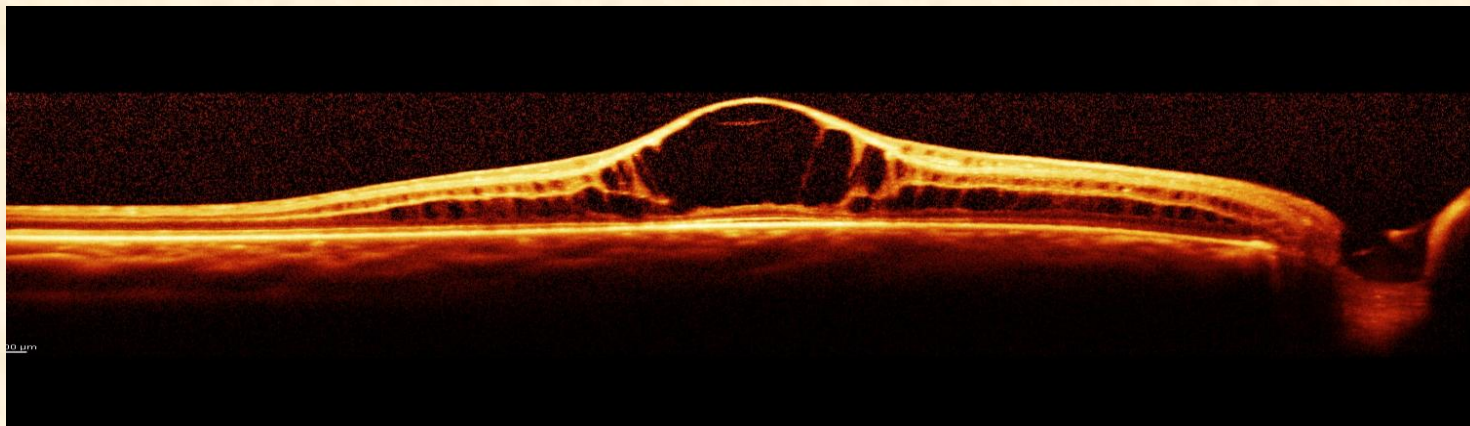


Descriptive Interpretation of OCT



Elizabeth L Affel, MS, OCT-C
Ophthalmic Photographers'
Society
MidYear Meeting 2013

Describe

- ***de·scribe* / di□skrīb /**
- Verb: Give an account in words of (someone or something), including all the relevant characteristics, qualities, or events.
- Indicate; denote.
- Synonyms: depict - delineate - portray - picture – represent
 - wikipedia

Interpret

- **in·ter·pre·ta·tion**
- *noun* \in- tər-prə- tā-shən, -pə-\ (*Medical Dictionary*)
- **Medical Definition of *INTERPRETATION***
- : the act or result of giving an explanation of something <*interpretation* of the symptoms of disease>; *especially* : an explanation in understandable terms to a patient in psychotherapy of the deeper meaning according to psychological theory of the material related and the behavior exhibited by the patient during treatment
- —**in·ter·pret** *transitive verb*
- —**in·ter·pre·tive** or **in·ter·pre·ta·tive** *adjective*

• Merriam Webster

Interpret

- **Verb**
- **interpret** (*third-person singular simple present interprets, present participle interpreting, simple past and past participle interpreted*)
- To explain or tell the meaning of; to expound; to translate orally into intelligible or familiar language or terms; to decipher; to define; -- applied especially to language, but also to dreams, signs, conduct, mysteries, etc.; as, to interpret the Hebrew language to an Englishman; to interpret an Indian speech.

• wikipedia

Descartian Analysis:

**(the physician's role)*

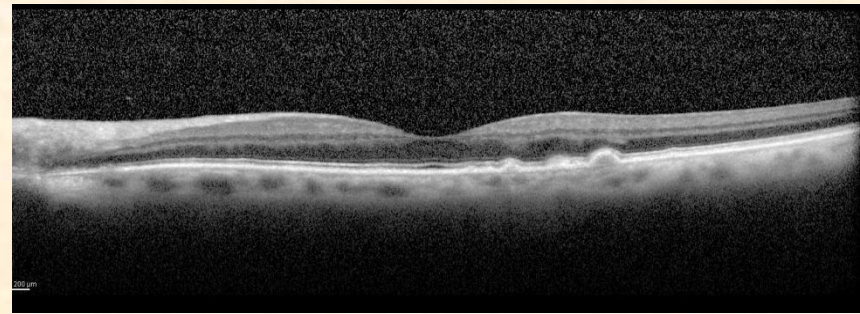
- *The science of the intellect is universal, and there can only be one true method, which consists of **separating what is already simple and clear in order then to attempt to understand that which is complex and obscure.** The method is a collection of reliable, easy rules, observing which there is no risk of mistaking the false for the true. In a logical process, the analyses of each of the possible elements is first performed: Then after this phase, the synthesis of all these elements is performed, and the results of these flow into the conclusions. **To replace the apparent chaos of data with an ordered and rationally constructed system.***

Role of Ophthalmic Imager

- Provide the best quality images
- Facilitate good patient compliance to ease the process and assure repeatability
- Understand (interpret) what is being shown in order to make adjustments to improve the quality of the information

Logical Sequence

- Essential when analyzing (OCT) scan.
- Each element
 - hyperreflective lesions
 - hyporeflective lesions
 - anatomical changes
 - quantitative alterations
 - retinal thickness
 - retinal mapmust be analyzed to arrive at an interpretation.



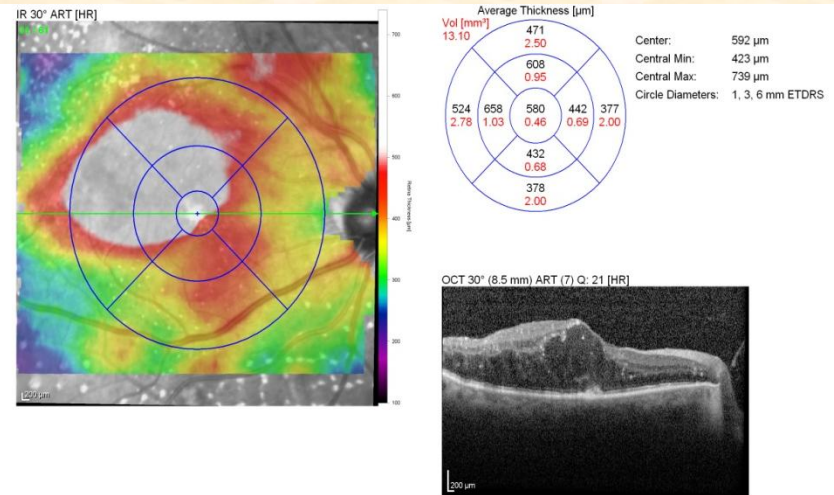
Two Types of Analysis

Qualitative analysis

- morphology and anomalous structures
- reflectivity: hyper, hypo and shadowing

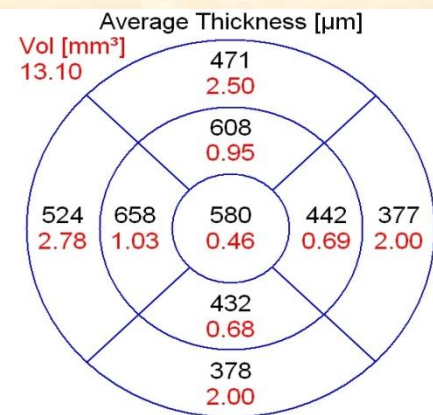
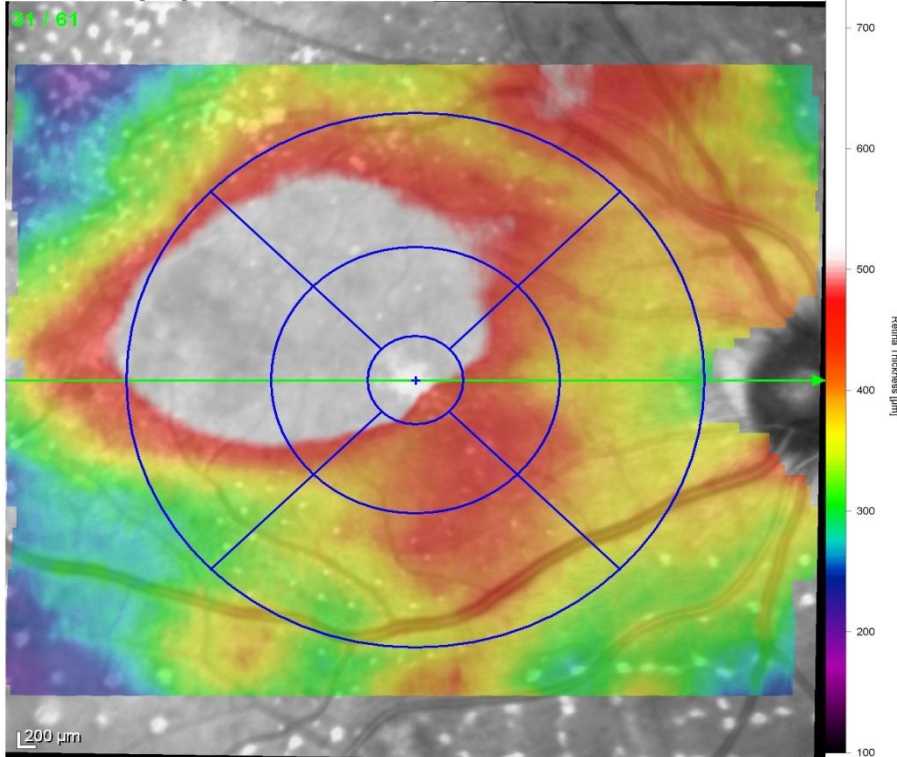
Quantitative analysis

- thickness
- volume
- area



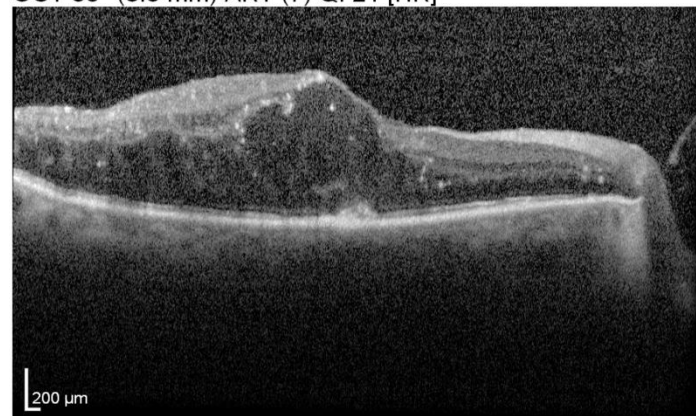
Quantitative /Qualitative

IR 30° ART [HR]



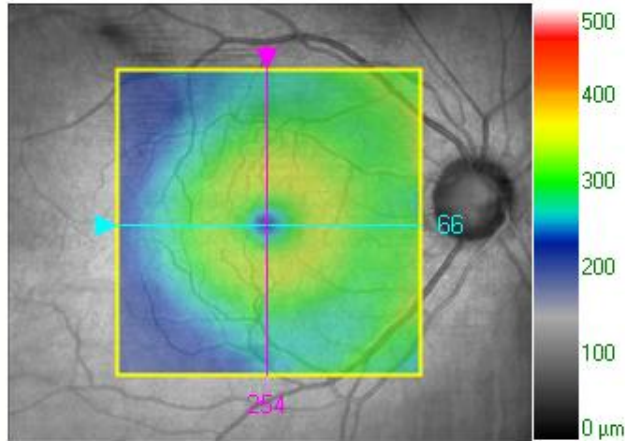
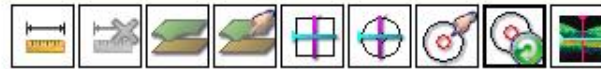Center: 592 μm
 Central Min: 423 μm
 Central Max: 739 μm
 Circle Diameters: 1, 3, 6 mm ETRS

OCT 30° (8.5 mm) ART (7) Q: 21 [HR]



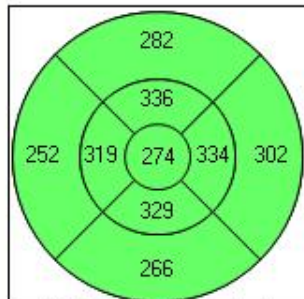
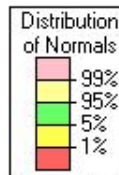
False Color Scale

Signal Strength 10/10

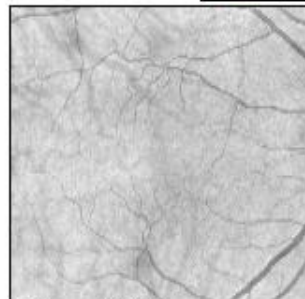


Overlay **ILM - RPE**
 Transparency 50%

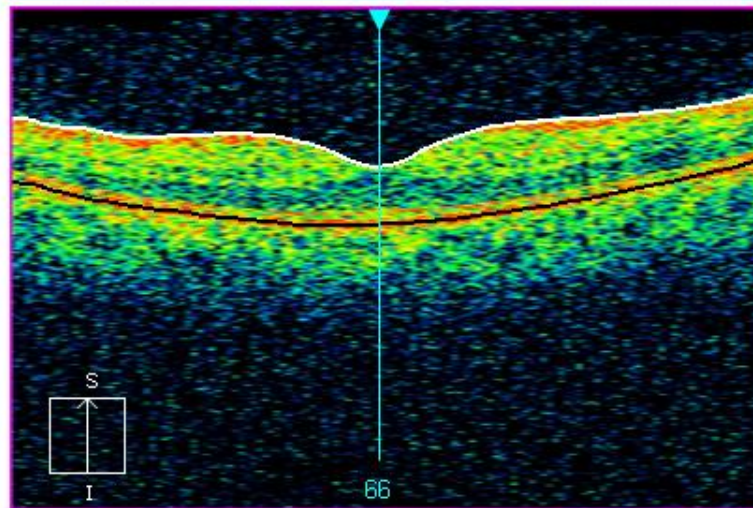
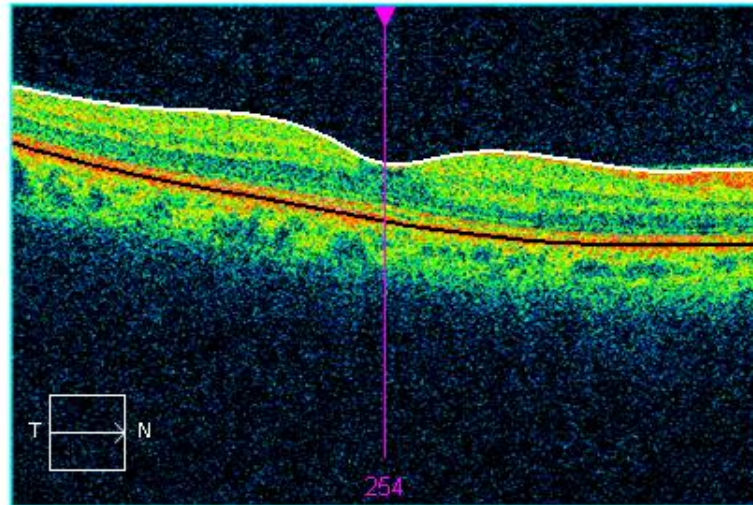
	Central Subfield Thickness μm	Cube Volume mm^3	Cube Avg Thickness μm
ILM - RPE	274	10.2	282



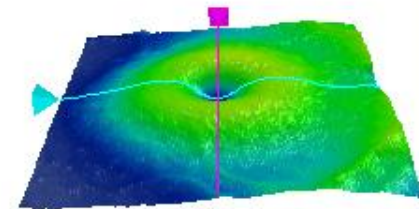
ILM-RPE Thickness (μm)



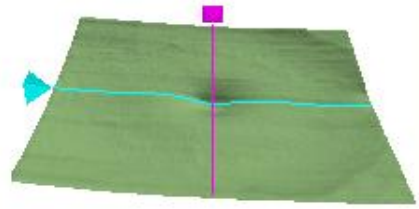
Fovea: 254, 66



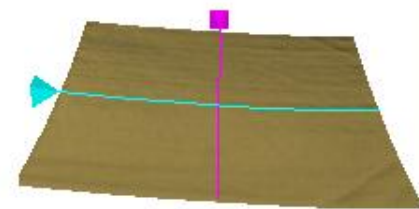
ILM - RPE



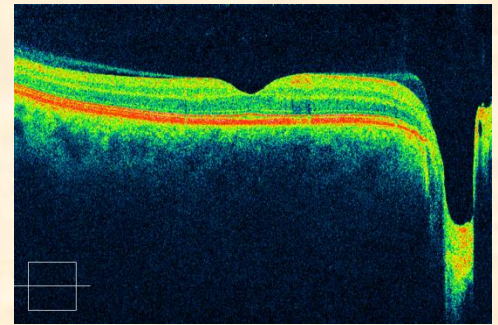
ILM



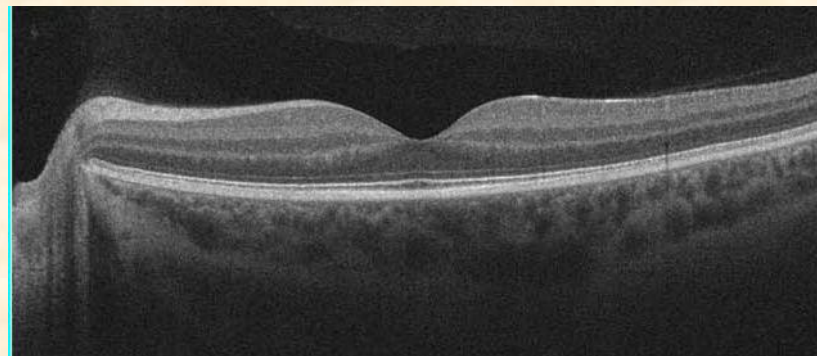
RPE



Normal Scans

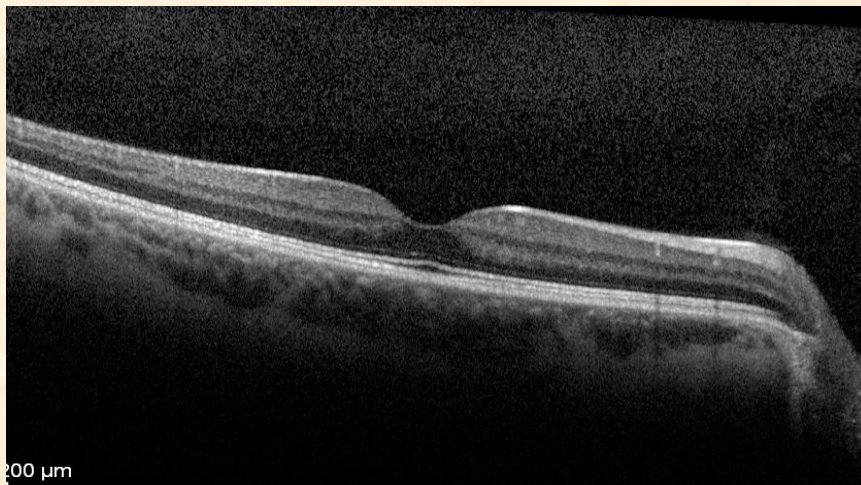
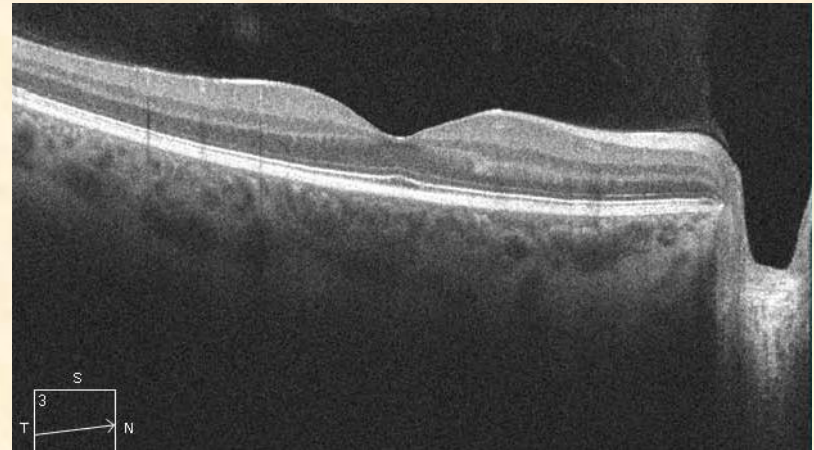


- There are “normals” for ocular structures
- Deviation from the norm = abnormality = pathology
- **Being able to discern *differences* in reflectivity, morphology and qualitative measures either from “normals” or from previous scans is the essence of OCT interpretation**



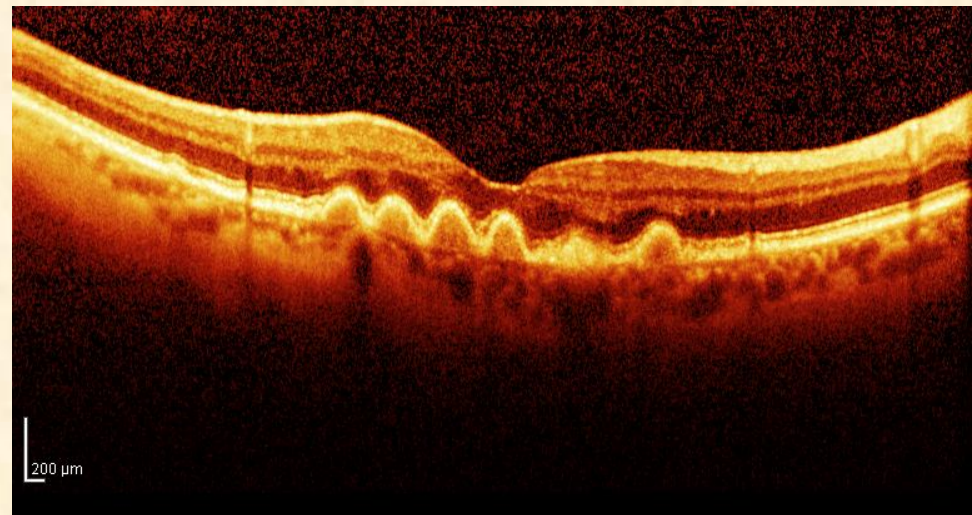
Reflectivity of Normal Retinal Tissues

- High reflectivity
Nerve Fiber Layer
RPE
- Medium
Plexiform layers
Nuclear layers
- Low
Photoreceptors



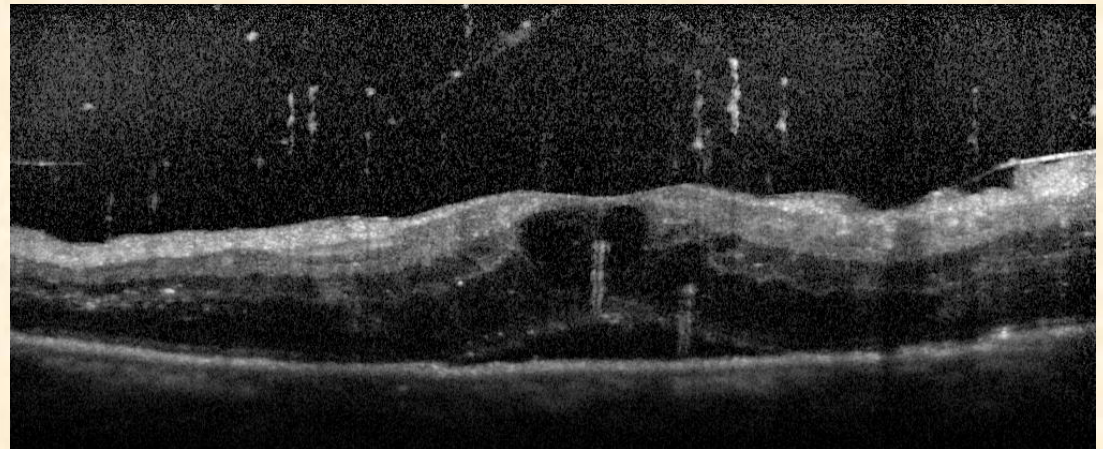
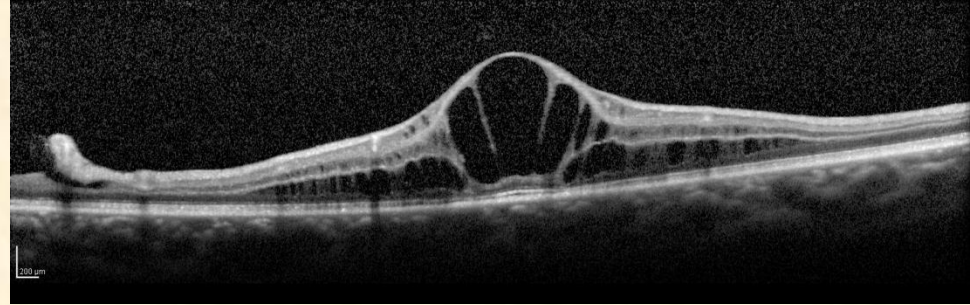
Reflectivity *Increased (hyper)*

- Superficial –
ERM, hemorrhage, cotton-wool spots
- Intraretinal –
hemorrhage, hard exudates
- Deep – drusen, SRNV, nevi, RPE hyperplasia



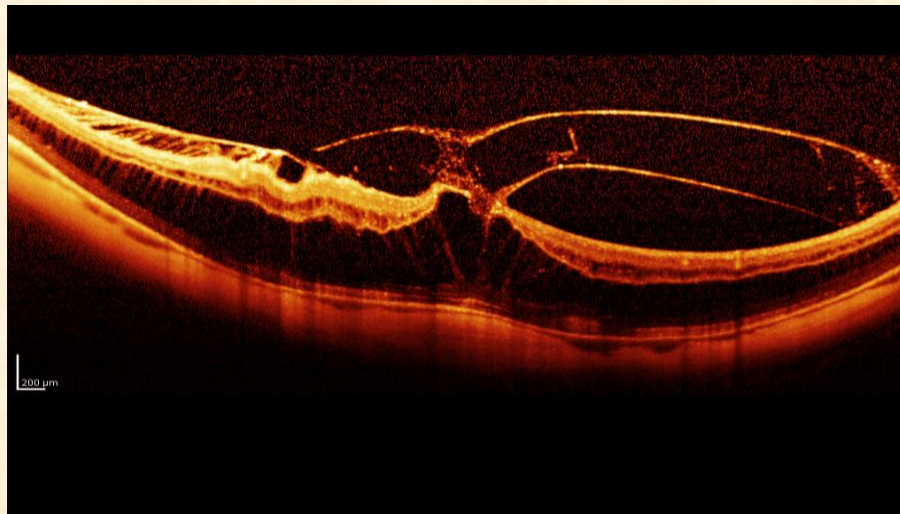
Reflectivity *Reduced (hypo)*

- intraretinal –
- fluid, cysts
- deep – RPE detachments
- *Shadow areas* – “screened”
- anterior –
asteroid bodies, vitreous
hemorrhage



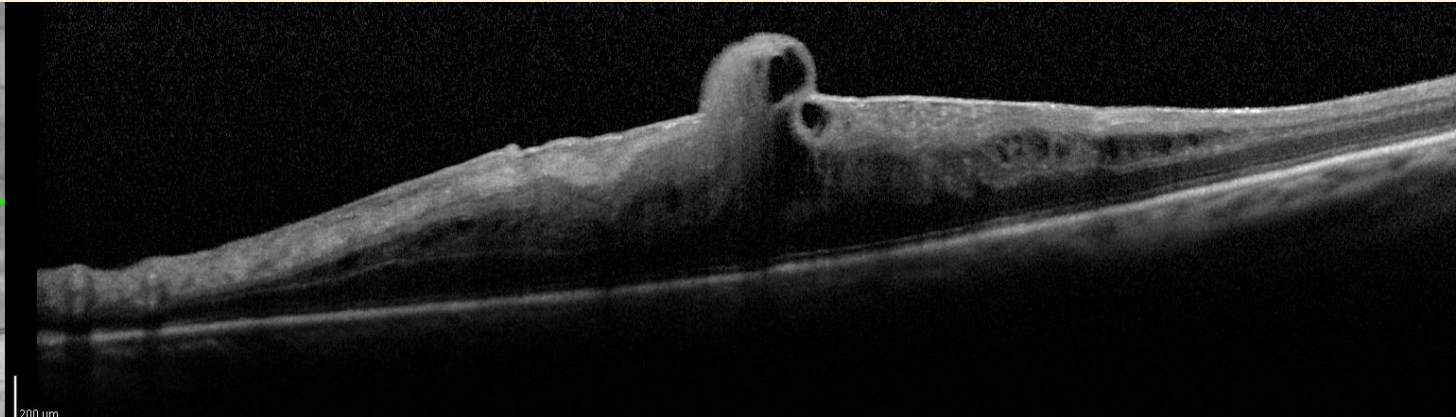
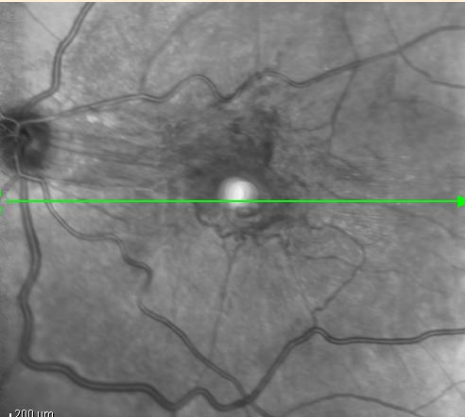Morphological Changes in Structure

- Myopia (concavity)
- Detachments (convexity)
- Vitreo-retinal traction
- Disappearance of the foveal depression
- Surface distortions (folds)
- Separation of tissue (holes)



Morphological changes – *Abnormal Structures*

- Structural changes
- Vitreous strands
- Preretinal neovascular membranes
- Epiretinal membranes
- Exudates
- Drusen
- Choroidal neovascular membranes



Qualitative

- Boundaries of RPE Detachments

Regular

Rounded

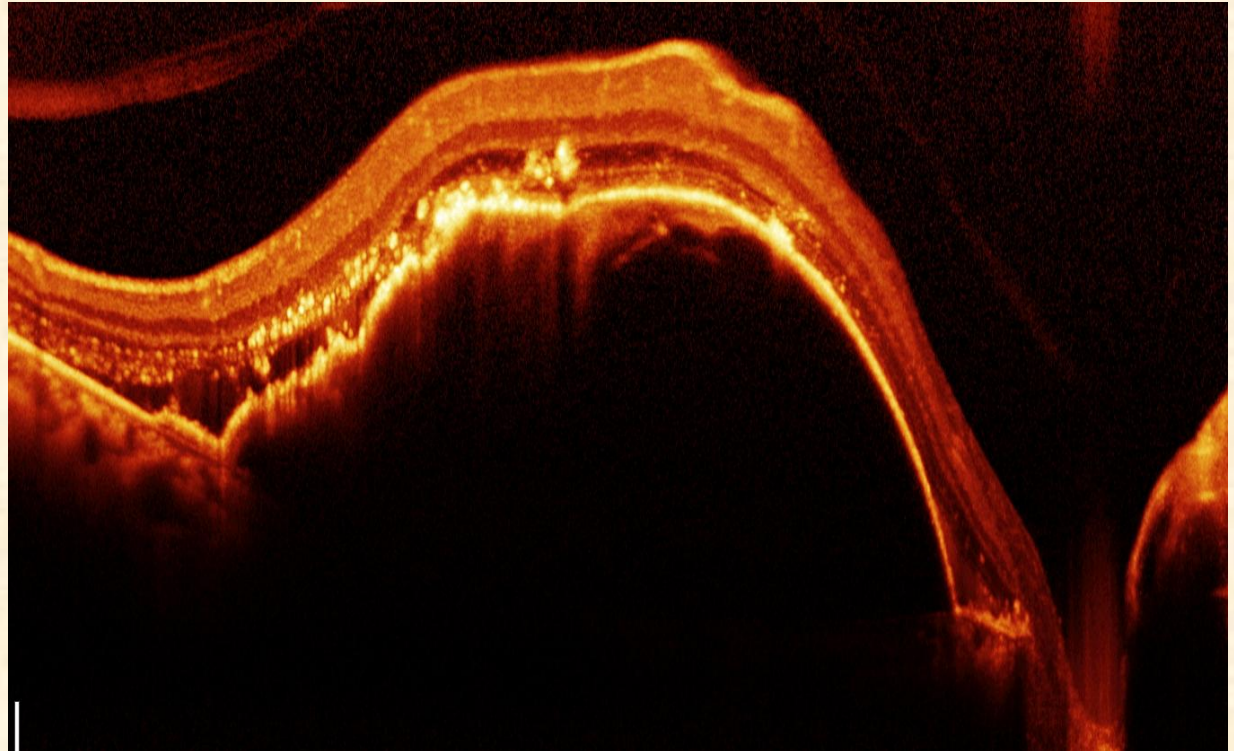
Single or

Multiple

Irregular

Smooth

Bump



Qualitative

Anterior

Hemorrhage

Exudates

Retinal blood vessels

Posterior

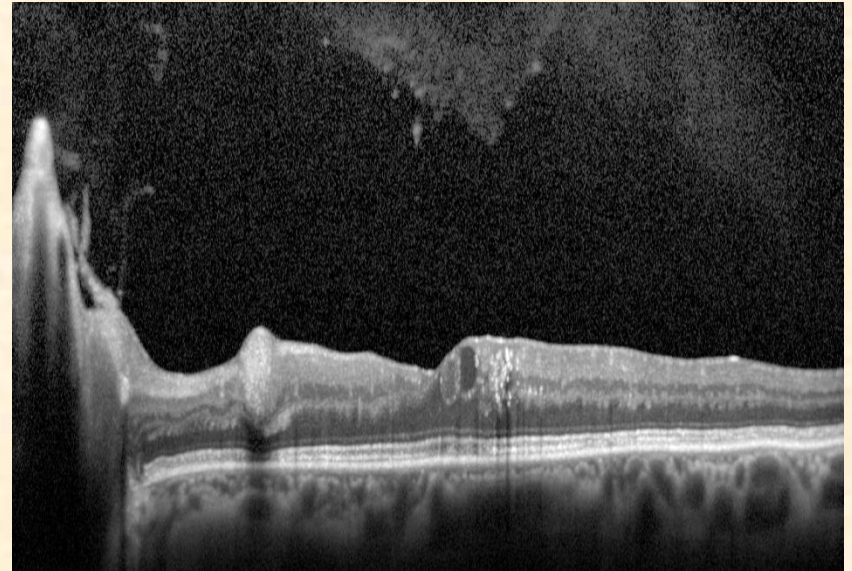
Neovascular membrane

RPE thickening

Accumulation of pigment

Choroidal neovascularization

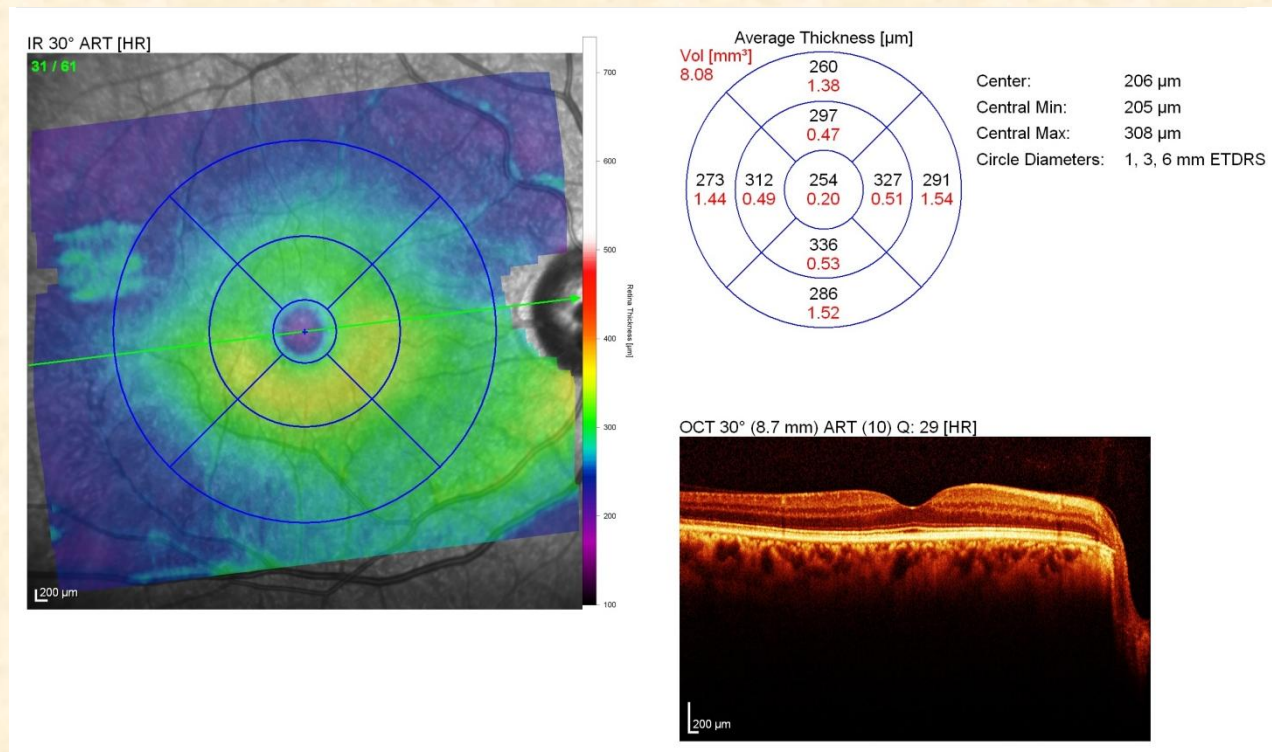
Retinal scar



Quantitative Interpretation

Quantitative analysis

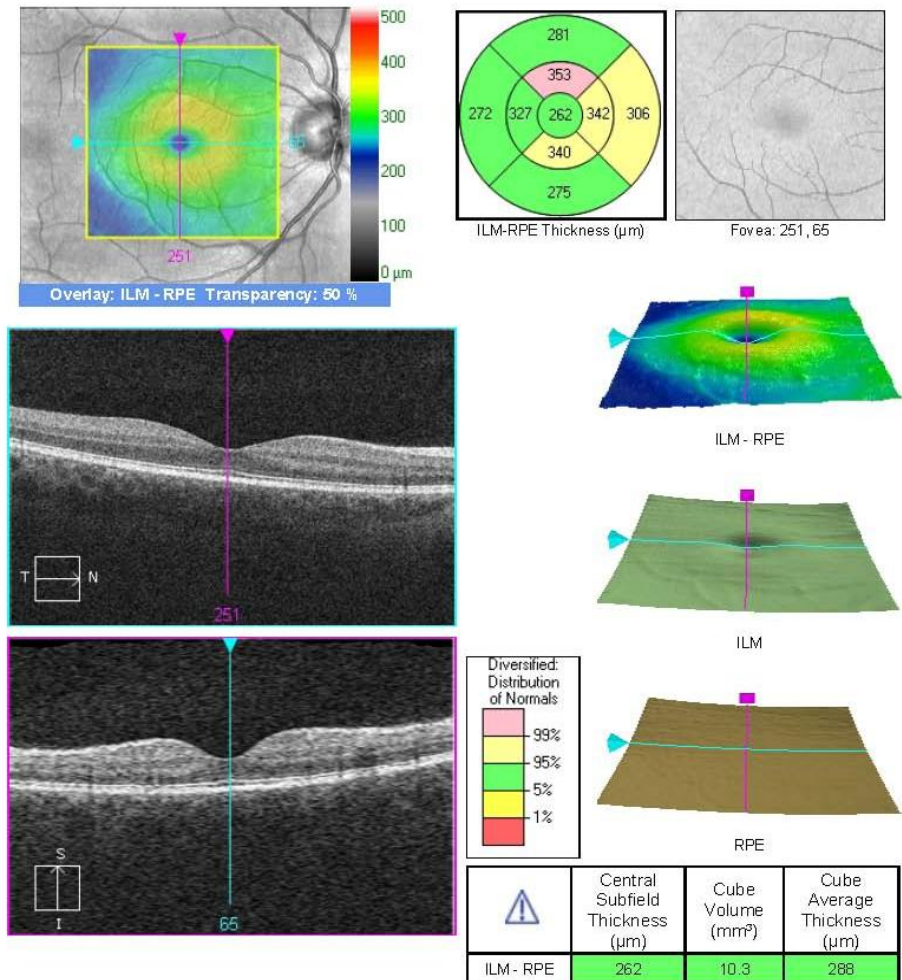
- Thickness
- Volume
- Area



Quantitative Interpretation

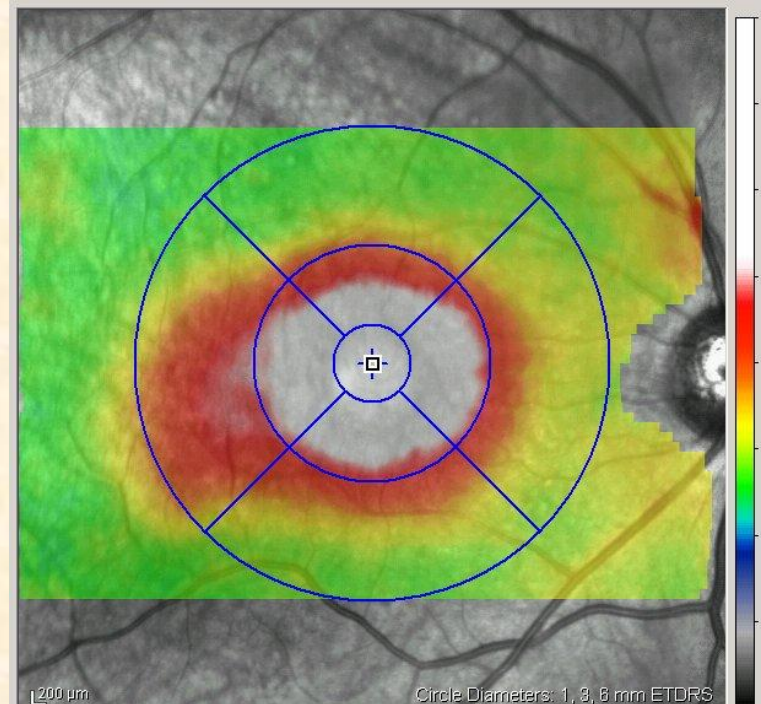
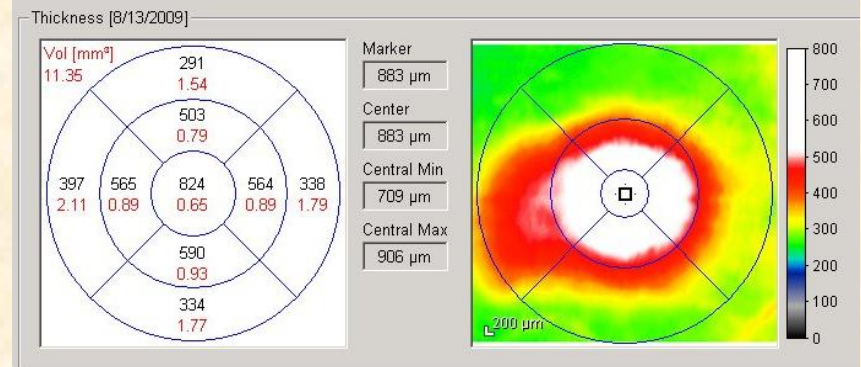
Quantitative

- Thickness
- Volume
- Area



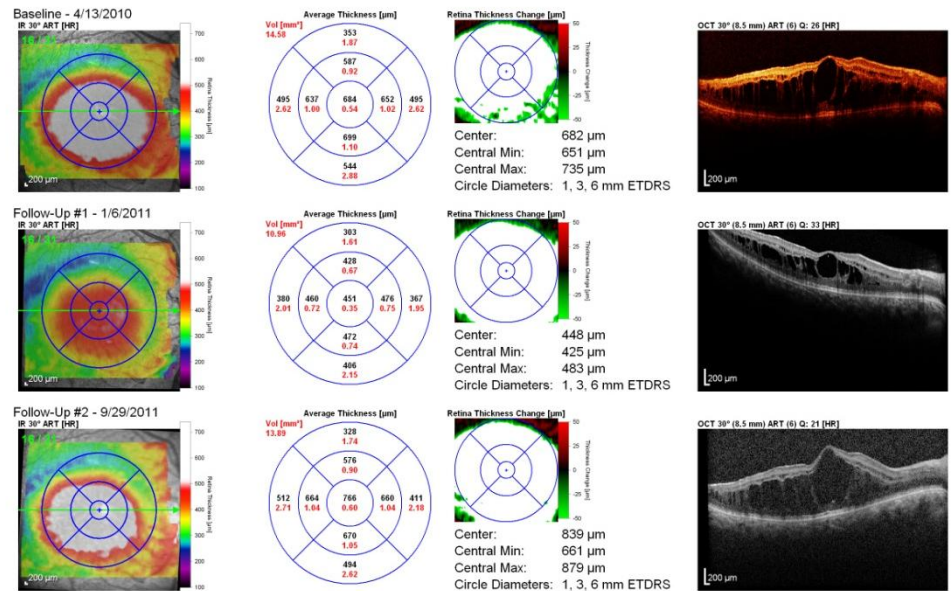
Retinal Thickness

- Increased
- Decreased
- Variations in thickness of a layer
 - (e.g., nerve fibers)
- Retinal map
- Volume

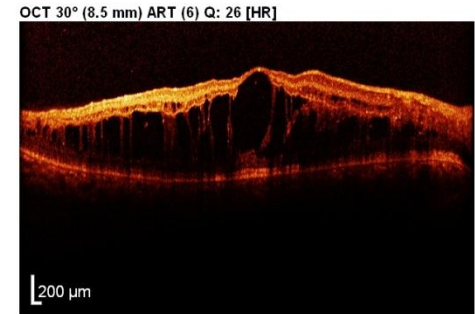
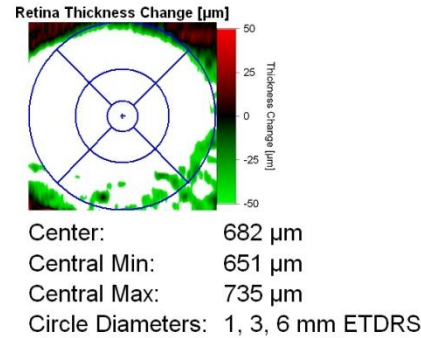
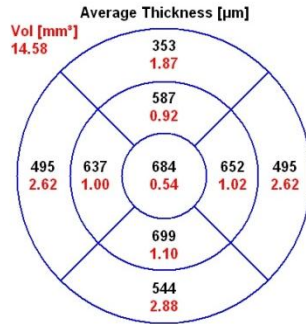
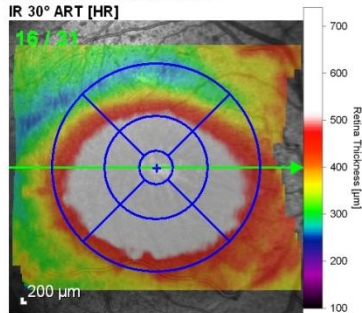


Thickness

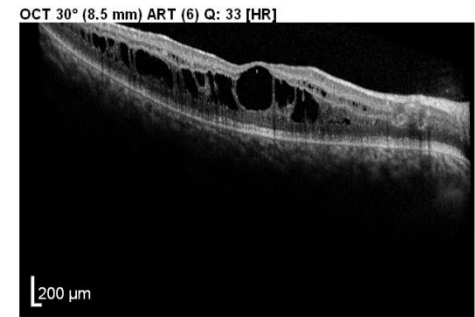
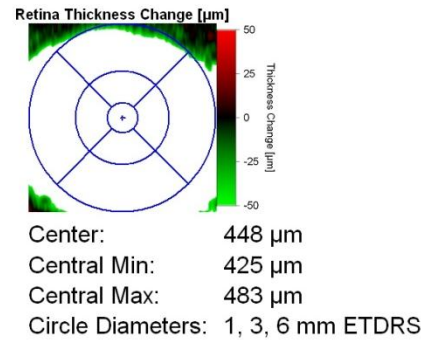
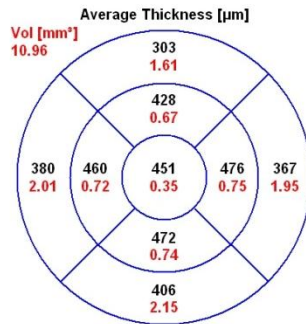
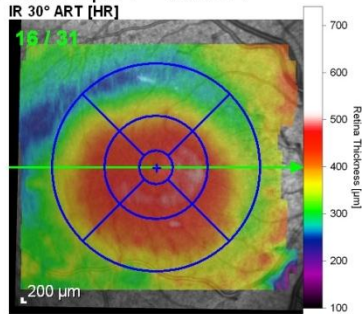
- Quantify thickness and volume of retina
- RNFL thickness
- Comparison of numerical data
 - natural course of a disease
 - response to therapy.



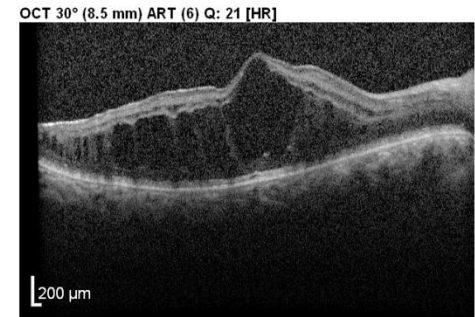
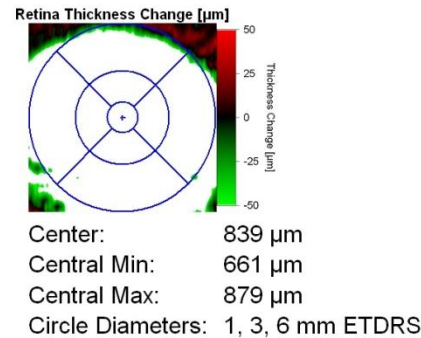
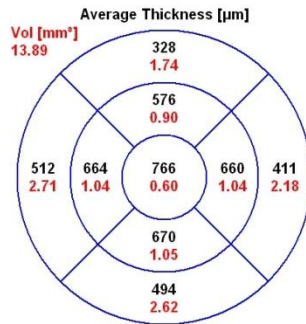
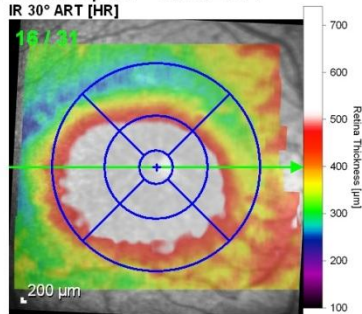
Baseline - 4/13/2010



Follow-Up #1 - 1/6/2011

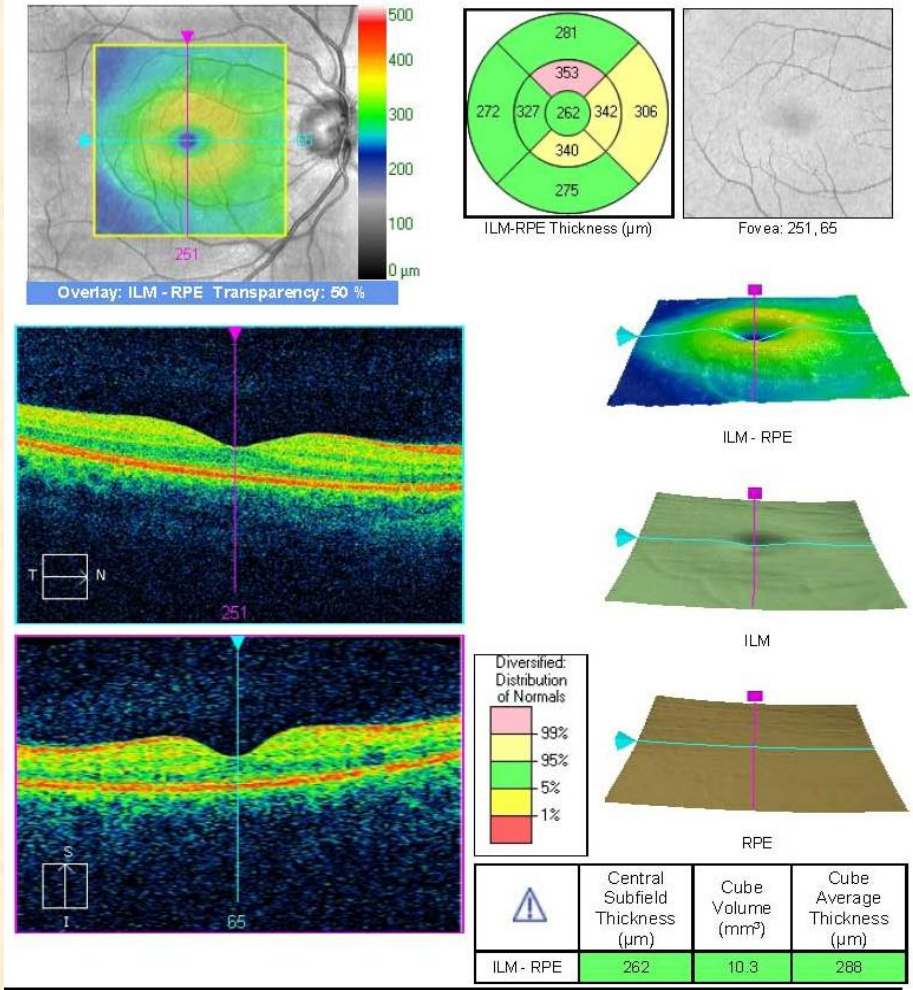


Follow-Up #2 - 9/29/2011



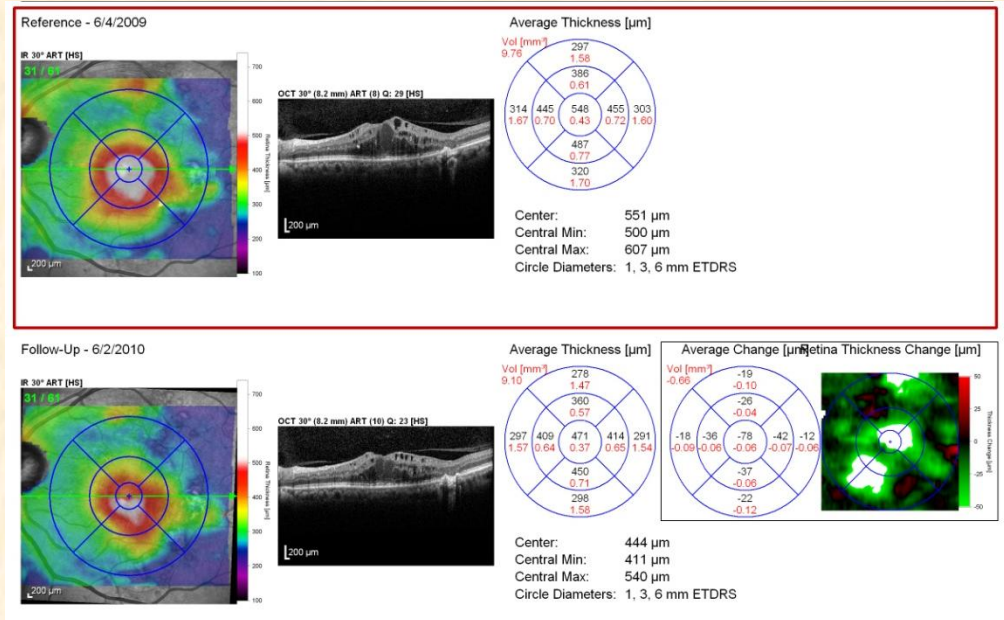
Macular Map

Thickness data
 Thickness -
 Topographic and
 Comparison to
 normal -Traffic
 light



Macular Map

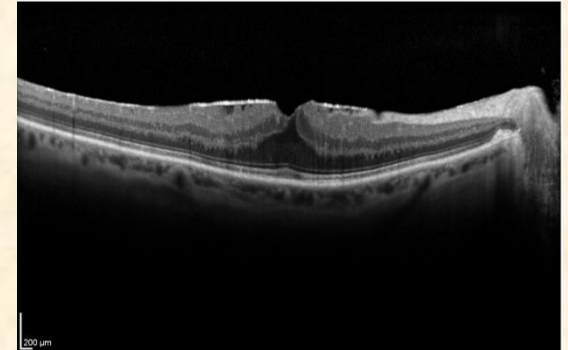
- Volume, cube, thickness maps
- Immediate visualization of increased or decreased thickness.
- Follow progression of edema or atrophy more precisely



Retinal Thickening

• ***Retinal edema***

- Simple edema
- Cystoid macular edema (CME)
- Chronic edema with serous detachment of the retina



Vitreoretinal traction

- *ERM*--diabetic retinopathy or interface syndromes
- Pulling superficial layers of the retina
- Deformations in the profile and secondary edema

Retinal Thinning

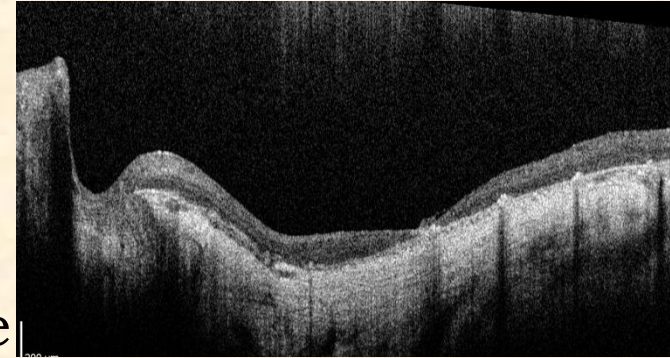
- *Atrophic degeneration.*
- 150 or even 100 microns.

RPE atrophy,

- which are thinner and less reflective
- owing to loss of pigment.

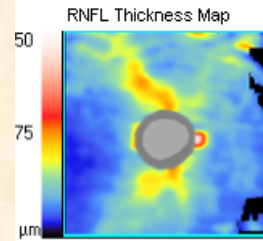
The hyporeflective RPE

- allows increased penetration of light into the
- choroid. The reflectivity is increased because light
- absorption is reduced at the retina and the RPE.
- *Laser scars, fibrous scars. Scars consequent to laser*
- treatment, chorioretinitis or trauma indicate
- atrophy of the retina, with thickening of the
- pigment epithelium/choriocapillaris complex.

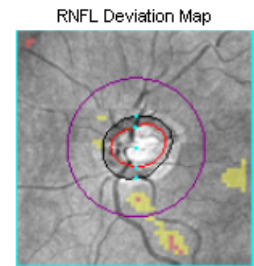
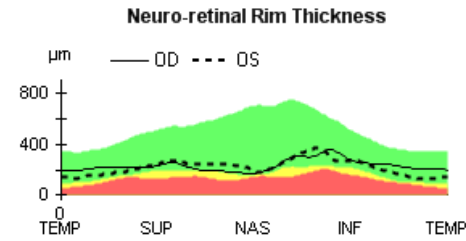
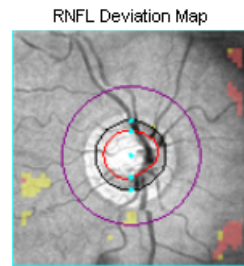
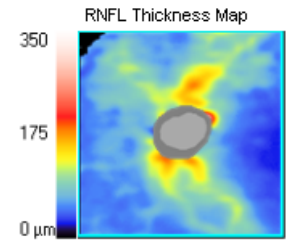


RNFL Thickness

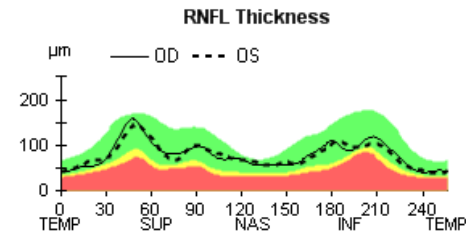
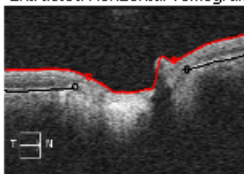
- Thickness Data
- Topographic
- Traffic Light Comparison



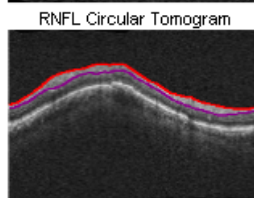
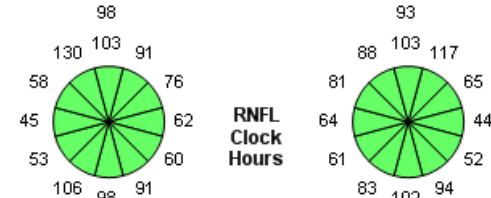
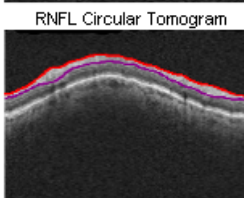
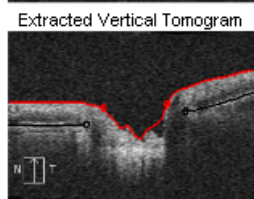
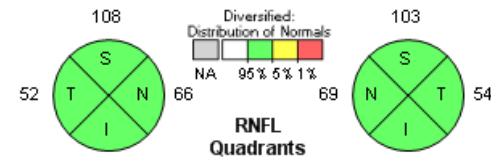
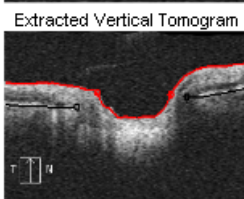
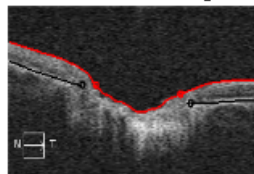
	OD	OS
Average RNFL Thickness	81 μm	80 μm
RNFL Symmetry	96%	
Rim Area	1.12 mm^2	1.00 mm^2
Disc Area	2.43 mm^2	2.15 mm^2
Average C/D Ratio	0.72	0.72
Vertical C/D Ratio	0.69	0.66
Cup Volume	0.315 mm^3	0.311 mm^3



Disc Center (-0.03,-0.15) mm

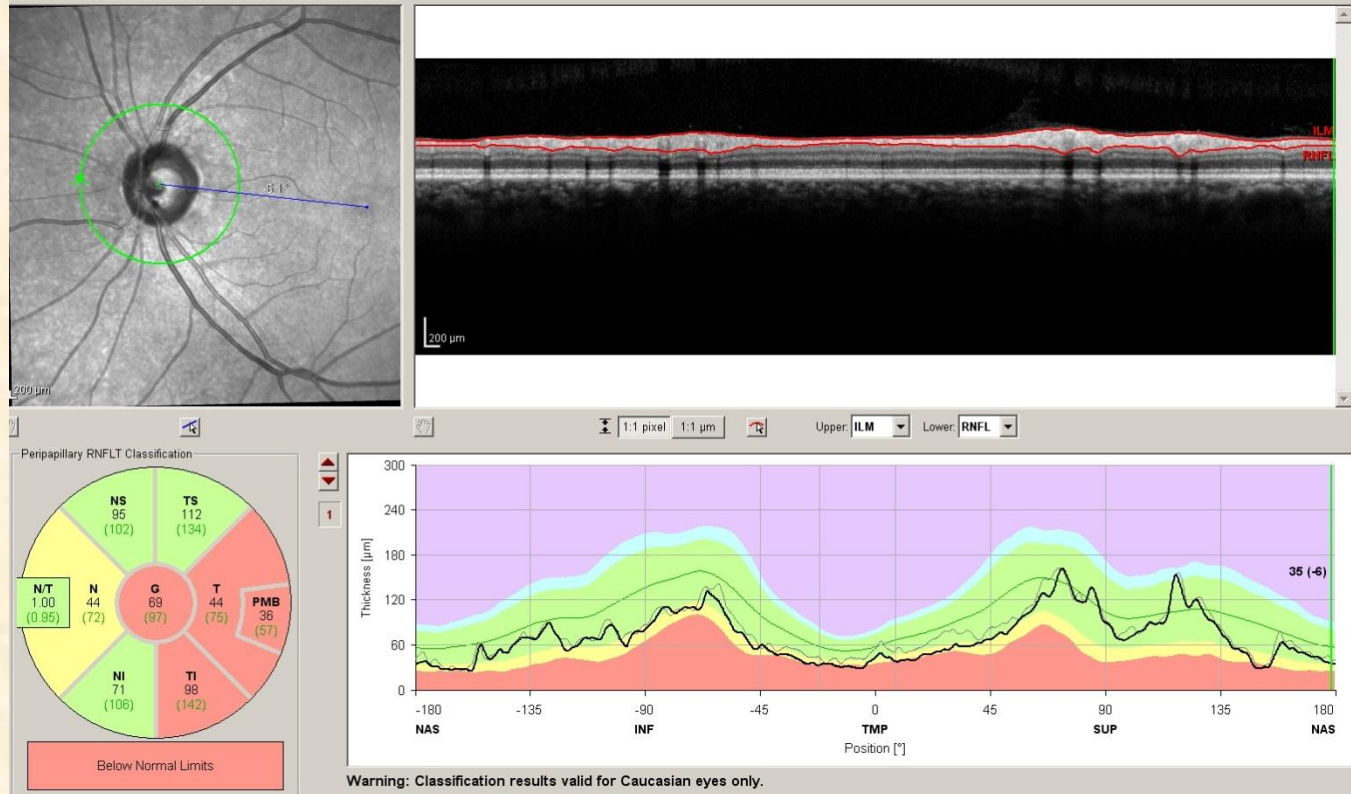


Disc Center (0.00,0.06) mm



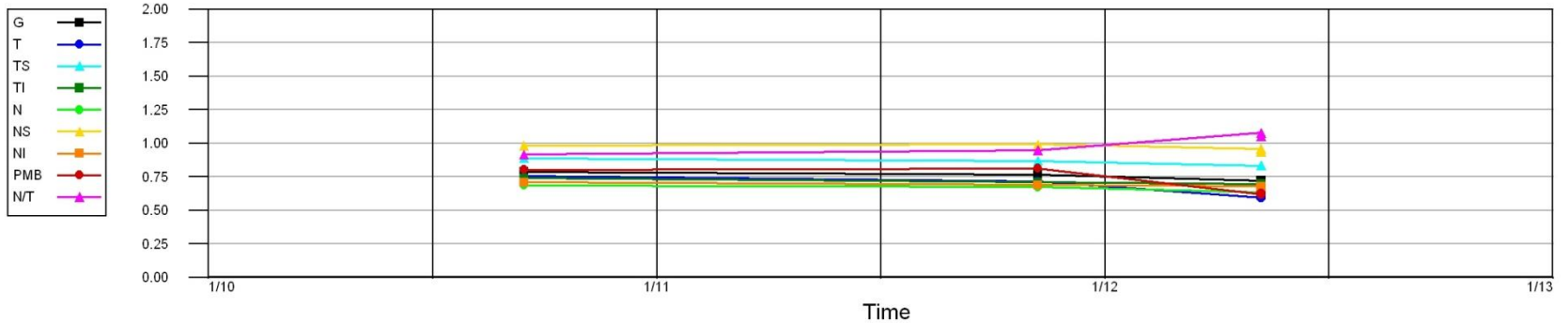
RNFL Thickness

- TSNIT
- NITSN
- PMB
- Changes over time



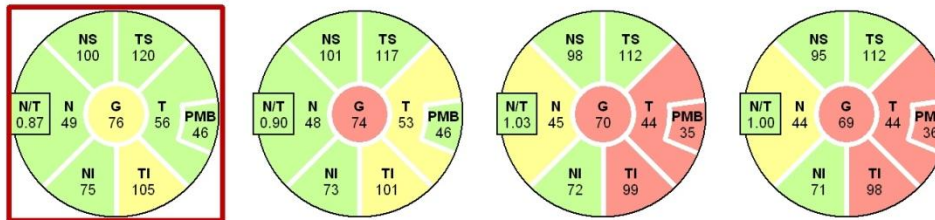
RNFL thinning

Normalized RNFL Thickness

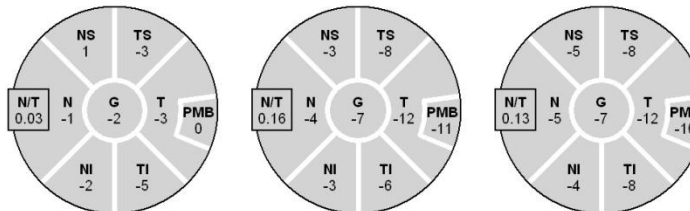


Exam Date Sep/15/2010 Nov/8/2011 May/8/2012 May/8/2012

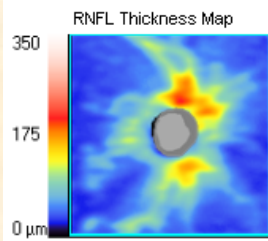
RNFL Thickness



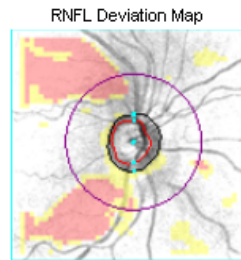
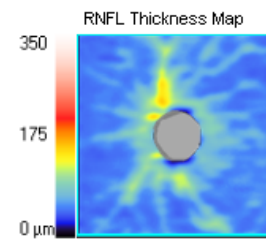
Difference to Selected Reference



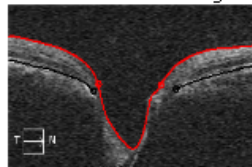
RNFL thinning



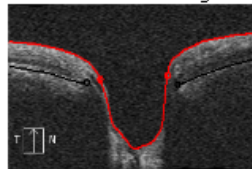
	OD	OS
Average RNFL Thickness	76 μm	64 μm
RNFL Symmetry	74%	
Rim Area	0.71 mm^2	0.36 mm^2
Disc Area	1.54 mm^2	1.67 mm^2
Average C/D Ratio	0.75	0.91
Vertical C/D Ratio	0.76	0.90
Cup Volume	0.491 mm^3	1.181 mm^3



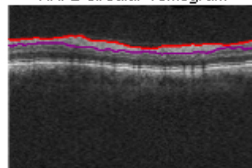
Disc Center (0.12,0.12) mm
Extracted Horizontal Tomogram



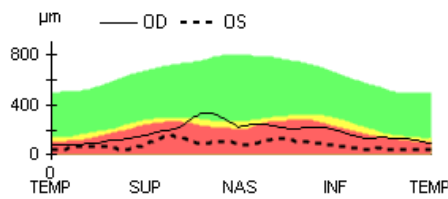
Extracted Vertical Tomogram



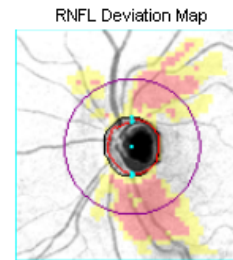
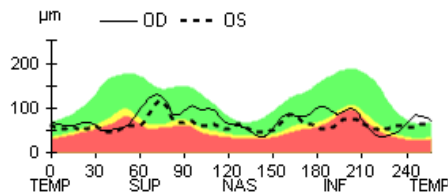
RNFL Circular Tomogram



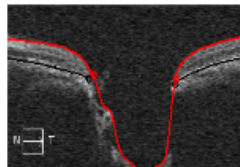
Neuro-retinal Rim Thickness



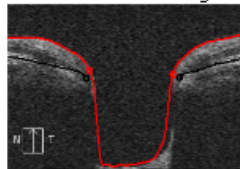
RNFL Thickness



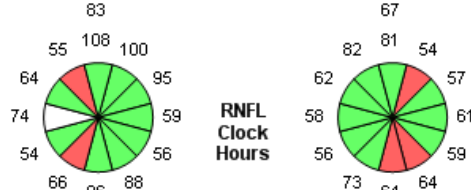
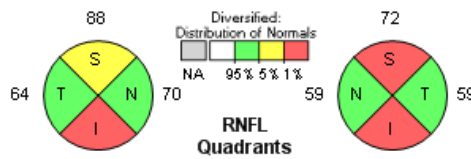
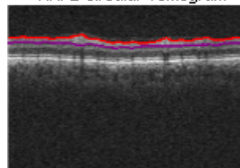
Disc Center (-0.03,0.00) mm
Extracted Horizontal Tomogram



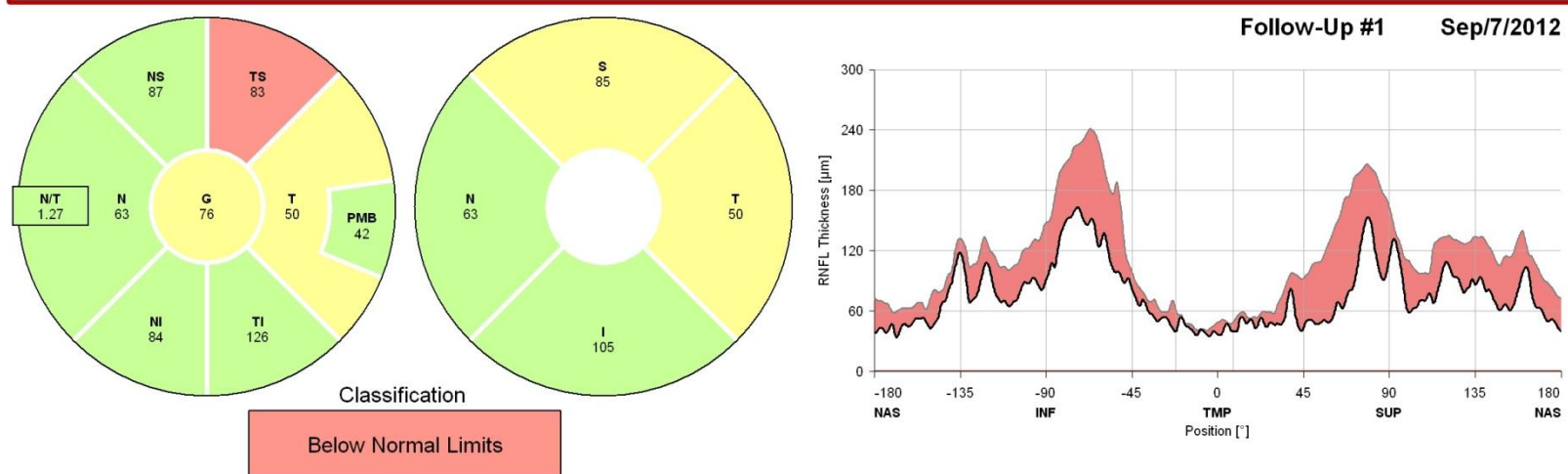
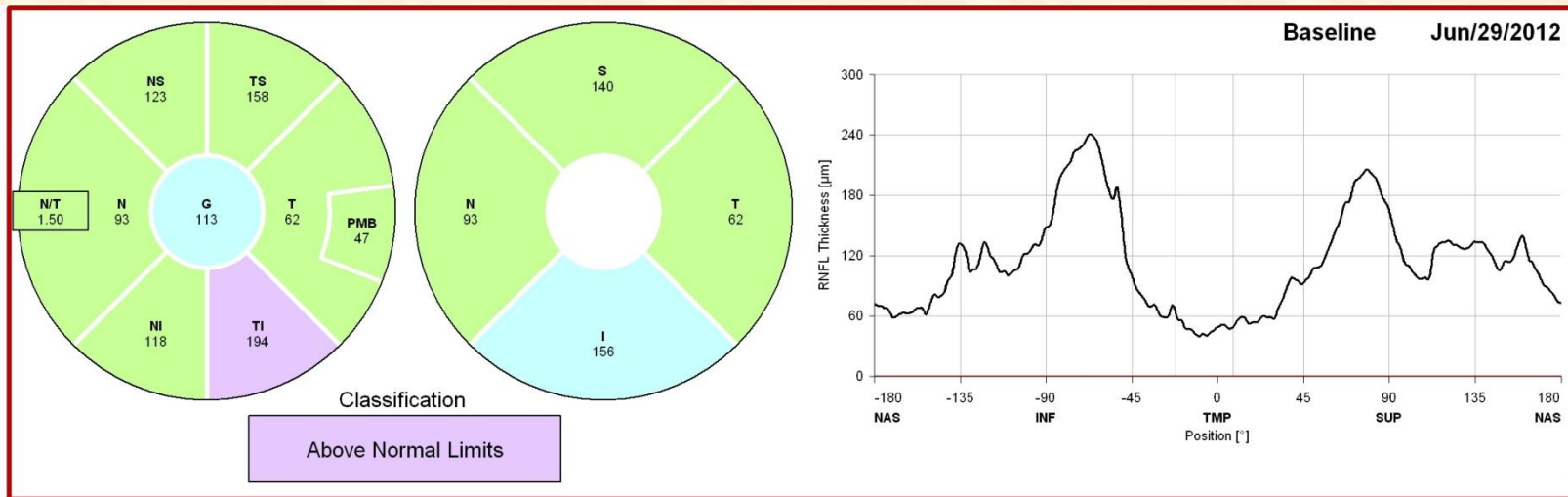
Extracted Vertical Tomogram



RNFL Circular Tomogram



RNFL thinning



Warning: Classification results valid for Caucasian eyes only.

RNFL Thickening

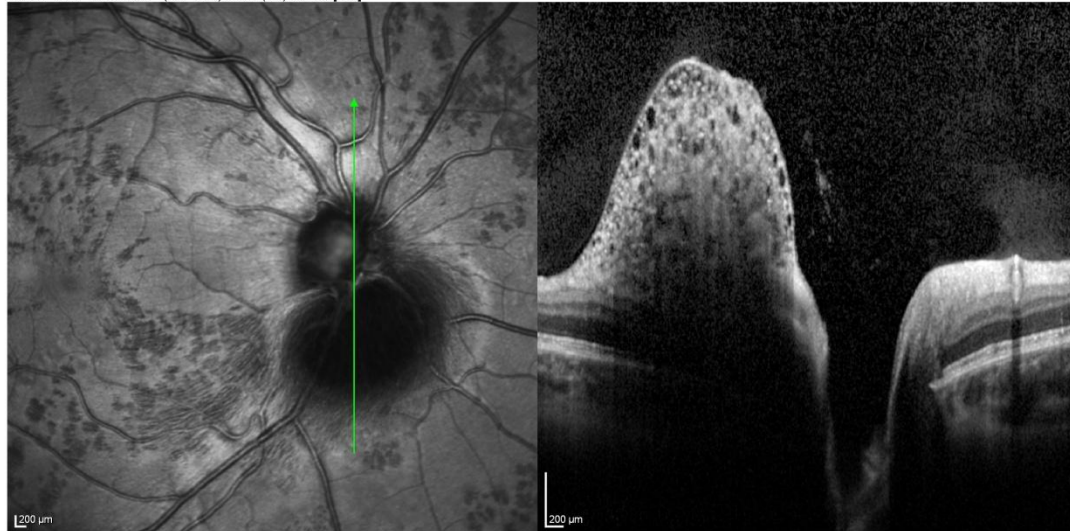
Overview Report
SPECTRALIS® Tracking Laser Tomography

HEIDELBERG
ENGINEERING

Diagnosis: ---

Comment: ---

IR 30° ART + OCT 20° (5.7 mm) ART (38) Q: 30 [HS]

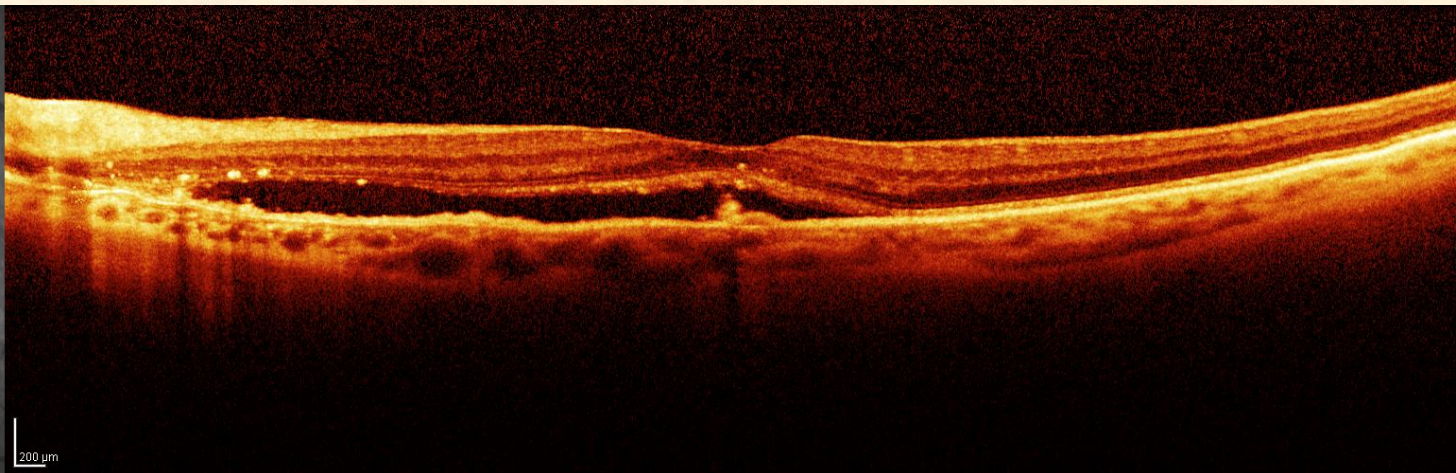
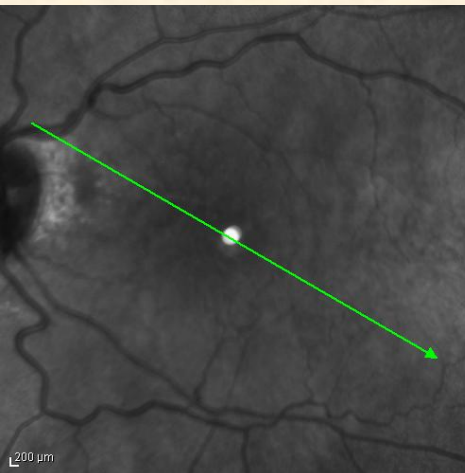


Notes:

Date: 10/12/2012

Signature:

RNFL Thickening



4/30/2009, OS
#59 IR&OCT 30° ART

“Descriptive Interpretation”

- Using common terms to describe the morphology, reflectivity, thickness, volume and area of tissue being scanned with OCT

- **Excellent reference to help you**
- ***Guide to Optical Coherence Tomography Interpretation***, Brancato R, Lombroso B et al; I.N.C. Innovation-News-Communication, Roma, IT 2005

